

The diagnosis and management of synovial cysts: Efficacy of surgery versus cyst aspiration

Nancy E. Epstein, Jamie Baisden¹

Clinical Professor of Neurological Surgery, The Albert Einstein College of Medicine, Bronx, NY, 10461, and Chief of Neurosurgical Spine and Education, Winthrop University Hospital, Mineola, NY 11501, ¹Department of Neurosurgery, The Medical College of Wisconsin, 9200 W Wisconsin Ave, Milwaukee WI 53226

E-mail: *Nancy E. Epstein - nancy.epsteinmd@gmail.com; Jamie Baisden - jbaisden@mcw.edu

*Corresponding author

Received: 17 February 12

Accepted: 4 April 12

Published: 17 July 12

This article may be cited as:

Epstein NE, Baisden J. The diagnosis and management of synovial cysts: Efficacy of surgery versus cyst aspiration. *Surg Neurol Int* 2012;3:S157-66.

Available FREE in open access from: <http://www.surgicalneurologyint.com/text.asp?2012/3/4/157/98576>

Copyright: © 2012 Epstein NE. This is an open-access article distributed under the terms of the Creative Commons Attribution License, which permits unrestricted use, distribution, and reproduction in any medium, provided the original author and source are credited.

Abstract

Background: The surgical management of lumbar synovial cysts that have extruded into the spinal canal remains controversial (e.g. decompression with/without fusion).

Methods: The neurological presentation, anatomy, pathophysiology, and surgical challenges posed by synovial cysts in the lumbar spine are well known. Neurological complaints typically include unilateral or, more rarely, bilateral radicular complaints, and/or cauda equina syndromes. Anatomically, synovial cysts constitute cystic dilatations of synovial sheaths that directly extrude from facet joints into the spinal canal. Pathophysiologically, these cysts reflect disruption of the facet joints often with accompanying instability, and potentially compromise both the cephalad and caudad nerve roots.

Results: Aspiration of lumbar synovial cysts, which are typically gelatinous and non-aspirable, and typically performed by "pain specialists" (e.g. pain management, rehabilitation, radiologists, others) utilizing fluoroscopy or CT-guided aspiration, is associated with 50–100% failure rates. Surgical decompression with/without fusion (as the issue regarding fusion remains unsettled) results in the resolution of back and radicular pain in 91.6–92.5% and 91.1–91.9% of cases, respectively.

Conclusions: After a thorough review of the literature, it appears that the treatment with the best outcome for patients with synovial cysts is cyst removal utilizing surgical decompression; the need for attendant fusion remains unsettled. The use of an alternative treatment, percutaneous aspiration of cysts, appears to have a much higher recurrence and failure rate, but may be followed by surgery if warranted.

Key Words: Decompression, extruded lumbar synovial cysts, failed aspiration, failed techniques, fusion

Access this article
online

Website:
www.surgicalneurologyint.com

DOI:
10.4103/2152-7806.98576

Quick Response Code:



INTRODUCTION

Synovial cysts that have extruded into the lumbar spinal canal may be managed by "pain specialists" (e.g. pain management, rehabilitation, radiologists, others) utilizing

fluoroscopy or computed tomography (CT)-guided aspiration techniques, or by spinal surgeons utilizing decompression with or without fusions. In this review, we explore the pathology, diagnosis, and relative efficacy of the multitude of techniques available for addressing

synovial cysts arising in the lumbar spinal canal [Figures 1–12, Video, and Table 1].

ANATOMY OF SYNOVIAL CYSTS

Lumbar synovial cysts are cystic dilatations of synovial sheaths that directly emanate from facet joints and extrude into the spinal canal. When Tillich *et al.* correlated magnetic resonance (MR) scans with surgical findings for 18 patients with synovial cysts, the cysts measured an average of 16 mm (ranged 10–28 mm); 3 additionally (17%) contained hemorrhages.^[25]

Two fluid types are found within these cysts.^[11] The

most common gelatinous cysts are not easily aspirated, while the less frequently encountered serosanguinous cysts, containing less viscous fluid, may be somewhat more amenable to percutaneous aspiration. Nevertheless, whether or not fluid can be removed from within these cysts, the fibrous capsule that remains continues to contribute to the clinically relevant compression of the thecal sac and nerve root.^[11]

PATHOLOGY OF SYNOVIAL CYSTS

In Wilby *et al.*'s study, 27 consecutive patients with stenosis undergoing laminectomy and *en bloc* resection of the ligamentum flavum and facet joints yielded 51

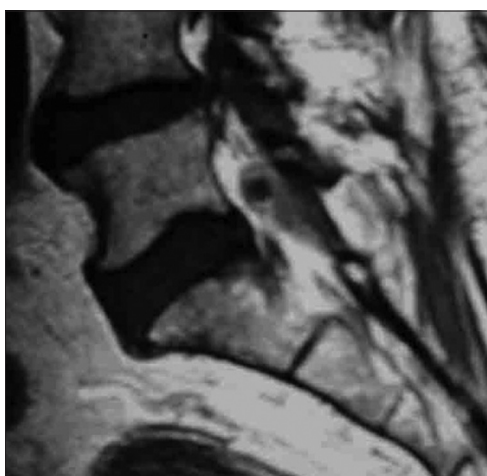


Figure 1: On the T2-weighted parasagittal MR scan of the lumbar spine at the L5–S1 level, the large, isointense, fibrinous capsule of the synovial cyst (isointense mass) contributes to the majority of dorsolateral thecal sac compression, with only a small component coming from the hypointense, fluid-filled cyst

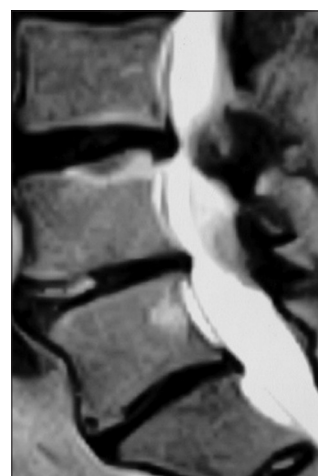

Figure 2: On the T2-weighted parasagittal MR scan, a massive L4–L5 heterogeneous synovial cyst (isointense capsule, hypointense cyst) contributes to marked thecal sac compression extending all the way to the L3–L4 level

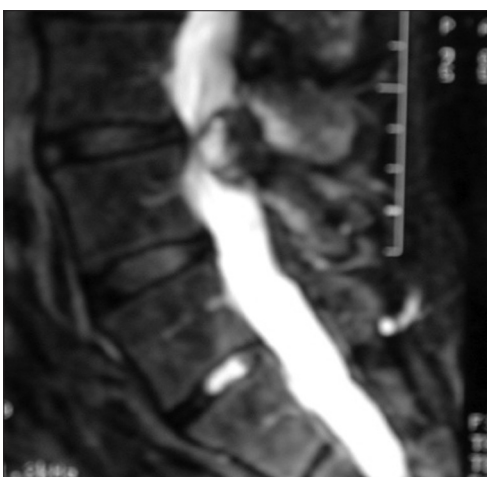

Figure 3: The parasagittal T2-weighted MR demonstrates a heterogeneous dorsolateral cyst resulting in thecal sac compression at the L3–L4 level. Notably, it contains hyperintense, isointense, and hypointense elements

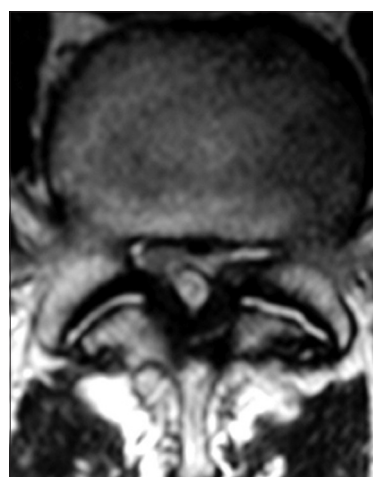


Figure 4: On the axial T1-weighted MR image, congenital lumbar stenosis is exaggerated by the presence of ossification of the yellow ligament (hypointense) resulting in marked bilateral, dorsolateral thecal sac compression. Additionally, fluid is seen in both facet joints, indicating the presence of moderate degenerative changes and instability, accompanied by a broad-based right-sided hyperintense synovial cyst that fills the dorsal aspect of the spinal canal

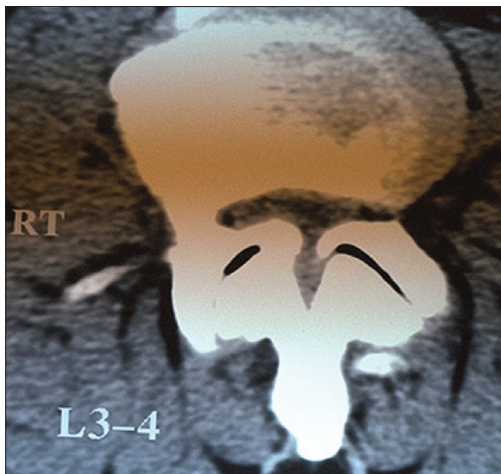


Figure 5: The axial non-contrast lumbar CT scan demonstrates marked congenital stenosis accompanied by superior facet hypertrophy. Note that air (hypodense) within the facet joints is indicative of instability. With such severe spinal stenosis, epidural steroid injections would likely fail or result in dural fistulas as there is essentially no epidural compartment. Similarly, if this patient had a synovial cyst, there would have been virtually no space available for "cyst aspiration"

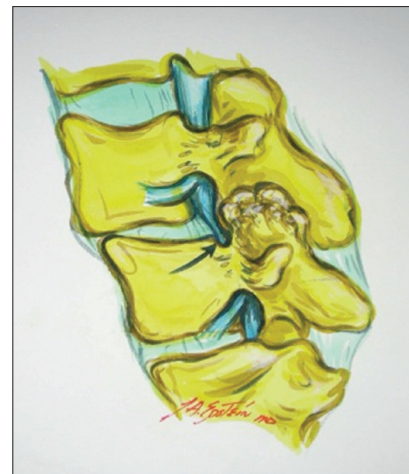

Figure 6: The illustration demonstrates the marked arthrotic changes of the facet joints that occur with degenerative spondylolisthesis at the L4–L5 level that contribute to marked impingement on the superior, foraminally/far laterally exiting L4 nerve root

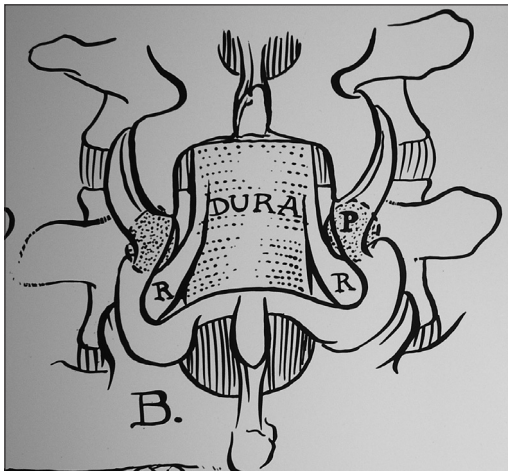


Figure 7: The illustration demonstrates an L4–L5 partial laminectomy (coronal hemilaminectomy) with medial facetectomy/foraminotomy that deliberately spares the pars interarticularis bilaterally, overlying the pedicles (P), to enhance stability. Observe the decompression of the thecal sac (DURA) and bilateral inferiorly exiting L5 nerve roots (R) that are now free in the lateral recesses. For the smaller synovial cysts, such a single-level decompression may suffice

specimens and 28 synovial cysts.^[27] Specimens were compared to 47 comparable cadavers. Articular cartilage and bone fragments were embedded in the walls of 89% of cysts, while a bursa-like channel averaging 12 mm in length extended between the medial facet joint and yellow ligament in 75% of cases. Synovial cyst formation was, therefore, attributed to blockage of these channels from osteoarthritic changes consisting of fragments of cartilage, bone, granulation tissue, and scar.^[27] When

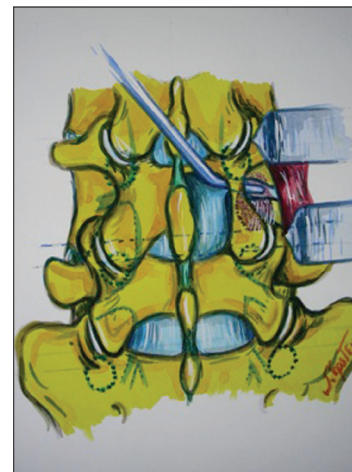

Figure 8: A right-sided near-complete L4 hemilaminectomy has been performed, allowing a dental tool to be passed underneath the pars interarticularis extending through the superior L4–L5 foramen overlying the foraminally/far laterally exiting L4 nerve root. In cases where minimal stenosis is present, an L4–L5 synovial cyst that typically extends to the L3–L4 level will require a full L4 hemilaminectomy with medial facetectomy/foraminotomy at the L3–L4 levels in order to adequately visualize the superior L4 nerve root and avoid damaging it during the dissection of the superior portion of the synovial cyst capsule

Kusakabe *et al.* studied 46 juxtafacet cysts, they similarly documented a communication channel between the cyst and the joint in all cases, along with “moderate to severe facet degeneration.”^[12]

En bloc specimens consisting of medial facetectomy and the attached ligamentum flavum and cysts revealed three shapes: small protrusions, semicircular cysts, or round cysts.^[12] Additionally, cyst walls contained elastic and collagen fibers that had undergone fibrinoid

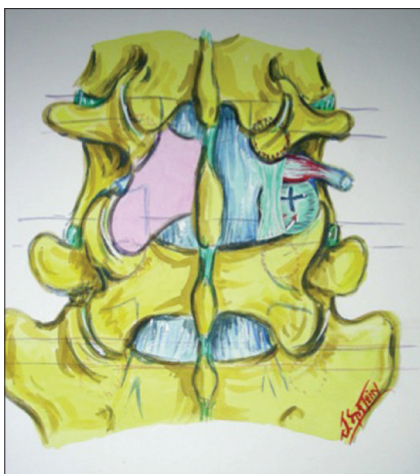


Figure 9: In this illustration, a full inferior facetectomy with hemilaminectomy in the presence of minimal stenosis (pink) was required to address a large synovial cyst extending from the L4–L5 to the L3–L4 level. More typically, with moderate or marked stenosis, this would require a full laminectomy. Here, the inferior facetectomy facilitated full visualization of the foraminally/far laterally exiting L4 nerve root, the thecal sac, and inferiorly exiting L5 root. Additionally noted is a full right L4–L5 facetectomy on the right side, performed to address a far lateral L4–L5 disc herniation (+ sign)

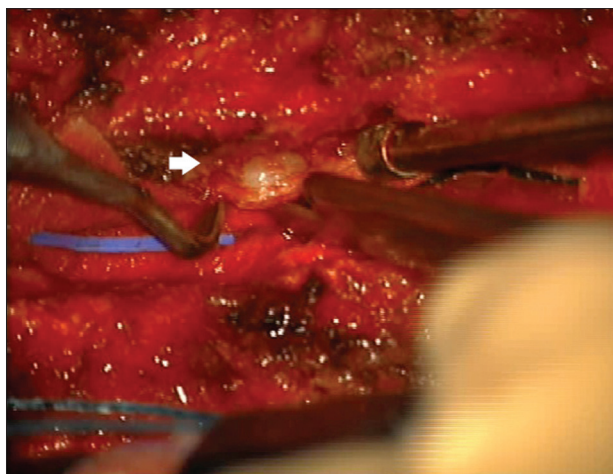


Figure 10: This intraoperative photograph (see also mpeg) taken from under an operating microscope shows a right-sided L4–L5 synovial cyst (open arrow) that extended cephalad toward the L3–L4 level. Following an L3–L5 laminectomy with medial facetectomy and foraminotomy at both the L3–L4 and L4–L5 levels (note: more extended right-sided foraminal dissection was warranted), a right-sided thick, fibrous, and gelatinous filled cyst was decompressed and excised/teased away (dense adhesions) from the underlying dura, L4, and L5 nerve roots

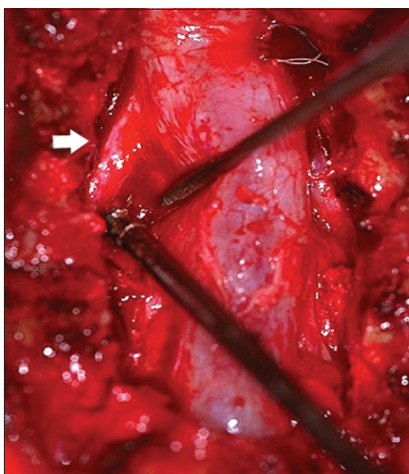


Figure 11: Following excision of an L4–L5 massive left-sided synovial cyst extending to the L3–L4 level, this intraoperative photograph reveals the freed superiorly and foraminally exiting L4 nerve root (open arrow), and the decompressed thecal sac and inferior L5 nerve root. Additionally, the Penfield elevator and suction show the massive dimensions of the cavity previously occupied by the synovial cyst

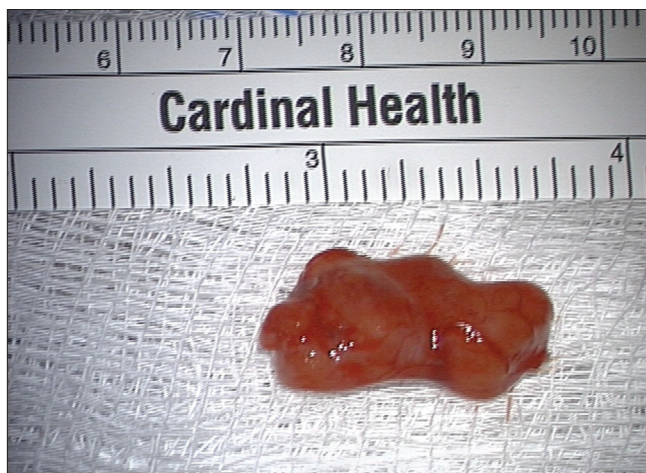

Figure 12: The thick, fibrous, and gelatinous synovial cyst removed in this case measured 2.5 cm. Intraoperative dissection here warranted laminectomy from L3–L5 with extended foraminal dissection on the right for exposure of the synovial cyst extending from L4 to L5 level cephalad. Note, how the Penfield elevator is utilized to dissect the capsule away from the underlying dura. This is feasible only if there is truly a plane present, as in many instances, the capsule is densely adherent to the underlying dura (See Video). The cyst once skeletonized, is ruptured with the Kerrison rongeur. Following decompression of the cyst which contained thick, gelatinous tissue, the margins of the residual capsule may be more readily defined and dissected away from the underlying thecal sac and superiorly/foraminally, and inferiorly/foraminally exiting nerve roots (See Video)

degeneration, or alternatively often there was no synovial lining. Furthermore, cysts often contained fibrinoid and myxoid degeneration. Similar pathologic findings were identified in Pytel’s study of 985 surgical specimens with a 1.6% incidence of synovial cysts and another 5.3% of cases with synovial tissue often embedded within disc material.^[19]

CT AND MR DIAGNOSIS OF SYNOVIAL CYSTS

When Bydon *et al.* reviewed the surgical management of

Table 1: Summary of literature regarding outcomes of varying management strategies for synovial cysts

Author	No. of patients with synovial cysts (Subset DS) (Subset LY)	Operative technique	% Excellent/good outcomes (second operations/complications)
Pirotte ^[18]	46	46 MIS	89.1% (10.9% cyst recurrence)
Metellus ^[16]	77 (37 DS)	77 LAM	97.4% (1 secondary fusion)
Deinsberger ^[4]	31 (14 DS)	31 MicroS	80.7%
Epstein ^[5]	45 No DS 35 DS	80 LAM	58% No DS 63% DS <i>SF-36 physical function</i> +44 No DS +38 DS
Epstein ^[8]	60 (48 DS) (2 LY)	60 LAM NF	85% (15 Pseudarthrosis) (2 Secondary fusion)
Bydon ^[3]	966	811 LAM 155 IF/NF	92.5% LAM 91.1% LAM IF (6.2% LAM secondary fusion)
Weiner ^[26]	46	23 LAM 23 LAM/IF	88% (15% Secondary fusion) (3 LAM, 4 LAM IF)
Xu ^[28]	167 (195 synovial cysts)	90 LAM 18 LAM NF 56 LAM IF	91.6% Back pain 91.9% Radicular pain <i>3 Years: Recurrent</i> 21.6% Back pain 11.8% Leg pain 3% Recurrent cysts
Schultz ^[22]	45	25 MicroS 20 CT	100% MicroS 40% CT
Allen ^[1]	32	32 Fluoro	72% (37.5% Cyst recurrence) (11 of 12 repeat CT rupture) (6 of 11 required surgery)
Martha ^[15]	100	100 Fluoro	66% (54% second surgery)

MIS: Minimally invasive surgery, MicroS: Microsurgery, LAM: Laminectomy, NF: Non-instrumented fusion, IF: Instrumented fusion, Fluoro: Fluoroscopic-guided cyst aspiration, CT: CT-guided cyst aspiration, DS: Degenerative spondylolisthesis, LY: Spondylolysis

966 spinal synovial cysts (1970–2009) in 82 studies, 96.2% were in the lumbar (75.4% at the L4–L5 level), 2.6% in the cervical, and 1.2% were in the thoracic spine.^[3]

Although CT studies more readily diagnose lumbar stenosis and ossification of the yellow ligament (OYL) associated with synovial cysts, MR studies better delineate the severity and extent of the cysts themselves [Figures 1–5].

In Pirotte *et al.*'s series of 46 consecutive patients (1990 and 2001), CT documented cysts in 19 of 30 cases, while MR documented all 30 cysts.^[18] Cysts predominated at the L4–L5 level (61%) and were accompanied by disc degeneration/spondylosis in 54% of cases.

Liu *et al.* observed that CT scans could document cysts adjoining facet joint capsules, but noted that MR revealed more specific information [Figures 1–5].^[14] On short TR/TE, MR images revealed slightly hyperintense (3 cases) or isointense (1 case) cysts, while long TR/TE showed hyperintensities (2 cases) or hypointensities (others).^[14] Furthermore, hypointense signals surrounding cysts often indicated rim calcification better confirmed on CT.

MR can additionally differentiate between the hyperintense signals characteristic of fluid within synovial cysts and focal hypointense signals typical of hypertrophy and/or ossification of the yellow ligament [Figures 1–12].^[11] Unfortunately, MR scans cannot readily distinguish between the more frequently encountered gelatinous (non-aspirable) versus the rarer serosanguinous (more readily aspirated) cysts.^[11]

MR studies further demonstrate the large, thick, fibrous, and often calcified capsules surrounding the fluid within the synovial cysts, which are predominantly responsible for the majority of neural/dural compression and neurological dysfunction [Figures 1–4]. Moreover, enhanced MR studies document dense adhesions between the overlying cyst capsules and the underlying dura and nerve roots, the cephalad/foraminally exiting and the caudad/lateral recess exiting nerve roots [Figure 11]. For example, a synovial cyst at the L4–L5 level typically contributes to dural compression along with both cephalad L4 and caudad L5 nerve root compromise.

Some patients with synovial cysts exhibit no active Grade I slip (25% or less of the vertebral body width), while others exhibit instability associated with degenerative spondylolisthesis. In particular, older patients with marked degenerative changes of the facet joints accompanied by bony osteophytic bridging across facet joints and/or vertebrae on dynamic X-rays, and/or CT studies, without active motion, may not warrant fusion.

MR-documented increased fluid in the facet joints is highly correlated with degenerative spondylolisthesis and synovial cyst degeneration, and may indicate instability [Figure 4]. Alicioglu and Sut noted that facet joint osteoarthritis was present in 30 patients with degenerative spondylolisthesis, and that synovial joint effusions occurred in 24 patients with synovial cysts.^[2] Tillich *et al.* documented instability in 11 (61%) of 18 patients with synovial cysts, 6 of whom also demonstrated degenerative spondylolisthesis.^[25]

SPONTANEOUS RESOLUTION OF SYNOVIAL CYSTS

An added, albeit rare occurrence, is that occasionally

synovial cysts can spontaneously resolve. Swartz and Murtagh reported a case in which a patient originally presented with radicular pain and an MR documented L5–S1 lumbar synovial cyst.^[24] Eighteen months later, utilizing conservative medical management alone, clinical symptoms abated and the follow-up MR showed resolution/full regression of the cyst. Similarly, Ewald and Kalff reported on six cases in which synovial cysts spontaneously resolved.^[9]

NEUROLOGICAL SYMPTOMS AND SIGNS IN PATIENTS WITH SYNOVIAL CYSTS

Patients with synovial cysts typically present with unilateral or bilateral radicular pain, but rarely with cauda equina syndromes. When Bydon *et al.* evaluated 966 patients with synovial cysts from 82 studies (96.2% with lumbar lesions), 48.3% had back pain while 69.6% had radicular pain.^[3] In the study of Metellus *et al.*, 51 of 77 patients with synovial cysts exhibited radiculopathy, while 26 exhibited neurogenic claudication accompanied by motor deficit (12%), sensory loss (26%), and reflex changes (35%).^[16] Epstein assessed 35 patients with synovial cysts, with stenosis/degenerative spondylolisthesis; preoperative symptoms included low back pain (33 patients), radiculopathy (33 patients), and neurogenic claudication (26 patients), respectively.^[5]

SURGICAL MANAGEMENT

Utilizing the operating microscope is extremely helpful in avoiding cerebrospinal fluid fistulas during decompression and removal of synovial cysts as these fistulas are more likely to arise secondary to dense adhesions between the cyst capsule and underlying dura/nerve roots. In Epstein's retrospective analysis of 110 predominantly geriatric patients undergoing multilevel laminectomies with non-instrumented fusions, 5 of 10 patients who developed dural tears had attendant synovial cysts.^[7] For the 10 patients with dural tears, the average age was 74 years, and they had undergone slightly more extensive laminectomies (average 5.5 levels) and non-instrumented fusions (average 1.8 levels). Notably, all 10 patients exhibited marked OYL that extended to and through the dura in 3 patients. Alternatively, for the 100 patients without dural tears, 8 of whom also had synovial cysts, the average age was a younger 69 years, and they had undergone lesser average 5.0-level laminectomies and 1.6-level non-instrumented fusions. More critically, for these latter patients, 57 had moderate/hypertrophied OYL, while 22 showing marked OYL.^[7] Of interest, Short Form (SF)-36 outcomes at one postoperative year were comparable for both groups irrespective of the presence/absence of dural tears.

Intraoperative somatosensory evoked potential

monitoring, electromyographic monitoring, and sphincter monitoring are also useful while resecting synovial cysts. In particular, monitoring these potentials alerts the surgeon to inadvertent, excessive traction that may occur during dissection/manipulation of the cyst away from the underlying thecal sac and/or nerve roots, thereby avoiding permanent injury (e.g. cauda equina syndrome, root and sphincteric deficits).

Surgical pathology for synovial cysts

Patients with synovial cysts are also frequently symptomatic from underlying lumbar stenosis (central, lateral recess, foraminal, far lateral). Rarely, small unilateral cysts compress just the unilateral dura and the inferiorly exiting nerve root in the lateral recess. More typically, larger synovial cysts compress both the cephalad, foraminal and/or far laterally exiting nerve root, and the caudally exiting root, along with the potential for more extensive unilateral or bilateral thecal sac and/or cauda equina compromise [Figures 6–9].

For the safe excision of typically large synovial cysts, the decompression must start at the level above the cyst. This allows for safe identification of the superiorly/foraminally exiting nerve root that often only becomes visible once the synovial cyst is dorsally debulked [Figure 11]. Beginning the dissection/decompression at the immediately supradjacent spinal level will help avoid inadvertently damaging the cephalad root. Alternatively, solely decompressing from the level at which the cyst originates may risk damaging or transecting the cephalad root that is typically markedly compressed and adherent to the ventral aspect of the cyst capsule. An example of the resection technique follows. When removing an L4–L5 synovial cyst, the initial decompression should begin at the L3–L4 level with clear identification of the L4 root as it traverses the L3–L4 interspace. When the decompression is extended inferiorly to the L4–L5 level, this allows for full lateral/foraminal decompression of the cephalad root, along with the caudad root [Figures 6–9, 12, Video].

MINIMALLY INVASIVE SURGERY FOR SYNOVIAL CYSTS

One study cited the efficacy of minimally invasive surgical (MIS) techniques utilized to excise synovial cysts. In Landi *et al.*'s series, microsurgical excision of synovial cysts utilizing hemilaminectomy with partial arthroctomy without fusion achieved uniform clinical success with postoperative MR confirmation of adequate decompression.^[13]

In Pirotte *et al.*'s study, immediate resolution of symptoms occurred in 46 patients with lumbar synovial cysts following microsurgical excision that included bipolar coagulation of the synovial membrane, while

maintaining the integrity of the facet joint [Table 1].^[18] Of interest, within the first postoperative year, 5 (10.9%) patients developed contralateral synovial cysts also requiring microsurgical management.

DECOMPRESSIONS WITHOUT FUSIONS

Many patients with synovial cysts have been successfully managed with decompression without fusions. When Métellus *et al.* evaluated (1992–1998) 77 patients with symptomatic lumbar synovial cysts undergoing decompressive surgery without fusion, patients averaging 63 years of age were divided into those with radicular pain ($n = 51$ patients) and those with bilateral neurogenic claudication ($n = 26$ patients) [Table 1].^[16] Degenerative disc disease and facet joint osteoarthritis was accompanied by a 48% incidence of spondylolisthesis. Patients were followed up on an average of 45 months during which time a synovial cyst recurred in just one patient. Excellent/good outcomes were seen in 97.4% of patients; 89% of motor deficits resolved.^[16] Of interest, only 1 of 77 patients later required a fusion to address symptomatic spondylolisthesis.

Deinsberger *et al.* treated 31 patients with lumbar synovial cysts (14 with degenerative spondylolisthesis) with microsurgical resection (27 patients) and with laminectomy for stenosis (4 patients) [Table 1].^[4] Within 12–30 postoperative months, 80.7% achieved excellent/good results. Persistent low back pain was more typical for those with preoperative olisthesis and was attributed to instability.^[4]

Epstein evaluated both surgeon- and patient-based (SF-36) outcomes to assess the results of laminectomies performed to excise synovial cysts with coexistent lumbar spinal stenosis (45 patients) or stenosis with degenerative spondylolisthesis (35 patients) [Table 1].^[5] Of interest, surgery required average 3.8- and 3.5-level laminectomies, respectively, for the two patient groups. When Epstein evaluated SF-36 outcomes following 45 decompressive laminectomies for the excision of synovial cysts with stenosis, 58% of all patients exhibited good/excellent outcomes.^[5] Although five patients developed postoperative olisthesis, only the two who were symptomatic required secondary fusions.^[5] Other second operations included neurolysis/duralysis of scar (1 patient), excision of a recurrent synovial cyst (1 patient), and herniated discs (3 patients). Nearly comparably, the 35 patients with synovial cysts, lumbar stenosis, and degenerative spondylolisthesis exhibited a 63% incidence of good/excellent postoperative results.^[5] Here, however, although olisthesis increased from Grade I to Grade II in 11 patients, only 2 were sufficiently symptomatic to warrant secondary fusions. Second operations for the remaining three individuals included the resection of postoperative scar tissue (2 patients)

and removal of a recurrent synovial cyst (1 patient). When outcomes were assessed 2 years postoperatively, SF-36 improvement on the Physical Function Scale also increased by +44 and +38 points, respectively. Notably, the more moderate quality of postoperative outcomes could not solely be attributed to the necessity for secondary fusion, but rather was variously attributed to postoperative scar, recurrent synovial cyst, and recurrent disc herniations.^[5]

When Epstein reviewed synovial cysts, up to 40% of patients had accompanying spinal stenosis with degenerative spondylolisthesis.^[6] Decompressions included unilateral or bilateral laminotomies, hemilaminectomies, or laminectomies alone or in combination with *in situ* or instrumented fusion. Adequate outcomes spanning 1–2 postoperative years were documented on SF-36 outcome questionnaires.

DECOMPRESSION WITH NON-INSTRUMENTED FUSIONS

Another group of Epstein's older patients whose dynamic X-rays documented mild/moderate motion only, were sufficiently managed with non-instrumented one-level or two-level posterolateral fusions (depending on the number of contiguous levels of olisthy). Fusions utilizing local autologous laminectomy bone combined with a bone graft expander [e.g. Vitoss-beta tricalcium phosphate (B-TCP); DePuy Orthopedics, Warsaw, IN, USA] [Table 1].^[8] Out of 60 patients averaging 70 years of age, fusion rates and outcomes were assessed following average 5.4-level lumbar laminectomies and 1- to 2-level non-instrumented fusions performed with B-TCP (Vitoss) and laminectomy autograft.^[8] Laminectomies addressed multilevel stenosis (60 patients), with varying combinations of OYL (46 patients), disc herniations (20 patients), and/or synovial cysts (8 patients). Fusions addressed degenerative spondylolisthesis (48 patients), spondylolisthesis/lysis (2 patients), or degenerative scoliosis (10 patients). Fusion was documented independently by two neuroradiologists blinded to the study design, and utilized dynamic X-rays and thin-cut 2D-CT scans which were obtained up to 2 years following surgery. Utilizing these stringent criteria, although pseudarthrosis was documented in 9 (15%) patients, only two were sufficiently symptomatic to warrant secondary fusion. Odom's criteria revealed 28 excellent, 23 good, 5 fair, and 4 poor results, while SF-36 improvement occurred on six of eight Health Scales in all patients.^[8]

Bydon *et al.*'s systematic literature review (1970–2009) revealed 82 published studies of 966 patients who underwent surgical resection of spinal synovial cysts [Table 1].^[3] Following decompressions (84%) or fusions (16.0%), 92.5% and 91.1% of patients, respectively, experienced complete resolution of their back or leg pain.^[3]

Within an average of 25.4 postoperative months, 6.2% required secondary surgery, with the majority ($n = 47$) undergoing fusion for mechanical back pain/instability. Same-level recurrence of synovial cysts was noted in 1.8% of patients undergoing decompressions alone, but none occurred following fusions.

Weiner *et al.* studied the long-term (average 9.7 years, range 5–22 years) postoperative outcomes of micro-decompression for lumbar synovial cysts with and without arthrodesis [Table 1].^[26] Of the 46 patients, 23 had decompressions with arthrodesis whereas 23 had decompression alone. Overall, 88% reported relief of the preoperative pain/symptoms. Fifteen percent of patients went on to need additional surgery (three requiring fusion, and four developing adjacent segment stenosis requiring a secondary decompression and fusion at the adjacent level).^[26]

In Xu *et al.*'s study, 167 consecutive patients with 195 symptomatic synovial cysts underwent various surgical procedures over a 19-year period [Table 1].^[28] These included unilateral hemilaminectomy ($n = 51$), bilateral laminectomy ($n = 39$), facetectomy with *in situ* fusion ($n = 18$), and facetectomy with instrumented fusion ($n = 56$). Prior to surgery, the complaints included 97.5% radiculopathy, 82.5% back pain, 20% neurogenic claudication, and 3.2% bladder complaints. Postoperatively, although back and radicular pain improved in 91.6% and 91.9% of patients, respectively, those undergoing instrumented fusions exhibited better outcomes compared with patients having decompressions alone.^[28]

DECOMPRESSIONS WITH INSTRUMENTED FUSIONS

Younger patients or those who demonstrate activeolisthesis/translational instability on dynamic X-rays and no significant degenerative changes on preoperative CT studies may warrant instrumented fusions. These fusions may include laminectomy with pedicle screw instrumentation and posterolateral fusion. Other fusion alternatives such as transforaminal lumbar interbody fusion (TLIF) or posterior lumbar interbody fusion (PLIF) may also be utilized.

FREQUENCY OF EPIDURAL/FACET STEROID INJECTIONS

As spine injection frequencies have escalated from 18 to 90%, there is increasing concern regarding the clinical efficacy of these procedures.^[10] Utilizing Medicare Physician Part B claims from 1994 to 2001, Friedly *et al.* found an increase of frequency for epidural (271%) and facet injections (231%) for patients over the age of

65 years.^[10] The total reimbursement jumped from \$24 million to \$175 million, with costs for each injection doubling from \$115 to \$227. In Friedly *et al.*'s study, epidural injections addressed low back pain in 36%, spinal stenosis in 23%, and a combination of sciatica/radiculopathy/discs in 41% of patients. The authors concluded thus: "Less than half were performed for sciatica or radiculopathy, where the greatest evidence of benefit is available. These findings suggest a lack of consensus regarding the indications for epidural steroid injections and are cause for concern given the large expenditures for these procedures."^[10]

FREQUENCY OF PERCUTANEOUS SYNOVIAL CYST ASPIRATION

Predominantly "pain specialists", and occasionally "spinal surgeons" have utilized CT-guided and/or fluoroscopic techniques to aspirate synovial cysts with/without accompanying epidural/transforaminal steroid injections [Table 1].^[11,20,21,23] However, a review of multiple studies utilizing these techniques reveals often short-term benefits, with high 50–100% long-term failure rates.^[11,20,21,23] Notably, the majority of cysts are gelatinous and non-aspirable, leaving the large residual cyst capsules to continue to compress the neural/dural structures, and contribute to ongoing neurological dysfunction.

In one series, 9 (90%) of 10 patients undergoing fluoroscopic-guided cyst aspiration with local or transforaminal epidural steroid injections performed by physiatrists did poorly.^[23] In a second study, 2 (100%) of 2 patients exhibited failure following attempts by orthopedists at aspiration of gelatinous cysts.^[11] In a third study, 9 (50%) of 18 fluoroscopically guided, contrast-enhanced cyst aspirations performed by physiatrists exhibited significant long-term benefits defined by only 9.9 postoperative months. Nevertheless, the authors concluded that this was a "safe and effective" alternative to the open surgical removal of synovial cysts.^[21] Interestingly, they interpreted this as a 50% success rate rather than a 50% failure rate. In a fourth single-case study, pain management specialists (radiologists, anesthesiologists) claimed they were the first to "successfully" perform lumbar "CT assisted (fluoroscopically guided) aspiration and cyst rupture," in the pain medicine literature.^[20]

Schultz *et al.* performed a comparative prospective, non-randomized analysis of 45 patients with sciatica/claudication, undergoing microsurgical resection (25 patients) versus percutaneous CT-guided destruction (20 patients) of lumbar synovial cysts [Table 1].^[22] All treated microsurgically were asymptomatic at an average of 27 postoperative months, while only 8 (40%) out of 20 patients treated percutaneously improved at 24 months; 12 later required microsurgery. The authors

concluded thus: “Minimally invasive cyst destruction is not a viable alternative to microsurgical resection considering the long-term outcome, neither in this study nor in the reviewed literature.”^[22]

Allen *et al.* evaluated 32 patients with symptomatic lumbar synovial cysts, who underwent fluoroscopically guided, contrast-enhanced, percutaneous facet cyst distention and rupture; this was followed by an intra-articular facet joint injection of 1 ml Kenalog and 1 ml of 1% Lidocaine [Table 1].^[1] Additionally, 17 of 32 patients received transforaminal epidural steroid injections just prior to rupturing the cyst. Although the authors concluded that long-term results were excellent (with pain relief in 72%; average follow-up 1 year), 37.5% of patients exhibited synovial cyst recurrence. Of the 11 of 12 who chose to undergo cyst rupture again, 5 improved, but 6 required surgery.

In Martha *et al.*'s series, 100 patients with lumbar facet joint synovial cysts underwent fluoroscopically guided corticosteroid facet joint injections and attempted cyst rupture.^[15] Although cyst rupture was documented fluoroscopically in 81% of cases, 54% required subsequent surgery over an average of 8.4 months [Table 1]. Furthermore, the authors observed thus: “Successful cyst rupture does not appear to have added benefit, and it was associated with increased disability 3 years post injection.”

Parlier-Cuau *et al.* assessed the clinical results of facet steroid injections in the treatment of symptomatic lumbar facet joint synovial cysts after 1 month, 6 months, and long term (mean 26 months) [Table 1].^[17] After 6 months, 18 of 30 patients (60%) had fair or poor outcomes and 14 of the 18 required surgery.

CONCLUSION

After a thorough review of the literature on the treatment of symptomatic synovial cysts and a study of the anatomy of these cysts, it appears that the treatment with the best outcome for these patients is surgical decompression and removal of the cyst. The question of fusion for all patients after this surgery and the manner in which it is done is still unsettled from the literature that was reviewed. Percutaneous aspiration of the cysts appears to be a treatment alternative that has a much higher recurrence and failure rate than surgery, but may be followed by surgery to correct the problem. An economic analysis of the comparison of cyst aspiration versus surgery does not appear in the literature.

ACKNOWLEDGMENT

The authors would like to thank Ms. Sherry Grimm,

administrator of Long Island Neurosurgical Associates P.C., for her proof reading and editorial suggestions.

REFERENCES

- Allen TL, Tatli Y, Lutz GE. Fluoroscopic percutaneous lumbar zygoapophyseal joint system rupture: A clinical outcome study. *Spine J* 2008;9:387-95.
- Alicioglu B, Sut N. Synovial cysts of the lumbar facet joints: A retrospective magnetic resonance imaging study investigating their relation with degenerative spondylolisthesis. *Prague Med Rep* 2009;110:301-9.
- Bydon A, Su R, Parker S, McGirt MJ, Bydon M, Gojasian ZL, *et al.* Recurrent back and leg pain and cyst reformation after surgical resection of spinal synovial cysts: Systematic review of reported postoperative outcomes. *Spine J* 2010;10:820-6.
- Deinsberger R, Kinn E, Ungersbock K. Microsurgical treatment of juxta facet cysts of the lumbar spine. *J Spinal Disord Tech* 2006;19:155-60.
- Epstein NE. Lumbar laminectomy for the resection of synovial cysts and coexisting lumbar spinal stenosis or degenerative spondylolisthesis: An outcome study. *Spine* 2004;29:149-55.
- Epstein NE. Lumbar Synovial Cysts: A review of diagnosis, surgical management, and outcome assessment. *J Spinal Disord Tech* 2004;17:321-5.
- Epstein NE. The frequency and etiology of intraoperative dural tears in 110 predominantly geriatric patients undergoing multilevel laminectomy with non-instrumented fusion. *J Spinal Disord Tech* 2007;20:380-6.
- Epstein NE. An analysis of non-instrumented posterolateral lumbar fusions in predominantly elderly patients utilizing lamina autograft and beta tricalcium phosphate. *Spine J* 2008;8:882-7.
- Ewald C, Kalf R. Resolution of a synovial cyst of the lumbar spine without surgical therapy—A case report. *Zentralbl Neurochir* 2005;66:147-51.
- Friedly J, Chan L, Deyo R. Increases in lumbosacral injections in the Medicare population: 1994 to 2001. *Spine (Phila Pa 1976)* 2007;32:1754-60.
- Imai K, Nakamura K, Inokuchi K, Oda H. Aspiration of intraspinal synovial cyst: Recurrence after temporal improvement. *Arch Orthop Trauma Surg* 1998;118:103-5.
- Kusakabe T, Kasama F, Aizawa T, Sato T, Kokubun S. Facet cyst in the lumbar spine: Radiological and histopathological findings and possible pathogenesis. *J Neurosurg Spine* 2006;5:398-403.
- Landi A, Marotta N, Tarantino R, Ruggeri AG, Cappelletti M, Ramieri A, *et al.* Microsurgical excision without fusion as a safe option for resection of synovial cyst of the lumbar spine: Long-term follow up in mono-institutional experience. *Neurosurg Rev* 2012;35:245-53.
- Liu SS, Williams KD, Drayer BP, Spetzler RF, Sonntag VK. Synovial cysts of the lumbosacral spine; diagnosis by MR imaging. *AJR Am J Roentgenol* 1990;154:163-6.
- Martha JF, Swaim B, Wang DA, Kim DH, Hill J, Bode R, *et al.* Outcomes of percutaneous rupture of lumbar synovial cysts: A case series of 101 patients. *Spine J* 2009;9:899-904.
- Metellus P, Fuentes S, Adetchessi T, Levrier O, Flores-Parra I, Taliano D, *et al.* Retrospective study of 77 patients harboring lumbar synovial cysts: Functional and neurological outcome. *Acta Neurochir (Wien)* 2006;148:47-54.
- Parlier-Cuau C, Wybier M, Nizard R, Champsaur P, Le Hir P, Laredo JD. Symptomatic lumbar facet joint synovial cysts: Clinical assessment of facet joint steroid injection after 1 and 6 months and long-term follow-up in 30 patients. *Radiology* 1999;210:509-13.
- Pirotte B, Gabrovsky N, Massager N, Levivier M, David P, Brotchi J. Synovial cysts of the lumbar spine: Surgery-related results and outcome. *J Neurosurg* 2003;99 Suppl 1:S14-9.
- Pytel P, Wollmann RL, Fessler RG, Krausz TN, Montag AG. Degenerative spine disease. *Am J Clin Pathol* 2006;125:193-202.
- Rauchwerger JJ, Candido KD, Zoarski GH. Technical and imaging report: Fluoroscopic guidance for diagnosis and treatment of lumbar synovial cyst. *Pain Pract* 2011;11:180-4.
- Sabers SR, Ross SR, Grogg BE, Lauder TD. Procedure-based nonsurgical management of lumbar zygoapophyseal joint cyst-induced radicular pain. *Arch Phys Med Rehabil* 2005;86:1767-71.
- Schulz C, Danz B, Waldeck S, Kunz U, Mauer UM. Percutaneous CT-guided

- destruction versus microsurgical resection of lumbar juxtafacet cysts. *Orthopade* 2011;40:600-6.
23. Shah RV, Lutz GE. Lumbar intraspinal synovial cysts: Conservative management and review of the world's literature. *Spine J* 2003;3:479-88.
 24. Swartz PG, Murtagh FR. Spontaneous resolution of an intraspinal synovial cyst. *Am J Neuroradiol* 2003;24:1261-3.
 25. Tillich M, Trummer M, Lindbichler F, Flaschka G. Symptomatic intraspinal synovial cysts of the lumbar spine: Correlation of MR and surgical findings. *Neuroradiology* 2001;43:1070-5.
 26. Weiner BK, Torretti J, Stauff M. Microdecompression for lumbar synovial cysts: An independent assessment of long-term outcomes. *J Orthop Surg Res* 2007;2:5.
 27. Wilby MF, Fraser RD, Vernon-Roberts B, Moore RJ. The prevalence and pathogenesis of synovial cysts within the ligamentum flavum in patients with lumbar spinal stenosis and radiculopathy. *Spine (Phila Pa 1976)* 2009;34:2518-24.
 28. Xu R, McGirt MJ, Parker SL, Bydon M, Olivi A, Wolinsky JP, et al. Factors associated with recurrent back pain and cyst recurrence after surgical resection of one hundred ninety-five spinal synovial cysts: Analysis of one hundred sixty-seven consecutive cases. *Spine (Phila Pa 1976)* 2010;35:1044-53.

Disclaimer: The authors of this paper have received no outside funding and have nothing to disclose.

Video available at www.surgicalneurologyint.com

Announcement

iPhone App



Download
**iPhone, iPad
application**

FREE

A free application to browse and search the journal's content is now available for iPhone/iPad. The application provides "Table of Contents" of the latest issues, which are stored on the device for future offline browsing. Internet connection is required to access the back issues and search facility. The application is compatible with iPhone, iPod touch, and iPad and Requires iOS 3.1 or later. The application can be downloaded from <http://itunes.apple.com/us/app/medknow-journals/id458064375?ls=1&mt=8>. Please send us your suggestions and comments.