

Occult choroidal neovascularization after successful macular hole surgery treated with ranibizumab

Ha Na Oh¹
Joo Eun Lee²
Hyun Woong Kim¹
Jae Wook Yang¹
Il Han Yun¹

¹Department of Ophthalmology,
Busan Paik Hospital, Inje University
College of Medicine, Busan, Korea;

²Department of Ophthalmology,
Haeundae Paik Hospital, Inje
University College of Medicine,
Busan, Korea

Purpose: To report on a case that developed an atypical form of occult choroidal neovascularization (CNV) after successful macular hole surgery.

Methods: Visual acuity change, color fundus photographs, fluorescein and indocyanine green angiograms, and optical coherence tomography results were compared throughout the follow-up duration.

Patients: A 64-year-old woman with a macular hole in the right eye and drusen in both eyes underwent pars plana vitrectomy, internal limiting membrane peeling, and gas tamponade. One month after the operation she developed occult CNV, in which pigment epithelial detachment and fine retinal pigment epithelial (RPE) layer wrinkles were observed under the completely sealed macular hole. After 3-monthly intravitreal injections of ranibizumab, the lesion did not change significantly.

Conclusion: CNV can develop after otherwise successful macular hole surgery, especially in patients with pre-existing aging changes in the macula, such as drusen. Care should be taken in such patients, to prevent the development of CNV after macular hole surgery.

Keywords: drusen, macular hole surgery, occult choroidal neovascularization, ranibizumab injection

Introduction

Full-thickness macular holes are effectively managed by pars plana vitrectomy and gas tamponade with a high anatomic success rate. However, vision-threatening complications such as retinal detachment, cystoid macular edema, and endophthalmitis can occur in some patients after macular hole surgery.¹⁻³

A few cases of choroidal neovascularization (CNV) after successful macular hole surgery have been reported in the literature.³⁻⁶ We report a case that developed an atypical form of occult CNV after an otherwise successful macular hole surgery, and was treated using intravitreal injection of ranibizumab.

Case report

A 64-year-old woman presented with a 3-week history of decreased vision in the right eye. Her best corrected visual acuity was 0.2 in the right eye and 0.8 in the left eye. Anterior segment examination did not show any abnormal findings. On fundus examination, multiple soft drusen were seen in the macula of both eyes (Figure 1A and B). In the right eye, a full-thickness macular hole was observed and was confirmed by optical coherence tomography (OCT) (Figure 1C). Fluorescein angiogram (FAG) revealed a window defect at the corresponding area of the macular hole. No evidence

Correspondence: Il Han Yun
Department of Ophthalmology,
Busan Paik Hospital, Inje University
College of Medicine, Busan,
Korea 633-165 Kekum-Dong,
Busanjin-ku, Busan 614-735, Korea
Tel +82 51 890 6016
Fax +82 51 890 6292
Email ihyun@inje.ac.kr

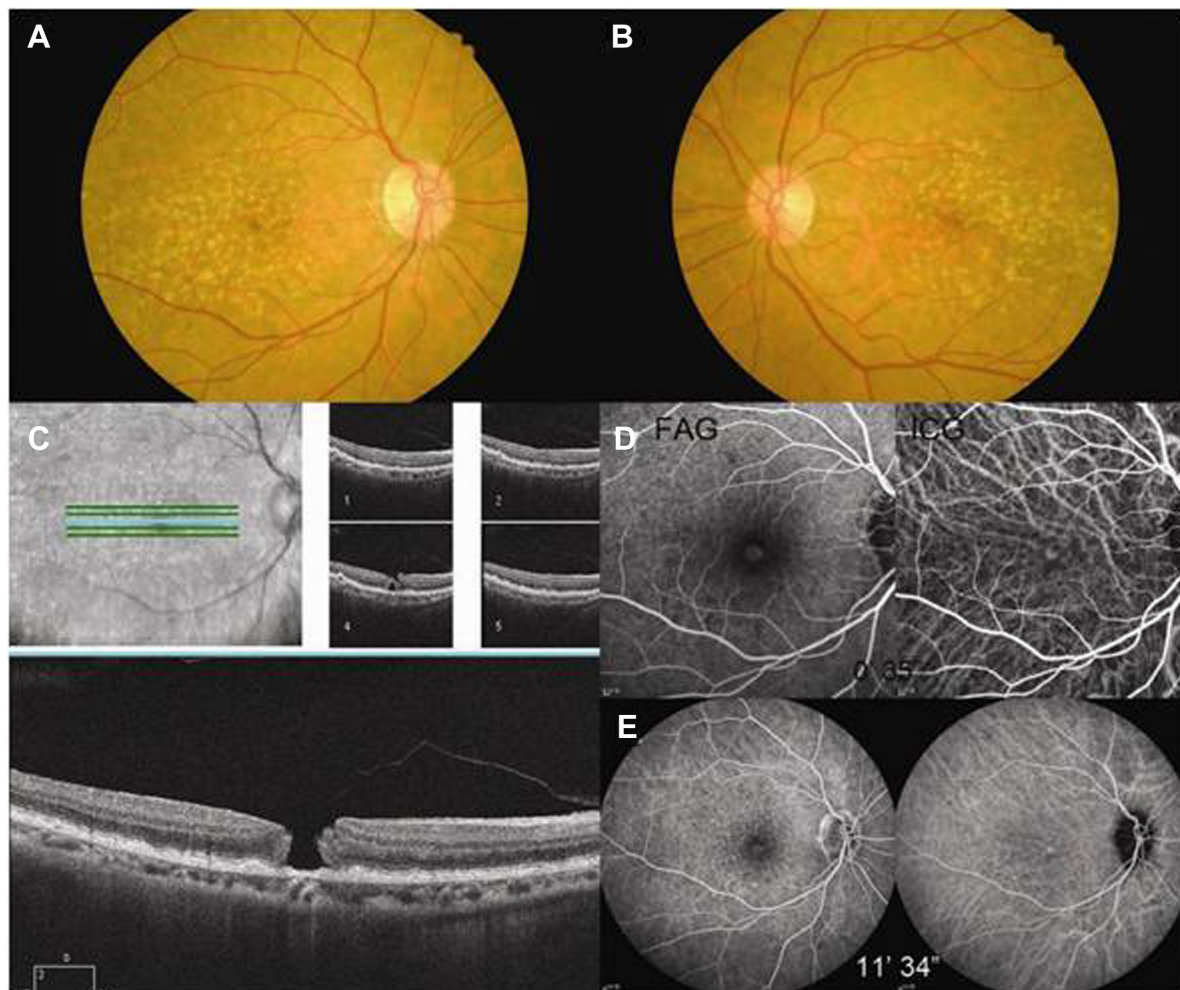


Figure 1 Baseline fundus photographs (**A** and **B**) show a macular hole in the right eye and multiple soft drusen in both eyes. A full thickness macular hole is evident in the optical coherence tomography (**C**) of the right eye. Early (**D**) and Late (**E**) phase fluorescein and indocyanine green angiograms demonstrate a window defect.

Note: There is no evidence of choroidal neovascularization.

Abbreviation: FAG; Fluorescein angiogram.

of CNV was found either in FAG or in indocyanine green (ICG) angiography (Figure 1D and E).

Pars plana vitrectomy, internal limiting membrane (ILM) peeling after ICG staining, and perfluoropropane (C3F8) gas tamponade were performed to treat the macular hole of the right eye. The patient was asked to keep her face down for 2 weeks postoperatively. One month after the surgery, fluid accumulation under the macula and multiple blot subretinal hemorrhages near the inferotemporal vascular arcade were observed (Figure 2A). OCT showed retinal pigment epithelial detachment (PED) under the successfully sealed macular hole (Figure 2B). Best corrected visual acuity was 0.15. The patient was followed up for another month without any intervention to see whether there was further change.

The next month, her visual acuity had slightly decreased to 0.1. On fundus examination, most of the retinal

hemorrhages disappeared. However, more opaque fluid accumulation and fine wrinkles under the macula were noted, obscuring the detail of the drusen at the region (Figure 3A). On OCT examination, reduction in the height of the PED and RPE layer wrinkling were noted (Figure 3B). FAG and ICG angiography showed distinct hypofluorescent lines at the macula throughout the study of the angiogram (Figure 3C and D). An early-phase ICG angiogram showed a radiating fine CNV network (Figure 3C). Late FAG pictures showed pinpoint leakages and pooling at the corresponding PED area (Figure 3D).

Monthly intravitreal injections of 0.5 mg/0.05 mL ranibizumab (Lucentis; Genentech, South San Francisco, CA) were given to the patient. After 3-monthly injections, visual acuity remained the same. The boundary of the lesion showed some fibrotic change along the superotemporal and superonasal border, and the subretinal wrinkles became

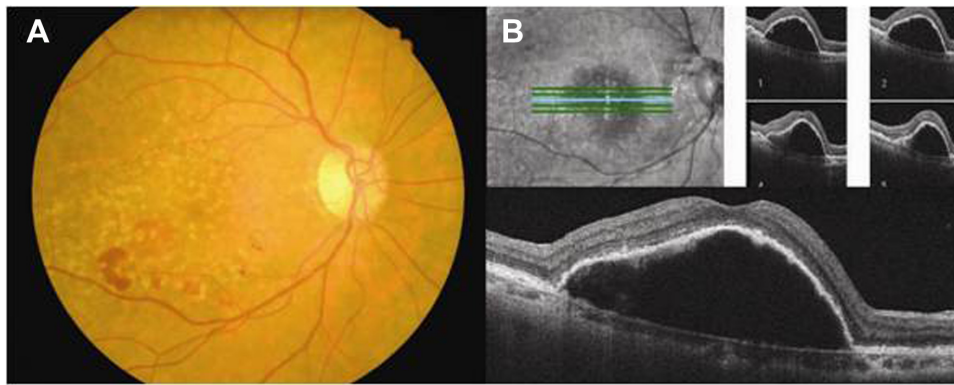


Figure 2 One month after the macular hole surgery. A fundus photograph of the right shows newly onset blot retinal hemorrhages (A). An optical coherence tomography image demonstrates dome-shaped retinal pigment epithelial detachment under the successfully sealed macular hole (B).

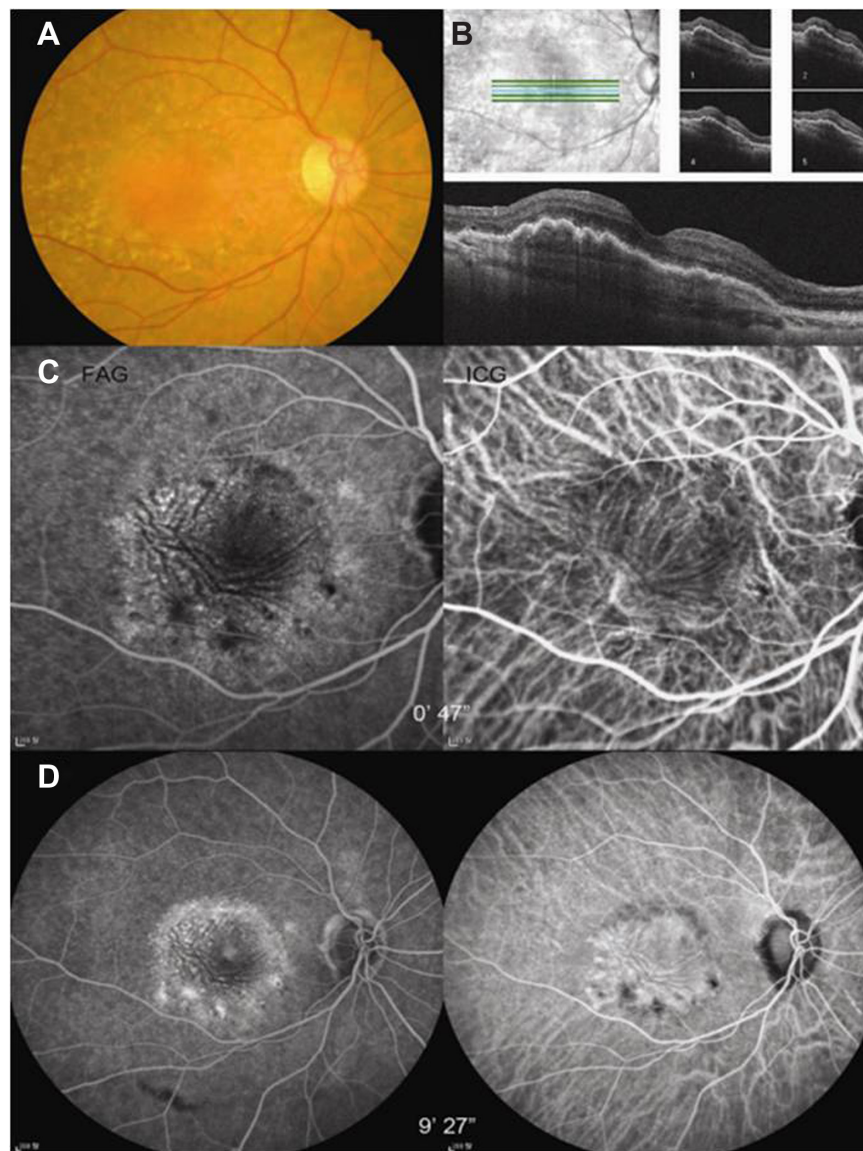


Figure 3 Two months after the macular hole surgery. Darker fluid accumulation is noted in the fundus photograph (A). Optical coherence tomography shows a decrease in height of the pigment epithelial detachment and wrinkling of the pigment epithelial layer (B). Hypofluorescent lines corresponding to the pigment epithelial wrinkles are evident in the angiogram (C and D). Note fine radiating choroidal neovascular network on early phase indocyanine green angiogram (C). Late phase angiogram shows multiple pinpoint leakages and pooling at the lesion (D).

more obvious (Figure 4A). OCT findings did not change significantly (Figure 4B).

Discussion

To date, there are only a few case reports of CNV that have developed after macular hole surgery.^{2–6} Tabandeh et al⁶ reported characteristics of CNV occurring after macular hole surgery. The interval to CNV formation was 1.5–30 months. Typically, the CNV showed a predominantly classic pattern (eight in nine eyes, 89%), and moderate to severe leakage (eight in nine eyes, 89%) on FAG. The size of the CNV was ≤ 2 Macular Photocoagulation Study disc diameter in eight of nine eyes (89%). The patient in the present study, however, showed larger occult-type CNV. A unique feature of the patient was fine wrinkling of the RPE layer, as evidenced by the angiogram and the OCT (Figures 3 and 4). These wrinkles were not evident at the initial stage of the CNV development (Figure 2). One month later, the fine wrinkles became more prominent, and the height of the PED decreased. This could be attributed to RPE tear. However, the exact location of the RPE tear was not evident either on the FAG or on the OCT.

Another possible explanation includes conversion from pure serous PED or PED with latent CNV to fibrous PED. The OCT finding of the PED at 1 month postoperatively is compatible with pure serous PED. However, subretinal hemorrhage and rather flattened contour of the PED could be signs of an occult vascular component. FAG and/or ICG at this time should have provided more information regarding the nature of the PED. As contraction of the fibrous component of CNV continued along the CNV, the fine RPE wrinkles, more clearly seen on FAG (Figure 3C, FAG), seem to have been formed perpendicular to the axis of the CNV (Figure 3C, ICG).

The pathogenesis underlying the development of the CNV is not yet fully understood. However, the most plausible explanation is age-related degenerative changes in the RPE and Bruch membrane, as evidenced by old age and a high prevalence of drusen in both eyes of most patients who showed CNV development after macular hole surgery.⁶ The patient in the present report also showed bilateral multiple drusen and was 64 years old. However, in the reports by Berinstein et al,⁴ in which 34 eyes of 32 patients who had intermediate to large-sized macular drusen at the baseline underwent macular hole surgery, only one eye was complicated by CNV development after the surgery. This means that pre-existing senile change is not the sole etiologic factor. Another possible explanation is trypan blue toxicity, which was used for ILM staining.³ In the present study, ICG dye was used for the ILM staining and peeling. ICG dye could be toxic to the neurosensory retina and RPE,⁷ although it is widely used for macular surgery. The vital dye can easily pass through the macular hole to the RPE, and may have resulted in toxic damage to the vulnerable RPE, with drusen facilitating CNV formation.

Mechanical trauma during the ILM peeling could have played a role in the pathogenesis as well. Therefore, measures have to be taken to minimize mechanical and toxic insults to the retina and RPE in patients with macular hole and drusen, to limit the risk of CNV development. ILM peeling without staining could be ideal in this situation. However, triamcinolone-assisted ILM peeling⁸ using safer dye such as brilliant blue G⁹ or using viscoelastic material to cover the macular hole during the staining may be reasonable options for less experienced surgeons.

Focal laser photocoagulation or photodynamic therapy has been used to treat CNV arising after macular hole surgery.^{3,6}

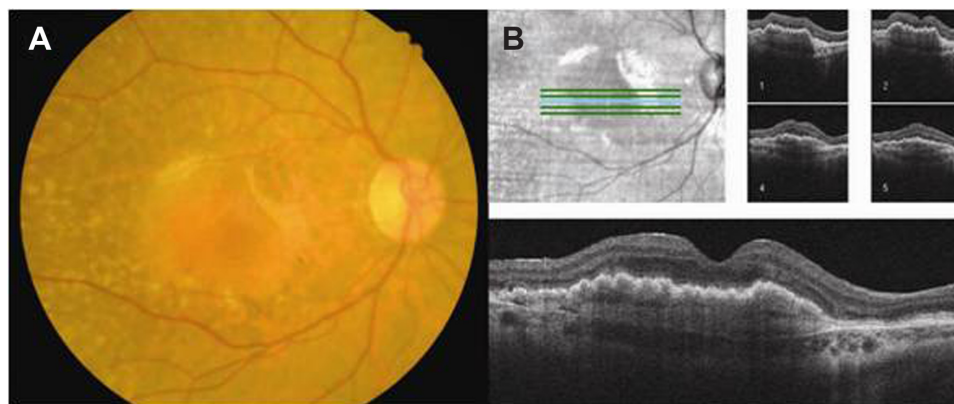


Figure 4 After 3 monthly intravitreal injection of ranibizumab. Fine wrinkles are more evident and some fibrotic changes are noted along the superotemporal and superonasal border of the lesion (A). An optical coherence tomographic finding did not change significantly compared to the previous image (B).

In the present report, ranibizumab was used to treat the occult CNV. After 3-monthly intravitreal injections, the lesion and visual acuity did not change significantly.

In summary, we report on a case that developed occult CNV with PED and fine RPE wrinkles after an otherwise successful macular hole surgery. Toxic and mechanical damage to the RPE, which already had aging changes, as shown by drusen, may have facilitated the formation of the CNV. Intravitreal injection of ranibizumab did not induce complete resolution of the PED while maintaining visual acuity.

Care should be taken in patients with macular hole accompanied by aging changes in the macula, such as drusen, to prevent development of CNV after macular hole surgery.

Acknowledgment

This study was conducted at the Inje University Busan Paik Hospital, Busan, Korea. This study was supported by a grant from the Korea Healthcare Technology R&D Project, Ministry of Health and Welfare Affairs, Republic of Korea (Grant no A120006).

Disclosure

No author has any financial interest related to the article.

References

1. Park SS, Marcus DM, Duker JS, et al. Posterior segment complications after vitrectomy for macular hole. *Ophthalmology*. 1995;102(5):775–781.
2. Banker AS, Freeman WR, Kim JW, et al. Vision-threatening complications of surgery for full-thickness macular holes. Vitrectomy for Macular Hole Study Group. *Ophthalmology*. 1997;104(9):1442–1452; discussion 52–53.
3. Natarajan S, Mehta HB, Mahapatra SK, Sharma S. A rare case of choroidal neovascularization following macular hole surgery. *Graefes Arch Clin Exp Ophthalmol*. 2006;244(2):271–273.
4. Berinstein DM, Hassan TS, Williams GA, et al. Surgical repair of full-thickness idiopathic macular holes associated with significant macular drusen. *Ophthalmology*. 2000;107(12):2233–2239.
5. Tabandeh H, Smiddy WE. Choroidal neovascularization following macular hole surgery. *Retina*. 1999;19(5):414–417.
6. Tabandeh H, Smiddy WE, Sullivan PM, et al. Characteristics and outcomes of choroidal neovascularization occurring after macular hole surgery. *Retina*. 2004;24(5):714–720.
7. Lee JE, Yoon TJ, Oum BS, et al. Toxicity of indocyanine green injected into the subretinal space: subretinal toxicity of indocyanine green. *Retina*. 2003;23(5):675–681.
8. Kumagai K, Furukawa M, Ogino N, et al. Long-term outcomes of macular hole surgery with triamcinolone acetonide-assisted internal limiting membrane peeling. *Retina*. 2007;27(9):1249–1254.
9. Fukuda K, Shiraga F, Yamaji H, et al. Morphologic and functional advantages of macular hole surgery with brilliant blue G-assisted internal limiting membrane peeling. *Retina*. 2011;31(8):1720–1725.

Clinical Ophthalmology

Publish your work in this journal

Clinical Ophthalmology is an international, peer-reviewed journal covering all subspecialties within ophthalmology. Key topics include: Optometry; Visual science; Pharmacology and drug therapy in eye diseases; Basic Sciences; Primary and Secondary eye care; Patient Safety and Quality of Care Improvements. This journal is indexed on

Submit your manuscript here: <http://www.dovepress.com/clinical-ophthalmology-journal>

Dovepress

PubMed Central and CAS, and is the official journal of The Society of Clinical Ophthalmology (SCO). The manuscript management system is completely online and includes a very quick and fair peer-review system, which is all easy to use. Visit <http://www.dovepress.com/testimonials.php> to read real quotes from published authors.