

# A Case of Allopurinol-Induced Fixed Drug Eruption Confirmed With a Lymphocyte Transformation Test

Min-Hye Kim,<sup>1,2</sup> Eun-Jin Shim,<sup>1,2</sup> Jae-Woo Jung,<sup>1,2</sup> Seong-Wook Sohn,<sup>3</sup> Hye-Ryun Kang<sup>1,2\*</sup>

<sup>1</sup>Department of Internal Medicine, Seoul National University College of Medicine, Seoul, Korea

<sup>2</sup>Institute of Allergy and Clinical Immunology, Seoul National University Medical Research Center, Seoul, Korea

<sup>3</sup>Department of Internal Medicine, Dongguk University Ilsan Hospital, Goyang, Korea

This is an Open Access article distributed under the terms of the Creative Commons Attribution Non-Commercial License (<http://creativecommons.org/licenses/by-nc/3.0/>) which permits unrestricted non-commercial use, distribution, and reproduction in any medium, provided the original work is properly cited.

Allopurinol is one of the causative drugs that induce fixed drug eruption (FDE). The lymphocyte transformation test (LTT) is a safe and reliable diagnostic procedure for drug allergy, but is reported to be rarely positive in patients with FDE. In the current case, we performed an LTT and successfully confirmed allopurinol as the offending drug. This case report suggests that an LTT should be an optional diagnostic tool for FDE or delayed reaction due to allopurinol.

**Key Words:** Allopurinol; fixed drug eruption; lymphocyte transformation test

## INTRODUCTION

Fixed drug eruption (FDE) is a distinct type of drug eruption, which appears as pruritic, well-circumscribed, erythematous macules or edematous plaques.<sup>1</sup> FDE is characterized by recurrence at the same sites upon re-exposure to the offending drug and resolves spontaneously with hyperpigmentation.<sup>1</sup> Intraepidermal CD8+ T cells in the FDE lesions contribute to the development of localized tissue damage.<sup>1</sup> They are not cytolytic in the resting state, but once activated, they kill surrounding keratinocytes and release cytokines such as interferon gamma (IFN- $\gamma$ ) and CD4+, CD8+ T cells and neutrophils are recruited in the lesions and as a whole result in tissue damage.<sup>1</sup>

There are several tests to identify the causative drugs, such as the systemic oral challenge test and topical provocation tests including the patch test.<sup>1</sup> However, it is not easy to identify the culprit drug clearly particularly when there are multiple culprit drugs. Oral challenge, which is the gold standard for the diagnosis of FDE, can induce severe reactions and patch tests for FDE has revealed highly variable positivity rates.<sup>2</sup>

The lymphocyte transformation test (LTT) is a diagnostic procedure for drug allergy and has been in use for more than 30 years.<sup>3</sup> The LTT is a safe and reliable test for determining hypersensitivity to various types of drugs, but is reported to be rarely positive in patients with FDE.<sup>3</sup> Here, we report a case of allopurinol-induced FDE that was successfully proven with an LTT.

## CASE REPORT

A 75-year-old man with chronic renal disease was consulted about recurrent erythema and a blister on the glans penis, which occurred repeatedly on the day after he took allopurinol (100 mg once daily) for treatment of gouty arthritis five years ago. The lesion resolved with the discontinuation of allopurinol and a diagnosis of FDE was made based on the history of same-site recurrence with residual hyperpigmentation after the administration of allopurinol. His symptom did not recur, since he has abstained from allopurinol. He recently experienced gouty arthritis as his uric acid level increased with renal function deterioration and required urate lowering agents. He had no other history of allergic disease except allopurinol-induced FDE. An oral challenge test was not performed because the patient experienced multiple (more than three times) apparent episodes of FDE after ingestion of allopurinol and refused to take allopurinol again. To confirm whether allopurinol was the causative drug of his previous FDE, we performed an LTT with allopuri-

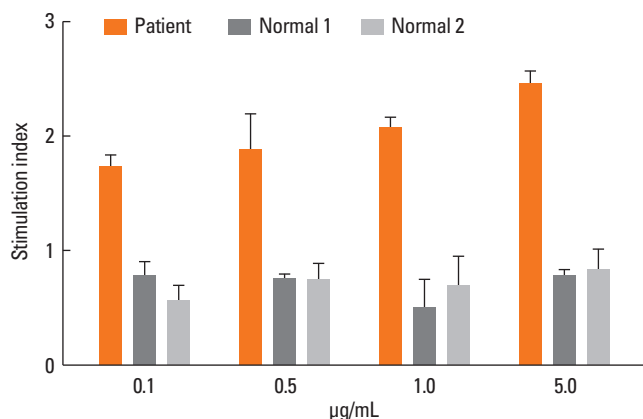
**Correspondence to:** Hye-Ryun Kang, MD, PhD, Department of Internal Medicine, Seoul National University Hospital, 101 Daehak-ro, Jongno-gu, Seoul 110-744, Korea.

Tel: +82-2-2072-3291; Fax: +82-2-742-3291; E-mail: [helenmed@snu.ac.kr](mailto:helenmed@snu.ac.kr)

Received: November 10, 2011; Revised: December 22, 2011;

Accepted: January 11, 2012

• There are no financial or other issues that might lead to conflict of interest.



**Figure.** Result of lymphocyte transformation test with increasing dose of allopurinol.

nol, as follows: peripheral blood mononuclear cells (PBMCs) without allopurinol and with various concentrations (0.1-5 µg/mL) of allopurinol were cultured for 5 days,  $^3\text{H}$ -thymidine was then added, and lymphocyte proliferation was measured as  $^3\text{H}$ -thymidine uptake on day 6.<sup>4</sup> We compared the patient's results with those of two normal controls who had not been exposed to allopurinol before. The LTT result was interpreted as positive if the patient's stimulation index (SI) was more than 1.8.<sup>4</sup> The patient's SI value increased in a dose-dependent manner (Figure) and was higher than 1.8 for every concentration of allopurinol and above 2.0 at concentrations of 1.0 and 5.0 µg/mL, while the SI values of the two normal controls were less than 1.0 (Figure).

## DISCUSSION

Allopurinol (4-hydroxypyrazolol [3,4-d] pyrimidine) is a drug frequently used for the treatment of hyperuricemia and patients are commonly reported to develop adverse reactions.<sup>5</sup> There are occasional reports regarding the induction of FDE by allopurinol.<sup>5-8</sup> Although an oral challenge is the most reliable test for verifying the drug responsible for FDE, it can be hazardous to patients if a previous reaction was severe.<sup>1</sup> Furthermore, if there were multiple culprit drugs, an oral challenge is very time consuming as well as laborious. The patch test is much safer than the oral challenge, but it can give false negative results arising from the low concentration of drug being tested, the refractory period of the patient, or the patient being sensitized to a metabolite, not the original drug.<sup>1</sup> The patch test should be performed on the affected area; however, FDE frequently develops on the lips, face, or genitalia, where a patch test is difficult to perform.<sup>6</sup> Moreover, allopurinol-induced delayed skin reactions including FDE are rarely positive in patch testing.<sup>2,9</sup> LTT is a well-established and useful test in various disease and drugs.<sup>10</sup> In LTT, pe-

ripheral blood mononuclear cells (PBMCs) of patients are sampled and cultivated with the suspected causative drug, and enhanced lymphocyte proliferation is interpreted as drug-specific T cell sensitization.<sup>3</sup> Sensitivity and specificity of LTT is reported to be 60%-70% and 85%, respectively<sup>10</sup> and is higher than sensitivity of patch test about 50%.<sup>2,10</sup> LTT is useful in the hypersensitivity reactions with strong immune response leading to detectable activation of peripheral drug-specific T cells by the *in vitro* stimulation. Generally, patients with FDE is known to be consistently negative in LTT.<sup>10</sup> However, we tried LTT in the patient with allopurinol-induced FDE and successfully confirmed allopurinol as the offending drug. This case report suggests that LTT could be an optional diagnostic tool for FDE due to allopurinol.

## ACKNOWLEDGMENTS

This research was supported by Basic Science Research Program through the National Research Foundation of Korea (NRF) funded by the Ministry of Education, Science and Technology (No. 2009-0072738).

## REFERENCES

- Shiohara T. Fixed drug eruption: pathogenesis and diagnostic tests. *Curr Opin Allergy Clin Immunol* 2009;9:316-21.
- Andrade P, Brinca A, Gonçalo M. Patch testing in fixed drug eruptions--a 20-year review. *Contact Dermatitis* 2011;65:195-201.
- Nyfelner B, Pichler WJ. The lymphocyte transformation test for the diagnosis of drug allergy: sensitivity and specificity. *Clin Exp Allergy* 1997;27:175-81.
- Kano Y, Hirahara K, Mitsuyama Y, Takahashi R, Shiohara T. Utility of the lymphocyte transformation test in the diagnosis of drug sensitivity: dependence on its timing and the type of drug eruption. *Allergy* 2007;62:1439-44.
- Umpiérrez A, Cuesta-Herranz J, De Las Heras M, Lluch-Bernal M, Figueredo E, Sastre J. Successful desensitization of a fixed drug eruption caused by allopurinol. *J Allergy Clin Immunol* 1998;101:286-7.
- Mahboob A, Haroon TS. Drugs causing fixed eruptions: a study of 450 cases. *Int J Dermatol* 1998;37:833-8.
- Kelso JM, Keating RM. Successful desensitization for treatment of a fixed drug eruption to allopurinol. *J Allergy Clin Immunol* 1996;97:1171-2.
- Teraki Y, Shiohara T. Successful desensitization to fixed drug eruption: the presence of CD25+CD4+ T cells in the epidermis of fixed drug eruption lesions may be involved in the induction of desensitization. *Dermatology* 2004;209:29-32.
- Santiago F, Gonçalo M, Vieira R, Coelho S, Figueiredo A. Epicutaneous patch testing in drug hypersensitivity syndrome (DRESS). *Contact Dermatitis* 2010;62:47-53.
- Pichler WJ, Tilch J. The lymphocyte transformation test in the diagnosis of drug hypersensitivity. *Allergy* 2004;59:809-20.