

Analysis of Clinical Feature and Management of Laryngeal Fracture: Recent 22 Case Review

Jin Pyeong Kim,¹ Sang Jae Cho,¹ Hee Young Son,³ Jung Je Park,¹ and Seung Hoon Woo^{1,2}

Department of ¹Otorhinolaryngology and ²Institute of Health Sciences, Gyeongsang National University, Jinju;

³Department of Otolaryngology, Thyroid/Head & Neck Cancer Center of The Dongnam Institute of Radiological & Medical Sciences (DIRAMS), Busan, Korea.

Received: September 8, 2011

Revised: October 27, 2011

Accepted: October 28, 2011

Corresponding author: Dr. Seung Hoon Woo,
Department of Otorhinolaryngology,
Gyeongsang National University,
79 Gangnam-ro, Jinju 660-702, Korea.
Tel: 82-55-750-8173, Fax: 82-55-750-9380
E-mail: lesaby@hanmail.net

The authors have no financial conflicts of interest.

Purpose: Laryngeal fracture is rare, but complications are frequent and severe. Controversy still exists in regards to its proper management. The aim of this study was to present the clinical findings and management of laryngeal fracture in Korea. **Materials and Methods:** We analyzed the medical records of 22 patients with laryngeal fracture at a tertiary care trauma center from 2000 to 2010 retrospectively. **Results:** In total, 22 patients (19 men and 3 woman) presented with laryngeal fractures caused by blunt (n=13) or penetrating (n=9) injury. Pain (68.1%), odynophagia (68.1%), hoarseness (18.1%), hemoptysis (13.6%), and subcutaneous emphysema (9%) were the common presenting symptoms and noncomminuted fracture was common. High velocity blunt trauma (mostly traffic accidents) patients had more extensive injury and poor voice outcomes. Penetrating trauma patients due to physical assault or suicide attempt demonstrated more frequently injuries on the left side. **Conclusion:** In driver-caused traffic accidents, where injuries in a wide area within the larynx occurred, poor voice results were seen, and these injuries required aggressive treatment. When endotracheal intubation was performed at experienced emergency centers with fiberoptic laryngoscopes, airway management was safely achieved. In addition, if the fractured laryngeal framework was corrected at appropriate times, voice results were good.

Key Words: Larynx, fracture, voice, cartilage, injury

INTRODUCTION

The larynx is protected by the mandible and the sternum. In addition, because of the elasticity and movability of the laryngeal cartilage, it is able to resist trauma to a certain extent. Thus, laryngeal fracture is very rare¹⁻³ and is rarely encountered in clinics. In the literature, the incidence has been reported to be 1 in 30000 patients who are admitted to severe trauma centers.¹⁻⁴ However, if laryngeal fracture is not diagnosed properly when it initially occurs and the airway is not secured, high mortality rates will result; thus, early treatment of laryngeal fracture is critical.

Early treatment for laryngeal fracture comprises securing the airway, but in late treatment, consideration of the voice, which is pertinent to quality of life, is important. Therefore, although laryngeal fracture is rare, clinicians who treat it should

© Copyright:

Yonsei University College of Medicine 2012

This is an Open Access article distributed under the terms of the Creative Commons Attribution Non-Commercial License (<http://creativecommons.org/licenses/by-nc/3.0>) which permits unrestricted non-commercial use, distribution, and reproduction in any medium, provided the original work is properly cited.

comprehensively understand its diagnosis and treatment.

In Korea, basic analysis of laryngeal fracture has not been performed to date. We have therefore clinically analyzed laryngeal fracture to assess fracture patterns and their causes, as well as to report treatment experiences and outcomes that might help with determining treatment directions.

MATERIALS AND METHODS

Of the patients who were admitted to Gyeongsang National University Hospital for laryngeal trauma from March 2000

to May 2010, 22 patients diagnosed with laryngeal fracture were selected, and their medical records were analyzed retrospectively. The Gyeongsang National University Hospital is the only tertiary medical institute in the Gyeongsang Nam Do province and operates a severe trauma center. The following aspects of the medical records were analyzed: the proportion of male and female patients, the age of onset, 1) symptoms, 2) injury severity, 3) injury mechanism, 4) injury area, 5) fracture pattern, 6) airway management, 7) treatment methods at the time of admission, and 8) voice outcomes after treatment (Table 1). The injury level was classified according to the Schaefer-Fuhrman classification of

Table 1. Summary of Demographics, Mechanism of Injury, Management of Laryngeal Fracture

No.	Age	Sex	Mechanism of injury	Symptom	Injury site	Fracture pattern	SF grade	Initial airway intervention (tracheostomy)	Tx.	Stent	Day to decan.	Voice (good, fair, poor)	Swallowing	VC palsy
1	44	M	Pt. (stab, assault)	P	Lt. TC	Noncom	2	No tracheostomy	ORIF-s	No	-	Good	Good	
2	40	M	B (fall down)	H	Lt. TC	Noncom	2	No tracheostomy	-	No	-	Fair	Good	Lt.
3	45	M	Pt. (stab, suicide)	P, O, H	Lt. TC	Noncom	2	No tracheostomy	ORIF-s	No	-	Good	Good	
4	35	M	B (dTA)	P, O, H, dg	Rt. TC, Rt. Aex, Rt. FVC	Noncom	3	Tracheotomy at OR	ORIF	No	13	Fair	Good	Rt.
5	26	M	Pt. (stab, suicide)	P	Lt. TC	Noncom	2	No tracheostomy	-	No	-	Good	Good	
6	63	M	B (automatic machine)	P, O	Rt. TC	Noncom	2	No tracheostomy	ORIF-m	No	-	Good	Good	
7	43	M	Pt. (stab, accident)	P, O	Both TC, EG	Noncom	3	Orotracheal intubation at ER, tracheotomy at OR	ORIF-m, PR	No	11	Fair	Good	
8	30	M	Pt. (stab, assault)	LOC	C	Com	4	Orotracheal intubation at OP, tracheotomy at OR	ORIF-s	No	6	Good	Good	
9	48	M	B (automatic machine)	P, O	Both TC	Noncom	2	No tracheostomy	ORIF-s	No	-	Good	Good	
10	66	M	B (dTA)	P	Both TC	Noncom	3	No tracheostomy	PR	No	-	Good	Good	
11	42	M	Pt. (automatic machine)	P, H	Lt. TC	Com	3	Tracheotomy at OR	PR	No	9	Good	Good	
12	34	M	Pt. (automatic machine)	P, O, D, H	Tr. Both TC, C	Noncom	4	Orotracheal intubation at ER, tracheotomy at OR	ORIF-s	No	7	Good	Good	
13	32	M	B (dTA)	D, O, Dg	LTS		5	Tracheotomy at OR	LTa	Yes	21	Fair	Good	Rt.
14	21	M	Pt. (stab, assault)	H, O	Lt. TC, Lt. Aex	Noncom	3	Tracheotomy at OR	PR	No	7	FU loss	FU loss	Lt.
15	48	M	B (dTA)	D, H	Both TC, Both Adis	Com	4	Tracheostomy at OR	ORIF-m	Yes	10	Bad	Fair	Both
16	24	M	B (dTA)	LOC	Both TC	Com	4	Tracheotomy at ER	ORIF-m	No	22	Fair	Good	
17	57	M	B (fall down)	P, O	Rt. TC	Noncom	3	No tracheostomy	ORIF-m	No	-	Good	Good	
18	34	M	B (sport)	P, O	Rt. TC	Noncom	3	No tracheostomy	PR	No	-	Good	Good	
19	50	F	Pt. (stab, suicide)	P, O, H	Lt. TC	Noncom	3	No tracheostomy	ORIF-s	No	-	Fair	Fair	Lt.
20	55	M	B (assault)	P, O, H	Lt. TC	Noncom	2	No tracheostomy	ORIF-s	No	-	Good	Good	
21	31	M	B (fall down)	P, O, H	Lt. TC	Noncom	3	No tracheostomy	ORIF-s	No	-	Good	Good	
22	77	F	B (fall down)	P, O, H	Rt. TC	Noncom	3	No tracheostomy	-	No	-	Good	Good	

dTA, driver-caused traffic accident; P, pain; H, hoarseness; O, odynophagia; D, dyspnea; Dg, dysphagia (+); LOC, LOC state; TC, thyroid cartilage; Aex, arytenoid exposed; Adis, arytenoid dislocation; FVC, false vocal cord; EG, epiglottis; Tr, trachea; LTS, laryngotracheal separation; C, cricoids; com, communicated; decan., decannulation; B, blunt trauma; Pt., penetrating trauma; VC, vocal cord; ORIF, open reduction & internal fixation; OR, operation room.

laryngeal injury. The injury mechanism was classified as blunt trauma or penetration trauma, and the mechanism of trauma was examined comprehensively.

The injured area was described on the basis of the surgical record of the injured area of the laryngeal framework, and we examined whether or not the injury was a crushed comminuted fracture. For the evaluation of voice after treatment, patients who recovered their voice as it was prior to the trauma were classified as having a good result; those who recovered to a level at which they could function socially were classified as having a fair result; and those with aphonia or who could not carry out intellectual lingual com-

munication were classified as having a bad result. After the trauma occurred, laryngoscopy and suspension laryngoscopy were performed as laryngeal tests. Postsurgical laryngoscopy results obtained approximately 3 months after treatments were examined.

RESULTS

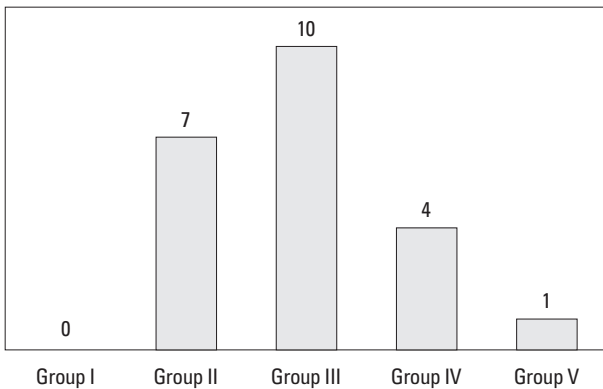
Among 22 patients, there were 19 male patients and 3 female patients. Laryngeal trauma occurred preferentially in males. Patient ages ranged from 21 to 77 years, with an average of 42±14 years. The age distribution was as follows: 3 cases of patients in their twenties (14%), 6 cases in their thirties (27%), 7 cases in their forties (32%), 3 cases in their fifties (14%), 2 cases in their sixties (9%), and 1 case in their seventies (5%). The proportion of patients who were in their thirties to forties who were social activity was high (Table 1).

The most prevalent symptoms of laryngeal fracture were pain at the trauma site (n=15) and odynophagia (n=15), followed by, in order of prevalence, voice change (n=4), dysphonia (n=3), hemoptysis (n=3), respiratory distress (n=3), subcutaneous emphysema at the neck (n=2), and loss of consciousness (n=2).

Concerning the severity of injury, according to the Schaefer-Fuhrman classification of laryngeal trauma, none of the patients corresponded to Group I, but Group II consisted of 7 patients, Group III of 10 patients, Group IV of 4 patients, and Group V of 1 patient (Fig. 1).

For the mechanism of injury, 13 patients experienced blunt trauma and 9 experienced penetrating trauma: 4 patients were assaulted by other people, 5 were in driver-caused traffic accidents, 3 had agricultural machinery accidents, 3 attempted suicide, 2 had safety accidents in the workplace, 4 had a fall, and 1 patient experienced a sports related trauma (Fig. 2).

The thyroid cartilage was the most prevalent injury site (n=18), followed by the cricoid cartilage (n=3), the arytenoid cartilage (n=3), and the epiglottis cartilage (n=1) (Fig. 3). Among the cases of injury to the arytenoid cartilage, only laceration and dislocation of the mucosa were observed in 2 cases, and in 1 case, severe displacement also occurred. Among the driver-caused traffic accident cases, in particular, bilateral fractures were prevalent, and the severity tended to be higher than that of fractures caused by different blunt and penetrating traumas. In addition, the pro-



Group	Injury
I	Minor endolaryngeal hematoma without detectable fracture
II	Edema, hematoma, minor mucosal disruption without exposed cartilage, nondisplaced fractures
III	Massive edema, mucosal disruption, exposed cartilage, vocal fold immobility, displaced fracture
IV	Group III with two or more fracture lines or massive trauma to laryngeal mucosa
V	Complete LT separation

Fig. 1. Severity of laryngeal injury (Schaefer-Fuhrman's classification). LT, laryngo tracheal.

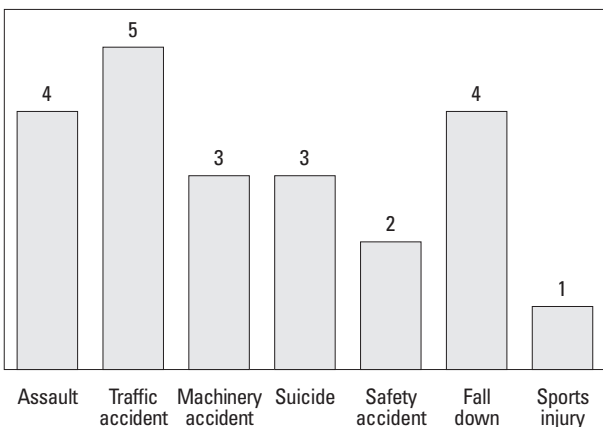


Fig. 2. Causes of laryngeal fracture.

portion of subjective voice changes and vocal cord paralysis was high (Fig. 4). Of the penetrating fractures, primarily in trauma cases caused by assault with a weapon by other people, but also in suicide attempts, the proportion of injuries in the left laryngeal cartilage was high. On the other hand, blunt trauma was equal for both sides (Fig. 5).

Noncomminuted fracture occurred in 17 patients, comminuted fracture in 4 patients, and laryngotracheal separation in 1 patient.

Airway management of laryngeal fracture patients was performed according to the airway management protocol of the severe trauma center. For Group II patients of the Schaefer-Fuhrman laryngeal trauma classification, no case required airway management. In patients higher than Group III who had injury in a relatively wide area, only 60% (9/15) required airway management. In all 9 patients who underwent airway management, the airway was secured by performing transoral flexible fiberoptic laryngoscope intubation at an emergency medical center and by subsequently converting to tracheostomy in the operating room. The tube was removed after an average of 11.2 days after tracheostomy intubation.

Of the 22 laryngeal fracture patients, surgical treatments were attempted in 19. First, for the assessment of the laryngeal injury area, a suspension laryngoscope was performed under general anesthesia. For reduction of a displacement fracture, 2 patients were fixated with plates. For nondisplacement fractures, 4 patients underwent suturing of the injured periosteum and adjacent soft tissues. In 11 cases, after reduction of the fracture cartilage, primary suturing was performed, the fixation suture covered by the periosteum and adjacent soft tissues. For laryngotracheal separation, laryngotracheal anastomosis was performed in 1 case. In fractures in a wide area, primary suturing was performed after debridement only in 1 patient (Fig. 6). In most cases,

insertion of laryngeal stents was not required. Nonetheless, in 2 cases, laryngeal stents were inserted because of severe injury to the inner mucosa.

Regarding the voice results after treatment for laryngeal fracture, 6 cases showed fair results and 1 case showed a bad result. Of 7 patients who presented with heterophony after treatment, 6 experienced blunt trauma. One penetrating trauma case (No. 4) showed unilateral vocal cord paralysis prior to treatment; the patient could not be followed up, and thus posttreatment results were unable to be assessed (Table 1). Six cases presented vocal cord paralysis after treatment. In 2 cases (No. 7 and 16), after the lacerated vocal cord was sutured, it was replaced with granulation tissue, and a reduction in vocal cord movements and closure failure occurred. Of 6 cases of vocal cord paralysis, 4 experienced blunt trauma caused by driver-caused traffic accidents. One of these cases (No. 13) was diagnosed as laryngotracheal separation and unilateral vocal cord paralysis due to severance of the recurrent laryngeal nerve. For another patient with unilateral vocal cord palsy (No. 14), who experienced penetrating trauma, arytenoid cartilage reduction and suture of the mucosa were performed. After the treatments, vocal cord paralysis in the

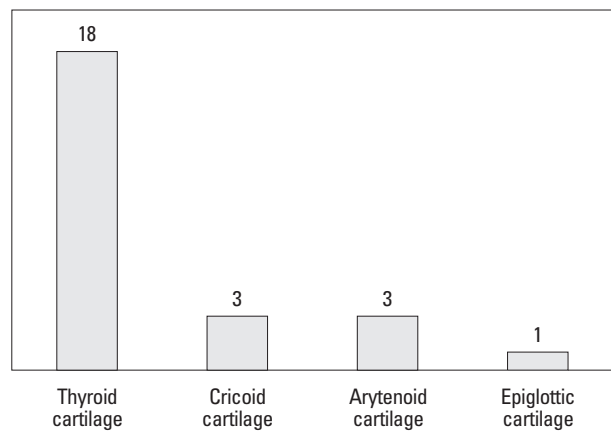


Fig. 3. Subsite of injury in laryngeal fracture.

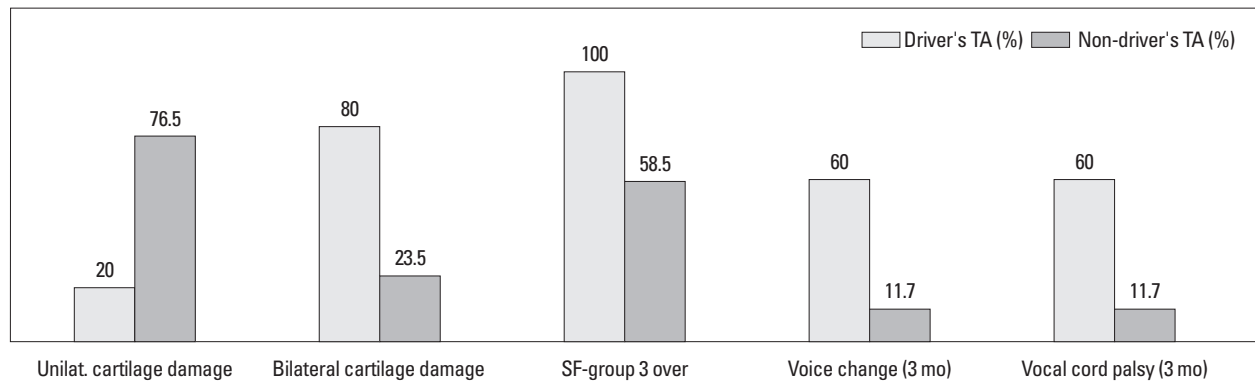


Fig. 4. Severity of laryngeal fracture due to driver-caused TAs and non-driver-caused TAs. TA, traffic accident.

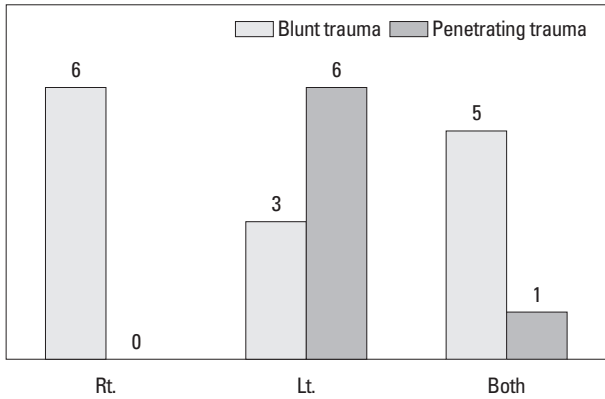


Fig. 5. Characteristic features of penetrating injury with laryngeal fracture.

left side was detected (Table 1).

The posttreatment follow-up observation period was, on average, 3 years. During this period, none of the patients died.

DISCUSSION

Laryngeal fracture is an infrequent acute traumatic injury in the neck area due to the fact that the upper area of the larynx is protected by the maxilla and the lower area by the sternum and other framework. On one hand, the elasticity of the cartilage resists fractures caused by low-velocity trauma. On the other hand, in many cases, patients die before reaching the trauma emergency medical center because of severe airway injury or multicentric organ injury occurring in association with laryngeal fracture.^{2,3}

According to Gussack, et al.,² in 2500 trauma patients, approximately 1 has an injury associated with the upper respiratory system and gastrointestinal system. Minard, et al.⁵ reported that approximately 0.3% of patients who were admitted to trauma emergency medical centers were laryngeal trauma patients. Jalisi and Zoccoli³ reported 12 cases in 10 years.^{2,4,6} Consequently, it could be inferred that approximately 2-5 laryngeal trauma patients are admitted to an emergency medical center annually. The rate of laryngeal fracture in our study was comparable to that in reported studies.

For successful diagnosis and treatment of laryngeal fracture, it is most important to suspect laryngeal fracture in patients with trauma in the neck and to perform aggressive physical examination. In our study, 1 case (No. 2) was treated for neck trauma in the emergency medical center at another hospital, but thyroid cartilage fracture and vocal cord paralysis were not diagnosed. Afterward, the patient visited our hospital for hoarseness caused by vocal cord paralysis.

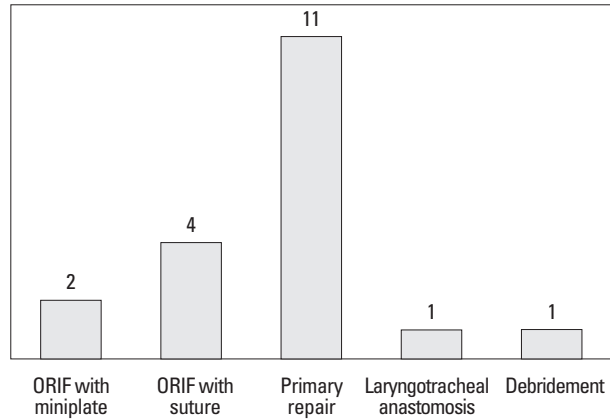


Fig. 6. Operating management of laryngeal fracture. ORIF, open reduction & internal fixation.

The representative findings in cases in which laryngeal trauma should be considered are respiratory distress, hoarseness, stridor, subcutaneous emphysema in the neck, hemoptysis, neck hematomas, subcutaneous hemorrhage in the neck, laryngeal tenderness, vocal cord dysfunction, and the loss of an anatomical landmark in the neck.^{1,6} In our results, pain at the trauma site and odynophagia were most prevalent, followed by, in order of prevalence, voice change, hemoptysis, dyspnea, subcutaneous emphysema in the neck, and loss of consciousness. At the time of diagnosis of laryngeal fracture, the most helpful radiological test is computed tomography of the neck with contrast dye, which a sensitive method that can be used to diagnose abnormalities in the laryngeal framework.⁷⁻¹⁰

The mortality rate, which reflects the severity of an injury, in laryngeal fracture caused by blunt trauma has been reported to be higher than 40%, whereas that for penetrating trauma has been reported to be lower than 20%.⁵ The mortality rate is determined by early airway management performed at the rescue field and emergency medical centers, as well as considering the severity of associated injury. Airway management is the greatest problem, in particular, and airway management methods are controversial. Shortcomings of transoral endotracheal intubation include the displacement of the arytenoid cartilage during intubation, laceration of injured laryngeal tissues, and the complete closure of an airway that is already meager if airway management by endotracheal intubation fails. However, if performed at experienced emergency centers or for cases in which fiberoptic laryngoscopic examination is normal, attempting to secure the airway by immediate transoral flexible fiberoptic laryngoscope intubation and conversion to tracheostomy afterwards is a good method.^{4,6,11} Similarly, in our study, transoral intubation with a fiberoptic laryngoscope was first at-

tempted at the emergency center for patients who required airway management, and by this means, the airway could be secured safely.

The injury mechanism of laryngeal fracture can be classified broadly as either blunt trauma or penetrating trauma. In the literature, blunt trauma has been reported to be the most frequent cause of laryngeal fracture. For this type of trauma, the proportion of injuries caused by driver-caused traffic accidents is decreasing, and thus, laryngeal fractures caused by general blunt trauma are also decreasing.¹² This is thought to be due to improvement of airbags and abundant safety devices for riders. In driver-caused traffic accidents, the incidence of laryngeal fracture has also decreased. On the other hand, laryngeal fracture caused by sports is on the increase. It occurs in relatively fast sports such as those in which motorcycles, bicycles, skis, and other such equipment are used.¹³ In addition, the proportion of penetrating laryngeal injury is on the rise, and is thought to be the result of increased trauma caused by industrialization and urbanization. Stabbing injury, injury caused by guns or machines, and other similar types of injury have been reported to be important causes of penetrating neck trauma.^{1,2,14} In our study, in comparison with other studies, trauma caused by sports was not abundant, and penetrating trauma caused by machines or stabbing was abundant (40.9%). This was thought to be influenced by the locality of the area, which is adjacent to an agricultural and fishing area, where there are few young populations, and thus trauma pertinent to sports is not abundant, but trauma caused by brush cutters and suicide is on the rise.

In blunt trauma cases, the thyroid cartilage and the front area of the cricoid cartilage, which are relatively protruded, were frequent injury sites, and cases with injury to several areas were more prevalent than seen with penetrating trauma. In penetrating trauma, nondisplacement fractures were abundant, and fracture in the thyroid cartilage of the widest area was abundant. In cases caused by attacks with weapons and in suicide cases, the left cartilage was injured, which is thought to be due to the high proportion of right-handed people (Fig. 5).

In laryngeal trauma cases, to rule out association with esophageal laceration, esophagus examination is generally performed.^{3,4,15} In our study, tests that assess associated esophageal injury were performed in all patients, and esophageal injury was not detected in any of them. In blunt trauma, the possibility of esophageal trauma is low in comparison with that associated with penetrating trauma, and in

mild cases, the possibility of esophageal injury is lower than that in severe injury cases. Thus, more studies are required to determine whether esophageal tests should always be performed in mild blunt trauma cases.

In regards to the selection of treatment methods, in our study, assessment of airway abnormality and vocal cord injury was made during suspension laryngoscopy in the operating room. For cases in which hematomas may have hindered secure airway management, cases in which edema in the mucosa was detected in a wide area, or cases in which laryngeal fracture occurred in a wide area (higher than SF grade III), tracheostomy was performed. After reduction of the laryngeal framework, the fractured larynx was fixated by suturing or by using a plate and the injured mucosa was sutured. In our study, all except 2 cases associated with injury in the laryngeal framework and the mucosa in a wide area were able to be safely treated without the insertion of stents. In 1 patient who received debridement for injury in the laryngeal framework in a wide area (No. 15), a permanent tracheostomy was performed. In the other cases, the tubes could be removed after surgery. One patient (No. 13) was admitted for laryngotracheal separation. The airway was secured by transoral intubation, and end-to-end anastomosis was performed.

After treatment of laryngeal fracture, voice outcomes have been reported to be relatively good (higher than good in 76-97% cases). Butler, et al.⁷ reported that the voice results of a group who were treated early after injury (within 48 hours) and a delayed treatment group were examined, and the early treatment group had a recovery rate that was more than two times that of the delayed treatment group.^{1,2,11} After treatment of laryngeal trauma, voice change occurred primarily by three mechanisms: 1) because of the alteration of the laryngeal framework, the tension of both vocal cords changed; 2) after the laceration of the vocal cord mucosa and ligaments, they were replaced with granulation tissue, and thus the elasticity of the vocal cord and the movement of the mucosa during phonation was reduced; and 3) unilateral and bilateral vocal cord palsy.¹⁶ In our study, to correct voice change, surgery at the early phase was focused on the correction of the laryngeal framework; the laceration and injury of the laryngeal lumen were corrected by use of adjacent tissues if possible; and aggressive treatments were performed by injection laryngoplasty for cases of injury in the laryngeal recurrent nerves; and relatively good results were obtained. However, most patients required endotracheal intubation or tracheostomy and the voice could not be as-

sessed prior to surgery; thus it was difficult to evaluate it objectively. It is thus thought that the most important treatment principle is to make efforts to restore the original conditions during surgery if possible.

In comparison with the findings of past studies (20%), in the current study, the proportion of laryngeal fracture caused by penetrating trauma was higher (40.9%) and the laryngeal injury sites were different, depending on the mechanism and cause of laryngeal injury. In driver-caused traffic accidents, injury in a wide area within the larynx occurred, poor voice results were seen after injury, and these injuries required aggressive diagnosis and treatment. In the treatment of laryngeal fracture, early diagnosis and airway management were important, and when endotracheal intubation was performed at experienced emergency centers with fiberoptic laryngoscopes, airway management was able to be safely achieved. In addition, if the fractured laryngeal framework was corrected at appropriate times, voice results were good.

ACKNOWLEDGEMENTS

This work was supported by clinical research fund (GNU HCRF- 2011-011) from the Gyeongsang National University Hospital.

REFERENCES

- Schaefer SD. The acute management of external laryngeal trauma. A 27-year experience. *Arch Otolaryngol Head Neck Surg* 1992; 118:598-604.
- Gussack GS, Jurkovich GJ, Luteran A. Laryngotracheal trauma: a protocol approach to a rare injury. *Laryngoscope* 1986;96:660-5.
- Jalisi S, Zoccoli M. Management of laryngeal fractures--a 10-year experience. *J Voice* 2011;25:473-9.
- Bent JP 3rd, Silver JR, Porubsky ES. Acute laryngeal trauma: a review of 77 patients. *Otolaryngol Head Neck Surg* 1993;109(3 Pt 1):441-9.
- Minard G, Kudsk KA, Croce MA, Butts JA, Cicala RS, Fabian TC. Laryngotracheal trauma. *Am Surg* 1992;58:181-7.
- Hwang SY, Yeak SC. Management dilemmas in laryngeal trauma. *J Laryngol Otol* 2004;118:325-8.
- Butler AP, Wood BP, O'Rourke AK, Porubsky ES. Acute external laryngeal trauma: experience with 112 patients. *Ann Otol Rhinol Laryngol* 2005;114:361-8.
- Eliachar I. Management of acute laryngeal trauma. *Acta Otorhinolaryngol Belg* 1996;50:151-8.
- Fuhrman GM, Stieg FH 3rd, Buerk CA. Blunt laryngeal trauma: classification and management protocol. *J Trauma* 1990;30:87-92.
- Jewett BS, Shockley WW, Rutledge R. External laryngeal trauma analysis of 392 patients. *Arch Otolaryngol Head Neck Surg* 1999; 125:877-80.
- Grewal H, Rao PM, Mukerji S, Ivatury RR. Management of penetrating laryngotracheal injuries. *Head Neck* 1995;17:494-502.
- Lee WT, Eliashar R, Eliachar I. Acute external laryngotracheal trauma: diagnosis and management. *Ear Nose Throat J* 2006;85: 179-84.
- Irish JC, Hekkenberg R, Gullane PJ, Brown DH, Rotstein LE, Neligan P, et al. Penetrating and blunt neck trauma: 10-year review of a Canadian experience. *Can J Surg* 1997;40:33-8.
- Hanft K, Posternack C, Astor F, Attarian D. Diagnosis and management of laryngeal trauma in sports. *South Med J* 1996;89:631-3.
- Vassiliu P, Baker J, Henderson S, Alo K, Velmahos G, Demetriades D. Aerodigestive injuries of the neck. *Am Surg* 2001;67:75-9.
- Hirano M, Kurita S, Terasawa R. Difficulty in high-pitched phonation by laryngeal trauma. *Arch Otolaryngol* 1985;111:59-61.