

## Open Access

# Management of Non-Variceal Upper Gastrointestinal Bleeding

Seung Young Kim, Jong Jin Hyun, Sung Woo Jung and Sang Woo Lee

Division of Gastroenterology and Hepatology, Department of Internal Medicine, Korea University College of Medicine, Seoul, Korea

Upper gastrointestinal bleeding (UGIB) is a critical condition that demands a quick and effective medical management. Non-variceal UGIB, especially peptic ulcer bleeding is the most significant cause. Appropriate assessment and treatment have a major influence on the prognosis of patients with UGIB. Initial fluids resuscitation and/or transfusion of red blood cells are necessary in patients with clinical evidence of intravascular volume depletion. Endoscopy is essential for diagnosis and treatment of UGIB, and should be provided within 24 hours after presentation of UGIB. Pre-endoscopic use of intravenous proton pump inhibitor (PPI) can downstage endoscopic signs of hemorrhage. Post-endoscopic use of high-dose intravenous PPI can reduce the risk of rebleeding and further interventions such as repeated endoscopy and surgery. Eradication of *Helicobacter pylori* and withdrawal of non-steroidal anti-inflammatory drugs are recommended to prevent recurrent bleeding.

**Key Words:** Gastrointestinal hemorrhage; Peptic ulcer hemorrhage; Gastrointestinal endoscopy; Disease management

## INTRODUCTION

Non-variceal upper gastrointestinal bleeding (UGIB) is a critical clinical condition that requires an urgent management. Although there was a significant reduction in the incidence of bleeding peptic ulcers with the introduction of proton pump inhibitor (PPI) and eradication of *Helicobacter pylori*,<sup>1,2</sup> UGIB still remains a clinically important issue due to the increase in the proportion of elderly population, use of non-steroidal anti-inflammatory drugs (NSAIDs) and in-hospital UGIB. This review focuses on recently published articles addressing the management of acute non-variceal UGIB.<sup>3-5</sup>

## INITIAL ASSESSMENT AND RISK STRATIFICATION

The first step in the management of patients presenting with overt UGIB is the assessment of hemodynamic status

Received: July 7, 2012 Revised: July 21, 2012

Accepted: July 21, 2012

Correspondence: Sang Woo Lee

Division of Gastroenterology and Hepatology, Department of Internal Medicine, Korea University Ansan Hospital, Korea University College of Medicine, 123 Jeokgeum-ro, Danwon-gu, Ansan 425-707, Korea

Tel: +82-31-412-5580, Fax: +82-31-412-5582, E-mail: leesw@kumc.or.kr

© This is an Open Access article distributed under the terms of the Creative Commons Attribution Non-Commercial License (<http://creativecommons.org/licenses/by-nc/3.0>) which permits unrestricted non-commercial use, distribution, and reproduction in any medium, provided the original work is properly cited.

and initiation of resuscitative measures as needed. Intravenous (IV) fluids and transfusion of red blood cells targeting hemoglobin level of  $\geq 7$  g/dL may be required in euvolemic patients. Higher hemoglobin levels may need to be targeted in patients with clinical evidence of intravascular volume depletion or comorbidities such as coronary artery disease.

Risk assessment of patients is clinically useful to determine which patients are at higher risk of further bleeding and may aid in making management decisions such as timing of endoscopy, time of discharge and level of care. The widely studied methods used to assess risk and to predict risk of rebleeding and mortality include the Rockall score<sup>6</sup> and Blatchford score.<sup>7</sup> In a recent study from Hong Kong,<sup>8</sup> patients who needed endoscopic treatment showed a significantly higher Blatchford score and a threshold of more than 1 (high risk) was useful for predicting patients who needed endoscopic treatment; however, Rockall score could not definitely identify higher risk patients in this study. On the other hand, another study from United Kingdom showed that patients who were classified as low risk with Blatchford score of 0 and were managed on the outpatient bases showed no additional adverse events, and that the proportion of admitted patients also fell.<sup>9</sup>

## PRE-ENDOSCOPIC CARE

Recent consensus suggests that nasogastric or orogastric lavage is not helpful in patients with UGIB for diagnosis, prog-

nosis, visualization, or therapeutic effect.<sup>3,5</sup>

A Cochrane meta-analysis of six randomized trials of pre-endoscopic PPI therapy found no significant differences between PPI group and control in mortality (odds ratio [OR], 95% confidence interval [CI] 1.12, 0.72 to 1.73), rebleeding (OR, 95% CI, 0.81, 0.61 to 1.09), or surgery (OR, 95% CI, 0.96, 0.68 to 1.35). However, pre-endoscopic use of PPIs significantly reduced the proportion of patients with high-risk stigmata (OR, 95% CI, 0.67, 0.54 to 0.84) and the need for endoscopic therapy (OR, 95% CI, 0.68, 0.50 to 0.93) compared with patients who received placebo or a histamine-2 receptor antagonist.<sup>10</sup> A large single-center randomized controlled study also showed the benefit of pre-endoscopic high-dose IV PPI therapy in downgrading the stigmata of hemorrhage at index endoscopy.<sup>11</sup>

## TIMING OF ENDOSCOPY

Observational studies showed the benefit of endoscopy within 24 hours after admission in terms of decreasing length of stay and surgical intervention.<sup>12,13</sup> Therefore, it is recommended that all hospitals provide sufficient resources for an endoscopy service that can offer an examination within 24 hours after patient presentation, including weekends and holidays. In addition, in very high risk patients who are hemodynamically unstable and those who present with massive hematemesis, endoscopy should be performed as soon as they are stabilized through resuscitation.<sup>14</sup>

## ENDOSCOPIC THERAPY

Endoscopic therapy is considered according to the stigmata of recent hemorrhage which indicates the appearance of an ulcer base at endoscopy in patients with ulcer bleeding. The stigmata can predict the risk of further bleeding and the need for therapeutic intervention.<sup>15,16</sup> The Forrest classification is commonly used to describe the stigmata in Europe and Asia. In this classification, grade I represents active hemorrhage, grade II denotes recent stigmata of bleeding, and grade III indicates no stigmata of recent hemorrhage (Fig. 1).<sup>15,17</sup> Endoscopic therapy should be provided to patients with active spurting or oozing of blood or a non-bleeding visible vessel. The role of endoscopic therapy for ulcers with adherent clot is controversial.<sup>18</sup> However, endoscopic therapy may be considered in patients with adherent clot resistant to vigorous irrigation, especially for those with higher risk of rebleeding.

Thermocoagulation, clips or sclerosant injection are recommended alone or in combination with epinephrine injection. Although epinephrine therapy alone is more effective than medical therapy, it is inferior to other monotherapies or combi-

nation therapies.<sup>19-22</sup>

Second-look endoscopy, which is generally defined as a repeat endoscopy within 24 hours after initial endoscopy and hemostatic therapy, is not routinely recommended after endoscopic hemostasis. Several data reported a small but significant reduction in rebleeding in patients undergoing second-look endoscopy,<sup>23,24</sup> but these studies were done before high-dose IV PPI therapy have been adopted as the current standard after endoscopic therapy, which suggest that second-look endoscopy may not provide additional benefits.<sup>25</sup> However, a subgroup of patients with particularly high-risk presentations may benefit from second-look endoscopy, but this requires further study.

## MEDICAL THERAPY AFTER ENDOSCOPY

After endoscopic management, an IV bolus followed by infusion of high-dose PPI reduces recurrent bleeding, need for repeated endoscopy, surgery and blood transfusion. This was evident in the Cochrane meta-analysis, which showed that even mortality was reduced with the use of IV high-dose PPIs.<sup>26</sup> The use of high-dose IV PPIs has also been found to be cost effective in both Asia and USA.<sup>19,27</sup> However, in patients with lower risk stigmata (clean base, flat pigmented spot), standard PPI therapy (e.g., oral PPI once-daily) is enough to heal the ulcer.<sup>15</sup>

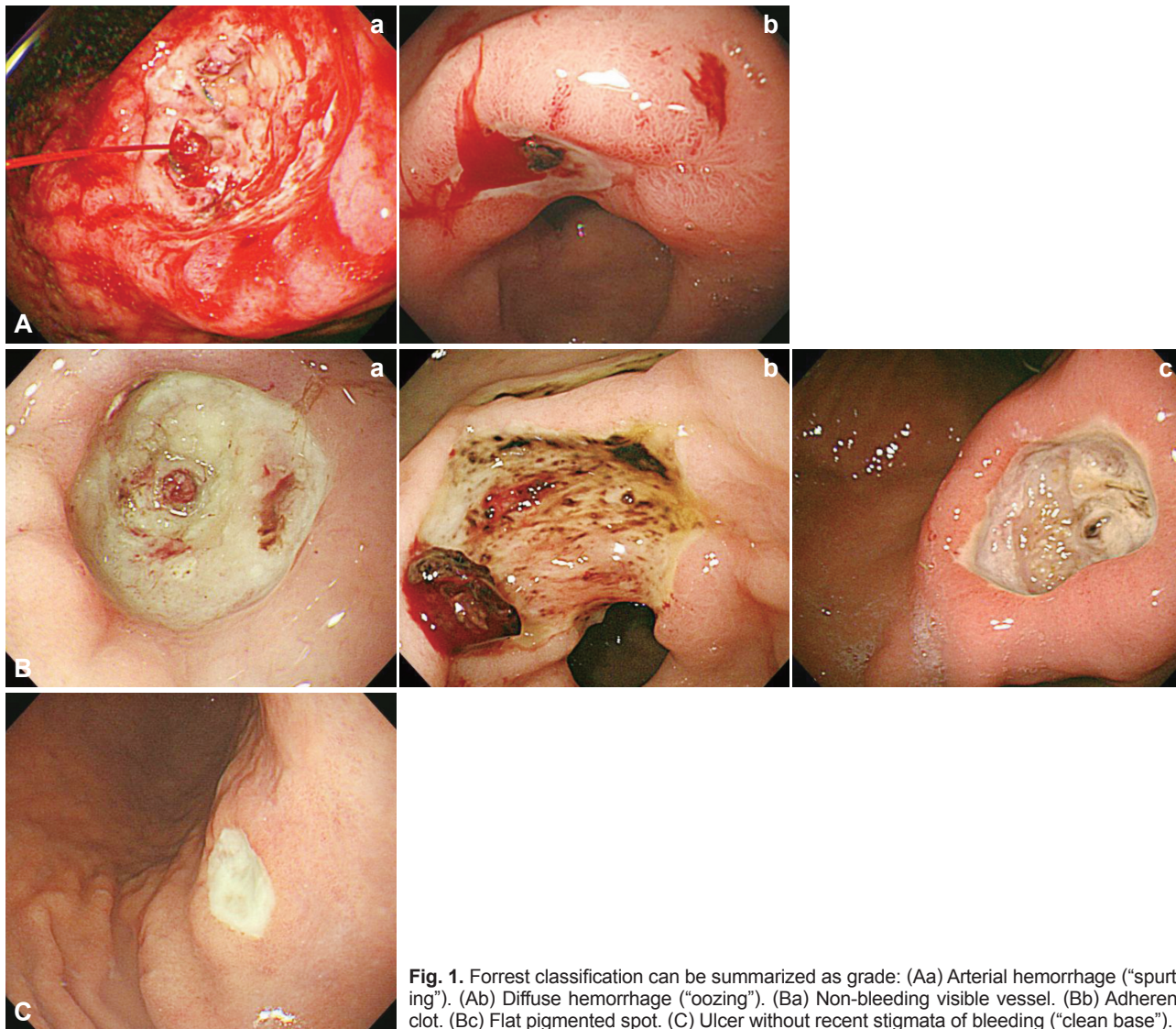
## OTHER CONSIDERATIONS

When the first endoscopy fails to control peptic ulcer bleeding, surgery offers a better chance to secure hemostasis but repeated endoscopic treatment carries fewer complications.<sup>28</sup> Angiographic embolization should be considered as an alternative to surgery because not all patients are suitable candidates for surgery.<sup>29</sup>

## LONG-TERM PREVENTION OF RECURRENT BLEEDING ULCERS

Patients with *H. pylori*-associated bleeding ulcers should receive *H. pylori* therapy. A systematic review of studies assessing rebleeding in patients with documented *H. pylori* eradication revealed a 1.3% incidence of rebleeding over a mean follow-up periods of 11 to 53 months.<sup>30</sup> After documentation of eradication, maintenance of antisecretory therapy is not needed unless the patient also requires administration of NSAIDs or antithrombotics.

In patients with NSAID-associated bleeding ulcers, the need for NSAIDs should be carefully assessed and NSAIDs should not be resumed if possible. In patients who must restart NS-



**Fig. 1.** Forrest classification can be summarized as grade: (Aa) Arterial hemorrhage (“spurting”). (Ab) Diffuse hemorrhage (“oozing”). (Ba) Non-bleeding visible vessel. (Bb) Adherent clot. (Bc) Flat pigmented spot. (C) Ulcer without recent stigmata of bleeding (“clean base”).

AIDs, a COX-2 selective NSAID plus PPI offers the best available upper gastrointestinal (GI) protection.<sup>31,32</sup> The need for antiplatelet therapy should be reviewed in patients who have ulcer bleeding while taking low-dose aspirin. In patients who are taking aspirin for primary prophylaxis (no overt cardiovascular disease), the benefit of low-dose aspirin is relatively small.<sup>33</sup> However, the benefit of low-dose aspirin for secondary prophylaxis in patients with established cardiovascular disease is much larger.<sup>33</sup> Discontinuing antiplatelet treatment in patients with high cardi thrombotic risk increases the likelihood of occurrence of adverse cardiovascular events. A prospective study in Asia showed that patients whose aspirin treatment was discontinued after endoscopic hemostasis of ulcer bleeding had a lower risk of recurrent bleeding but significantly higher mortality, most of which were related to cardiovascular and cerebrovascular death.<sup>34</sup> Thus, it is recommended that aspirin be resumed as soon as possible after ach-

ieving endoscopic hemostasis. Data are lacking regarding the optimal timing for resuming clopidogrel or dual antiplatelet treatment after GI bleeding.

## CONCLUSIONS

Management of patients with non-variceal UGIB should proceed in a step-wise manner. After initial assessment of hemodynamic status and resuscitation, patients can be risk stratified by clinical features. Most patients should receive an upper endoscopy within 24 hours, and those with high-risk findings on endoscopy should receive endoscopic therapy with IV PPI infusion. Prevention of recurrent bleeding is based on the presumed etiology of the bleeding ulcer. It is recommended that *H. pylori* should be eradicated if present and NSAIDs should be stopped whenever possible. Patients with established cardiovascular risk should resume antiplatelet

therapy as soon as possible after hemostasis.

## Conflicts of Interest

The authors have no financial conflicts of interest.

## REFERENCES

- Hermansson M, Ekedahl A, Ranstam J, Zilling T. Decreasing incidence of peptic ulcer complications after the introduction of the proton pump inhibitors, a study of the Swedish population from 1974-2002. *BMC Gastroenterol* 2009;9:25.
- Loperfido S, Baldo V, Piovesana E, et al. Changing trends in acute upper-GI bleeding: a population-based study. *Gastrointest Endosc* 2009; 70:212-224.
- Barkun AN, Bardou M, Kuipers EJ, et al. International consensus recommendations on the management of patients with nonvariceal upper gastrointestinal bleeding. *Ann Intern Med* 2010;152:101-113.
- Sung JJ, Chan FK, Chen M, et al. Asia-Pacific Working Group consensus on non-variceal upper gastrointestinal bleeding. *Gut* 2011;60:1170-1177.
- Laine L, Jensen DM. Management of patients with ulcer bleeding. *Am J Gastroenterol* 2012;107:345-360.
- Rockall TA, Logan RF, Devlin HB, Northfield TC. Risk assessment after acute upper gastrointestinal haemorrhage. *Gut* 1996;38:316-321.
- Blatchford O, Murray WR, Blatchford M. A risk score to predict need for treatment for upper-gastrointestinal haemorrhage. *Lancet* 2000; 356:1318-1321.
- Pang SH, Ching JY, Lau JY, Sung JJ, Graham DY, Chan FK. Comparing the Blatchford and pre-endoscopic Rockall score in predicting the need for endoscopic therapy in patients with upper GI hemorrhage. *Gastrointest Endosc* 2010;71:1134-1140.
- Stanley AJ, Ashley D, Dalton HR, et al. Outpatient management of patients with low-risk upper-gastrointestinal haemorrhage: multicentre validation and prospective evaluation. *Lancet* 2009;373:42-47.
- Sreedharan A, Martin J, Leontiadis GI, et al. Proton pump inhibitor treatment initiated prior to endoscopic diagnosis in upper gastrointestinal bleeding. *Cochrane Database Syst Rev* 2010;(7):CD005415.
- Lau JY, Leung WK, Wu JC, et al. Omeprazole before endoscopy in patients with gastrointestinal bleeding. *N Engl J Med* 2007;356:1631-1640.
- Cooper GS, Chak A, Connors AF Jr, Harper DL, Rosenthal GE. The effectiveness of early endoscopy for upper gastrointestinal hemorrhage: a community-based analysis. *Med Care* 1998;36:462-474.
- Cooper GS, Chak A, Way LE, Hammar PJ, Harper DL, Rosenthal GE. Early endoscopy in upper gastrointestinal hemorrhage: associations with recurrent bleeding, surgery, and length of hospital stay. *Gastrointest Endosc* 1999;49:145-152.
- Lin HJ, Wang K, Perng CL, et al. Early or delayed endoscopy for patients with peptic ulcer bleeding. A prospective randomized study. *J Clin Gastroenterol* 1996;22:267-271.
- Laine L, Peterson WL. Bleeding peptic ulcer. *N Engl J Med* 1994;331: 717-727.
- Enestvedt BK, Gralnek IM, Mattek N, Lieberman DA, Eisen G. An evaluation of endoscopic indications and findings related to nonvariceal upper-GI hemorrhage in a large multicenter consortium. *Gastrointest Endosc* 2008;67:422-429.
- Gisbert JP, Legido J, Castel I, et al. Risk assessment and outpatient management in bleeding peptic ulcer. *J Clin Gastroenterol* 2006;40: 129-134.
- Laine L, McQuaid KR. Endoscopic therapy for bleeding ulcers: an evidence-based approach based on meta-analyses of randomized controlled trials. *Clin Gastroenterol Hepatol* 2009;7:33-47.
- Barkun AN, Herba K, Adam V, Kennedy W, Fallone CA, Bardou M. High-dose intravenous proton pump inhibition following endoscopic therapy in the acute management of patients with bleeding peptic ulcers in the USA and Canada: a cost-effectiveness analysis. *Aliment Pharmacol Ther* 2004;19:591-600.
- Marmo R, Rotondano G, Piscopo R, Bianco MA, D'Angella R, Cipolletta L. Dual therapy versus monotherapy in the endoscopic treatment of high-risk bleeding ulcers: a meta-analysis of controlled trials. *Am J Gastroenterol* 2007;102:279-289.
- Sung JJ, Tsoi KK, Lai LH, Wu JC, Lau JY. Endoscopic clipping versus injection and thermo-coagulation in the treatment of non-variceal upper gastrointestinal bleeding: a meta-analysis. *Gut* 2007;56:1364-1373.
- Yuan Y, Wang C, Hunt RH. Endoscopic clipping for acute nonvariceal upper-GI bleeding: a meta-analysis and critical appraisal of randomized controlled trials. *Gastrointest Endosc* 2008;68:339-351.
- Chiu PW, Lam CY, Lee SW, et al. Effect of scheduled second therapeutic endoscopy on peptic ulcer rebleeding: a prospective randomised trial. *Gut* 2003;52:1403-1407.
- Marmo R, Rotondano G, Bianco MA, Piscopo R, Prisco A, Cipolletta L. Outcome of endoscopic treatment for peptic ulcer bleeding: is a second look necessary? A meta-analysis. *Gastrointest Endosc* 2003;57:62-67.
- Tsoi KK, Chan HC, Chiu PW, Pau CY, Lau JY, Sung JJ. Second-look endoscopy with thermal coagulation or injections for peptic ulcer bleeding: a meta-analysis. *J Gastroenterol Hepatol* 2010;25:8-13.
- Leontiadis GI, Sharma VK, Howden CW. Proton pump inhibitor treatment for acute peptic ulcer bleeding. *Cochrane Database Syst Rev* 2006;(1):CD002094.
- Lee KK, You JH, Wong IC, et al. Cost-effectiveness analysis of high-dose omeprazole infusion as adjuvant therapy to endoscopic treatment of bleeding peptic ulcer. *Gastrointest Endosc* 2003;57:160-164.
- Lau JY, Sung JJ, Lam YH, et al. Endoscopic retreatment compared with surgery in patients with recurrent bleeding after initial endoscopic control of bleeding ulcers. *N Engl J Med* 1999;340:751-756.
- Ripoll C, Bañares R, Beceiro I, et al. Comparison of transcatheter arterial embolization and surgery for treatment of bleeding peptic ulcer after endoscopic treatment failure. *J Vasc Interv Radiol* 2004;15:447-450.
- Gisbert JP, Khorrami S, Carballo F, Calvet X, Gene E, Dominguez-Munoz E. Meta-analysis: Helicobacter pylori eradication therapy vs. antisecretory non-eradication therapy for the prevention of recurrent bleeding from peptic ulcer. *Aliment Pharmacol Ther* 2004;19:617-629.
- Chan FK, Hung LC, Suen BY, et al. Celecoxib versus diclofenac and omeprazole in reducing the risk of recurrent ulcer bleeding in patients with arthritis. *N Engl J Med* 2002;347:2104-2110.
- Chan FK, Wong VW, Suen BY, et al. Combination of a cyclo-oxygenase-2 inhibitor and a proton-pump inhibitor for prevention of recurrent ulcer bleeding in patients at very high risk: a double-blind, randomised trial. *Lancet* 2007;369:1621-1626.
- Antithrombotic Trialists' (ATT) Collaboration, Baigent C, Blackwell L, et al. Aspirin in the primary and secondary prevention of vascular disease: collaborative meta-analysis of individual participant data from randomised trials. *Lancet* 2009;373:1849-1860.
- Sung JJ, Lau JY, Ching JY, et al. Continuation of low-dose aspirin therapy in peptic ulcer bleeding: a randomized trial. *Ann Intern Med* 2010; 152:1-9.