

Case Report

Alveolar Soft Part Sarcoma Metastasized to Both the Skull and the Brain

Tae-Hee Shin, M.D., Young-Jin Jung, M.D., Oh-Lyong Kim, M.D., Min-Su Kim, M.D.

Department of Neurosurgery, Yeungnam University College of medicine, Daegu, Korea

Alveolar soft part sarcoma (ASPS) with skull and brain metastases is extremely rare. A 53-year-old patient diagnosed as skull metastasis of ASPS visited our clinic complaining of an outgrowing scalp mass in spite of radiation therapy. Past medical history revealed that the patient had been diagnosed and treated for ASPS of the thigh 4 years ago. Magnetic resonance imaging revealed a hyperintense ovoid mass on the T2-weighted image, an isointense on the T1-weighted image, and a homogeneous enhanced mass with gadolinium. Another small-sized enhanced mass with mild peritumoral swelling was found at the deep white matter of the left frontal lobe. A gross total resection of the skull lesion with cranioplasty was performed for the surgical defect. A histologic examination of the specimens revealed metastatic ASPS involving the skull. Surgery with a total removal of the lesions may be effective for improving a patient's symptoms especially from neurological dysfunction.

Key Words : Alveolar soft part sarcoma · Brain metastasis · Sarcoma · Surgery.

INTRODUCTION

Alveolar soft part sarcoma (ASPS), a rare tumor accounting for less than 1% of the sarcoma subtypes, usually develops in the soft tissues of the extremities¹⁰. The histopathogenesis of ASPS is unclear, but it has specific cellular characteristics. It is also characterized by unusual patterns of metastatic spread. For example, brain metastases have been described as a common feature of metastatic ASPS^{5,9,14,16,19}, whereas those metastases are reported to be relatively rare in other high grade sarcomas. However, ASPS metastasized to both skull and brain metastases are unusual and only several cases have been reported^{9,15,16}. The present report discusses such a rare case of ASPS with metastases to both the skull and the brain.

CASE REPORT

A 53-year-old woman had a growing hard mass on the frontal part of her head for 8 months and complained of cosmetic problems. Four years ago, the patient had undergone surgery at the Orthopedic Surgery department of our hospital due to a palpable mass on the left thigh, and had been diagnosed with ASPS.

The patient had also been diagnosed with multiple lung metastases. At that time, the patient was treated with chemotherapy at our Oncology department. Although first-line, third-generation cyclophosphamide, vincristine, doxorubicin and dacarbazine chemotherapy and second-line, third-generation mesna, adriamycin, ifosfamide and dacarbazine chemotherapy were done, there was no interval change of size of the lung metastases. About 1 year ago, the patient developed a metastatic tumor in the skull and the brain despite systemic chemotherapy, and received radiotherapy (30 cGy/10 fractions) to the involved skull and frontal lesion. However the skull mass continued to outgrow.

Computed tomography showed a mass lesion with bony erosion on the midline of the frontal area. Magnetic resonance imaging revealed a hyperintense ovoid mass on the T2-weighted image, an isointense on the T1-weighted image, and a homogeneous enhanced mass with gadolinium (Fig. 1A, B). Another small-sized enhanced mass with mild peritumoral edema was found at the deep white matter of the left frontal lobe (Fig. 1C). The patient showed no neurological deficit except complaint of a cosmetic problem. We performed a craniotomy for excision of the tumor. The tumor mass was soft, hypervascular and well-

• Received : November 30, 2011 • Revised : May 16, 2012 • Accepted : July 6, 2012

• Address for reprints : Min-Su Kim, M.D.

Department of Neurosurgery, Yeungnam University College of Medicine, 170 Hyeonchung-ro, Nam-gu, Daegu 705-717, Korea

Tel : +82-53-620-3790, Fax : +82-53-620-3770, E-mail : mogumns@daum.net

• This is an Open Access article distributed under the terms of the Creative Commons Attribution Non-Commercial License (<http://creativecommons.org/licenses/by-nc/3.0>) which permits unrestricted non-commercial use, distribution, and reproduction in any medium, provided the original work is properly cited.

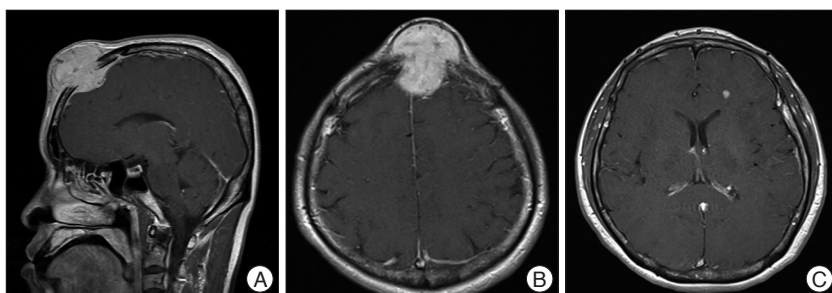


Fig. 1. Magnetic resonance images of the patient with ASPS metastases to both the skull and the brain. A and B : The T1-weighted-enhanced sagittal and axial images reveal an osteolytic mass lesion on the frontal bone. C : The T1-weighted-enhanced axial image reveals a well-enhanced lesion in deep white matter on the left frontal lobe. ASPS : alveolar soft part sarcoma.

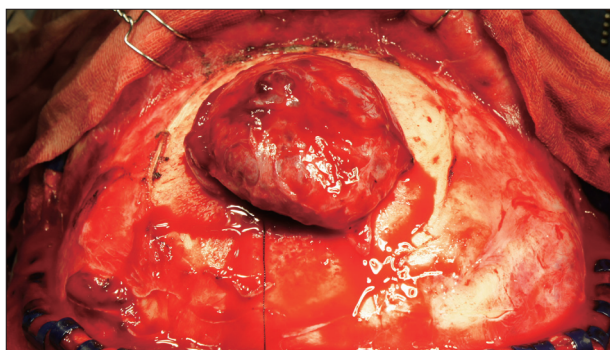


Fig. 2. Intra-operative photographs. Following subgaleal dissection, a well-circumscribed mass is found on the frontal bone.

separated with galeal tissue. Infiltration around the skull and dural involvement were evident, but mass did not involve brain parenchymal tissue. After the skull lesion and involved dura were totally resected grossly, duroplasty and cranioplasty were performed (Fig. 2). A histological examination of the specimens revealed large, round-to-polygonal tumor cells growing in the classical alveolar pattern, which was compatible with ASPS metastasis to the skull. Positive immunohistochemical staining of the fuses with transcription factor 3 (TFE3) antibody was noted (Fig. 3).

DISCUSSION

Sarcomas are a type of mesenchymal tumor with an incidence of 2 for every 100000 population per year, accounting for 0.7% of all cancer cases²⁰. Typically, sarcomas metastasize to the lungs and bones, and only 1-8% of cases leads to brain metastasis^{7,21,22}, thus the sarcomas account for less than 3% of all brain metastases at autopsy⁹. The incidence of brain metastasis from sarcoma has increased in recent years, owing to the advent of effective systemic chemotherapy regimens, which prolong patient survival.

Christopherson et al.⁴ described ASPS as a distinct tumor of uncertain histogenesis. This tumor primarily affects young adults, with an incidence peak at 15-35 years. It is also more common in women. Most ASPS cases have a primary site in the lower limbs and show right-sided laterality⁶. In children, the

primary site is in the head and the neck. Ronald et al.¹⁸ hypothesized that ASPSs arise from displaced paraganglionic mesoderm and have a close homology with paragangliomas of the carotid body type. A muscle origin is indicated^{12,13}. The most common metastases reported are those affecting the lungs (42%), bones (19%), brain (15%), and lymph nodes (7%)¹⁰. In another series, the incidence rate of brain metastases was reported to be 19%, and it was always cited in association with metastases to other sites¹⁷.

Histologically, the ASPS tumor should be distinguished from renal cell carcinoma, granular cell tumor, and paraganglioma. Histological features show alveolar clusters separated by thin-walled vascular channels. The cells are polygonal with vesicular nuclei containing a nucleolus and eosinophilic granulated cytoplasm, which exhibit a positive periodic acid-Schiff (PAS) reaction and crystalline-to-granular material. ASPS is characterized by a tumor-specific ASPL-TFE3 fusion protein, der(17)t(X;17)(p11;q25), that fuses the transcription factor 3 (TFE3) gene at Xp11 to the ASPL gene at 17q25, creating an ASPL-TFE3 fusion protein⁸. Recently, an antibody directed against the C-terminus of the TFE3 has emerged as a highly sensitive and specific marker of ASPS¹¹.

The treatment of metastatic sarcoma to the brain is complicated by the relative radioresistance and chemoresistance of sarcoma cells³. Thus, surgery is considered an important part of the management of this disease, and an appropriate plan of care should take into account the status of the patient's systemic disease, the overall neurological and clinical status of the patient, and the number, size, location, and histological and radiographic features of the patient's sarcomas.

Fox et al.⁷ reported a statistically significant increase in the survival rate of patients with ASPS histology (median survival of 27 months) when compared with all other sarcoma histologies (6.1 months). Previous case reports showed that surgically treated cases have a favorable outcome^{9,11}. Bindal et al.² recommended surgical excision of the intracranial metastases in patients who were not terminally ill and did not consider the involvement of the lungs as a contra-indication for surgery. They found that the five-year survival in these patients was better than the case with metastases from other sarcoma histologies. Radiotherapy is recommended after surgical excision because metastatic ASPS is resistant to conventional doxorubicin-based chemotherapy. However, in our case, adjuvant radiotherapy was not applicable due to preoperative radiation.

CONCLUSION

We report the very unusual case of ASPS metastatic to both

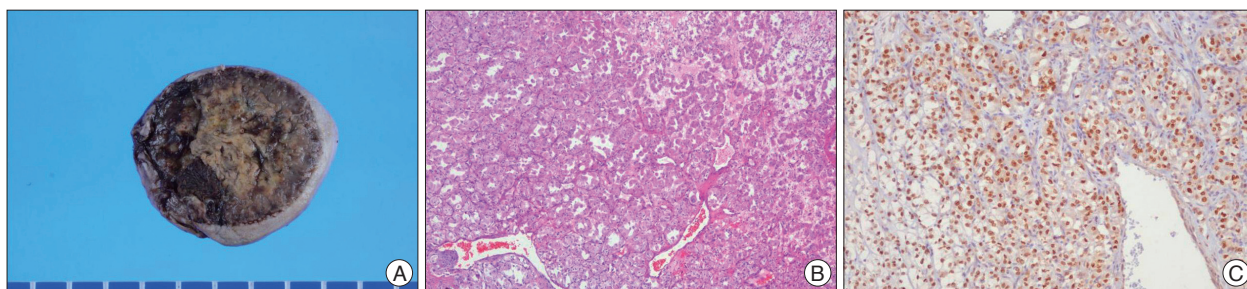


Fig. 3. A : The photograph shows the resected tumor mass with surrounding skull bone. B : The histological finding shows large, round to polygonal tumor cells growing in the classical alveolar pattern (H&E stain, $\times 100$). C : An ASPS showing uniform, strong nuclear positivity with an antibody directed against the C-terminus of transcription factor 3 (TFE3), confirming the presence of an ASPL-TFE3 fusion protein ($\times 100$). ASPS : alveolar soft part sarcoma.

the skull and the brain. The ideal management and the effective therapeutic strategy to adopt are still unclear. Total surgical resection may be effective in improving a patient's survival and in treating neurological conditions.

References

- Argani P, Lal P, Hutchinson B, Lui MY, Reuter VE, Ladanyi M : Aberrant nuclear immunoreactivity for TFE3 in neoplasms with TFE3 gene fusions : a sensitive and specific immunohistochemical assay. *Am J Surg Pathol* 27 : 750-761, 2003
- Bindal RK, Sawaya RE, Leavens ME, Taylor SH, Guinee VF : Sarcoma metastatic to the brain : results of surgical treatment. *Neurosurgery* 35 : 185-190; discussion 190-191, 1994
- Chang EL, Seleck U, Hassenbusch SJ 3rd, Maor MH, Allen PK, Mahajan A, et al. : Outcome variation among "radioresistant" brain metastases treated with stereotactic radiosurgery. *Neurosurgery* 56 : 936-945; discussion 936-945, 2005
- Christopherson WM, Foote FW Jr, Stewart FW : Alveolar soft-part sarcomas; structurally characteristic tumors of uncertain histogenesis. *Cancer* 5 : 100-111, 1952
- Evans HL : Alveolar soft-part sarcoma. A study of 13 typical examples and one with a histologically atypical component. *Cancer* 55 : 912-917, 1985
- Fassbender HG : [Alveolar myoblastic sarcoma of the skeletal musculature]. *Oncologia* 13 : 184-191, 1960
- Fox BD, Patel A, Suki D, Rao G : Surgical management of metastatic sarcoma to the brain. *J Neurosurg* 110 : 181-186, 2009
- Ladanyi M, Lui MY, Antonescu CR, Krause-Boehm A, Meindl A, Argani P, et al. : The der(17)t(X;17)(p11;q25) of human alveolar soft part sarcoma fuses the TFE3 transcription factor gene to ASPL, a novel gene at 17q25. *Oncogene* 20 : 48-57, 2001
- Lewis AJ : Sarcoma metastatic to the brain. *Cancer* 61 : 593-601, 1988
- Lieberman PH, Foote FW Jr, Stewart FW, Berg JW : Alveolar soft-part sarcoma. *JAMA* 198 : 1047-1051, 1966
- Lokich JJ : The management of cerebral metastasis. *JAMA* 234 : 748-751, 1975
- Miettinen M, Ekfors T : Alveolar soft part sarcoma. Immunohistochemical evidence for muscle cell differentiation. *Am J Clin Pathol* 93 : 32-38, 1990
- Mukai M, Torikata C, Iri H, Mikata A, Hanaoka H, Kato K, et al. : Histogenesis of alveolar soft part sarcoma. An immunohistochemical and biochemical study. *Am J Surg Pathol* 10 : 212-218, 1986
- Ogose A, Morita T, Hotta T, Kobayashi H, Otsuka H, Hirata Y, et al. : Brain metastases in musculoskeletal sarcomas. *Jpn J Clin Oncol* 29 : 245-247, 1999
- Okada K, Takeda F, Kawafuchi J, Suzuki Y : [Skull and cerebral metastases of alveolar soft-part sarcoma. A report of an autopsy case (author's transl)]. *No Shinkei Geka* 2 : 481-486, 1974
- Perry JR, Bilbao JM : Metastatic alveolar soft part sarcoma presenting as a dural-based cerebral mass. *Neurosurgery* 34 : 168-170, 1994
- Portera CA Jr, Ho V, Patel SR, Hunt KK, Feig BW, Respondek PM, et al. : Alveolar soft part sarcoma : clinical course and patterns of metastasis in 70 patients treated at a single institution. *Cancer* 91 : 585-591, 2001
- Ronald AW, David MB, Frederick HS, Adele TM : Histopathogenesis of Alveolar soft part sarcoma. *Cancer* 29 : 191-204, 1972
- Salvati M, Cervoni L, Caruso R, Gagliardi FM, Delfini R : Sarcoma metastatic to the brain : a series of 15 cases. *Surg Neurol* 49 : 441-444, 1998
- Salvati M, D'Elia A, Frati A, Santoro A : Sarcoma metastatic to the brain : a series of 35 cases and considerations from 27 years of experience. *J Neurooncol* 98 : 373-377, 2010
- Wróński M, Arbit E, Burt M, Perino G, Galicich JH, Brennan MF : Resection of brain metastases from sarcoma. *Ann Surg Oncol* 2 : 392-399, 1995
- Yoshida S, Morii K, Watanabe M, Saito T : Brain metastasis in patients with sarcoma : an analysis of histological subtypes, clinical characteristics, and outcomes. *Surg Neurol* 54 : 160-164, 2000