

Perforated midgut diverticulitis: Revisited

Milan Spasojevic, Jens Marius Naesgaard, Dejan Ignjatovic

Milan Spasojevic, Jens Marius Naesgaard, Dejan Ignjatovic, Department of Gastrointestinal Surgery, Vestfold Hospital, 3103 Tonsberg, Norway

Dejan Ignjatovic, Department of Digestive Surgery, Akershus University Hospital, University of Oslo, 1478 Lorenskog, Norway

Author contributions: Spasojevic M, Naesgaard JM and Ignjatovic D made substantial contributions to conception and design, drafted the article, and revised it critically for important intellectual content; Spasojevic M and Ignjatovic D performed the acquisition, analysis and interpretation of the data; and all authors approved the version to be published.

Correspondence to: Dejan Ignjatovic, MD, PhD, Department of Digestive Surgery, Akershus University Hospital, University of Oslo, 1478 Lorenskog, Norway. dejan.ignjatovic@ahus.no
Telephone: +47-6-7969895 Fax: +47-6-7969040

Received: June 9, 2011 Revised: May 13, 2012

Accepted: June 8, 2012

Published online: September 14, 2012

Abstract

AIM: To study and provide data on the evolution of medical procedures and outcomes of patients suffering from perforated midgut diverticulitis.

METHODS: Three data sources were used: the Medline and Google search engines were searched for case reports on one or more patients treated for perforated midgut diverticulitis (Meckel's diverticulitis excluded) that were published after 1995. The inclusion criterion was sufficient individual patient data in the article. Both indexed and non-indexed journals were used. Patients treated for perforated midgut diverticulitis at Vestfold Hospital were included in this group. Data on symptoms, laboratory and radiology results, treatment modalities, surgical access, procedures, complications and outcomes were collected. The Norwegian patient registry was searched to find patients operated upon for midgut diverticulitis from 1999 to 2007. The data collected were age, sex, mode of access, surgical procedure performed and number of patients per year. Historical controls were retrieved from an article published in 1995 containing pertinent individual patient data. Statistical analysis was done with SPSS software.

RESULTS: Group I : 106 patients (48 men) were found. Mean age was 72.2 ± 13.1 years (mean \pm SD). Age or sex had no impact on outcomes ($P = 0.057$ and $P = 0.771$, respectively). Preoperative assessment was plain radiography in 53.3% or computed tomography (CT) in 76.1%. Correct diagnosis was made in 77.1% with CT, 5.6% without ($P = 0.001$). Duration of symptoms before hospitalization was 3.6 d (range: 1-35 d), but longer duration was not associated with poor outcome ($P = 0.748$). Eighty-six point eight percent of patients underwent surgery, 92.4% of these through open access where 90.1% had bowel resection. Complications occurred in 19.2% of patients and 16.3% underwent reoperation. Distance from perforation to Treitz ligament was 41.7 ± 28.1 cm. At surgery, no peritonitis was found in 29.7% of patients, local peritonitis in 47.5%, and diffuse peritonitis in 22.8%. Peritonitis grade correlated with the reoperation rate ($r = 0.43$). Conservatively treated patients had similar hospital length of stay as operated patients (10.6 ± 8.3 d vs 10.7 ± 7.9 d, respectively). Age correlated with hospital stay ($r = 0.46$). No difference in outcomes for operated or nonoperated patients was found ($P = 0.814$). Group II : 113 patients (57 men). Mean age 67.6 ± 16.4 years (range: 21-96 years). Mean age for men was 61.3 ± 16.2 years, and 74.7 ± 12.5 years for women ($P = 0.001$). Number of procedures per year was 11.2 ± 0.9 , and bowel resection was performed in 82.3% of patients. Group III : 47 patients (21 men). Patient age was 65.4 ± 14.4 years. Mean age for men was 61.5 ± 17.3 years and 65.3 ± 14.4 years for women. Duration of symptoms before hospitalization was 6.9 d (range: 1-180 d). No patients had a preoperative diagnosis, 97.9% of patients underwent surgery, and 78.3% had multiple diverticula. Bowel resection was performed in 67.4% of patients, and suture closure in 32.6%. Mortality was 23.4%. There was no difference in length of history or its impact on survival between Groups I and III ($P = 0.241$ and $P = 0.198$, respectively). Resection was more often performed in Group I ($P = 0.01$). Mortality was higher in Group III ($P = 0.002$).

CONCLUSION: In cases with contained perforation, conservative treatment gives satisfactory results, laparoscopic

py with lavage and drainage can be attempted and continued with a conservative course.

© 2012 Baishideng. All rights reserved.

Key words: Intestinal; Small bowel; Jejunum; Ileum; Perforation; Diverticulitis; Conservative treatment

Peer reviewer: Naoki Ishii, MD, Department of Gastroenterology, St. Luke's International Hospital, 9-1 Akashi-cho, Chuo-ku, Tokyo 104-8560, Japan

Spasojevic M, Naesgaard JM, Ignjatovic D. Perforated midgut diverticulitis: Revisited. *World J Gastroenterol* 2012; 18(34): 4714-4720 Available from: URL: <http://www.wjgnet.com/1007-9327/full/v18/i34/4714.htm> DOI: <http://dx.doi.org/10.3748/wjg.v18.i34.4714>

INTRODUCTION

Perforated midgut diverticulitis is an uncommon, acquired condition that is only sporadically observed and treated in surgical departments^[1]. This could be the reason for the confusion that still exists when clinical manifestations, diagnosis and treatment options are concerned. The evidence at hand does not seem to be satisfactory to provide the answers needed. Furthermore, there are no data on the use of minimally invasive procedures in the treatment of perforated midgut diverticulitis. A previously published review by Chendrasekhar *et al*^[2] in 1995 provided individual patient data for all case reports previously published. This article was chosen to be the landmark for this study because of its extensive data, firm grasp of the problem up to 1995, prior to important developments in diagnostics and treatment.

The aim of this study is to provide new data on the evolution of medical procedures and outcomes in patients with perforated midgut diverticulitis based on individual patient data derived from published case reports, original data and the Norwegian patient registry.

MATERIALS AND METHODS

The data obtained in this study came from three different sources: (Group I) review of published case reports in the literature after 1995 combined with original data; (Group II) data from the Norwegian patient registry; and (Group III) case reports from the literature prior to 1995 as historical controls^[2].

Case reports and original data (Group I)

Search strategy: Two independent researchers with a medical degree performed the search. The Medline database (<http://www.ncbi.nlm.nih.gov/PubMed/>) was searched for articles published after 1995. An effort to incorporate all available articles not included in Medline was made through the use of the Google search engine (<http://www.google.com/>). The following key search strategy

was used: ("perforated" or "perforation") and [("jejunum" or "jejunal") or ("intestine, small") or ("intestine" and "small") or ("small intestine") or ("small" and "bowel") or ("small bowel")] and ("diverticulum" or "diverticulitis") for medline databases; and ("perforated" or "perforation") and [("jejunum" or "jejunal") or ("intestine" and "small") or ("small intestine" or "intestine") and ("bowel" or "small bowel")] and ("diverticulum" or "diverticulitis") not sigmoid for Google. References did not have to have abstracts. There were no restrictions by language or publication type. English, French, Spanish, Portuguese, Italian, German and the Scandinavian and Slavic languages were translated by the authors, while help was acquired for translations of Turkish and Korean. All references matching the search were identified and screened for retrieval. Duplicate references were removed by a manual search. The retrieved references were scanned by the authors independently.

Selection: The inclusion criterion was original articles or case reports with any study design including at least one patient undergoing any kind of treatment for perforated midgut diverticulitis (Meckel's diverticulitis excluded), containing pertinent individual patient data. Perforated midgut diverticulitis was defined either as histopathologically confirmed in the surgical specimen (operated patients) or where clear radiological evidence was provided in conservatively treated patients. This evidence was usually computed tomography (CT)-based (localized inflammation or thickened wall of the midgut with/without air bubbles, pseudotumor or abscess in the midgut mesentery), or confirmed with a small bowel series, and in some cases, through radiography with contrast medium after abscess drainage. The population selected were 18 years or older.

Data abstraction: Individual data for each patient included the following: age; sex; surgical procedure (if operated); access (laparoscopic/open/combined); number of diverticula (single/multiple); distance from the ligament of Treitz; diverticula in other segments of the gut (jejunum/ileum/colon); length of symptoms prior to hospitalization; fever; peripheral blood leucocytes and C-reactive protein (CRP) at admission; method of diagnosis; hospital stay; complications (general and surgical); reoperation; and outcome. Details of the intervention included any type of treatment (conservative or surgical). Surgical procedure was classified as resection, suture closure or exploration, laparoscopic or open. Other complications of midgut diverticulitis (bleeding, bacterial overgrowth) were not studied.

Vestfold hospital patient data: Patients treated at Vestfold hospital for perforated midgut diverticulitis from March 2008 to December 2010 were included in this series. All patients had an abdominal CT scan at hospitalization. Indication for surgery was made through the evaluation of abdominal tenderness, rebound tenderness, bowel sounds, blood work-up and CT scan. Antibiotics

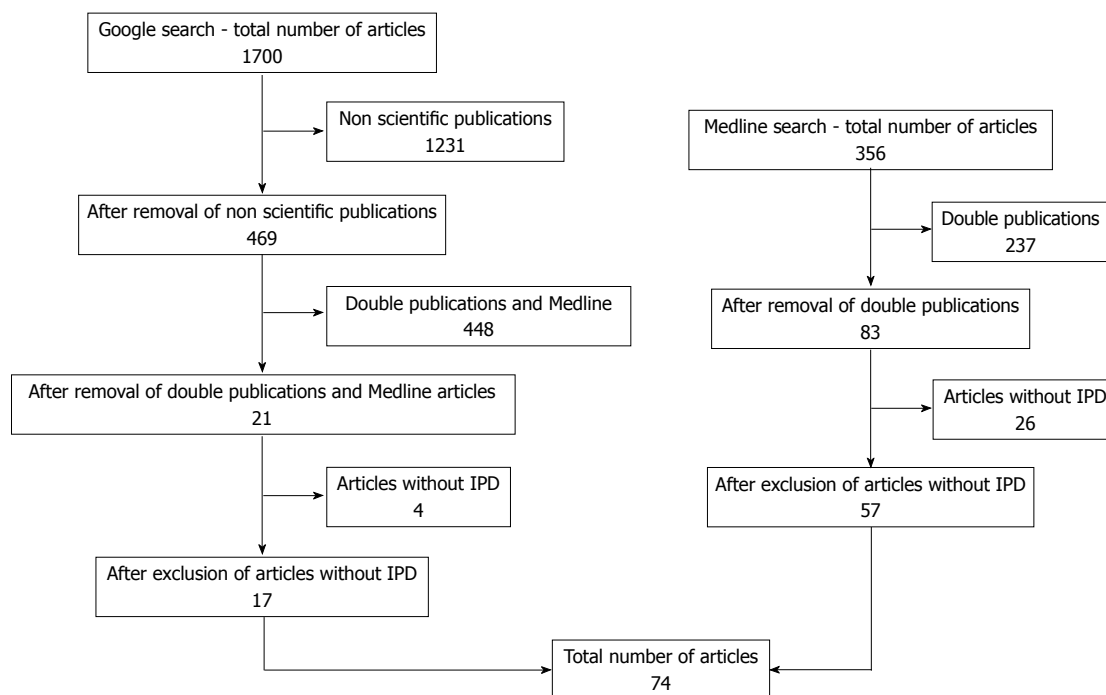


Figure 1 Schematic of the search strategy. IPD: individual patient data.

were administered. Patients who were operated upon had laparoscopy that confirmed the diagnosis, and thereafter a precisely placed minilaparotomy 4-5 cm in length, through which a limited small bowel resection and end-to-end hand-sewn anastomosis was performed. Further investigations (gastroscopy, colonoscopy and small bowel series) were done several weeks after the patient was discharged from the hospital.

Norwegian patient registry (Group II)

A comprehensive search of the Norwegian patient registry was performed. The time limit was from 1999 (introduction of the ICD-10 coding system in Norway) to 2007. The search criteria: K57.0 (midgut diverticulitis with perforation or abscess), K57.4 (small and large bowel diverticulitis with perforation or abscess), K57.8 (bowel diverticulitis, unspecified with perforation or abscess), Q43.0 (Meckel's diverticulum) excluded, crossed with JFB00 (small bowel resection), JFB01 (laparoscopic small bowel resection), JFA70 (enterorrhaphy), JFA71 (laparoscopic enterorrhaphy). Patients under the age of 18 years were excluded. The data requested were age, sex, mode of access, surgical procedure performed, and number of patients per year.

Historical controls (Group III)

The data on historical controls was retrieved from Chendrasekhar *et al*^[2]. Patients under the age of 18 years, and patients that did not have data on age were deleted and the remaining data were copied into the statistical software and used for further analysis.

Statistical analysis

Analysis was done using SPSS statistical software (Chica-

go, IL, United States). Distribution of data was checked with the Shapiro-Wilks test. Nonparametric values were compared using the χ^2 test and the Mann-Whitney test, while parametric values were compared using Student's *t* test. Correlations were tested with Spearman's test. The *P* values given were two sided, *P* < 0.05 was considered as the limit of significance.

RESULTS

Case reports and patients treated in Vestfold Hospital (Group I)

The search strategy (Figure 1) provided 356 articles from the Medline database, and 1700 documents were retrieved through the Google search engine. After manual removal of duplicate references, 104 articles were retrieved. Thirty of these did not contain pertinent patient data and were, therefore, excluded. The end result was 74 articles with 103 case reports containing detailed and pertinent individual patient data mostly retrieved through Medline^[3-59], while 22.9% of these came from Google alone^[60-76]. The individual patient data collected from the three patients treated for perforated midgut diverticulitis at Vestfold Hospital were added to this group, making a total of 106 patients (48 men and 58 women). The mean age of the group was 72.2 ± 13.1 years, and the age distribution was not normal (*P* = 0.001). The mean age for men was 73.7 ± 12.2 years and the mean age for women was 71.1 ± 13.8 years, with non-normal distribution for both sexes, *P* = 0.005 and *P* = 0.001, respectively. Sex distribution according to age was not significantly different in this group (*P* = 0.296). Patient age or sex did not have an impact on outcome (*P* = 0.057 and *P* = 0.771, respectively).

Preoperative assessment was described as plain radi-

Table 1 Overview of complications in Group I (case reports)

Complications	Frequency	Present
General ¹	5	4.7
Surgical ²	8	7.5
Both	3	2.9
None	59	55.7
Not available	31	29.2
Total	106	100

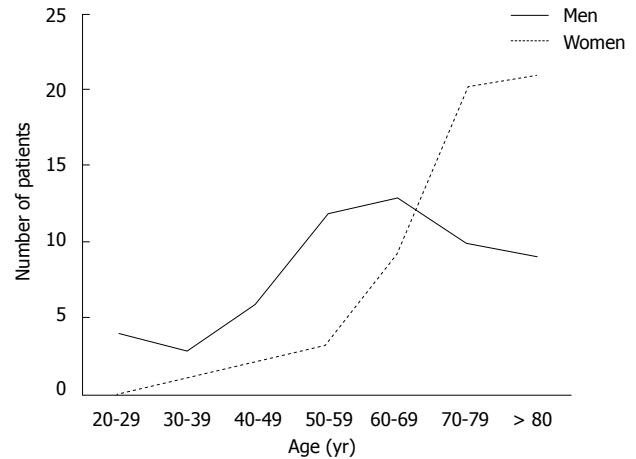
¹Acute myocardial infarction, pulmonary embolism, pneumonia, deep vein thrombosis, urinary tract infection and stroke; ²wound infection/delirium, anastomotic leakage, small bowel obstruction, intra-abdominal abscess and incisional hernia.

ography in 49 patients (53.3%) or CT in 70 (76.1%) in a total of 92 (86.8%) patients. Case reports did not include preoperative assessment in 14 (13.2%) patients. Where CT was performed, the correct preoperative diagnosis was made in 54 (77.1%) patients, while the probability of detecting perforated midgut diverticulitis without CT was 5.6% (two patients), both patients were previously known to have midgut diverticulosis. The difference in diagnosis with/without CT was statistically significant ($P = 0.001$).

Data on the duration of symptoms prior to hospitalization were present for 88 (83.0%) patients. The mean duration of symptoms prior to hospitalization was 3.6 d (range: 1-35 d). A longer duration of symptoms did not result in a poor outcome ($P = 0.748$). Data on fever were listed in 49 (46.2%) patients. Patients most often presented with moderate fever 23 (46.9%), while no fever or high fever was present in 26.5% each. Leukocyte and CRP levels were $13.8 \pm 3.6 \times 10^9/L$ and 155.4 ± 100.6 mg/L, respectively. Ninety-two (86.8%) patients underwent surgery, and 14 (13.2%) received conservative treatment. The surgical procedure most often performed was small bowel resection (83, 90.1%), followed by suture closure (5, 5.5%). Two patients (2.2%) underwent complex procedures that included multiple resections and 2 (2.2%) underwent surgical exploration with drainage. Access was through open surgery in 85 (92.4%) patients, while laparoscopic access was chosen in 5 (5.5%) and converted in 3 (60%). Two procedures (2.2%) were completed through laparoscopy. Data on postoperative complications were accessible in 73 patients. Complications occurred in 19.2% (Table 1). Fifteen (16.3%) patients underwent reoperation.

The operative report contained data on the distance of the perforated diverticulum to the ligament of Treitz in 29 patients, setting the mean distance to 41.7 ± 28.1 cm (range: 4-110 cm). Data on peritonitis was missing in five (4.7%) patients. There was no peritonitis or abscess in 30 (29.7%) patients, local peritonitis was present in 48 (47.5%), and 23 (22.8%) had diffuse peritonitis. Two (2.0%) patients had a mesenteric abscess. A reasonable correlation between the grade of peritonitis and reoperation rate was noted ($r = 0.43$, Spearman's test).

Seventeen (16.8%) patients had a solitary midgut diverticulum. Multiple jejunal diverticula were noted in 84 (83.2%) patients, while no data were provided for 5 (4.7%).

**Figure 2** Correlation between sex and age for patients in the Norwegian patient registry.

Data on location and number of diverticula throughout the digestive tube were listed for 46 (43.4%) patients. Concomitant ileal diverticulosis was found in 18 (39.1%), while 31 (67.4%) had colon diverticulosis. In all, 21 (45.6%) patients had diverticulosis throughout the intestinal tract.

Mean hospital stay was 10.7 ± 7.9 d. Conservatively treated patients did not have a longer hospital stay than operated patients (10.6 ± 8.3 d *vs* 10.7 ± 7.9 d, respectively). Reoperated patients had a longer hospital stay 13.6 ± 8.4 d. There was a reasonable correlation between patient age and length of hospital stay ($r = 0.46$). Overall mortality was 5.7%. There was no statistically significant difference in outcomes for operated or nonoperated patients ($P = 0.814$).

Norwegian patient registry (Group II)

The analysis of the Norwegian patient registry provided data on 113 patients, 57 men and 56 women. Patient mean age was 67.6 ± 16.4 years (range: 21-96 years). The age distribution within this group was not normal ($P = 0.04$). Mean age for men was 61.3 ± 16.2 years, while that for women was 74.7 ± 12.5 years, with non-normal distribution for both sexes, $P = 0.027$ and $P = 0.013$, respectively. The difference in age between the sexes was highly significant ($P = 0.001$) (Figure 2). The mean frequency of surgical procedures per year was 11.2 ± 0.9 . The procedures most often performed were small bowel resection in 93 (82.3%) patients and enterorrhaphy in 17 (15%). Equivalent procedures performed through laparoscopic access were performed in 2 (1.8%) and 1 (0.9%) patients, respectively.

Historical controls (Group III)

After the exclusion of patients under the age of 18 years, the group consisted of 47 patients (21 men and 26 women). Patient mean age was 65.4 ± 14.4 years. The age distribution within this group was normal ($P = 0.18$). Mean age for men was 61.5 ± 17.3 years, while that for women was 65.3 ± 14.4 years, with normal distribution for both sexes, $P = 0.29$ and $P = 0.76$, respectively.

Duration of symptoms prior to hospitalization was 6.9 d (range: 1-180 d). No patients had a preoperative diagnosis. Only one (2.1%) patient was treated conservatively, while the remaining 46 (97.9%) underwent surgery. Peroperative data were available for 24 (51.1%) patients, and cited as perforation in all, without grade of peritonitis. Twenty-three (48.9%) patients had data on number of diverticula, 18 (78.3%) had multiple and 5 (21.7%) had solitary diverticula. Small bowel resection was performed in 31 (67.4%) patients and suture closure in 15 (32.6%). Mortality in this group was 23.4%.

Comparison between patient groups

When length of history was concerned there was no difference between Groups I and III ($P = 0.241$). Furthermore, there was no impact of length of history on survival between Groups I and III ($P = 0.198$). No significant difference was detected in outcomes of conservative and surgical treatment ($P = 0.23$). However, there was a significant difference noted for type of surgical procedure, in favor of resection in Group I compared to Group III ($P = 0.01$), as well as the number of diverticula ($P = 0.001$). Mortality was significantly higher in Group III compared to Group I ($P = 0.002$).

DISCUSSION

One of the objective difficulties that a researcher encounters when investigating rare conditions is the absence of evidence and data. Data from the Norwegian patient registry show that a trial on a national level would prove to be difficult, including at most 10 patients per year. In these circumstances, one chooses the next best solution, reanalysis of small case series or case reports that contain sufficient individual patient data. A tendency to not publish case reports or small case series in indexed journals is noted, making this task even more demanding, hence, the contribution of the Google search engine in locating almost 20% of these case reports. We are well aware of the shortcomings of such a study; however, the use of abductive, probabilistic reasoning^[77] allows for some valuable conclusions to be drawn.

The main finding of the present study is a transition in treatment, diagnosis and outcomes of patients suffering from perforated midgut diverticulitis. There seems to be a shift towards conservative treatment when properly diagnosed, a much higher percentage of accurate diagnosis, and small bowel resection is usually performed with lower mortality rates. This implies that elderly patients suffering from acute abdominal symptoms with elevated infection parameters should undergo a CT scan. Hence, the surgeon should have a high level of suspicion that the patient is suffering from perforated midgut diverticulitis after the initial CT scan is performed. Moreover, it seems that a substantial number of patients that could have been treated conservatively underwent surgery, because the majority of operated patients suffered from contained perforation. Surgical treatment should be avoided not only because of the burden of age and comorbidity

in this patient group, but rather to avoid the risk of extensive resection in patients with multiple diverticula^[1,2,78]. The fact that laparoscopy was so seldom used is even more surprising, because laparoscopic exploration and evaluation do not represent advanced minimally invasive surgical procedures.

The present study provides an opportunity to recommend the intensive use of laparoscopic exploration and evaluation in the emergency surgical setting. Nowadays, it seems that laparoscopic exploration provides at least as useful evaluation of abdominal pathology as open surgery does. Apart from the obvious benefits, laparoscopic exploration allows us to abandon the abdomen after lavage and drainage, and continue a conservative course^[79]. A heavy proximal (within 1 m from the Treitz ligament) midgut mesentery with fibrin deposits is typical for the condition, and if generalized peritonitis is not present, our results seem to show that a conservative approach is feasible. The rationale is the fact that length of history prior to surgery does not seem to affect treatment outcome; there was no increase in mortality or morbidity between the groups. Even length of hospital stay was equal between patients operated upon and those conservatively treated. On the other hand, generalized peritonitis had a significant correlation with length of hospitalization and mortality, and should be treated surgically. The affected loop can be exteriorized through a mini-laparotomy after laparoscopic mobilization, and limited resection performed. Suture closure does not seem to have a place in the treatment of perforated midgut diverticulitis.

Such an approach would minimize the frequency of midgut resections in this high-risk population, while allowing the correct choice of patients for conservative treatment. A similar approach has recently had an impact on the treatment of sigmoid diverticulitis. Laparoscopic lavage and drainage have been advocated for generalized peritonitis due to perforated sigmoid diverticulitis. In this study, only 8% of patients underwent conversion and surgical resection, while the vast majority were handled conservatively after lavage and drainage^[79].

It seems that correct diagnosis, together with the recognition of the immunological and physiological advantages of minimally invasive surgery, modern antibiotics and critical care could contribute to even better outcomes.

In summary, technological developments have led to better diagnosis of patients with perforated midgut diverticulitis. However, these have as yet not been applied in the operating room, where open surgery is still dominant over laparoscopy. When properly diagnosed, a transition in treatment is noticed towards conservative treatment. Only generalized peritonitis seems to have a significant correlation with length of hospitalization and mortality, and should be treated surgically. In these patients, laparoscopy and small bowel resection should be performed.

COMMENTS

Background

Perforated midgut diverticulitis is an uncommon, acquired condition that is only

sporadically observed and treated in surgical departments. Most of the literature consists of case reports, and this could be the reason for the confusion that still exists when clinical manifestations, diagnosis and treatment options are concerned. In addition, developments in surgery, radiology and other branches of medicine have occurred since the last review that has changed both surgical and conservative treatment.

Research frontiers

As demonstrated in the results this is a condition occurring in the elderly, and therefore has its challenges in choice of conservative treatment over surgical in the individual patient. Minimally invasive surgery would seem to have a place in this setting as well as the development of innovative surgical techniques to tackle this specific setting.

Innovations and breakthroughs

A transition to conservative treatment due to a correct preoperative diagnosis is apparent. Laparotomy continues to be dominant and the use of minimally access surgery is negligible. Small bowel resection is most often performed; suture closure is abandoned.

Applications

All elderly patients presenting with fever, infection and abdominal pain should have a computed tomography (CT) scan at admission. Surgery should be considered only in cases with generalized peritonitis. Conservative treatment should have a main role in treatment. Innovative minimally invasive procedures are required.

Terminology

Midgut is a segment of bowel that extends from the apex of the duodenal loop to the last third of the transverse colon. The midgut is supplied with blood by the superior mesenteric artery and innervated by the vagus nerve.

Peer review

The paper described a transition in diagnosis, treatment (a shift toward conservative treatment when properly diagnosed with CT), and outcomes (lower mortality rates) of patients suffering from perforated midgut diverticulitis. This topic will be of interest to WJG readers.

REFERENCES

- 1 Tsiotos GG, Farnell MB, Ilstrup DM. Nonmeckelian jejunal or ileal diverticulosis: an analysis of 112 cases. *Surgery* 1994; **116**: 726-731; discussion 731-732
- 2 Chendrasekhar A, Timberlake GA. Perforated jejunal diverticula: an analysis of reported cases. *Am Surg* 1995; **61**: 984-988
- 3 Rosing MA, Amory S. Perforated ileal diverticulitis. An atypical presentation with definitive diagnosis by laparoscopy. *Surg Endosc* 1995; **9**: 522-524
- 4 Koger KE, Shatney CH, Dirbas FM, McClenathan JH. Perforated jejunal diverticula. *Am Surg* 1996; **62**: 26-29
- 5 Alvarez OA, Mejia A, Ostrower VS, Lee M. Jejunal diverticulitis manifesting with abdominal wall abscess. *Am J Gastroenterol* 1995; **90**: 2060-2062
- 6 Costa G, Mancini R, Di Castro A, Capaldi M, Sciacca P, Ialongo P. [Perforated jejunal diverticulum: a rare cause of acute abdomen]. *Chir Ital* 2005; **57**: 521-525
- 7 Benini B, Scocchera F, Giorgiano F, Manfroni S, Cataldi C, Antonellis D. [Perforated jejunal diverticulitis: A case report]. *Chir Ital* 2008; **60**: 745-748
- 8 Albu E, Parikh V, Alankar S, Gerst PH. Perforated solitary jejunal diverticulum. *South Med J* 1995; **88**: 575-576
- 9 Kleemann M, Kujath P, Stellmacher F, Gellissen J, Bruch HP, Eckmann Ch. [Perforated jejunal divertikula - a rare differential diagnosis of acute abdominal pain]. *Zentralbl Chir* 2006; **131**: 521-524
- 10 De Peuter B, Box I, Vanheste R, Dymarkowski S. Small-bowel diverticulosis: imaging findings and review of three cases. *Gastroenterol Res Pract* 2009; **2009**: 549853
- 11 Veen M, Hornstra BJ, Clemens CH, Stigter H, Vree R. Small bowel diverticulitis as a cause of acute abdomen. *Eur J Gastroenterol Hepatol* 2009; **21**: 123-125
- 12 Quiles AM, Rodríguez-Hermosa JI, Ortiz MR, Febrer M. [Perforated jejunal diverticulitis]. *Gastroenterol Hepatol* 2006; **29**: 432-433
- 13 Gotian A, Katz S. Jejunal diverticulitis with localized perforation and intramesenteric abscess. *Am J Gastroenterol* 1998; **93**: 1173-1175
- 14 Kirbaş I, Yildirim E, Harman A, Başaran O. Perforated ileal diverticulitis: CT findings. *Diagn Interv Radiol* 2007; **13**: 188-189
- 15 Sakurai Y, Tonomura S, Yoshida I, Masui T, Shoji M, Nakamura Y, Matsubara T, Uyama I, Komori Y, Ochiai M. Abdominal wall abscess associated with perforated jejunal diverticulitis: report of a case. *Surg Today* 2005; **35**: 682-686
- 16 Yağmur Y, Aldemir M, Büyükbayram H, Taçyıldız I. Multiple jejunal diverticulitis with perforation in a patient with systemic lupus erythematosus: report of a case. *Surg Today* 2004; **34**: 163-166
- 17 Eriguchi N, Aoyagi S, Nakayama T, Emi Y, Saku M, Yoshida K. Ileo-abdominal wall fistula caused by diverticulum of the ileum. *J Gastroenterol* 1998; **33**: 272-275
- 18 Klee FE, Osswald BR, Wysocki S. Severe abdominal pain and thrombocytopenia—typical symptoms of occult jejunal diverticulum perforation? *J Gastroenterol* 1997; **32**: 246-250
- 19 Habib NA, Enslin RC. Perforated jejunal diverticula. *Br J Clin Pract* 1984; **38**: 431, 433
- 20 Kubota T. Perforated jejunal diverticulitis. *Am J Surg* 2007; **193**: 486-487
- 21 Fass G, Colonval P. Perforation and abscess formation of a solitary jejunal diverticulum. *Acta Chir Belg* 2007; **107**: 222-224
- 22 Tankova L, Berberova M, Purvanov P, Tsankov Ts, Gegova A. Complicated small bowel diverticulosis—a case report and literature review. *Chirurgia (Bucur)* 2007; **102**: 603-606
- 23 Abboud B, Aouad R, Jaoude JB, Ghorra C. [A rare cause of acute abdomen: jejunal diverticulitis]. *Presse Med* 2008; **37**: 416-419
- 24 Iannelli A, Piche T, Novellas S, Gugenheim J. Small bowel diverticulitis of the Roux loop after gastric bypass. *Obes Surg* 2006; **16**: 1249-1251
- 25 Schock J, Mainster H. Perforation of acquired small bowel diverticulum. *J Am Osteopath Assoc* 1999; **99**: 113-115
- 26 Buis CI, Hofker HS, Nieuwenhuijs VB. Diverticulitis of the jejunum, an uncommon diagnosis. *Dig Surg* 2008; **25**: 83-84
- 27 Kassahun WT, Fangmann J, Harms J, Bartels M, Hauss J. Complicated small-bowel diverticulosis: a case report and review of the literature. *World J Gastroenterol* 2007; **13**: 2240-2242
- 28 Sibille A, Willocx R. Jejunal diverticulitis. *Am J Gastroenterol* 1992; **87**: 655-658
- 29 Cross MJ, Snyder SK. Laparoscopic-directed small bowel resection for jejunal diverticulitis with perforation. *J Laparoscopic Surg* 1993; **3**: 47-49
- 30 Morgenstern L. Acute diverticulitis of the jejunum; report of two cases. *Calif Med* 1954; **80**: 403-404
- 31 Donald JW. Major complications of small bowel diverticula. *Ann Surg* 1979; **190**: 183-188
- 32 Greenstein S, Jones B, Fishman EK, Cameron JL, Siegelman SS. Small-bowel diverticulitis: CT findings. *AJR Am J Roentgenol* 1986; **147**: 271-274
- 33 Novak JS, Tobias J, Barkin JS. Nonsurgical management of acute jejunal diverticulitis: a review. *Am J Gastroenterol* 1997; **92**: 1929-1931
- 34 McCourtney JS, Karim S, Rahilly M, Dalling R. Fatal complication of coincidental operative finding. *Postgrad Med J* 1999; **75**: 625-627
- 35 Fang M, Agha S, Lee R, Culpepper-Morgan J, D'Souza A. Perforation of jejunal diverticulum: case report and review of literature. *Conn Med* 2000; **64**: 7-10
- 36 Zager JS, Garbus JE, Shaw JP, Cohen MG, Garber SM. Jejunal diverticulosis: a rare entity with multiple presentations, a series of cases. *Dig Surg* 2000; **17**: 643-645
- 37 Matteoni R, Lolli E, Barbieri A, D'Ambrosi M. Perforated jejunal diverticulitis: personal experience and diagnostic with

- therapeutical considerations. *Ann Ital Chir* 2000; **71**: 95-98
- 38 **Franzen D**, Gürtler T, Metzger U. [Multiple recurrent perforated jejunal diverticulitis]. *Chirurg* 2002; **73**: 1218-1220
- 39 **Cunningham SC**, Gannon CJ, Napolitano LM. Small-bowel diverticulosis. *Am J Surg* 2005; **190**: 37-38
- 40 **Lempinen M**, Salmela K, Kemppainen E. Jejunal diverticulosis: a potentially dangerous entity. *Scand J Gastroenterol* 2004; **39**: 905-909
- 41 **García LJ**, Otero J, Santamaría L, Pérez A. [Jejunal diverticulitis. A rare cause of acute abdomen]. *Cir Esp* 2005; **77**: 357-358
- 42 **Al-Samarrai AY**. Perforation of jejunal diverticulum. *Saudi J Gastroenterol* 2002; **8**: 62-63
- 43 **Aksoy F**, Demirel C, Bilgiç T, Güngör IG, Özçelik A. A previously diagnosed mitochondrial neurogastrointestinal encephalomyopathy patient presenting with perforated ileal diverticulitis. *Turk J Gastroenterol* 2005; **16**: 228-231
- 44 **Ahlman H**, Björck S, Jonsson O, Gamklou R. Perforated jejunal diverticula. Report on two cases. *Acta Chir Scand* 1980; **146**: 79-80
- 45 **Priestley J**, Patiniotis T. Gram-negative sepsis as a presentation of jejunal diverticular disease. *ANZ J Surg* 2004; **74**: 701
- 46 **De Raet J**, Brugman T, Geukens A. Non-Meckel's ileal diverticulitis with perforation: a rare cause of acute right lower quadrant pain. *Acta Chir Belg* 2010; **110**: 90-92
- 47 **Slaninka I**, Páral J, Chobola M, Motycka V, Ferko A, Bláha V. [Peritonitides caused by gastrointestinal perforations--analysis of an elderly patient group]. *Rozhl Chir* 2009; **88**: 656-661
- 48 **Basile G**, Buffone A, Boscarelli G, Maria S, Santagati G, Corsaro A, Cirino E. [Perforated jejunal diverticulum. A case report]. *Ann Ital Chir* 2008; **79**: 53-56
- 49 **Papaziogas B**, Koutelidakis J, Dragoumis D, Atmatzidis S, Giakoustidis A, Atmatzidis K. Perforated jejunal diverticulum presenting as acute abdomen. *Chirurgia (Bucur)* 2010; **105**: 119-121
- 50 **Graña L**, Pedraja I, Mendez R, Rodríguez R. Jejuno-ileal diverticulitis with localized perforation: CT and US findings. *Eur J Radiol* 2009; **71**: 318-323
- 51 **Prost A La Denise J**, Douard R, Berger A, Cugnenc PH. Small bowel diverticulosis complicated by perforated jejunal diverticula: conservative and/or surgical management? *Hepatogastroenterology* 2008; **55**: 1657-1659
- 52 **Jarral OA**, Purkayastha S, Darzi A, Zacharakis E. Education and Imaging. Gastrointestinal: Enterolith-induced perforation on a background of jejunal diverticulum. *J Gastroenterol Hepatol* 2010; **25**: 429
- 53 **França M**, Certo M, Silva D, Peixoto C, Varzim P. Elderly patient with acute, left lower abdominal pain: perforated jejunal diverticulitis (2010: 7b). *Eur Radiol* 2010; **20**: 2541-2545
- 54 **Lacz NL**, Zurlo JV. Small bowel diverticulitis: an often overlooked cause of acute abdomen. *Emerg Radiol* 2010; **17**: 497-501
- 55 **Colvin HS**, Kuenfoo C, Rajab TK, Sayadatas T. Non-surgical management of recurrent perforation of a jejunal diverticulum following previous segmental bowel resection: a case report. *J Med Case Rep* 2009; **3**: 7318
- 56 **Reeve K**, Hotouras A, Manghat M, Pillai S. Catheter balloon mimicking incarcerated femoral hernia and co-existing small bowel diverticular perforation: a case report. *Cases J* 2009; **2**: 8755
- 57 **Patel VA**, Jefferis H, Spiegelberg B, Iqbal Q, Prabhudesai A, Harris S. Jejunal diverticulosis is not always a silent spectator: a report of 4 cases and review of the literature. *World J Gastroenterol* 2008; **14**: 5916-5919
- 58 **Staszewicz W**, Christodoulou M, Proietti S, Demartines N. Acute ulcerative jejunal diverticulitis: case report of an uncommon entity. *World J Gastroenterol* 2008; **14**: 6265-6267
- 59 **Butler JS**, Collins CG, McEntee GP. Perforated jejunal diverticula: a case report. *J Med Case Rep* 2010; **4**: 172
- 60 **Juchems MS**, Brams HJ, Pauls S. Small bowel diverticulitis. *European J of Rad Extra* 2006; **59**: 119-121
- 61 **Kim KH**, Kim JH, Her MY, Lee SH, Paik BL, Jee SR, Park ET, Seol SY, Chung JM. A case of ileal diverticulitis causing small bowel stenosis. *Korean J Gastrointest Endosc* 2004; **28**: 193-196
- 62 **Choi JW**, Kim KH, Lee JE, Kim JH, Jang BI. A case of jejunal diverticulitis with perforation combined with intussusception caused by inflammatory fibroid polyp. *Yeungnam Univ J Med* 2005; **22**: 113-118
- 63 **Perea García J**, Turégano Fuentes F, Pérez Díaz MD, Sanz Sánchez M. Diverticulitis De Yeyuno Perforada. *Gastroenterol Hepatol* 2002; **25**: 526-527
- 64 **Koyuncu A**, Turan M, Sozeri S, Kivanc F, Gokgoz S. Perforated jejunal diverticulum: A case report. *Çukurova Üniversitesi Tıp Fakültesi Dergisi* 2002; **25**: 35-37
- 65 **Goshtasby P**, Tiruchelvam V, Nicholson T. Perforated Jejunal Diverticulitis. *Surgical Rounds* 2006; **29**: 361-364
- 66 **Cegla J**, Chudasama P, Agarwal T, Chaudhary S. A perforated Jejunal Diverticulum. *Grand Rounds* 2007; **7**: 5-8
- 67 **Das DN**, Walia J, Gone SR, Scobie DJ. Surgical options in proximal jejunal diverticulum perforation and review of literature. *SMJ* 2007; **52**: 53
- 68 **Woods AQ**, Ly JQ, Binstock A, Beall DP. Radiological case: Jejunal diverticulitis. *Appl Radiol* 2008; **37**: 7
- 69 **Stout CL**, Moore AB, Woodyard T. Emergency medicine quiz: Can you diagnose the cause of this patient's abdominal pain? *RSP* 2008. Available from: URL: http://www.hcplive.com/publications/Resident-and-Staff/2008/2008-WW/2008-06_W1
- 70 **Pelaez MC**, Rodriguez FR, Tato G, Quintela A. Perforated Jejunal Diverticulitis. *Publicado en Cir Esp* 2001; **69**: 627-628
- 71 **Lee BG**, Park SB, Byun CG, Koh YT, Suh DY, Park DS, Kang MJ, Lee KJ. Localized peritonitis due to perforation of multiple jejunal diverticula. *J Korean Surg Soc* 2004; **67**: 75-78
- 72 **Siyamek NM**, Terlizzi J, Mills C, Steele J. Jejunal diverticulitis masked by subhepatic collection. *Internet J Surg* 2009; **19**: 9
- 73 **Ozdemir A**, Ulas M, Karaman K, Teke Z, Ozer I, Ercan M, Ozogul YB, Seven, MC. Acute abdomen caused by a jejuna diverticulum perforation: A rare clinical entity. *Anatol J Clin Investig* 2010; **4**: 168-170
- 74 **Eisold S**, Guenther KH, Reith HB. Diverticulitis of the small bowel. *Pol Przegl Chir* 2007; **79**: 385-388
- 75 **Mortimer A**, Harding J, Roach H, Callaway M, Virjee J. Jejunal diverticulitis: an unusual cause of an intra-abdominal abscess - coronal Computed Tomography reconstruction can aid the diagnosis. *J Radiol Case Rep* 2008; **2**: 15-18
- 76 **Tilakaratne S**, Coomaraswamy W, Ratnapala SD. A rare case of jejunal diverticulitis. *Galle Medical Journal* 2009; **14**: 79-80
- 77 **Haig BD**. Scientific method, abduction, and clinical reasoning. *J Clin Psychol* 2008; **64**: 1013-1018
- 78 **Vallicelli C**, Coccolini F, Catena F, Ansaloni L, Montori G, Di Saverio S, Pinna AD. Small bowel emergency surgery: literature's review. *World J Emerg Surg* 2011; **6**: 1
- 79 **Myers E**, Hurley M, O'Sullivan GC, Kavanagh D, Wilson I, Winter DC. Laparoscopic peritoneal lavage for generalized peritonitis due to perforated diverticulitis. *Br J Surg* 2008; **95**: 97-101

S- Editor Cheng JX L- Editor Kerr C E- Editor Xiong L