

# A Case of Severe Coronary Spasm Associated with 5-Fluorouracil Chemotherapy

Sang-Min Kim<sup>1</sup>, Cheol-Hoon Kwak<sup>1</sup>, Bora Lee<sup>1</sup>, Seong Beom Kim<sup>1</sup>, Jung-Ju Sir<sup>2</sup>, Wook-Hyun Cho<sup>1</sup>, and Suk-Koo Choi<sup>1</sup>

<sup>1</sup>Department of Internal Medicine, Cardiovascular Center, Inje University Seoul Paik Hospital; <sup>2</sup>Department of Internal Medicine, Cardiovascular Center, National Medical Center, Seoul, Korea

Cardiotoxicity associated with 5-fluorouracil (FU) is an uncommon, but potentially lethal, condition. The case of an 83-year-old man with colon cancer who developed chest pain during 5-FU infusion is presented. The electrocardiogram (ECG) showed pronounced ST elevation in the lateral leads, and the chest pain was resolved after infusion of nitroglycerin. A coronary angiogram (CAG) revealed that the patient had significant atherosclerosis in the proximal left circumflex artery. Coronary artery spasm with fixed stenosis was considered, and a drug-eluting stent was implanted. After 8 hours, the patient complained of recurring chest pain, paralleled by ST elevation on the ECG. The chest pain subsided after administration of intravenous nitroglycerin followed by sublingual nifedipine. Repeated CAG showed patency of the previous stent. This case supports the vasospastic hypothesis of 5-FU cardiac toxicity, indicating that a calcium channel blocker may be effective in the prevention or treatment of 5-FU cardiotoxicity.

**Keywords:** Fluorouracil; Coronary vasospasm; Calcium channel blockers; Angina pectoris

## INTRODUCTION

The antimetabolite 5-fluorouracil (FU) is widely used in the treatment of solid tumors, including gastrointestinal, breast, head, and neck cancers. Cardiotoxicity, a rare adverse effect of 5-FU, has a reported incidence of 1.2% to 18% [1,2]. The pathogenesis of 5-FU cardiotoxicity is unclear. The prevalent hypothesis suggests that 5-FU induces coronary vasospasm [1]. We report here a case of 5-FU cardiotoxicity. The patient presented with typical angina and electrocardiographic changes suggestive of an ischemic coronary event during the continuous infusion of 5-FU. The ischemia recurred when the infusion was stopped, and was relieved by administration of

nitroglycerin followed by a sublingual calcium channel blocker.

## CASE REPORT

An 83-year-old man who had been diagnosed with stage III<sub>c</sub> (T<sub>4</sub>N<sub>2</sub>M<sub>0</sub>) adenocarcinoma of the ascending colon and who had undergone a right hemicolectomy was admitted to Inje University Seoul Paik Hospital to begin adjuvant chemotherapy, using the FOLFOX4 regimen (400 mg/m<sup>2</sup> 5-FU bolus infusion followed by the continuous infusion of 600 mg/m<sup>2</sup> 5-FU for 22 hours on days 1 and 2; 200 mg/m<sup>2</sup> leucovorin as a continuous infusion for 2 hours

**Received :** March 22, 2008

**Revised :** June 16, 2008

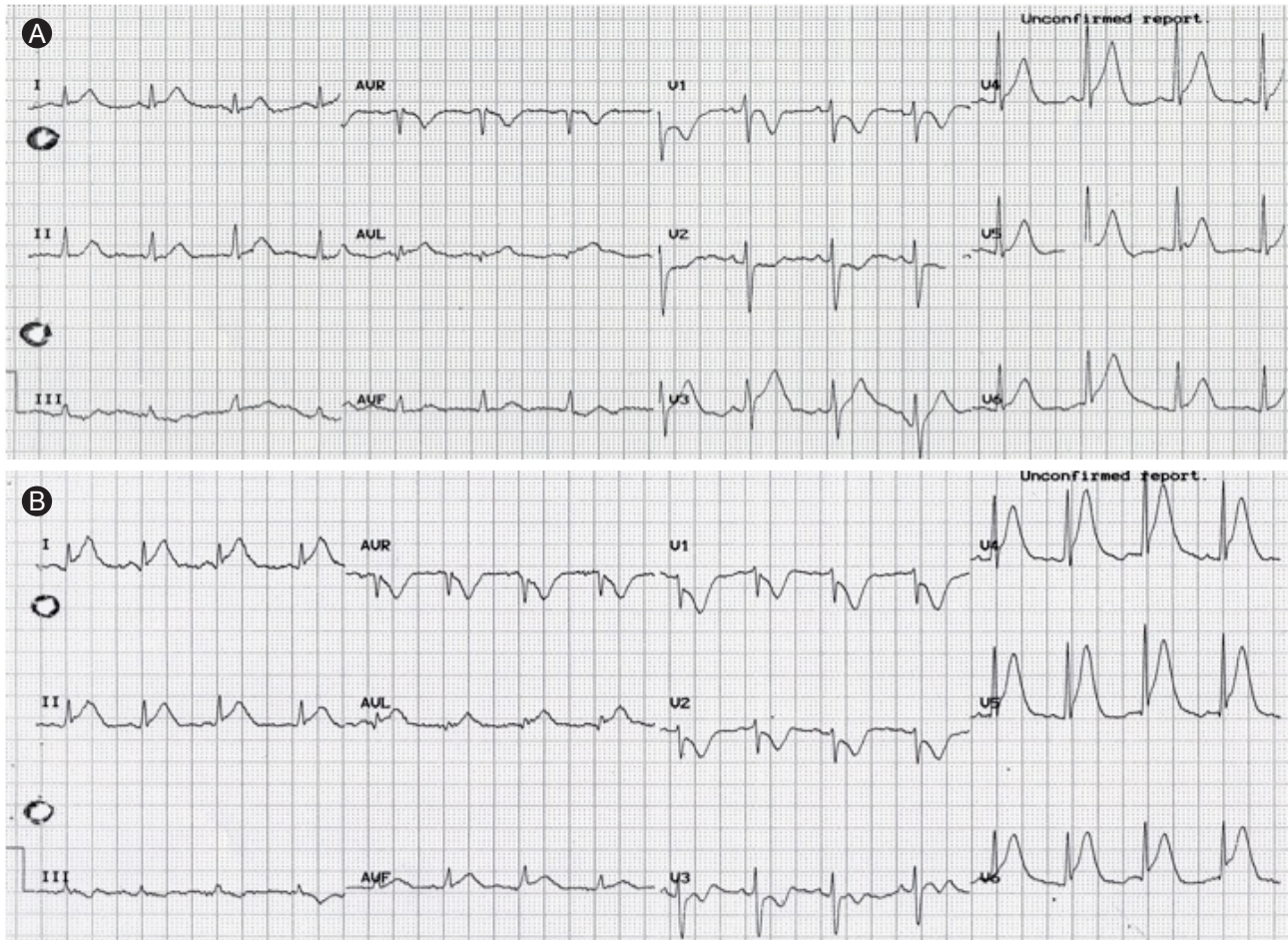
**Accepted:** July 30, 2008

**Correspondence to Jung-Ju Sir, M.D.**

Department of Internal Medicine, Cardiovascular Center, National Medical Center, 245 Eulji-ro, Jung-gu, Seoul 100-799, Korea  
Tel: 82-2-2260-7430, Fax: 82-2-2262-4749, E-mail: seo0515@medimail.co.kr

Copyright © 2012 The Korean Association of Internal Medicine

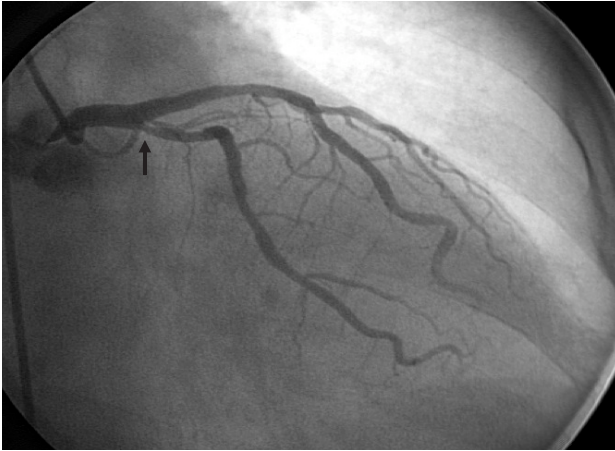
This is an Open Access article distributed under the terms of the Creative Commons Attribution Non-Commercial License (<http://creativecommons.org/licenses/by-nc/3.0/>) which permits unrestricted non-commercial use, distribution, and reproduction in any medium, provided the original work is properly cited.



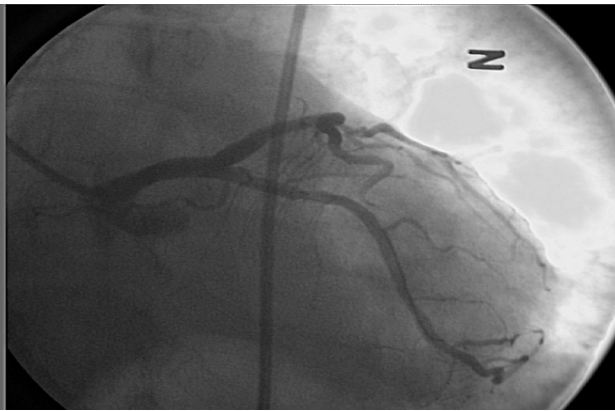
**Figure 1.** (A) 12-lead electrocardiogram obtained during the chest pain showed ST segment elevation with tall T waves in leads I, aVL, and V<sub>4-6</sub> and reciprocal ST segment depression in leads V<sub>1-2</sub>. (B) During a recurrence of the chest pain, ST segment elevation was seen in leads II, III, aVF, and V<sub>4-6</sub> and reciprocal ST segment depression in leads V<sub>1-3</sub>.

before 5-FU infusion on days 1 and 2; and infusion of 85 mg/m<sup>2</sup> oxaliplatin on day 1). The patient's medical history included no cardiovascular risk factors. Baseline echocardiography performed 1 month before admission showed normal left ventricular systolic function and no regional wall motion abnormality. He was treated with 1,500 mg high-dose 5-FU (1,000 mg/m<sup>2</sup>) per day. On the morning of the 3rd day, he developed a severe, substernal, crushing chest pain during the continuous intravenous infusion of 5-FU (cumulative dose 1,679 mg/m<sup>2</sup>), which was partially relieved by administering sublingual nitroglycerin. The electrocardiogram (ECG) showed ST segment elevation with a tall T wave in leads I, aVL, and V<sub>4-6</sub>, and reciprocal ST segment depression in leads V<sub>1-2</sub> (Fig. 1A). The troponin-I and CK-MB levels were 0.010 ng/mL (reference range,  $\leq$  0.1) and 3.73 ng/mL (reference range,  $\leq$  4.94), respectively. Severe hypokinesia of the lateral

wall of the left ventricle was noted on a portable bedside echocardiogram. The 5-FU infusion was stopped, and the chest pain and electrocardiographic changes resolved after intravenous infusion of nitroglycerin at 30  $\mu$ g/min. Emergency coronary angiography was then performed, which revealed significant stenosis in the proximal left circumflex coronary artery (LCx). Intracoronary nitroglycerin (200  $\mu$ g) was injected to exclude coronary vasospasm, but no change occurred (Fig. 2). Intravenous ultrasound (IVUS) showed severe luminal narrowing with a heavy concentric plaque in the proximal LCx. Coronary artery spasm with fixed stenosis was considered. Percutaneous coronary intervention of the proximal LCx lesion was performed successfully with the implantation of a drug-eluting stent (3.5  $\times$  16 mm; TAXUS, National Medical Center, Seoul, Korea) (Fig. 3). The patient was transferred to the coronary-care unit, where 8 hours later,

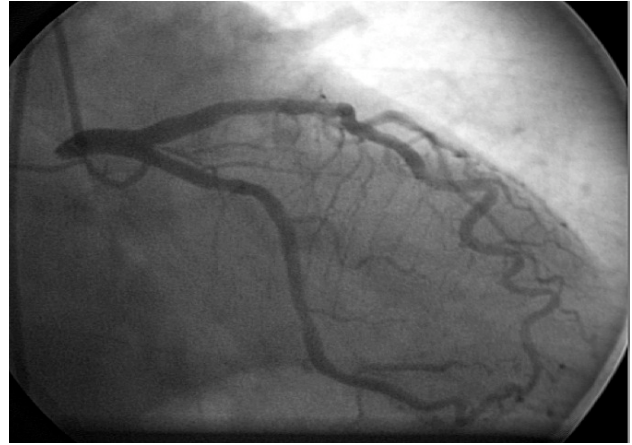


**Figure 2.** The left coronary angiogram in a right anterior oblique caudal projection showed a significant ostial lesion (arrow) in the left circumflex coronary artery.



**Figure 3.** The left coronary angiogram in a left anterior oblique caudal projection after percutaneous coronary intervention with drug-eluting stent implantation (3.5 × 1.6 mm; TAXUS).

he reported a recurrence of the anterior chest pain. The ECG also showed ST segment elevation and reciprocal ST changes similar to those seen in the previous ischemic events (Fig. 1B). The chest pain and ECG changes persisted despite a 100 µg/min nitroglycerin infusion. To rule out acute stent thrombosis, the patient was taken to the cardiac catheterization laboratory. The chest pain and ECG changes were relieved after sublingual administration of 10 mg nifedipine. Repeated coronary angiography showed a widely patent stent (Fig. 4). The postprocedural troponin-I and CK-MB levels were 0.010 and 4.62 ng/mL, respectively. Echocardiography performed the next day also showed the absence of the regional wall motion abnormality and normal left ventricular systolic function. The patient refused chemotherapy and was discharged in a stable condition. He remained free of the symptoms of recurrent angina pectoris.



**Figure 4.** Repeated left coronary angiogram in a right anterior oblique caudal projection showed a widely patent stent.

## DISCUSSION

We present here a case of severe cardiotoxicity mimicking acute anterolateral myocardial infarction occurring in a patient receiving 5-FU chemotherapy for adenocarcinoma of the colon. The cessation of 5-FU administration and the subsequent initiation of treatment with a sublingual calcium channel blocker and nitrate resulted in a successful outcome. Although the mechanism by which 5-FU exerts its cardiotoxic effects is unknown, the resolution of the patient's chest pain and the normalization of his ECG changes with a vasodilator strongly support the vasospastic hypothesis of 5-FU cardiotoxicity.

Many hypotheses regarding 5-FU-induced cardiotoxicity have been formulated. One study postulated that 5-FU-associated cardiotoxicity is due to the uncoupling of the electromechanical mechanisms that underlie normal myocardial function, which might be mediated at the level of the cell membrane [3]. Recently, Kuzel et al. [4] suggested that 5-FU promotes a hypercoagulable state (e.g., coronary artery thrombosis) and observed a significant increase in fibrinopeptide A and a decrease in protein C activity during 5-FU administration.

The incidence of clinically apparent 5-FU cardiotoxicity is less than 10% in patients receiving the drug [5]. Patients with a history of coronary artery disease (CAD) have a significantly increased risk of 5-FU-induced cardiotoxicity [6]. Although our patient did not have a history of CAD, a large atheromatous plaque was found on coronary angiography and IVUS. Therefore, during 5-FU infusion, close, careful monitoring of patients, especially those with pre-existing CAD or CAD risk factors, is mandatory. Prophylactic cal-

cium channel blockers or nitrates should be administered to patients with CAD during 5-FU administration, to prevent vasospasm [7]. One study proposed that impaired renal function is also a risk factor for 5-FU cardiotoxicity. Although it is not clear whether the cardiotoxic metabolites undergo renal excretion, the pathophysiological effect of 5-FU on the myocardium is likely to increase with decreased renal function. Thus it is necessary to clarify which patients may benefit from optimum anti-angina prophylaxis and careful, close monitoring [1].

The incidence of 5-FU-related cardiotoxicity appears to be dependent on the dosage and delivery system. Infusion of 5-FU, which is now being used more frequently and at higher doses instead of bolus therapy, may be a significant factor in the development of 5-FU cardiotoxicity [5]. In one study, nine patients treated with a higher-dose (> 800 mg/m<sup>2</sup>) continuous infusion of 5-FU died suddenly [5].

Interestingly, despite stopping the 5-FU, the chest pain and ECG changes recurred in our case. One series reported that 19% of the patients developed reversible angina pectoris during treatment, which lasted for up to 12 hours after cessation of the infusion [2]. The possible mechanisms of delayed angina are the late release of potent vasoactive 5-FU metabolites, which accumulate over time due to degradation of 5-FU [8]. Therefore, a calcium channel blocker or nitrates should be administered after stopping the 5-FU when 5-FU-induced cardiotoxicity occurs.

The long-term outcome of patients with 5-FU-related cardiotoxicity has not been investigated extensively. As with our case, Patel et al. [8] recently reported interval improvements in the left ventricular wall motion abnormalities in echocardiography performed 8 to 15 days following the initial study. Other investigators have reported similar reversible left ventricular dysfunction [9]. When cardiotoxicity occurs, 5-FU treatment is usually discontinued due to its very high recurrence rate (90%) [10]. The re-administration of 5-FU is not recommended, and a different chemotherapy regimen should be considered. Interestingly, Meydan et al. [10] continued 5-FU chemotherapy in one group who experienced 5-FU cardiotoxicity due to the absence of an alternative drug and found that subsequent serious, hemodynamic consequences were easily controlled with nitrate treatment. For the remaining patients, either 5-FU was removed from the combination regimen or an alternative drug was started and no cardiotoxicity developed subsequently.

In summary, although 5-FU-associated cardiac toxicity is rare, it may cause angina, myocardial infarction, and even sudden death. Physicians should be aware of this potentially lethal side effect and should start the proper treatment when 5-FU cardiotoxicity develops. This case supports the vasospastic hypothesis of 5-FU cardiac toxicity, indicating that a calcium channel blocker may be effective for prevention or treatment of 5-FU cardiotoxicity.

### Conflict of interest

No potential conflict of interest relevant to this article is reported.

### REFERENCES

1. Jensen SA, Sorensen JB. Risk factors and prevention of cardiotoxicity induced by 5-fluorouracil or capecitabine. *Cancer Chemother Pharmacol* 2006;58:487-493.
2. Wacker A, Lersch C, Scherpinski U, Reindl L, Seyfarth M. High incidence of angina pectoris in patients treated with 5-fluorouracil: a planned surveillance study with 102 patients. *Oncology* 2003;65:108-112.
3. Robben NC, Pippas AW, Moore JO. The syndrome of 5-fluorouracil cardiotoxicity: an elusive cardiopathy. *Cancer* 1993;71:493-509.
4. Kuzel T, Esparaz B, Green D, Kies M. Thrombogenicity of intravenous 5-fluorouracil alone or in combination with cisplatin. *Cancer* 1990;65:885-889.
5. Gradishar WJ, Vokes EE. 5-Fluorouracil cardiotoxicity: a critical review. *Ann Oncol* 1990;1:409-414.
6. Rezkalla S, Kloner RA, Ensley J, et al. Continuous ambulatory ECG monitoring during fluorouracil therapy: a prospective study. *J Clin Oncol* 1989;7:509-514.
7. Kleiman NS, Lehane DE, Geyer CE Jr, Pratt CM, Young JB. Prinzmetal's angina during 5-fluorouracil chemotherapy. *Am J Med* 1987;82:566-568.
8. Patel B, Kloner RA, Ensley J, Al-Sarraf M, Kish J, Wynne J. 5-fluorouracil cardiotoxicity: left ventricular dysfunction and effect of coronary vasodilators. *Am J Med Sci* 1987;294:238-243.
9. Baker WP, Dainer P, Lester WM, Marty AM, Blair TP. Ischemic chest pain after 5-fluorouracil therapy for cancer. *Am J Cardiol* 1986;57:497-498.
10. Meydan N, Kundak I, Yavuzsen T, et al. Cardiotoxicity of de Gramont's regimen: incidence, clinical characteristics and long-term follow-up. *Jpn J Clin Oncol* 2005;35:265-270.