

Peripheral primitive neuroectodermal tumor of head-neck region: our experience

Anirban Ghosh · Somnath Saha · Sudipta Pal · Padmini V. Saha · Sarbani Chattopadhyay

Abstract To present four rare cases of peripheral primitive neuroectodermal tumors of different sites of head and neck region. Four cases of different age (range 8–40 years) and sex (three female, one male) with rare primitive neuroectodermal tumor of sinonasal region and neck are presented. Treatment options, biological behavior and prognostic outcome are discussed herewith. Two patients succumbed to the disease within four to six months of treatment; other two patients are still under follow-up depicting the aggressive nature of the tumor. Primitive neuroectodermal tumor belongs to the class of malignant round cell tumor. Immunohistochemistry plays a pivotal role in differentiating this tumor entity. Chemoradiation was tried, but local and systemic spread occurs early and holds poor prognosis. This case series is an attempt to describe the aggressive behavior of this rare tumor with high mortality.

Keywords Primitive neuroectodermal tumor (PNET) · Ewing's sarcoma · Paranasal sinuses · Head-neck · Immunostaining · Chemotherapy · Radiation therapy

A. Ghosh¹ · S. Saha² · S. Pal³ · P. V. Saha⁴ · S. Chattopadhyay⁵

¹Department of ENT,

Anandolok Hospital, Raniganj, India

²Department of ENT,

B. S. Medical College, Bankura, India

³Department of ENT,

Medical College, Kolkata, India

⁴Department of Plastic Surgery,

R.G. Kar Medical College, Kolkata, India

⁵Department of Pathology,

B. M. College, Burdwan, India

S. Saha (✉)

E-mail: sreekar_saha@hotmail.com

Introduction

Primitive neuroectodermal tumor (PNET) is a term used to describe a group of highly malignant small round cell tumors of neuroectodermal origin with variable cell differentiation. Though PNET mostly occurs in the central nervous system, peripheral PNET (that occur outside CNS) has also been reported. In the head and neck region peripheral PNET has been reported in temporal region, paranasal sinuses, orbit, skull and masseter muscle. Immunohistochemistry is the main diagnostic tool to differentiate PNET from other small, round cell tumor such as rhabdomyosarcoma, neuroblastoma, lymphoma and Ewing's sarcoma. This tumor exhibits aggressive biological behavior and is prone to locoregional and systemic metastases. Surgical excision with tumor-free margin along with chemoradiation is the mainstay of treatment. Despite all modalities of treatment available, PNET still remains to be a tumor with very poor survival rate.

Case report

Case 1

A 9-year-old girl initially sought medical attention for nasal obstruction of right side, proptosis of right eye and cheek swelling of the right side. On clinical examination, a variegated mass was found in the right nasal cavity with diminished sensation over the cheek on the right side. There were slight bulge of gingivobuccal sulcus, mild axial proptosis of right eye. CECT PNS (Fig. 1) is suggestive of a soft tissue mass of heterogenous density inside right maxillary antrum with erosion of posterior wall. The mass invaded right nasal cavity and right pterygomaxillary fossa. Right ethmoid sinus was involved by the mass and right orbit. Endoscopic biopsy from the mass revealed round cell tumor. Immunohistochemistry showed the tumor was positive for MIC-2, vimentin (Figs. 2, 3) and thus the diagnosis of PNET was made. The patient underwent neoadjuvant chemotherapy

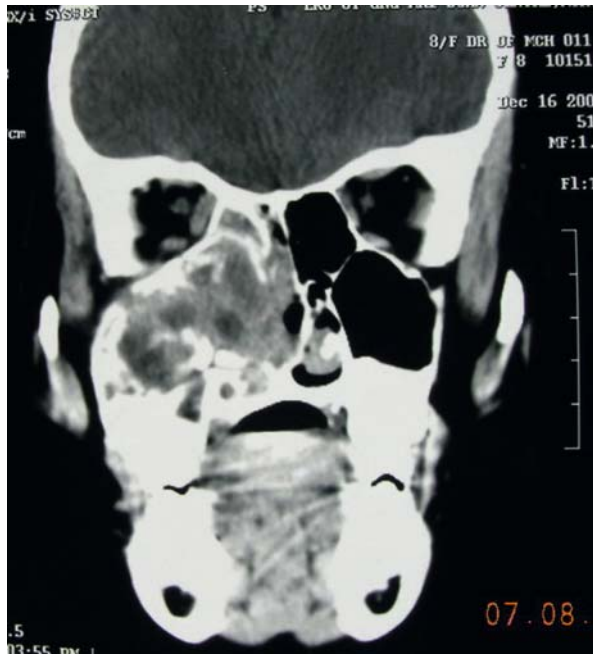

Fig. 1 CECT of PNS of Case no.1 shows heterogeneous soft tissue mass inside right maxillary antrum with erosion of posterior wall, invasion of right nasal cavity and right pterygomaxillary fossa, right ethmoid sinus and right orbit




Fig. 2 Immunohistochemistry of Case No. 1 shows positive results with vimentin

consisting of vincristine and Itoposide for six cycles followed by external beam radiotherapy from the zygoma to the upper two cervical vertebrae.

After one year, patient developed localized recurrence at right maxilla. CT scan at this time showed a near homogeneous mass in right maxillary antrum. Walls of right maxillary antrum shows sclerotic, ethmoid lesion as well as orbital lesion has regressed by chemoradiation. She underwent total maxillectomy. Within one month she complained of back pain and bony hard swelling over the frontal region. She underwent a bone scan (Fig. 4), which showed marked

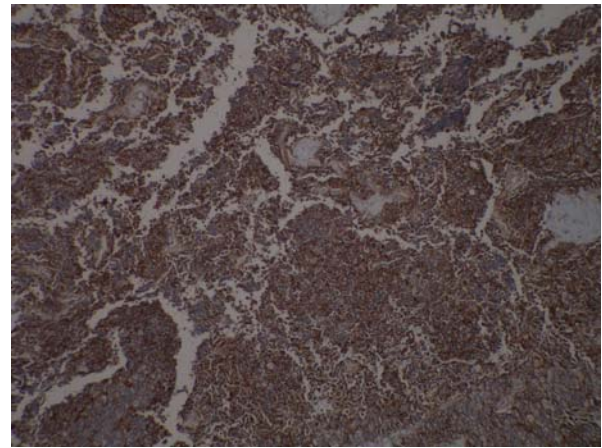


Fig. 3 Immunohistochemistry of Case No. 1 shows positive results with MIC-2

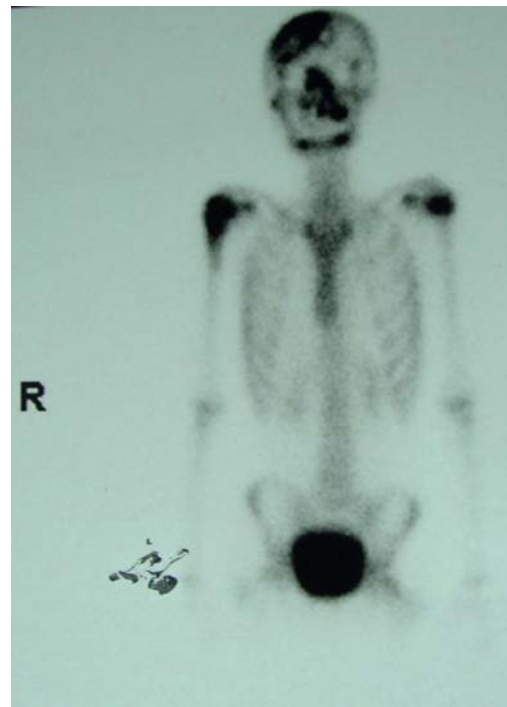

Fig. 4 Bone scan of Case No. 1 showed marked radiotracer uptake at right frontoparietal region, right shoulder joint with minute small deposits near hip joint and both knee joints

radiotracer uptake at right frontoparietal region, right shoulder joint with minute small deposits near hip joint and both knee joints, suggesting skeletal metastases. The patient was subjected to palliative chemotherapy and eventually succumbed within three months.

Case 2

A 17-year-old patient presented with a 5 × 7 cm, firm swelling in the right side of upper neck for last three months.

The mass was suddenly increasing in size and was painless. CT scan of neck revealed a heterogenous mass of about 6 cm diameter with indistinct margins situated in the right side of neck completely displacing the carotids (Fig. 5). Other otorhinolaryngological examinations were insignificant. FNAC from the swelling revealed malignant round cell tumor, immunohistochemistry revealed PNET. The blackish necrotic mass was adhered with great vessels and was abutting the skull base. The mass was dissected from its attachments and removed in totality. The patient was given postoperative chemotherapy consisting of vincristine and itoposide for six cycles. The patient did not develop any local or systemic recurrence after six months of follow-up.

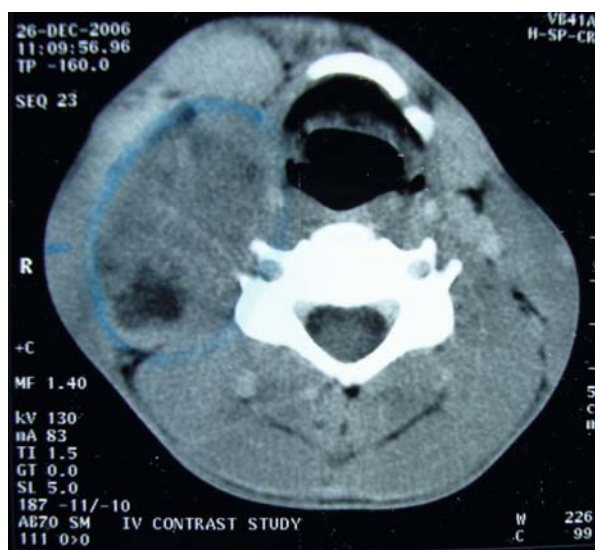


Fig. 5 CT scan of neck of Case No. 2 revealed a heterogenous mass of about 6 cm diameter with indistinct margins situated in the right side of neck completely displacing the carotids

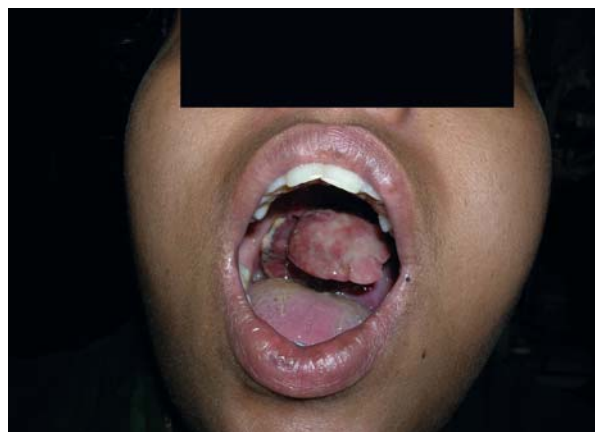

Fig. 6 Clinical photograph of Case No. 3 shows a fungating mass from nasopharynx with anterior bulging of soft palate

Case 3

A 30-year-old lady presented with a fungating mass from the nasopharynx with anterior bulging of soft palate (Fig. 6). She complained of obstructed nasal airway and nasal intonation of voice for last four months. On examination, a huge variegated mass was seen arising from nasopharynx with reduced nasal airway. CECT showed an enhancing heterogenous soft tissue mass originating from nasopharynx is present with erosion of base skull and abutting clivus. Punch biopsy from the mass revealed malignant round cell tumor which was then immunohistochemically proved as primitive neuroectodermal tumor. She was treated with six cycles of neoadjuvant chemotherapy consisting of vincristine and etoposide and followed by external beam radiotherapy. The mass was grossly reduced in size but did not completely disappear. The patient succumbed within four months of initial diagnosis.

Case 4

A 40-year-old lady presented with inflamed level two neck node of left side (Fig. 7). Routine otolaryngological examination revealed a blackish brown necrotic mass in the left side of the nasopharynx. Both endoscopic biopsy from the nasopharyngeal mass and FNAC from neck node revealed malignant round cell carcinoma. Immunologically it was positive for MIC-2. She was treated with neoadjuvant chemotherapy and external beam radiotherapy. She is still under strict follow-up and did not show any features of recurrent disease in three months.

Discussion

Stout initially reported first case of PNET in 1918 and found to be arisen from major nerves [1]. Later reports described these tumors in other anatomic locations—chest (Askin

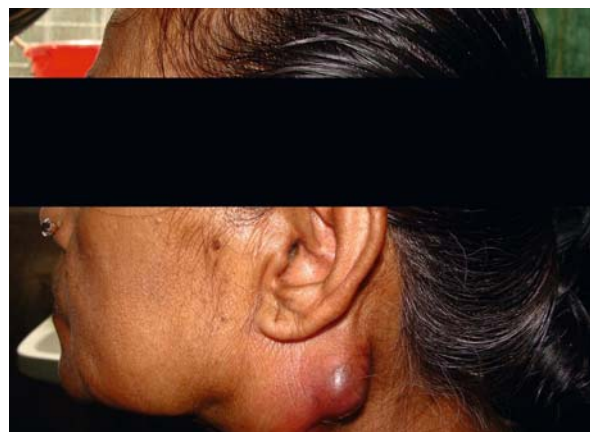

Fig. 7 Clinical photograph of Case No. 4 shows inflamed level two neck node of left side which on FNAC proved to be PNET

Case	Age/Sex	Clinical features	Radiological features	Treatment	Outcome
1	9 yr/F	Rt. maxillary mass with proptosis	Heterogenous mass with involvement of infratemporal and pterygopalatine fossae	Chemoradiation with vincristine and etoposide	Recurrence within 1 yr, Rx – maxillectomy, succumbed d/t bone metastasis
2	17 yr/M	Neck mass in right side of upper neck	Heterogenous mass in upper neck completely displacing carotids	Neck dissection followed by chemoradiation	Disease-free after 6 months of follow-up
3	30 yr/F	Fungating nasopharyngeal mass	Mass involving nasopharynx and skull base	Biopsy followed by chemoradiation	Succumbed within 4 months
4	40 yr/F	Level II neck nodes with nasopharyngeal mass	Heterogenous enhancing mass in both nasopharynx and neck	Chemoradiation	No recurrence after 3 months of follow-up

tumor), pelvis, abdomen, extremities. Most published series reveal a paucity of PNET cases in the head and neck region [2, 3, 4]. Paranasal sinuses, jugular foramen, neck, maxilla, mandible, orbit, masseter, temporal region, oral cavity, nasal cavity and skull are different sites in the head-neck region where PNET had been found.

Neural crest cells, primordial germ cells and uncommitted mesenchymal cells are among the cell lines responsible for the development of PNET. It is now believed that the likely progenitor are mesenchymal stem cells, not neural crest cells [5]. According to recent WHO definition, peripheral PNETs are also classified as part of the Ewing family of tumors (EFT); PNETs and Ewing's sarcoma are often referred interchangeably in the literature. Generally, Ewing sarcoma and PNETs represent different manifestations of the same tumor. Based on molecular cytogenetic analysis, both Ewing's sarcoma and PNET share same reciprocal translocations, most commonly between chromosome 11 and 22, t(11;22) [5].

The incidence of PNET is likely to be under-reported, as the recent advances in immunostaining have distinguished it from other round cell tumors. The estimated incidence of PNET is 2.9 per million per year. In most large series PNET usually presents in the second decade of life with slight male preponderance [2, 3, 4]. But in our series, we found cases of PNET in 9 to 40 years age group with female preponderance. Hence this study should be continued for a longer period to come to a conclusion.

In the head-neck region, clinical presentations depend on the site of involvement but invariably include pain and swelling of surrounding structures due to mass effect. Fever is also common. Other reported signs and symptoms are cranial neuropathy, exophthalmos, epistaxis, nasal obstruction, anosmia, neck masses, headache, etc. in this case series, we found epistaxis, exophthalmos, facial pain, nasal obstruction and neck mass as presenting complaints.

Once tumor is detected, radiographic evaluation is needed to know the character and extent of the lesion. CT scan reveals heterogenous enhancing soft tissue mass with or without bone erosion, with occasional intratumoral calcification. MRI reveals a mass isointense to muscle on T1-weighted images, while hyperintense on T2-weighted

images. Sabate et al. concluded that radiologic features of PNET are not pathognomonic and can not be diagnosed solely on the basis of radiographic technique [6].

Histologically, PNET appears to be a collection of small, round, darkly-stained cells. However, they cannot be differentiated from other round cell tumors by light microscopy alone. Electron microscopy reveals neurosecretory granules with microtubules and microfilaments. In addition short dendritic processes lie between cells in PNET; these are characteristically absent in Ewing's sarcoma. Rosette formation with tumor cells is absent in PNET, which is seen in other round cell tumors.

Immunohistochemical profile allows pathologist to distinguish PNET from other round cell tumors. PNET are positive for MIC-2, an antigen from MIC-2 gene, vimentin, S-100, Neuron-specific enolase, desmin, CD 75 and neurofilament protein. Electron microscopy and immunostaining play pivotal role in differentiating PNET from other similar appearing tumors such as non-Hodgkin lymphoma, neuroblastoma and rhabdomyosarcoma, etc. PNETs are typically positive for CD75, actin and desmin which are not positive in lymphoma. In these series, we found all cases were positive for MIC-2, vimentin, neuron-specific enolase etc.

Chromosomal studies such as reverse transcriptase PCR (RT-PCR) not only helps in differentiating PNET from other round cell tumors but also has a role in detecting occult micrometastases. 30% of PNET have micrometastases diagnosed by RT-PCR who are thought to have localized disease. The most common sites of metastases from PNET include lung, bone and bone marrow [7]. In a large series, the rate of metastases range from 20–31% with long-term survival rate of less than 25% [2, 3, 4]. In our series, we also found bone metastasis in one out of four cases of PNET.

Because of this high metastases rate at presentation, a detailed metastatic work-up is necessary in suspected cases of PNET. This includes chest radiograph, bone scan and if necessary bone marrow biopsy. PET scan is also indicated in suspected cases of bone metastases.

Surgical excision of the tumor with tumor-free margin is paramount in the surgical treatment of PNET. In large series, Kushner et al. [3] found that outcomes were more favourable among patients who underwent early surgical

removal combined with radiation and dose sensitive chemotherapy. Surgical treatment of this tumor in the head and neck region can be difficult in the light of anatomic consideration [8] and involvement of vital structures such as dura and base skull. In this series, we also found it difficult to treat PNET surgically when it involved nasopharynx, base skull abutting clivus. In such cases, palliative treatment with chemoradiation is the only feasible treatment option left.

Different chemotherapeutic drugs have been tried, but Carvajal and Meyers [9] have proposed chemotherapeutic regimen for PNET consisting of vincristine, doxorubicin, cyclophosphamide, iphosphamide and etoposide.

Radiation is generally administered as an adjuvant therapy when surgical excision is incomplete but can also be used as a primary therapy for unresected lesions. Though PNET is radiosensitive, radiation therapy alone is not curative for macroscopic disease [3]. Again high-dose radiation (more than 60 Gy) is associated with second sarcoma, acute myelocytic leukemia and myeloblastic syndrome. Those treated with less than 48 Gy had no additional risk of second malignancies [10]. Current recommendation provide for fractionated radiation therapy with higher treatment doses for patients with gross residual disease or microscopic residual disease with typical total doses that range from 45–55 Gy. Patients with negative gross or microscopic disease do not typically receive adjuvant radiation therapy.

Despite of all these modalities of treatment, the prognosis of PNET remains poor. Kushner et al. [3], in a review of Memorial-Sloan-Kettering's experience with PNET, reported 25% progression-free survival rate at 2 years in patients with localized disease. Other large series, however, reported somewhat better survival rates in patients with localized disease, with 2 large showing 2-year and 3-year survival rates of 65% and 56% respectively [3, 7]. In this series, we also found progression-free survival in one patient. Two patients succumbed to the disease within 6 months of initial treatment, one patient showed distant bone metastasis. This study should be carried forward to ascertain the actual survival statistics of PNET.

In conclusion, PNET is an aggressive tumor that is rarely encountered in the head and neck region. It presents with

rapid growth, epistaxis, bone involvement and facial pain. Diagnosis is based on immunohistochemical staining and radiological evaluation of the tumor. Treatment includes extensive surgical resection with tumor-free margins and adjuvant chemoradiation. Despite all attempts PNET still remains a very aggressive tumor with poor survival rate and high incidence of metastasis.

References

1. Stout AP (1918) A tumor of the ulnar nerve. *Proc NY Pathol Soc* 18:2–11
2. Jurgens H, Bier V, Harms D, et al. (1988) Malignant peripheral neuroectodermal tumors. A retrospective analysis of 42 patients. *Cancer* 61(2):349–357
3. Kushner BH, Hajdu SI, Gulati SC, et al. (1991) Extracranial primitive neuroectodermal tumors. The Memorial Sloan-Kettering Cancer Center experience. *Cancer* 67(7):1825–1829
4. Marina NM, Etcubanas E, Parham DM, et al. (1989) Peripheral primitive neuroectodermal tumor (peripheral neuroepithelioma) in children. A review of the St. Jude experience and controversies in diagnosis and management. *Cancer* 64(9):1952–1960
5. Dehner LP (1993) Primitive neuroectodermal tumor and Ewing's sarcoma. *Am J Surg Pathol* 17:1–13
6. Sabate JM, Franquet I, Parellada JA, et al. (1994) Malignant neuroectodermal tumor of the chest wall (Askin tumor): CT and MR findings in eight patients. *Clin Radiol* 49:634–638
7. Jones JE, McGill T (1995) Peripheral primitive neuroectodermal tumors of the head and neck. *Arch Otolaryngol Head Neck Surg* 121(12):1392–1395
8. Miser JS, Kinsella TJ, Triche TJ, et al. (1987) Treatment of peripheral neuroepithelioma in children and young adults. *J Clin Oncol* 5:1752–1758
9. Carvajal R, Meyers P (2005) Ewing's sarcoma and primitive neuroectodermal family of tumors. *Hematol Oncol Clin North Am* 19(3):501–25, vi–vii
10. Kuttesch JF, Wexler LH, Marcus RB, et al. (1996) Second malignancies after Ewing's sarcoma: radiation dose-dependency of secondary sarcomas. *J Clin Oncol* 14(10):2818–2825