

Innovative surgical management of large vallecular cysts

Halli Vijayanand · R. S. Mudhol · P. H. Patil · M. Maheswaran

Abstract Vallecular cysts are rare and vary from small cysts to large ones occupying the whole vallecula obscuring the view of the larynx. In the latter situation careful assessment and planning of airway management is required as in our case.

Keywords Vallecula · Cysts

Introduction

Cysts of the vallecula have been known by various names viz. base of tongue cyst, mucous retention cyst and many others [1, 2]. The presentations of vallecular cysts are varied with cough, dysphagia, foreign body sensation in throat, respiratory distress, pain in throat, hoarseness and stridor. The surgeries described are also many viz. deroofting, marsupialization, excision with snare, laser vaporization and others [1, 3].

We present a case of vallecular cyst presenting with dysphagia and operated in two stages. The advantages of operating a large cyst in two stages are discussed.

Case report

A 30-years-old male presented with progressive difficulty in swallowing of three months duration. He pointed to the back of his tongue as site of obstruction to food passage. There was no history of cough, difficulty in breathing, change in voice, earache, neck swelling, haemoptysis or haematemesis and disturbances of sleep. General and systemic examination revealed no abnormality. Indirect laryngoscopy revealed a smooth pale non pulsatile globular mass 4 cms × 3 cms occupying the whole base of tongue. The vallecula, larynx and hypopharynx were not visible. Fiberoptic laryngoscopy confirmed the above findings (Fig. 1). X-ray neck lateral view revealed no space between cystic mass and posterior pharyngeal wall for passage of endotracheal tube (Fig. 2). CT scan neck revealed a 4 cms × 3 cms unilocular cystic mass arising from left vallecula (Fig. 3). A haemogram, electrocardiogram, and urine analysis revealed no abnormality. T3, T4, TSH and thyroid scan showed no abnormality. With tracheostomy standby, individual was taken up for aspiration of cyst under local anesthesia (10% xylocaine spray) using a Boyle Davis mouth gag and 16 gauge needle with patient in Rose's position. Since the thick, viscous cyst fluid could not be aspirated using 16

H. Vijayanand (✉) · R. S. Mudhol · P. H. Patil · M. Maheswaran
Department of ENT & Head and Neck Surgery,
K.L.E.'S University, Jawaharlal Nehru Medical College,
Belgaum, Karnataka, India

E-mail: vijayanandhalli@gmail.com

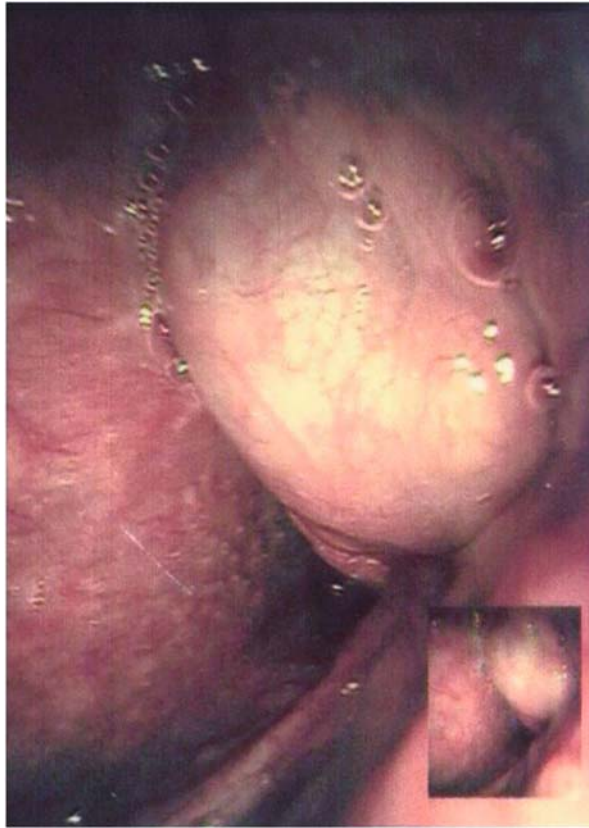

Fig. 1 Fibreoptic laryngoscopy showing a large globular swelling at the base of tongue and base of epiglottis

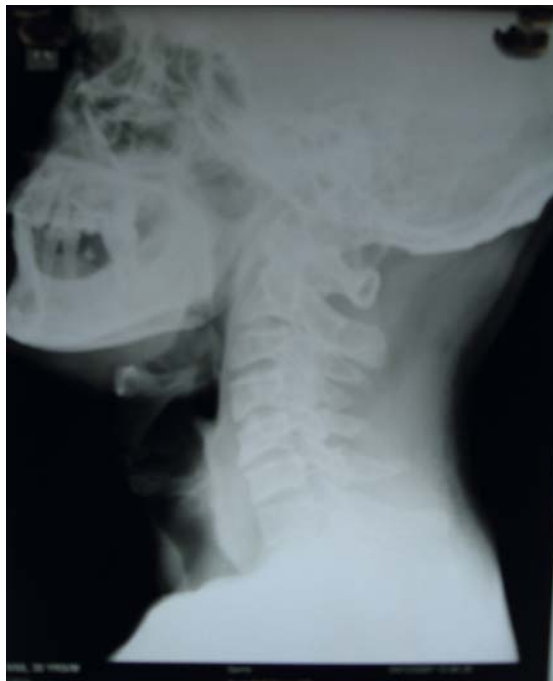

Fig. 2 X-ray neck lateral view- showing no space to pass Endotracheal tube

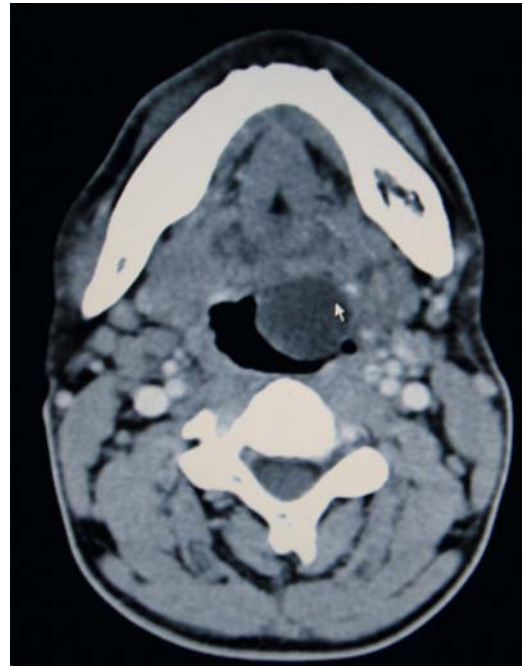


Fig. 3 CT scan-axial view of the neck (contrast) showing a cystic lesion at the root of tongue

gauge needle, a $\frac{1}{2}$ cm incision was made on the swelling and 25 ml thick, mucoïd, clear fluid was evacuated from the cyst and sent for microscopy to reveal only RBC's. Following aspiration of the cyst, the epiglottis and larynx were visible and the cyst was seen to be arising from the left vallecula. The next day the patient was taken up under general anesthesia for deroofing of the cyst and cautery of margins. There was no difficulty in passing the endotracheal tube and cyst could be deroofed with good haemostasis using the Boyle Davis mouth gag, tonsil scissors and bipolar cautery. Postoperatively patient was given steroids for three days and antibiotics for one week. Histopathology examination of the cyst showed chronic inflammatory lesion with mild dysplasia. Ten days post operatively patient showed a well-healed vallecula with good airway and no difficulty in swallowing.

Discussion

Vallecular cysts are believed to be essentially mucous retention cyst. They tend to grow in size with secretion of mucous. However their location necessitates the ruling out of a thyroglossal cyst and ectopic thyroid prior to excision, lest the only existing thyroid tissue at base of tongue is excised. In large cysts obscuring view of the larynx as in our patient, airway management is of prime importance. Evacuation of vallecular cyst contents under local anesthesia with standby tracheostomy and suction prevents tracheostomy and aspiration of cyst contents in the lung. Following aspiration of cyst, view of larynx is good and endotracheal intubation is

easily done with airway control. Additionally the benefit of microscopic examination of cyst fluid to rule out other pathologies like lymphatic malformation, thyroglossal cysts and malignancies is achieved. However smaller cysts with adequate space for endotracheal intubation may be excised as a single stage procedure.

Conclusion

Large vallecular cysts are better dealt with in two stages for better airway control and benefit of microscopic examination of cyst fluid. It helps in avoiding tracheostomy.

References

1. Albert DM, Ali Z (1985) Two cases of vallecular cyst presenting with acute stridor. *The Journal of Laryngology and Otology* 99:421–425
2. Ryouichi Fujii, Koichi Tsunoda (2007) Safe, complete resection of epiglottic cysts with phono-ultra-microsurgical technique. *The Journal of Laryngology and Otology* 1–3
3. Bhandary S (2003) Innovative surgical technique in the management of vallecular cysts. *Online Journal of Health and Allied Sciences*, 2:2
4. Cuillier F, Samperiz S, Testud R (2002) Antenatal diagnosis and management of a vallecular cyst. *Ultrasound Obstet Gynecol* 20:623–626