

Use of diode laser in oral submucous fibrosis with trismus: prospective clinical study

Jawahar R. Talsania · Umakant B. Shah · Ajay I. Shah · Naveen K. Singh

Abstract

Introduction Oral submucous fibrosis (OSMF) in later stages invariably leads to trismus due to retromolar fibrosis and buccal mucosa involvement. Medical treatment has limited role once trismus is established. Various surgical methods have been used with varying success to relieve trismus. We used diode laser to relieve trismus. All patients were diagnosed to have OSMF with trismus. The results are quite encouraging.

Study design Prospective clinical study. This study involved 8 patients between the years 2002 and 2006.

Objective To evaluate the efficacy of laser to reduce trismus in OSMF

Methods Laser with follow-up physiotherapy

Conclusion Diode laser gave good result in all our patients. Diode laser is a less expensive and alternative method in group III and group IVA cases in whom bilateral temporalis myotomy and coronoidectomy are considered to be the only solution.

This technique has less morbidity and is suitable for Asian population as it requires less hospital stay and less follow-up as compared to other surgical methods.

J. R. Talsania · U. B. Shah · A. I. Shah · N. K. Singh
Department of ENT,
Smt NHL Municipal Medical College,
V. S. General Hospital,
B-108, Doctor House,
Ellisbridge, Ahmedabad - 6, India

J. R. Talsania (✉)
e-mail: drtalsania_jawahar@yahoo.com

Keywords Oral submucous fibrosis · Trismus · Diode laser

Introduction

Oral submucous fibrosis (OSMF) is a collagen disorder usually involving oral mucosa. It is prevalent in people of the Indian subcontinent, commonly seen in those consuming betel nut. Its incidence in India has been reported to be 0.5% of the population with a 7.6% potential for development of malignancy [1].

In later stages, OSMF causes trismus leading to increased morbidity. Various surgical methods have been tried to relieve trismus but the use of diode laser with endoscope appears to be the easiest one for ENT surgeons and the procedure has good results. Diode laser emits through fiber-optic cable and has reasonable cutting efficacy.

Classification for management of trismus

The condition is staged into four categories as listed below [2]:

- Group I Interincisal distance greater than 35 mm
- Group II Interincisal distance of 26–35 mm
- Group II Interincisal distance of 15–25 mm. Fibrotic bands are visible at the soft palate, pterygomandibular raphe and anterior pillars of fauces
- Group IVA Interincisal distance of less than 15 mm with extensive fibrosis of oral mucosa all over
- Group IVB Premalignant and malignant changes throughout the mucosa (histologically)

Early cases, i.e. Group I and Group II cases, are usually treated by long-term antioxidant therapy with local injection of placentex, triamcinolone acetonide or hyalase [4],

while advanced cases, i.e. Group III, Group IV A and Group IV B cases, are treated by surgical intervention.

Selection criteria

Inclusion criteria: Patient belonging to Group III and Group IV A were selected for the prospective clinical study.

Exclusion criteria: As there were no patient of Group I, Group II having trismus therefore been managed by medical methods.

Group IV B cases labeled histologically having pre-malignant and malignant changes were excluded [2, 4, 10].

Group IV B, where zero-degree endoscope can't be introduced for visualization of retromolar fibrotic bands, were not taken for study.

Materials and methods

In the past, advanced cases of OSMF, characterized by trismus due to retromolar fibrosis and buccal mucosa

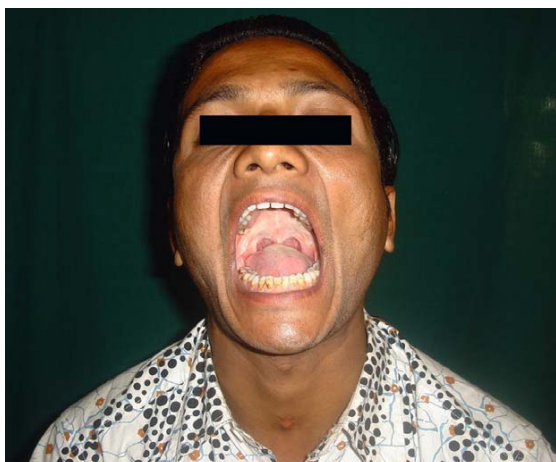


Fig. 1 Group IVA oral submucous fibrosis with trismus. Tracheostomy was performed (closure mark present), diode laser excision was done and followed by vigorous physiotherapy

involvement, were managed by various medical and surgical modalities. Medical treatment has limited role once trismus is established. Various surgical methods have been used with varying success to relieve trismus.

Of the numerous properties, penetration and absorption of rays are the two most relevant parameters for selection of diode laser. Diode laser is a portable device which delivers rays through a fiber-optic cable. Its cutting depth is less than 0.01 mm, and thus preserves tissues beyond this depth. It gives a precise line of controlled cutting without damaging the muscles and deeper structures. Hence, laser therapy eliminates the use of grafts, to close defect in spite of extensive resection. It yields excellent cosmetic and functional results [11].

The operation is done under general anesthesia. Of the 8 patients, 4 with group IVA underwent preoperative tracheostomy and in remaining 4 patients, flexible fiber-optic laryngoscope was used.

Zero-degree endoscope was introduced to visualize buccal mucosa and retromolar fibrotic bands with CCTV monitor. The bands were cut from anterior tonsillar pillar, retromolar area extending to the buccal mucosa using the diode laser so that there is resistance-free movement of the mandible.

The patients were started on a liquid diet on the same day and were allowed semisolid food from the next day and they were discharged in two to three days with analgesic and antibiotic. The surgery is followed by oral hygiene and aggressive physiotherapy with ice cream sticks. The patients were given dental clips. They were regularly followed-up initially once a week for one month and thereafter once every 3 months. The longest follow-up being 3 years.

Results

The patients were relieved of trismus in all cases. All of them had opening of the mouth with mean post-op interincisal distance about 33.25 mm. Laser causes average mouth opening of about 15 mm. The relief in trismus helped in improving the nutritional status, maintenance of proper oral hygiene and it also improves psychological well-being.

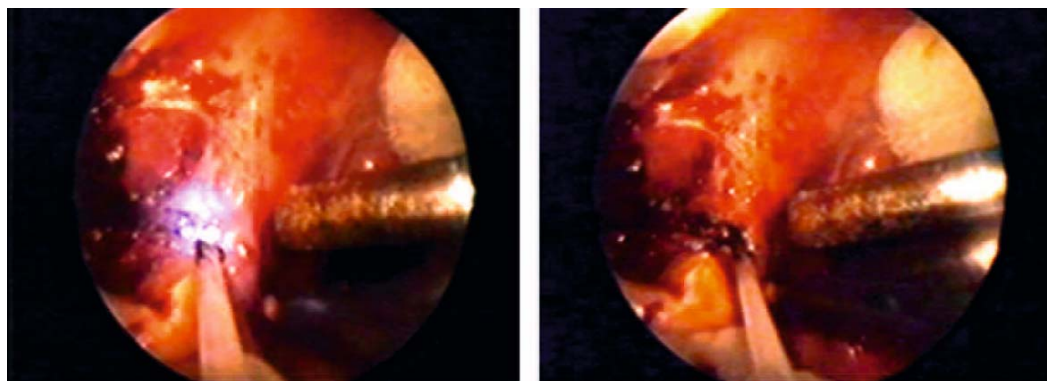


Fig. 2 Operative pictures showing laser excision of fibrotic band with diode laser

Discussion

OSMF is a collagen disorder found mainly in the Indian subcontinent and Southeast Asia in patients consuming betel nut. The incidence in India has been reported to be 0.5% of the population with a 7.6% potential for development of malignancy [1]. Prevalence of precancerous lesions was found to be 21.9 per 1000 [12].

Most medical treatments are ineffective and only give temporary relief. Effective medical treatment has still not been established. Trismus in OSMF is late stage manifestation and leads to poor oral and dental hygiene. This creates

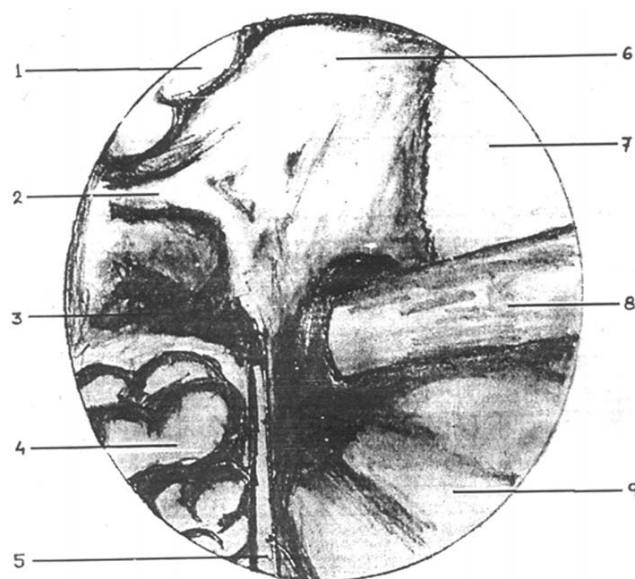


Fig. 3 Sketch of the operative pictures showing laser excision of the fibrotic band from the retromolar area 1. Upper molar 2. Retromolar fibrotic band 3. Laser excision of fibrotic band 4. Lower molar 5. Fibre optic fibre of diode laser 6. Palate 7. Gauze 8. Suction canula 9. Lack's tongue depressor

chronic irritation to these tissues may be the cause of oral cancer [4, 6].

Surgically, laser excision of fibrotic band with diode laser is a cheap, suitable and effective method to provide relief from trismus transoral laser excision gives the quality of recovery in spite of extensive resection, the defect is not closed nor covered by any flaps, and yet an excellent cosmetic and functional result is achieved Postoperative follow-up is done along with long-term antioxidant therapy and vigorous physiotherapy.

This prospective clinical study with follow-up of three years involved 8 patients. All patients were men, 5 (62.5%) were in the age group of 21–30 years, 2 (25%) were in the age group of 31–40 years and 1 (12.5%) was in the age group of 11–20 years.

Interestingly, the method of consumption of areca nut (the fruit of the areca nut) [8, 9] was also different in all patients. Three patients (37.5%) were consuming in the form of Mawa (areca nut, tobacco, lime), 2 patients pure areca nut were consuming and 3 patients (37.5%) in the form of *paan masala/gutka*. The study was done between 2002 and 2006 with the longest follow-up being 3 years. With the help of EPI Info™ the observations are tested with t, test and found highly significant ($t = 6.80, p < 0.0002$), proving that diode laser successfully relieved trismus.

Conclusion

Diode laser gave good result in all our patients. It is a less expensive and yet effective, alternative method in group III and group IVA cases. The observations were tested with t, test and found highly significant ($t = 6.80, p < 0.0002$), in relieving trismus. This technique is associated with less morbidity and is suitable for Indian people as it requires less hospital stay and less follow-up.

Table 1 Master chart

S. No.	Age	Sex	Occupation	Onset	Betel nut/ <i>gutka</i> / tobacco	Years of consumption	Grade	Interincisal distance (Pre-op)	Interincisal distance (Post-op)	Op*	F/up (Years)
1	23	M	Car mechanic	3	Budhalal + masala	6	IVA	12	38	L + T**	3
2	26	M	Baker	4	Manikchand	6	III	18	35	L + T	2.5
3	32	M	Scooter mechanic	5	Budhalal + masala	8	IVA	14	35	L*	2
4	38	M	Labourer	5	Masala + <i>gutka</i>	7	III	20	26	L	3
5	27	M	Street vendor	4	Masala	7	III	17	30	L + T	1.5
6	19	M	Motor mechanic	3	Masala	6	III	16	38	L + T	2
7	21	M	Laborer	4	Budhala + masala	7	III	17	33	L	2
8	30	M	Mason	3	Masala	8	III	22	31	L	2.5

L* = Laser

L+T** = Laser + Tracheostomy

References

1. Pindborg JJ (1965) Oral precancerous conditions in SE Asia. *Int Dental J* 32:750
2. Khanna, Andrade, Osmf A (1995) New concept in surgical management. *Int J Oral Maxil Sur* 24:433–439
2. Paymaster JC (1956) Cancer of buccal mucosa, a clinical study of 650 cases in Indian patients. *Cancer* 9:431
3. Pindborg JJ (1965) Frequency of oral sub mucosal fibrosis in north India. *Bulletin of the World Health Organization*. 32:748
4. Pindborg JJ (1967) Oral epithelial changes in thirty indians with oral cancer and sub mucosal fibrosis. *Cancer* 20: 1141–1146
5. Kakar PK (1986) Oral sub mucous fibrosis-treatment with hyalase. *Indian J Laryngol Otology* 99:57–59
6. Gupta DS, Gupta MK and Golhar BL (1980) Oral submucous fibrosis – clinical study management by physiofibriolysis. *J Indian Dental Assoc* 52:375–378
7. Mukherjee AI, Biswas SK (1972) Oral submucous fibrosis a search for etiology. *Indian J Laryngol Otology* 24:11–15
8. Canif JP, Harvey W (1981) The aetiology of oral submucous fibrosis. The stimulation of collagen synthesis by extracts of areca nut. *Int J Oral Surg* 10(Suppl 1): 163–167
9. Harey W Canif JP (1986) Stimulation of human buccal mucosa fibro blasts in vitro by betel nut alkaloids. *Arch Oral Biol* 31:45.9
10. Sadhu K, Makharia SM (2004) An unusual experience in OSMF. *Indian J Otolaryngo Head Neck Surg* 65–66
11. Robert HO, Coleman JA, Courey MS (1994) Clinical application of laser in otolaryngology – head and neck surg. *Laser in Surgery and Medicine* 15:217–248
12. Deshmukh PT, Raizada RM, Chaturvedi VN (1994) Epidemiological study of oral premalignant lesions in 3460 rural inhabitants of Maharashtra state. In: *Oral oncology*. Vol. III A Research. Ed. Verma AK. 3rd International Congress on OC Epi India (1994) Des: Case-control study 1994, pp 44–46