

## Isolated sphenoid sinus disease - a retrospective analysis

B. V. Manjula · Arun B. Nair · A. M. Balasubramanyam · Shantanu Tandon · Ravi C. Nayar

### Abstract

**Objective** To evaluate the etiology, symptoms, signs, imaging, surgical findings and outcomes of isolated sphenoid sinus disease (ISSD).

**Design** Retrospective study.

**Settings** Tertiary university based referral center.

**Materials and methods** All 8 patients aged 17–63, managed surgically in the department of ENT and Head and Neck Surgery at St. John's Medical College and Hospital, Bangalore from 2006 to 2008 for ISSD. Demographic data, presenting signs and symptoms endoscopic and imaging findings, surgical management, surgical pathology and clinical outcomes were investigated in the above patients.

**Results** Of the 8 cases of ISSD, 5 were male; 3 were female, with an age range of 17–63 years. The most common presenting symptom was headache (7 patients [87.5%]), followed by nasal obstruction and recurrent URTI (5 cases [62.5%]). Imaging included CT and/or MRI studies in all cases. Sphenoid sinus pathology was varied and included 5 (62.5%) inflammatory cases, 1 (11.1%) cerebrospinal fluid

fistula and 2 (22.2%) cases of sphenoid sinus neoplasms. Of the inflammatory cases 2 (40%) had isolated polyps in the sphenoid sinus [sphenchoanal polyps] and 3 (60%) had fungal sinusitis. Treatment was surgical, endoscopic transnasal sphenoidotomy under general anesthesia in all 5 patients with inflammatory ISSD. Two patients with sphenoid sinus tumors underwent endoscopic biopsy.

**Conclusion** ISSD is rare. A high index of suspicion is required for diagnosis, which should be an active process and not one of exclusion. Both diagnostic nasal endoscopy and CT imaging are essential for diagnosis. The direct approach to the sphenoid sinus, transnasal endoscopic sphenoidotomy without ethmoidectomy is safe and effective. With early and adequate surgery we were able to avoid the morbidity associated with ISSD.

**Keywords** Sphenoid sinus · Sphenchoanal polyp · Sinusitis · Headache · Sphenoidotomy

### Introduction

The sphenoid sinus was termed as the “neglected sinus” by Van Alyea, in 1941 [1], as it was rarely implicated in ENT diseases. However, sphenoid sinus disease has been reported increasingly in subsequent medical literature.

Patients with sphenoid sinusitis present with a long history of non-specific symptoms, headache (particularly retro-orbital), visual changes and cranial nerve deficits [2–5]. If diagnosis and treatment are delayed serious complications can occur. This is due to critical anatomic relationships, such as the brain and meninges, optic nerve, internal carotid artery and the cavernous sinus, with its associated cranial nerves (III, IV, V1, V2 and VI) [6, 7].

Isolated sphenoid sinus disease (ISSD) is rare. It accounts for <3% of inflammatory sinus lesions [2], and <0.05% of sinus malignancies. While there are many series reported

---

B. V. Manjula · A. B. Nair · A. M. Balasubramanya ·  
S. Tandon · R. C. Nayar  
Department of Otolaryngology and Head and Neck Surgery,  
St. Johns Medical College and Hospital,  
Bangalore - 560 034, India

B. V. Manjula (✉)  
E-mail: manjula\_doc@rediffmail.com

from the west [8–10] there is a paucity of series on ISSD from the Indian subcontinent in indexed literature.

We report a retrospectively analyzed series of 8 cases of ISSD managed at St. Johns Medical College and Hospital, a tertiary referral center in South India.

## Materials and methods

From 2006 to 2008, over 400 patients underwent endoscopic sinus surgery in the department of ENT and Head and Neck, St. Johns Medical College and Hospital, Bangalore. From this group 8 cases were identified as having ISSD. A retrospective analysis was made to evaluate the etiology, symptoms, signs, imaging, surgical findings and outcomes of ISSD in all cases. We report the use of both nasal endoscopy and imaging (CT or MRI), which together represent the present rhinologic standard of care.

## Results

Of the 8 cases of ISSD, 5 were male; 3 were female, with an age range of 17–63 years. Three patients (37.5%) had been directed to us by a neurologist and 1 (12.5%) by a physician. None of the patients had any previous history of chronic sinus infections. The disease was unilateral in 7 patients and bilateral in one. Co-morbid conditions were noted in 4 patients, type 2 diabetes mellitus (DM) and hypertension in 2 cases with fungal sinusitis, hepatitis B and HIV, respectively in each of 2 cases with sphenoid sinus tumors (Table 1).

**Table 1** Co-morbid conditions in 4 cases with ISSD

Co-morbid disease	No.	Sphenoid pathology
Diabetes mellitus type 2	2	Fungal sinusitis
Hypertension	2	Fungal sinusitis
Hepatitis B	1	Metastatic hepatocellular carcinoma
Retroviral	1	NHL deposit

**Table 2** Patients with inflammatory lesions of the sphenoid sinus

	Symptoms					Treatment
	Headache	Nasal obstruction	Recurrent URTI	Visual symptoms	Cranial nerve deficits	
Total inflammatory group (n = 5)	4	5	5	0	0	
Fungal (n = 3)	3	3	3	0	0	Sphenoidotomy and clearance
Polyps (n = 2)	1	2	2	0	0	Polypectomy, sphenoidotomy and clearance

## Inflammatory lesions

The presenting symptoms of 5 patients found to have inflammatory ISSD are highlighted in Table 2. Two of these patients had isolated polyps in the sphenoid sinus (sphenochanal polyps) and 3 of them had fungal sinusitis.

## Sphenoid polyps

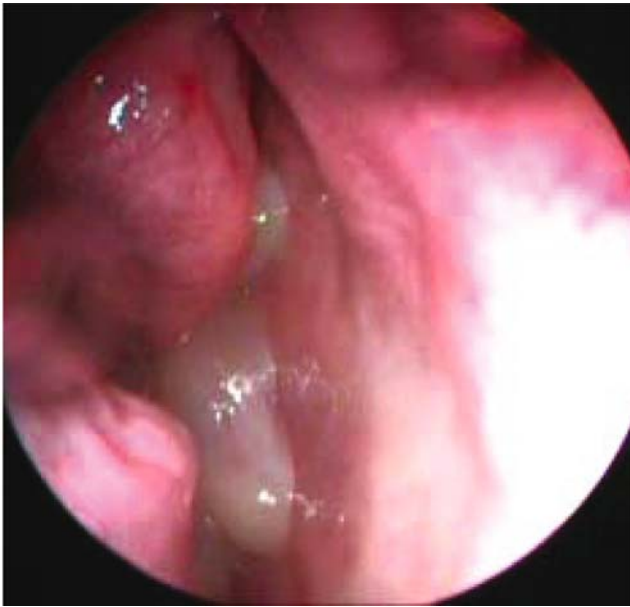
Both these patients presented with nasal obstruction on and off and recurrent upper respiratory tract infections (URTIs). The duration of symptoms ranged from 3 months to 10 years. Unilateral dull aching headache was seen in only 1 patient. On diagnostic nasal endoscopy (DNE) a polypoidal mass was seen in the choanae and the sphenothmoidal recesses on the affected side in both the cases. Figure 1 plain CT scan paranasal sinuses (PNS) in both these patients showed findings consistent with inflammatory disease, such as partial or complete opacification of the sphenoid sinus. Figure 2 bone erosion was not seen in either of these patients. In one case a globular opacity partially filling the cavity was seen. A contrast enhanced CT scan PNS was done to rule out a neoplastic lesion in the above patient.

## Fungal sinusitis

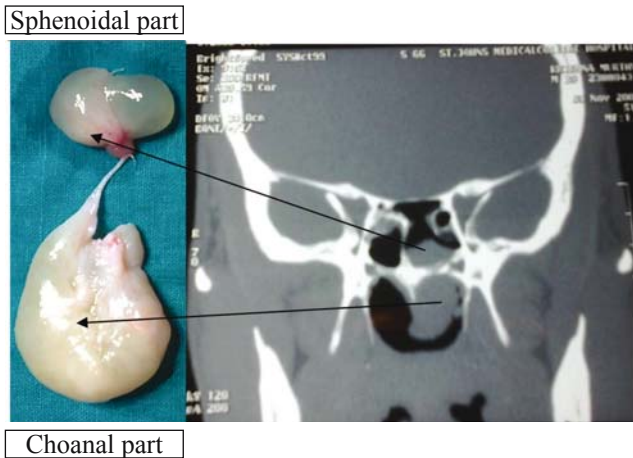
All 3 patients diagnosed as having fungal sinusitis presented with headache (Table 2). Headache was generalized in 1 patient whereas unilateral in two. Nasal block was also seen in 1 patient. Two of these patients had co-morbid conditions, Type 2 DM and hypertension, respectively (Table 1). CT scan PNS in all these patients showed findings consistent with inflammatory ISSD. Non-invasive *Aspergillus* organisms were found in the sphenoid sinus in all 3 cases.

## Surgical treatment

Treatment was surgical, endoscopic transnasal sphenoidotomy under general anesthesia in all 5 patients



**Fig. 1** Polyp in the right sphenothmoid recess, arising from sphenoid sinus and extending into right choana and nasal cavity



**Fig. 2** Plain CT PNS with specimen of sphenochanal polyp

with inflammatory ISSD. After decongesting the nasal cavities with 4% xylocaine and adrenaline soaked packs, the sphenoid rostrum was approached between the middle and superior turbinate laterally and the septum medially. At the rostrum the natural ostium of the sphenoid sinus was identified and enlarged with a sphenoid punch in an inferomedial direction. Inspissated secretions, fungal debris, diseased tissue, polyps were removed by a variety of techniques ranging from avulsion to suction and irrigation. Histopathologic examination of debris and Inspissated secretions disclosed non-invasive *Aspergillus* species in all 3 cases.

Postoperatively all 5 patients noted improvement of their symptoms and none of the patients had recurrence of

the disease based on postoperative nasal endoscopy, in the follow up period ranging from 6 months to 2 years.

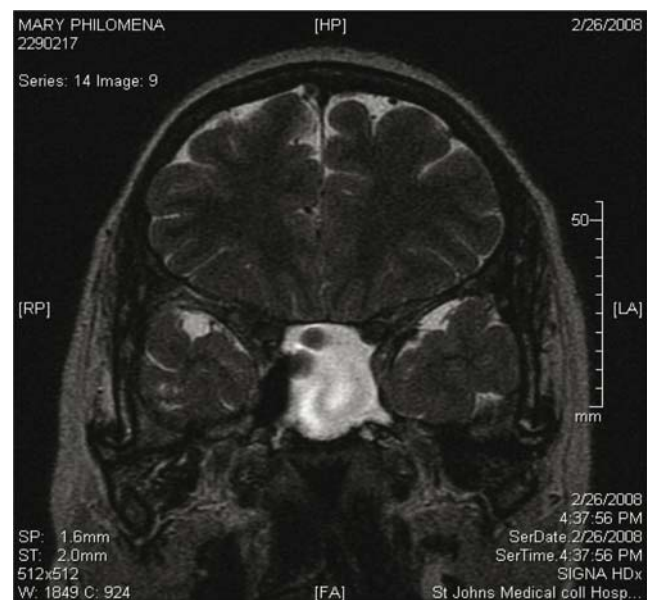
## Non-inflammatory lesions

### Cerebrospinal fluid (CSF) leak

A 54-year-old female patient was identified with sphenoid sinus CSF fistula. She presented with unilateral clear nasal discharge since 10 days that increased on provocative positioning. She also had complaints of vomiting and headache for 7 days. The cause of the leak was not apparent on the basis of history and physical examination. Nasal endoscopic findings were non-specific. Nasal fluid analysis was consistent with CSF. CT cisternography demonstrated bony dehiscence in the posterosuperior wall with partial opacification of the sphenoid sinus. On MRI hyperintense signal was noted on T2-weighted images within the sinus consistent with fluid CSF (Fig. 3). Herniation of brain parenchyma or meninges through the bony defect in the sinus was not identified by MRI. She underwent a transnasal repair of CSF leak with fascia lata, fat and tissue glue. She was followed up for a period of 1 year and no recurrence of leak was noted.

### Sphenoid sinus tumors

Two patients had neoplasms involving the sphenoid sinus (Table 3). A 53-year-old male patient was referred to us with symptoms of gradually progressive diplopia and ptosis over 3 months duration. On examination he had



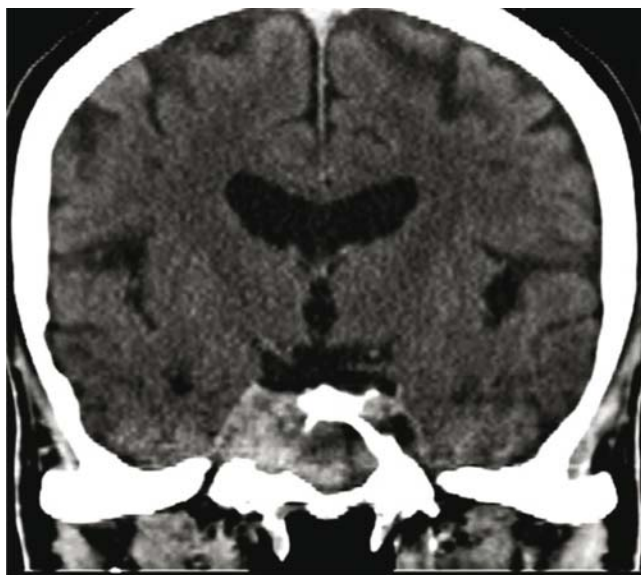**Fig. 3** CSF leak seen as bright signal in T2 weighted image

**Table 3** Patients with neoplasms of the sphenoid sinus

	Symptoms						Treatment
	Headache	Nasal obstruction	Diplopia and ptosis	Visual symptoms	Proptosis	Cranial nerve deficits	
Metastatic - HCC	P	P	P	P	A	P	DNE and biopsy
NHL deposits	P	A	A	P	P	P	DNE and biopsy

P: Present, A: Absent.

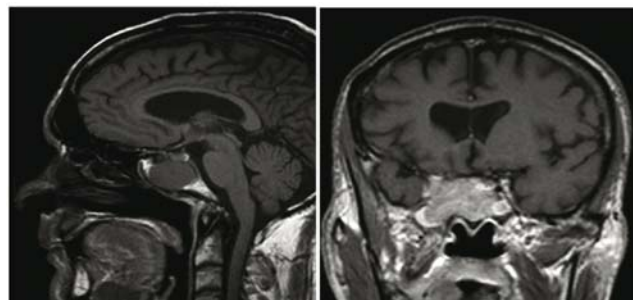
decreased vision, complete ophthalmoplegia and decreased sensation over the face on the right side suggestive of III, IV, V and VI cranial nerve weakness. A contrast CT scan PNS showed a large isodense mass, involving the whole of sphenoid sinus. There was destruction of the right lateral wall of the sphenoid sinus with the mass extending into the parasellar area (Fig. 4a), and involving the cavernous sinus. On MRI the mass was seen involving the right cavernous sinus fully encasing the carotid artery. It also showed the mass separate from the pituitary gland (Fig. 4b). A preoperative hematological workup revealed the patient to be positive for hepatitis B. A biopsy from the mass on histopathologic examination showed characteristics of metastatic hepatocellular carcinoma. This diagnosis was confirmed by immunohistochemistry which was positive for  $\alpha$ -fetoprotein. The primary was subsequently identified in the liver on abdominal ultrasonogram and CT scan. There was a large lesion near the portal vein in the right lobe of the liver with multiple smaller satellite lesions. A CT guided fine needle aspiration cytology (FNAC) of the liver lesion was diagnostic of hepatocellular Carcinoma. This case is noteworthy as the primary was asymptomatic



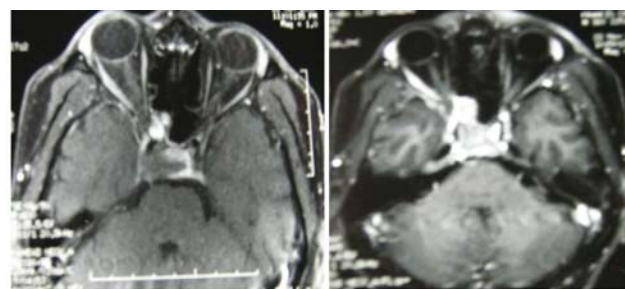
**Fig. 4a** Enhancing isodense lesion involving the whole of the right sphenoid sinus with destruction of right lateral wall of sphenoid with lesion extending to the parasellar area and cavernous sinus

and the patient was diagnosed only after evaluation of the metastatic lesion in the sphenoid sinus.

A 38-year-old male patient, a known case of human retro viral infection and non-Hodgkin's lymphoma (NHL) of stomach was referred to us from internal medicine department for evaluation of headache for 2 months, right eye swelling and blurring of vision since 1 month. On examination he had right eye proptosis, with complete ophthalmoplegia and decreased sensation of affected side of face suggestive of III, IV, V and VI cranial nerve deficits. He had an MRI which was suggestive of metastatic deposit in sphenoidal body, extending to right pterygoids, right orbital apex and dorsum sella (Fig. 5). He underwent DNE and biopsy of the sphenoid mass. Histopathology was consistent with NHL. Immunohistochemistry was positive for CD20 marker, which confirmed the findings.



**Fig. 4b** T2 MRI sagittal section: Lesion seen separate from pituitary, T2 MRI coronal section: Lesion in right sphenoid extending to right cavernous sinus, fully encasing the carotid artery



**Fig. 5** Metastatic deposit in sphenoidal body, extending to right pterygoids, right orbital apex, dorsum sella

## Discussion

ISSD presents a diagnostic and therapeutic challenge. The initial signs and symptoms of ISSD are often similar regardless of the pathology. The largest documented series of ISSD by Cakmak et al. [9] reported headache as the primary presenting symptom in 72.5% of patients. Similarly, in our study headache was the principal symptom in 7 patients (87.5%). This is explained by the innervations of the sphenoid sinus, which is derived from both cranial nerve V1 (Ophthalmic branch) and afferent fibers via the sphenopalatine ganglion [6]. This pain is often vague, unilateral or bilateral and difficult to characterize.

Recurrent nasal blockage and URTI was the second most common symptom in our series seen in 5 cases (62.5%) with sphenoidal polyps and fungal sinusitis and nasal obstruction with epistaxis in 1 patient with sphenoid sinus tumor. This finding was different from other studies reported in literature where visual changes and cranial nerve deficits were the second and third most common presenting symptoms, respectively [8, 9]. Although reported to occur in both inflammatory and neoplastic lesions, in our series both visual changes and cranial nerve deficits (“Sphenocavernous syndrome” including deficits in cranial nerves III, IV, V1, V2, VI) [11] were found only in our 2 cases with sphenoid sinus tumors. None of our inflammatory cases had any such symptoms.

DNE is helpful in defining any extension into the nasal cavity or in obtaining culture material. However even in cases where the lesion extends to the nasal cavity, only minimal information can be obtained regarding the cause of the process. For patients with CSF rhinorrhea, DNE can help in localizing the site of leak to the sphenoid sinus. Endoscopic biopsy should be avoided until the work up is complete and a treatment plan is in place to avoid complications like hemorrhage and cranial nerve injury.

Radiological imaging with CT scanning of PNS is regarded as the gold standard in the diagnosis of ISSD [8]. CT is helpful in defining the extent of the lesion and for identifying focal dehiscences within the sinus walls. MRI is an essential adjunct in the diagnosis and treatment of lesions of the sphenoid sinus. The algorithm for radiologic diagnosis of ISSD put forward by Lawson and Reino was followed in our study and findings recorded accordingly. Partial or complete opacification are consistent with inflammatory lesions such as sinusitis which do not necessitate an MRI. A globular opacity partially filling the cavity generally represents a mucous retention cyst or polyp. When thinning, expansion or remodeling of a sinus wall is noted MRI helps to differentiate mucocele from benign tumors. When total sinus opacification with sclerosis of surrounding bone is seen MRI can diagnose fungal sinusitis by demonstration of a signal void in the sinus cavity as opposed to the mixed signal pattern found with fibro osseous disorders. Evidence

of bone erosion and perisinus extension are hallmarks of malignant disease, including that primary in the sinus and those extending from adjacent areas (pituitary, clivus and nasopharynx) or metastasis [8].

Surgical intervention on a completely opacified sphenoid sinus that fails to respond to medical management is necessary for both diagnostic and therapeutic reasons [7, 12]. Transnasal endoscopic sphenoidotomy is recommended as a treatment for ISSD of inflammatory origin. This could be either transethmoidal or directly through the anterior sphenoid sinus wall [7] which was used in our series. This direct approach has the advantage of being regionally limited, minimally disruptive to the osteo meatal complex (OMC) and ethmoid sinus, with shorter surgical time, faster healing and less complication [13].

## Conclusion

ISSD is rare. A high index of suspicion is required for diagnosis, which should be an active process and not one of exclusion. Most common presenting signs and symptoms are vague headache refractory to medical management, with nasal obstruction, postnasal drip, visual loss and cranial nerve palsies. Visual loss and cranial nerve palsies were noted only in patients with sphenoid sinus tumors. Both DNE and CT imaging are essential for diagnosis. When bone erosion is noted on CT, MRI is required to determine the presence and extent of skull base and intracranial involvement. In ISSD therapeutic options should take into account endoscopic and radiographic findings to optimize patient safety and outcome. The direct approach to the sphenoid sinus, transnasal endoscopic sphenoidotomy without ethmoidectomy was found to be useful. With early and adequate surgery we were able to avoid the morbidity associated with ISSD.

## References

1. Van Alyea OE (1941) Sphenoid sinus: anatomic study, with consideration of the clinical significance of the structural characteristics of the sphenoid sinus. *Arch Otolaryngol* 34:225–253
2. Lew D, Southwick FS, Montgomery WM, et al. (1983) Sphenoid sinusitis: a review of 30 cases. *N Engl J Med* 309:1149–1154
3. Hadar T, Yaniv E, Shvero J (1996) Isolated sphenoid sinus changes - history, CT and endoscopic finding. *J Laryngol Otol* 110:850–853
4. Metson R, Gliklich RE (1996) Endoscopic treatment of sphenoid sinusitis. *Otolaryngol Head Neck Surg* 114: 736–744
5. Pearlman SJ, Lawson W, Biller HF, et al. (1989) Isolated sphenoid sinus disease. *Laryngoscope* 99:716–720
6. Levine H (1978) The sphenoid sinus, the neglected nasal sinus. *Arch Otolaryngol* 104: 585–587

7. Kron TK, Johnson CM (1983) Diagnosis and management of the opacified sphenoid sinus. *Laryngoscope* 93: 1319–1327
8. Lawson W, Reino AJ (1997) Isolated sphenoid sinus disease: an analysis of 132 cases. *Laryngoscope* 107:1590–1595
9. Cakmak O, Shohet MK, Kern EB (2000) Isolated sphenoid sinus lesions. *Am J Rhinol* 14:13–19
10. Wang Z, Kanoh N, Dai C, et al. (2002) Isolated sphenoid sinus disease: An analysis of 122 cases. *Ann Otol Rhinol* 111:323–327
11. Harbison JW, Lessell S, Selhorst JB (1984) Neurophthalmology of sphenoid sinus carcinoma. *Brain* 107:855–870
12. Sethi DS (1999) Isolated sphenoid sinus lesions: diagnosis and management. *Otolaryngol Head Neck Surg* 120: 730–736
13. Kieff, David A, Busaba, Nicholas (2002) Treatment of isolated sphenoid sinus inflammatory disease by endoscopic sphenoidotomy without ethmoidectomy. *Laryngoscope* 112(12):2186–2188