

# REPAIR OF TYMPANIC MEMBRANE PERFORATION BY TOPICAL APPLICATION OF 1% SODIUM HYALURONATE

Kulwant Kaur,\* Harpreet Singh,\*\* Manwinder Singh\*\*\*

**Abstract:** Objective: The administration of exogenous hyaluronic acid can increase the repair potential of damaged tissue. This study was conducted to verify whether or not the hyaluronic acid enhances the repair process in perforations of tympanic membrane. Hyaluronic acid is commercially available as its sodium salt.

**Study Design:** Thirty patients with dry central perforations of small or medium size (up to 3 mm) were treated locally with 1% sodium hyaluronate. The applications were repeated weekly for a maximum of five applications.

**Results:** It was found that treatment with sodium hyaluronate helps appreciably in the closure of tympanic membrane perforations and also that the scar formed in majority of them resembled the normal tympanic membrane. 86.67% (26/30) of the patients responded positively to the treatment. More importantly overall average percentage reduction in the size of perforations was 86.49%.

**Conclusions:** It was concluded that topical application of 1% sodium hyaluronate can be an alternative to surgery in selected cases of tympanic membrane perforations.

**Key words:** Hyaluronic Acid, Tympanic Membrane Perforation

## INTRODUCTION

Persistent tympanic membrane perforation has for long been a challenge to the medical science. The central perforations can be divided into 2 classes according to the cause: traumatic and inflammatory. Traumatic perforation can occur due to compression injuries, instrumentation, burn slag and blast injuries. In the inflammatory group, the perforation of tympanic membrane may be due to acute or chronic otitis media.

The possibility of topical treatment with sodium hyaluronate was first evaluated in animal models<sup>1</sup>. In that study a significantly accelerated rate of healing was reported. The results have also been verified in humans<sup>2-6</sup> leading to same conclusions as previously observed in animals. Hyaluronic acid is a glycosaminoglycan. Glycosaminoglycans are essential for maintaining structural integrity of many connective tissues<sup>7</sup>. Hyaluronic acid has high elasticity, because of which it lubricates joints and can hold cells together in intercellular connective tissue. The administration of hyaluronic acid can increase the repair potential of tympanic membrane<sup>8</sup>.

The purpose of the present study was to evaluate the degree of reduction of tympanic membrane perforation after treatment with 1% sodium hyaluronate. Also, the type of scar tissue formed was to be evaluated. Thus it was to be evaluated that whether or not hyaluronic acid can be an alternative to surgical myringoplasty in selected cases of tympanic membrane perforation.

## MATERIAL AND METHODS

Thirty patients (8 males and 22 females), age 15-60 yrs, visiting the outpatient department of Ear, Nose and Throat wing of Medical College, Amritsar during the period of 2002-2003, with dry central perforation were chosen according to the following criteria :-

1. Size of perforation was to be upto 3 mm, it should have been dry for at least 3 weeks in inflammatory group and in cases of traumatic perforations it had to be at least 6 weeks old to rule out spontaneous closure.
2. Eustachian tube should have been patent.
3. Good Air bone gap on audiometry should be present.

Table I shows the patient and perforation characteristics.

Sodium hyaluronate is available in a prefilled syringe. A fine canula was mounted over the syringe for its application. The treatment was given by direct application of 0.2 ml of 1% Sodium hyaluronate on the perforation under strictly sterile conditions. The application was repeated weekly for a maximum of 5 applications. The patients were followed up for 3 months. The final mapping was done 3 months after the last sodium hyaluronate application for the following:-

1. Status of tympanic membrane perforation, i.e. closed, reduced, persistent or recurrent. A comment was made about the type of scar tissue. The percentage of reduction was calculated as the difference between areas before and after treatment. Area was defined as square resulting from smallest and largest diameters of perforation.
2. Pure tone audiometry was done to assess the improvement in hearing.

## RESULTS

Table II shows healing results. 16 of the patients had completely closed tympanic membrane perforations and 10 had considerable number of cases in myringoplasty "waiting list" in a teaching hospital and is very much suitable for district or sub-divisional in size. Thus 86.67% (26/30) gave positive response to the treatment. More importantly overall average percentage reduction in size of perforations was 86.49%. There was some amount of

\* Associate Professor, \*\* Senior Resident, \*\*\* Junior Resident, Department of E.N.T. Govt. Medical College, Amritsar

**TABLE I**  
**Patient and Perforation characteristics**

S.No	Side	Age & Sex	Cause	Size in mm	Site	Time of Development in months
1	R	22M	T	1.5X1.25	AI	1.5
2	L	26F	I	1X2	AI	4
3	R	32F	I	3	AI	36
4	R	45M	I	2X1.5	AI	3
5	L	28F	I	3	AI	36
6	L	30F	I	3	AS	2.5
7	R	53M	I	3	PS	12
8	R	55F	T	1.5	PI	1.5
9	L	52F	T	1	AI	1.5
10	L	50F	I	3	AI	96
11	L	25F	T	2X1	PI	1.5
12	L	32F	I	2	AS	2.5
13	L	32F	I	2	AS	36
14	L	60F	I	1.5	AS	24
15	R	48M	I	1	PI	18
16	L	23M	T	2X1.5	AI	1.5
17	R	60M	T	1.5	PS	3
18	R	32F	T	3X2.5	PS	1.5
19	R	15F	I	3	PI	2.5
20	L	16F	T	2	AS	2
21	L	22F	I	2	PI	12
22	R	32F	T	2.5X3	PI	1.5
23	R	25F	I	2.5	AI	8
24	L	35F	I	2	AI	5
25	R	22F	I	2.5	AS	12
26	L	19M	I	2.5	PS	30
27	L	34F	I	2	PI	36
28	R	23F	I	3	PI	12
29	R	33F	I	2	PI	24
30	L	40M	I	3	AI	24

L- Left R- Right M- Male F- Female T-Traumatic I-Inflammatory

AI-Antero-inferior AS- Antero-superior PS-Postero-superior PI-Postero-inferior

TABLE II

## RESULTS OF TREATMENT

S. No	No. of Application	Evaluation	% Reduction	Status of TM
1	2	C	100%	N
2	4	C	100%	N
3	5	C	100%	T
4	4	C	100%	N
5	5	R	75%	FT
6	5	P	20%	-
7	5	R	90%	N
8	3	C	100%	N
9	2	C	100%	N
10	5	P	25%	-
11	4	C	100%	T
12	5	R	80%	N
13	5	R	80%	FT
14	5	C	100%	N
15	3	C	100%	N
16	4	C	100%	N
17	5	C	100%	T
18	5	R	75%	N
19	4	P	10%	-
20	5	C	100%	N
21	3	P	25%	-
22	5	R	75%	FT
23	5	R	60%	FT
24	5	C	100%	N
25	5	C	100%	N
26	5	R	90%	N
27	5	C	100%	T
28	5	R	75%	FT
29	5	R	75%	N
30	5	C	100%	N

C- Closed      R-Reduced      P- Persistent

N- Normal      T-Tympanosclerotic

FT-Fragile Tissue

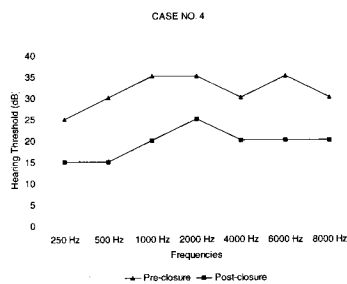


Fig.1: Pre and Post closure Audiogram of Case No 4

There were two more notable features in this study. Firstly the scar tissue in majority (56.67%) of the patients was of normal appearance. Out of the 30 cases 17 had normal appearing scar tissue, 5 had fragile tissue, 4 had tympanosclerotic scar and there were 4 failures. Secondly, no adverse effects of drug were observed in this study.

## DISCUSSION

The healing pattern in perforated tympanic membranes treated by hyaluronic acid has been well described in animal studies on rats as follows<sup>9-10</sup>: - . Initially the perforation becomes covered by a sheet of keratin and hyaluronic acid which appears to relax and orientate the collagen fibres at the margins of perforation. The hypertrophic keratinising squamous epithelium advances within the hyaluronan-keratin cover and closes the perforation ahead of an approaching connective tissue. Three months after the closure hyaluronic acid treated tympanic membrane appear transparent in comparison to the opaque untreated controls.

In the present study the patients showing positive response were 86.67% while in studies by Rivas Lacarte et al<sup>4</sup> and Stenfors<sup>2</sup> the results were 83.3% and 93% respectively. In the study by Stenfors<sup>2</sup> he also did excision of the margin of the perforation before applying hyaluronic acid. In this study another important parameter overall average percentage reduction of size of perforation was 86.49% in two similar studies by Rivas Lacarte et al<sup>4,5</sup> the overall average percentage reduction of size of perforation was 83 ± 26% and 86.5% respectively.

In this study besides the results mentioned above, certain other points were also noted. Perforations of traumatic origin showed a quick response. Those with inflammatory pathology were slow to respond. Even then once the activity started all around the margin of the perforation, healing process used to continue at a good pace.

Again small perforations upto 2 mm in size took on an average less time to close than the larger ones. Although old age patients did show a slow response initially to the treatment, age was not in any way a deciding factor in the final outcome. Scar tissue in significant number of patients (17/30) was of normal appearance. No adverse effects on inner ear like tinnitus, vertigo or otalgia were reported. Some patients reported a sudden bang a few hours after application, probably due to disappearance of covering of sodium hyaluronate.

auditory improvement as well. It ranged from 6-16 dB with an average of 11.61 dB in completely healed cases. A representative pre-closure and post-closure audiogram of Case No. 4 is shown in Fig 1.

## CONCLUSIONS

Sodium hyaluronate is effective in small to medium sized dry, central perforations of tympanic membrane. Surgical closure of tympanic membrane perforations by means of a variety of tissue materials is generally an accepted method. However, the use of sodium hyaluronate has several advantages: This procedure can be performed in a hospital out patient department; it reduces number of cases in myringoplasty "waiting list" in a teaching hospital and is very much suitable for district or sub-divisional hospitals.

## REFERENCES

- 1 Stenfors, L.E., Berghem, L., Bloom, G.D., Hellstrom, S. and Soderberg, O. (1985): Exogenous hyaluronic acid (Healon) accelerates the healing of experimental myringotomies. *Auris Nasus Larynx* 12: 214-5.
- 2 Stenfors, L.E. (1989): Repair of tympanic membrane perforations using hyaluronic acid: An alternative to myringoplasty. *J Laryngol Otol* 103: 39-40.
- 3 Laurent, C., Soderberg, O., Anniko, M. and Hartwig, S. (1991): Repair of chronic tympanic membrane perforations using application of hyaluronan or rice paper prostheses. *ORL J Otorhinolaryng Relat Spec* 53(1): 37-40.
- 4 Rivas Lacarte, M.P., Casasin, T., Pumarola, F and Alonso A. (1990): An alternative treatment for the reduction of tympanic membrane perforations: sodium hyaluronate. A double blind study. *Acta Otolaryngology* 110(1-2): 110-4.
- 5 Rivas Lacarte, M.P., Casasin, T. and Alonso A. (1992): Effects of sodium hyaluronate on tympanic membrane perforation. *J Int Med Res* 20(4): 353-9.
- 6 Kumar, S. and Gupta, A.K. (1995): Closure of persistent central perforation of tympanic membrane using 1% Hyaluronic acid. *IJO & HNS* 47(2): 127-131.
- 7 Lindahl, U and Hook, M. (1978): Glucosaminoglycans and their binding to biological macromolecules. *Ann Rev Biochem* 47: 385-417.
- 8 Camarda, V., Carvelline, M., Pedace, G and Pace, M. (1989): Sodium hyaluronate in the repair of perforations of the tympanic membrane. *Clin Ther* 11(6): 744-54.
- 9 Hellstrom, S., and Laurent, C. (1987): Hyaluronan and healing of tympanic membrane perforation - An experimental study. *Acta Otolaryngology* 442: 54-61.
- 10 Hellstrom, S, Bloom, G.D., Berghem, L., Stenfors, L.E., and Soderberg O. (1991): A comparison of hyaluronan and fibronectin in the healing of tympanic membrane perforations. *Eur Arch Otorhinolaryngol* 248(4): 230-5.

### Address for correspondence

Dr. (Mrs.) Kulwant Kaur,  
C/o Pannu Eye Hospital  
236- Medical Enclave,  
Circular Road, Amritsar (Pb) 143001