

REFERENCES

1. Belmont MJ, Behar PM, Wax MK. Atypical presentations of actinomycosis. *Head Neck* 1999;21:264–8.
2. Stewart MG, Sulek M. Pediatric actinomycosis of the head and neck. *Ear Nose Throat J* 1993;72:614–9.
3. Rippon JW. *Medical Mycology*. W.B. Saunders: Philadelphia; 1974. p. 13–28.
4. Yenson A, DeFries HO, Deeb ZE. Actinomycotic osteomyelitis of the facial bones and mandible. *Otolaryngol Head Neck Surg* 1983;91:173–6.
5. Daamen N, Johnson JT. Nasopharyngeal Actinomycosis: A Rare Cause of Nasal Airway Obstruction. *Laryngoscope* 2001;114:1403–5.
6. Chiang CW, Chang YL, Lou PJ. Actinomycosis imitating Nasopharyngeal Carcinoma. *Ann Otol Rhinol Laryngol* 2000;109:605–7.
7. Sobol SE, Samadi DS, Wetmore RF. Actinomycosis of the temporal bone: a report of a case. *Ear, Nose and Throat Journal* 2004.
8. Bhargava D, Bhusnurmath B, Sundaram KR, Raman R, Al Okbi HM, Al Abri R, et al. Tonsillar actinomycosis: a clinicopathological study. *Acta Trop* 2001;80:163–8.
9. Yadav S. Actinomycosis of tonsil masquerading as tumour in a 12–year old child. *Int J Pediatr Otorhinolaryngol* 2002;63:73.
10. Pransky SM, Feldman JI, Kearns DB, Seid AB, Billman GF. Actinomycosis in obstructive tonsillar hypertrophy and recurrent tonsillitis. *Arch Otolaryngol Head Neck Surg* 1991;117:883–5.
11. Aydin A, Erkilic S, Bayazit YA, Kocer NE, Ozer E, Kanlikama M. Relation between actinomycosis and histopathological and clinical features of the palatine tonsils: a comparative study between adult and pediatric patients. *Rev Laryngol Otol Rhinol Bord* 2005;126:95–8.
12. Bennhoff DF. Actinomycosis: Diagnostic and therapeutic considerations and a review of 32 cases. *Laryngoscope* 1984;94:1198–217.

Address for Correspondance

Dr. Sanjeev Mohanty,
SRMC and RI, Porur, Chennai-600 116, India.

ORBITAL APEX SYNDROME DUE TO MUCORMYCOSIS CAUSED BY RHIZOPUS MICROSPORUM

Suman P. Rao, Kalpana Rajiv Kumar, V. R. Rokade, Vikram Khanna, Chitra Pal

ABSTRACT: *The incidence of fungal rhino sinusitis has increased in recent years in a tropical country like India. A case of Orbital Apex Syndrome due to mucormycosis caused by Rhizopus microsporum fungus is reported in a 65 year old male diabetic patient. The disease though invasive with early diagnosis and treatment, has a good prognosis with a favorable outcome.*

Key Words: *Orbital apex, Mucormycosis*

INTRODUCTION

Fungal rhino sinusitis is being recognized and reported with increasing frequency over the last two decades worldwide. It occurs in two distinct forms - the fulminant invasive disease, which is predominantly seen in patients with some form of immunosuppression and the chronic fungal rhino sinusitis in apparently healthy hosts. Apart from the species of *Aspergillus* which is isolated from a majority of such cases, dematiaceous hyphomycetes, *Pseudoallescheria boydii*, *Candida*, *Fusarium*, *Hyalophamycetes* and *Zygomycetes* are also reported. The changing terminology for mucormycosis and of its causative agents has complicated data retrieval and confused clinicians. All the agents of mucormycosis belong to the order Mucorales.

The classification of the Genera that contain the agents of mucormycosis in man is:

-Zygomycetes (class)

Mucorales (order)

Mucorales order has six families.

Family	Genus
1. Cunninghamhamiaceae	Cunninghamhamella
2. Mortierellaceae	Mortierella
3. Mucoraceae	Rhizopus, Absidia, Rhizomucor, Mucor, Apophysomyces
4. Saksenaceae	Saksenaea
5. Syncephalastraceae	Syncephalastrum
6. Thamnidaceae	Cokeomyces.

Pathologically, mucormycosis is characterized by vascular invasion with hyphae, infarction and necrosis of tissue and by an acute or subacute course. Because mucormycosis is encountered as a secondary disease or an opportunistic infection, the distribution of the various clinical forms is based on predisposing factors rather than age, sex, race or geography. Based on histopathological findings, five categories of fungal rhinosinusitis disorders are recognized, each having characteristic presentation. The two broad categories are Invasive and Non-invasive. The tissue invasive fungal rhinosinusitis can be of 3 types: Acute necrotizing, fulminant fungal rhinosinusitis, Chronic Invasive fungal rhinosinusitis and Granulomatous Invasive (Indolent) fungal rhinosinusitis. The non-invasive category are of 2 types: fungal ball (sinus mycetoma) and AFS (Allergic fungal sinusitis).

CASE REPORT

A 65-year-old male patient presented with history of right-sided facial pain and numbness for 8 days. Pain in right eye and periorbital region for 5 days. Patient was diagnosed to be hypertensive and started on Amlodipine. On examination there was tenderness over right maxillary sinus. Diagnostic nasal endoscopy showed mucopus in the right maxillary ostium and edematous mucosa over the right uncinate process. Diagnosis of right acute maxillary sinusitis was made and patient was put on Ciprofloxacin, anti-inflammatory and anti-histamines. However, pain persisted and patient was admitted 6 days later with worsening of symptoms. He also developed cellulitis over the right cheek, edema of eyelids, axial proptosis, chemosis of conjunctiva and restriction of extra ocular movements (right eye). There was no evidence of cavernous sinus thrombosis. The patient was diagnosed to be diabetic and was put on Insulin and Cefotaxim 1g IV bd ECG showed sinus arrhythmia and patient was put on Tablet Alupant. 2 D Echo was normal. Hematological investigations revealed Hb 14.5 g%, WBC 9800 cells/mm³ L23 N77, chest X-ray was normal. CT Scan Para nasal sinuses showed isodense, non-enhancing soft tissue swelling in Right maxillary sinus, Right ethmoid sinuses, in Right nasal cavity and in right retro orbital region with proptosis. Mucosal thickening was evident in right sphenoid sinus. [Figures 1 and 2] The patient was diagnosed as chronic invasive fungal sinusitis with Orbital Apex Syndrome. Repeat Diagnostic Nasal endoscopy showed inflamed uncinate process (Rt.) with absence of pus. With conservative management and control of diabetes mellitus and hypertension, the cellulitis of the cheek started localizing and proptosis reduced, suggesting that the infection may have been bacterial initially and the fungus an opportunistic invader due to uncontrolled diabetes mellitus.

The patient was operated by FESS. The uncinate process was atretic. There was fungal debris in the maxillary *antrum*, in

the nasal cavity and anterior ethmoid with erosion of the anterolateral wall of the maxilla. In addition polypoid mucosa was removed from the *anterior* as well as posterior ethmoid. The lamina papyracea was intact. There was no neoplastic growth in the antrum or the ethmoid. The fungus naturally widened the maxillary ostium. The specimen was sent for smear, culture and histopathological examination.

Histopathology—mucormycosis

Micro biology- Mucor (Rhizopus microsporum) [Figure 3] KOH mount: revealed presence of broad aseptate hyphae.

Fungal culture was done on Sabourad's dextrose agar by incubating at 25° C Growth was observed within 3 days of incubation. Dense cottony fluffy growth was observed which was initially white and then became grey. Lactophenol cotton blue mount of the fungus showed the presence of aseptate hyphae, rhizoids and sporangia containing brown spores. The isolate was identified as Rhizopus microsporum.

Post operatively [Figure 4], the patient was put on Ciprofloxacin and insulin was continued. He showed dramatic improvement, with the cellulitis and proptosis reducing further and nasal irrigation showing little or no debris. But as the microbiology and Histopathology report came as fungal sinusitis, the patient was started on amphotericin - B Injection in dose of 1.5 gm IV on alternate days for 2 weeks. Haematological and renal profile along with other vital parameters were monitored

DISCUSSION

Mucormycosis is a fulminant and often fatal mycotic infection in human beings. It occurs in poorly controlled diabetes mellitus with keto acidosis, leukemia, lymphoma, severe burns, renal diseases, carcinoma, severe cachexia, profound dehydration septicemia in heroin addicts, children with severe sinusitis, immuno suppressed patients, recipients of renal transplants and supraphysiological doses of adrenal corticosteroids, azathioprine, leukopenics. The underlying disease influences the portal of entry and poorly controlled diabetes mellitus is the major condition in Para nasal infections. A review of predisposing factors in 179 cases of Para nasal sinus mucormycosis found that 126 patients had diabetes mellitus and only 8 had no known underlying disease (Kyonchun). These fungi are found almost ubiquitously in soil, decaying vegetables, seeds, fruits, composite piles, animal excreta and old bread. The fungus invades the wall of the blood vessels, causing mechanical and toxic damage to the intima leading to thrombosis, later it invades the lymphatics and veins. Mucormycosis starts in the nose and Para nasal sinuses and spreads to the eye via the angular vein, lacrimal or ethmoid vessels as well as direct extension from the

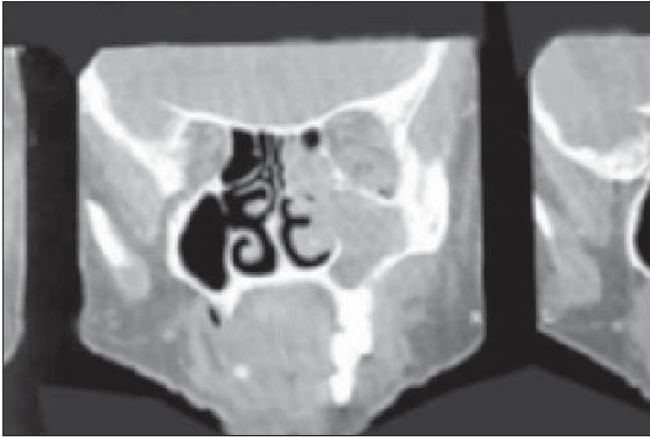


Figure 1: CT Scan of mucormycosis in the maxillary sinus

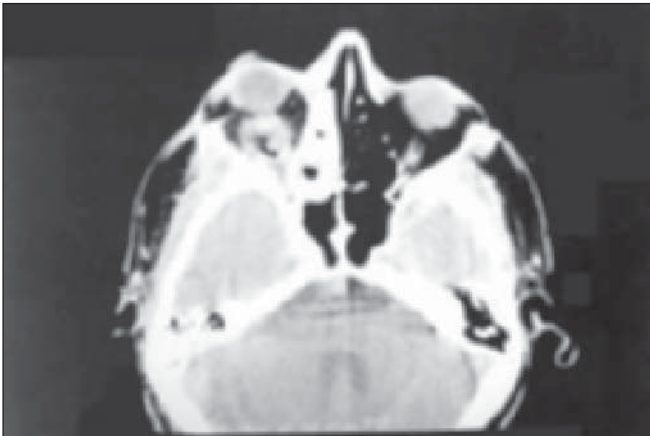


Figure 2: CT Scan of mucormycosis in the orbital apex

paranasal sinuses. Intracranial involvement occur from invasion by way of superior orbital fissure, ophthalmic vessels, cribriform plate and not uncommonly, through carotid artery. In such patients MRI has the advantage of detecting early vascular and intracranial invasion. In the Orbital apex syndrome the prognosis is good if treated early. There is mucosal invasion and hence radical debridement and anti fungal therapy is the treatment. Progression of the disease results in loss of corneal sensation, sluggish or absent pupillary response to light, visual blurring retinal pallor, exophthalmos, complete ophthalmoplegia and with occlusion of the retinal and ciliary artery and blindness. Also, numbness of the infra orbital skin (damage to infra orbital branch of the Vth cranial nerve), with skin necrosis haze in the vitreous humor (invasion of the globe) superior extension from the ethmoid sinus crossing the dura into the frontal lobe causing obtundation may occur. Sphenoidal sinus extension, thrombosis of cavernous sinus or carotid - cavernous fistula, infection of VIIth cranial nerve (facial palsy) and temporal lobe, cerebral infarction, sudden catastrophic loss of cerebral function may ensue. Death in coma is usual. Rare manifestation of mucormycosis originating in para nasal sinuses include extension along the sphenoid ridge into the middle ear,



Figure 3: Fungal culture in KOH Mount and Sabourads agar

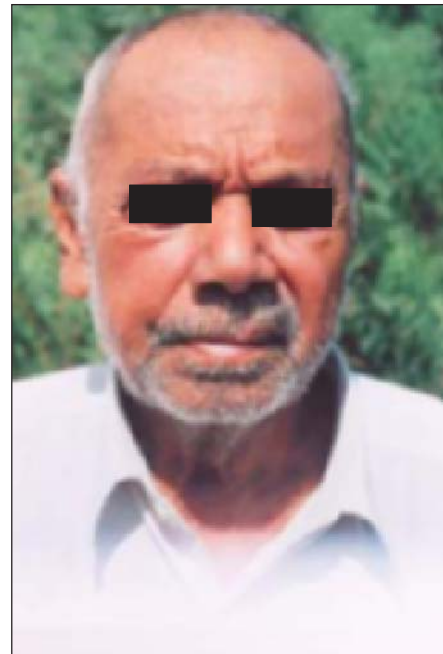


Figure 4: Post-operative photograph of patient

haematogenous, dissemination to the lung, or an indolent course, extending over many weeks. Ordinarily, death occurs in untreated cases within 4 weeks of onset. The other clinical manifestations of mucormycosis include pneumonia, skin and wound mucormycosis. However, rhinocerebral disease is the commonest, with the rhino - orbito - cerebral type having the highest mortality. The rhinomaxillary type runs a benign course without central nervous system involvement.

CONCLUSION

Mucormycosis is usually encountered as a secondary disease or an opportunistic infection due to numerous predisposing factors; commonly uncontrolled Diabetes Mellitus in the Orbital Apex syndrome, the prognosis is good, with prompt control of the predisposing factor and early management by radical debridement and antifungal therapy.

ACKNOWLEDGEMENT

We acknowledge the guidance given by Dr. B. M. Hemashettar (Former Professor in Microbiology-J. N. Medical College, Belgaum) and Dr. Padhye (C. D. C. Atlanta U.S.A) for confirming the identification of the fungus.

REFERENCES

1. Kyonchun Mucormycosis.
2. Glass JD. Ocular manifestations of acute mucormycosis. Arch Ophthalmol 1961;65:226-37.
3. Lowe JR, Hudson WR. Rhinocerebral phycomycoses and Internal carotid artery thrombosis. Arch Otolaryngol 1975;101:100-3.
4. Rippon JW. The pathogenic fungi and the pathogenic Actinomycetes Mucormycosis in medical mycology. W.B Saunders: Philadelphia; 1974. p. 430-47.
5. Yadav ST, Singh J, Ranga RK, Sen R. Mucormycosis. Indian J Otolaryngol Head Neck Surg 2003;55:208-10.
6. Grewal RS, Khurana S, Aujla KS, Goyal SC. Incidence of fungal Infection in chronic maxillary sinusitis. Indian J Pathol Microbio 1990;33:339-43.
7. Chakrabarti A, Sharma SC, Chander J. Epidemiology and Pathogenesis of Paranasal Sinus mycoses. Otolaryngol Head Neck Surg 1992;107:745-50.
8. Panda NK, Sharma SC, Chakrabarti A, Mann SB. Paranasal Sinus Mycoses in North India. Mycoses 1998;41:281-6.

Address for Correspondance

Dr. Suman P. Rao
T-5, RH-2, Sector 9, CBD Belapur,
Navimumbai – 400 614,
India.

PRIMARY LINGUAL TUBERCULOSIS PRESENTING AS COLD - ABSCESS TONGUE: A CASE REPORT

S. K. Vishwakarma, Shraddha Jain, Manisha Gupta

ABSTRACT: Oral manifestation of tuberculosis is uncommon Tongue is the most common oral site of involvement, where the presentations are varied. Here we report a case of primary lingual tuberculosis with an unusual presentation as a cold abscess.

Key Words: Lingual tuberculosis, cold-abscess

INTRODUCTION

Oral manifestation of tuberculosis is rare with an incidence of 1.4%. It could be primary tuberculous infection or secondary to pulmonary disease. Soft tissues are more frequently involved than bony structures, with the mandible more frequently involved than the maxilla. Of the oral soft tissues affected, the tongue is the most common site. *Morgagni* (1761) described first case of lingual tuberculosis. Other sites include the floor of mouth, soft palate, gingiva, lips, and hard palate.

Primary tuberculous infection may occur at extrapulmonary sites like gastro-intestinal tract, oropharyngeal lymphoid tissue and skin. These less common portals of entry are associated with primary complexes, similar to those of the pulmonary form, developing at these sites and in the corresponding draining nodes.

Secondary tuberculous infection of the oral cavity arises in a previously *sensitized* individual and is associated with pulmonary lesions.

We report a case of primary lingual tuberculosis with an unusual presentation.

CASE REPORT

A 13 year old female presented in ENT OPD of GTB Hospital with complaints of Fever for 3 months and a swelling over tongue for 15 days. Fever was continuous, low grade, with evening rise of temperature and associated with complaints of anorexia, malaise and weight loss which did not respond to medical treatment. There was no history of cough or night sweats.

On clinical examination, there was a swelling over the tongue