

# SPONTANEOUS CSF OTORRHOEA - PRESENTING AS CONDUCTIVE DEAFNESS

Rajeev Pachauri<sup>1</sup>, Smita Nagaonkar<sup>2</sup>, M. V. Kirtane<sup>3</sup>

**ABSTRACT :** Spontaneous CSF otorrhea specially in older age is a rare condition. Congenital inner ear malformation is one of the commonest causes in pediatric age group and either because of trauma or spontaneously it comes out into middle ear. In pediatric age group usual presentation is with history of meningitis while adult patients may present as watery discharge from nose or ear. This is a case, presented with conducted deafness with negative middle ear pressure. Grommet was put presuming secretory otitis media but B2-transferrin levels of the secretion confirmed it as a CSF otorrhea. He was operated with post aural transmastoid approach. The defect was sealed in layers. Patient is in regular follow up is asymptomatic and without any recurrence.

**Key Words :** Spontaneous, Ventilation, Dehiscence, Arachnoid granulation.

## INTRODUCTION

Leakage of cerebrospinal fluid through the temporal bone is usually accidental, iatrogenic or due to infection or neoplasm. There may, however, be not obvious cause, and then the CSF leak is known as being spontaneous. It's a rare condition and most commonly present either childhood or in older age.

Congenital labyrinthine malformation where free communication between the subarachnoid and perilymphatic spaces allow CSF flow from internal auditory canal to oval and round window and whenever either because of trauma or spontaneously it comes out into middle ear cavity through round or oval window. Clinically it presents with history of recurrent meningitis. Very few patients present with spontaneous CSF otorrhea at an older age, between 45 and 70 years. Dural and mastoid plates defects specially in tegmen tympani with and without herniation of brain tissue (Encephalocele) and arachnoid tissue (meningocele) results into CSF leak. The usual presentation is features of the middle ear effusion. Valtonen H et al<sup>1</sup> reported 5 cases of spontaneous CSF otorrhea with tegmental defect and recommend B2-transferren testing and combined mastoid and middle fossa approach for repair. Rudolf and Jan W<sup>2</sup> reported 4 cases of spontaneous CSF otorrhea repaired with transmatoid and minicraniotomy approach. This is a case of spontaneous CSF otorrhea, presented as conductive deafness. Transmastoid approach was used with successful outcome.

## CASE REPORT

A 52 year old man was first seen in some other hospital on February 2001 with bilateral conductive deafness of few months duration. Audiogram showed bilateral

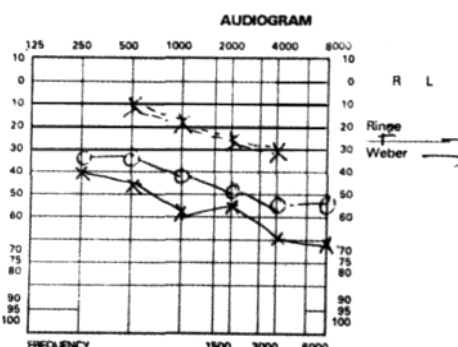


Fig I: Audiogram showing bilateral congenital deafness.

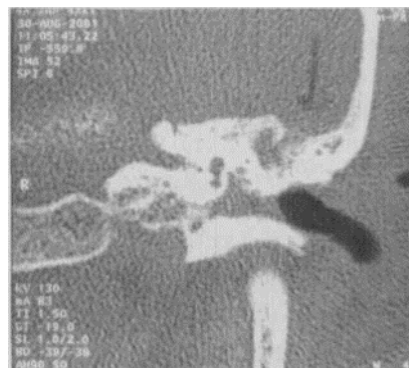

Fig II: CT cisternography showing defect in tegmen with opacity in mastoid air cells and middle ear.

<sup>1</sup>Clinical Ass., <sup>2</sup>Clinical Ass., <sup>3</sup>Consultant & Head of the department, P.D. Hinduja National Hospital & Medical Research Center, Veer Savarkar Marg, Mahim, Mumbai 400 016

conductive deafness (Fig.I) with bilateral negative pressure on impedance test.

On clinical examination clear fluid was seen in left ear. The otorrhea followed the insertions of a ventilation tube on left side presuming serous otitis media. There had been no prior history of head trauma, infection or ear surgery. Patient was referred to us and the examination showed a T-tube surrounded by copious amount of watery discharge which was pulsatile in nature. As proof, the patient brought a 5 ml sample of clear fluid, which contained 20 mg/dl glucose. B2 transferrin level was strongly positive for CSF (5.12 mgs/dl). A plain CT scan revealed a large defect in tegmen tympani with fluid filled mastoid air cells and middle ear spaces (Fig-II).

Patient was taken for surgery cortical mastoidectomy was performed by usual post aural approach which demonstrated a large encephalocele from the bony defect in the tegmen overlying the antrum in epitympanum. A gush of clear fluid could be seen coming out through the defect along the encephalocele.

The defect was first filled with fat followed by fascia lata taken from left thigh. Grommet was removed and tympanic membrane defect was sealed with fat graft. Lumbar puncture was done after finishing the surgery. Patient was kept in hospital for 4 days with bed rest & intravenous antibiotic were given for three days. Patient is in regular follow up without any symptoms and recurrence.

## DISCUSSION

Spontaneous CSF otorrhea is a rare condition and can be classified into two categories according to age. In childhood it is due to congenital deformities of labyrinths. Perilabyrinthine pathway of leak have been reported as widened fallopian canal. Hyrtl's fissure and possibility of leak via the petromastoid canal along the subarcuate artery<sup>3</sup>. Presentation is usually with recurrent attack of meningitis in hearing impaired child.

In adult, it is almost always due to a bony and dural defect mainly in tegmen tympani. Different studies have been conducted which showed more than 20% bony dehiscence in the tegmen in selected temporal bones<sup>4,5</sup>. The pathogenesis remain obscure that why only very few patients present with CSF leak. The pulsatile CSF pressure progressively drives the dura through the defects and

because of one way valve system and blocking action of brain tissue, the dura cannot return back to normal position leading to progressive weakness and rupture of dura leading to spontaneous CSF leak<sup>6</sup>. Increased intracranial pressure, mastoiditis and age related dural weakness have been postulated as contributing factors for CSF otorrhea<sup>4</sup>.

In older people, the arachnoid granulation (Pacchioni's granulation) which are meant for resorption of CSF, increases in size and exhibit a particular propensity to invade bone. This feature and pulsatile CSF pressure inside these arachnoid granulation produces bone erosion and thus a communication with mastoid air cells leading to spontaneous CSF otorrhea<sup>7</sup>. But so far, however, arachnoid granulation in temporal bone have only been reported on the posterior fossa plate, whereas spontaneous CSF leaks mainly involves middle cranial fossa<sup>4,7</sup>. Little pinholes indicating pressure marks of arachnoid granulation have also been observed in the middle fossa surface in 22% of dried temporal bone specimen<sup>4</sup>, correlates with high incidence in middle cranial fossa proves the finding suggested by Gacek<sup>7</sup>. Arachnoid granulation have also been seen in the roof of the sphenoid and ethmoid sinuses where they have been associated with spontaneous CSF rhinorrhea<sup>8</sup>. Osteoradionecrosis of the temporal bone following radiotherapy for head and neck malignancies can lead to CSF otorrhea by exposing to chronic infection or direct necrosis of tissue leading to dehiscence<sup>9</sup>.

In contrast to the pediatric age group, only 20% of the adults have a history of meningitis<sup>4</sup>. Middle ear effusion, resulting in clear discharge after myringotomy is common presentation. Since there is no pathology in middle ear ventilation so pressure should be normal. In this case impedance test showed marked negative pressure that's why myringotomy and ventilation tube was put presuming secretory otitis media.

Diagnosis largely depends on suspicion specially in children. Identification of B2 - transferrin in sampled fluid is currently biochemical investigation of choice with high specificity<sup>10,11</sup>. Contamination by pus or blood does not invalidate this test unlike glucose estimation. B2 transferrin is a protein produced by neuramidase activities in the brain, found only in CSF, aqueous humour and perilymph, this infact makes it a valuable test in the suspected CSF leak<sup>10</sup>. In this case B2 transferrin level was more than three times of normal range. High resolution CT with and without using contrast may locate defects

of the tegmen plate which may be associated with soft tissue density in the mastoid. The soft tissue density may indicate either granulation tissue or herniating brain tissue (encephalocle). MRI does not have added advantage over CT scan, since herniating brain tissue is non functioning and hence does not show features of normal brain tissue<sup>11</sup>. In this case HRCT of temporal bone by using water soluble non ionic iodinated contrast medium (omnipaque) showed a well defined defect in tegmen tympany with soft tissue bulging representing encephalocele. But overall systematic application of any form of cisternography in the diagnostic workup of a spontaneous CSF leak is not advocated until unless needed<sup>12</sup>. A positive B2-transferrin test justifies a surgical exploration, for the condition in life threatening and to reduce complications<sup>4</sup>.

In this case post aural approach was used. Cortical mastoidectomy extending upto attic with intact canal wall was done. Defect could be seen with bulging denta. Cauterization of encephalocele followed by sealing the defect in layers with fat and fascia lata supported by gelfoam was done. If the defect involves the posterior fossa plate or the tegmen overlying the mastoid, treatment then consist of a canal wall up mastoidectomy with fat obliteration of the cavity<sup>2</sup>. A middle fossa approach seems indicated only when : A recurrence after attempted closure from the mastoid, a very large tegmen tympani defect, multiple defects or the defect in the anterior in inaccessible part of the tegmen with good hearing<sup>2</sup>. A transmastoid repair with mini craniotomy technique is indicated when the defect is either questionable on CT scan or localized in the posterior part of the tegmen tympani, which is accessible from the mastoid- if required by including removal of the incus and malleus head and subsequent incus interposition<sup>13</sup>.

Transmastoid approach for tegmen defects does not necessarily include the shaping of a mini craniotomy like in this case. A piece of septal cartilage or a mastoid cortical bone chip can be tucked intracranially from the mastoid side of the defect, like a button hole<sup>6</sup>.

Traumatic or iotrogenic CSF leaks are known to have a higher inclination towards spontaneous healing. On the other hand, it has been shown repeatedly that spontaneous CSF leaks have a particular tendency to recur<sup>4</sup>. Thus edition of a minicraniotomy helps considerably in the performance of a transmastoid repair of spontaneous CSF

leaks<sup>2</sup> and it avoid the morbidity of middle fossa craniotomy<sup>13</sup> recommended if a tegmen defect is exhibited by CT scan<sup>4</sup>. Post operative CSF drainage by lumbar puncture or drain can act as a safety measure depends upon size and site of defect. Yet the very need for post operative lumbar drainage may be questioned. In this case intravenous antibiotic were given for couple of days followed by oral antibiotic for one week. The use of antibiotic prophylaxis is controversial and not routinely indicated<sup>11</sup>.

## CONCLUSION

Spontaneous cerebrospinal fluid otorrhea in older age is a rare entity. Difficult to diagnose unless after insertion of ventilation tube or when it present as otorrhoea. In this case, since it was present with negative middle ear pressure, initially he was treated as secretory otitis media. Biochemical examination specially B2-transferrin, CT scan with or without using contrast are most important diagnostic modalities to find out suspected CSF leak. Repair with minimal exposure avoid morbidity and post operative sequelies.

## REFERENCES

1. Valtonen H, Geyer C, Tarlov E, Heilman C, Poe D. Tegmental defects and cerebrospinal fluid otorrhea. *Orl; Journal of Oto-Rhino-Laryngology and its related species* 2001; 63 (1) : 46-52.
2. Rudolf Kuhweide, Jan W. Casselman. Spontaneous cerebrospinal fluid otorrhea form a tegmen defect: transmastoid repair with minicraniotomy. *Ann Otol rhinol laryngol* 1999; 108: 653-658.
3. Gacek RR, Leipzig B. Congenital cerebrospinal otorrhea. *Ann otol rhinol laryngol* 1979; 88: 358-65.
4. Ferguson BJ, Wilkins RH, Hudson W. spontaneous CSF otorrhea form tegmen and posterior fossa defects. *Laryngoscope* 1986; 96: 635-44.
5. Lang DV. Macroscopic bony deficiency of the tegmen tympani in adult temporal bones. *J Laryngol Otol* 1983; 97 : 685-8.
6. Neely JG, Neblett CR, Rose JE. Diagnosis and treatment of spontaneous cerebrospinal fluid otorrhea. *Laryngoscope* 1982;92:609-12.
7. Gacek RR. Arachnoid granulation cerebrospinal fluid otorrhea. *Ann otol rhinol laryngol* 1990; 99: 854-62.
8. Kaufman B, Nulsen FE, Weiss MH, Brodkey JS, White RJ, Sykora GF. Acquired spontaneous non traumatic normal pressure cerebrospinal fluid fistulas originating from the middle fossa. *Radiology* 1977; 122 : 379-87.
9. Sikand A, Longridge N. CSF otorrhea complicating osteoradionecrosis of the temporal bone. *Journal of Otolaryngology* 1991 ; 20(3) : 209-11.

10. Skedros DG, Cass SP, Hirsch BE, Kelly RH. B2 transferrin assay in clinical management of cerebral spinal fluid and perilymphatic fluid leaks. Journal of otolaryngology 1993; 22(5) : 341-4.
11. McGuirt WF, Stool SE. Cerebrospinal fluid fistula: the identification and management in pediatric temporal bone features. Laryngoscope 1995 ; 105 (4) : 359-64.
12. Gacek R R. Evaluation and management of temporal bone arachnoid granulation. Arch Otolaryngol Head and Neck surgery 1992 : 118: 327-32.
13. Adkins WY, Osguthorpe JD. Mini craniotomy for management

of CSF otorrhea from legmen defect. Laryngoscope ; 1983: 93:1038-40.

***Address for Correspondence :***

Dr. Rajeev Pachauri

C/o Dr. M. V. Kirtane

Consultant & Head ENT department, Dept. of ENT & Head & Neck Surgery, 1<sup>st</sup> Floor, Old Building, P.D. Hinduja National Hospital & Medical Research Center, Veer Savarkar Marg, Mahim, Mumbai 400 016