

Staghorn rhinolith in nasopharynx: an unusual case

Yasmeen Aziz · Jitender Chauhan · S. A. Hasan · S. F. Hashmi

Abstract The present case report is of a young female with complaint of foul smelling nasal discharge normal anterior rhinoscopic findings and an irregular mass on digital palpation of nasopharynx, confirmed by NCCT and extracted through oral route

Keywords Rhinolith · Nasopharynx

Introduction

A nasal foreign body is not unusual, particularly among children, but true rhinoliths are rare indeed. A rhinolith [1] is a rock, which forms in the nose. It occurs from the solidification of mucus and nasal debris: By mineral salts, calcium, magnesium phosphate and carbonate, and it leads to unilateral obstruction of the nasal airways followed by inflammatory changes of the nasal mucus membrane and Para nasal sinuses. This inflammatory process may lead to a purulent form with complication; intracranial propagation & dacryocystitis.

Y. Aziz¹ · J. Chauhan² · S. A. Hasan³ · S. F. Hashmi⁴

¹Senior Resident

²Junior Resident

³Professor

⁴Reader

Department of ENT,
JNMC Aligarh
India

Y. Aziz (✉)

G-1, Sagheera Apartment

Medical road

Aligarh - 202 002

e-mail id: lazeera@bsnl.in; lazeera@yahoo.co.in;
hammaad2001@hotmail.com

Tel: +91 - 9837165138, +91 - 9319077803, 0571-3290695,
0571-3208447

Rhinoliths are considered endogenous if they arise around normal body material [2]. These are closely related to the nasal region, such as misplaced teeth, sequestra, or dried blood clots that become lodged in the nasal cavity and form the nuclei of crystallization. Rhinoliths are considered exogenous if nonhuman material or objects, usually unrelated to the nose and surrounding tissues such as beads, buttons, fruit stones, cotton wool, or impression material, gain access to the nasal cavity and act as the nidus for precipitation.

Case report

A 30-year-old female presented in outpatient department of Otorhinolaryngology of Jawaharlal Nehru, Medical College, AMU. She complained of blood stained, foul smelling discharge from her left nostril, with increasing pain over left side of face. Intra-oral inspection and on anterior rhinoscopy apart from fetor no abnormality was found. Palpation of nasopharynx revealed a solid mass in nasopharynx. CT scan revealed a radio opaque shadow of a mass measuring around 3 × 1.5 cm (Figs. 1, 2) in the nasopharynx. The stag horn shape rhinolith of size around 3 × 1.5 cm was delivered through the nasopharynx. (Fig. 3) It was brownish black in colour, with rough surfaces, and was extremely foul smelling. Two weeks later all examinations including indirect nasopharyngoscopy, showed no sign of foreign material or inflammation.

Discussion and conclusion

Foreign bodies are not unusual in the head and neck region, particularly in body orifices. Some are lodged by the accidents; others mostly inserted by hand, mostly in children. The variety of the retrieved objects (and the length of time they are tolerated by patients) is amazingly wide: Impressions materials tire valve, eraser, button, battery, and wood-screw. Most frequent are beads, seeds, and fruit stones.

On the other hand, true rhinoliths are exceedingly rare. They are the result of partial or complete encrustation of an intranasal foreign body by mineral salts precipitation onto them. The cause and pathogenesis of rhinoliths are not fully understood. It is thought that the predisposing factor is the entry and lodgment of a foreign body. However, other very important factors are needed, since only a tiny fraction of the foreign bodies become petrified.

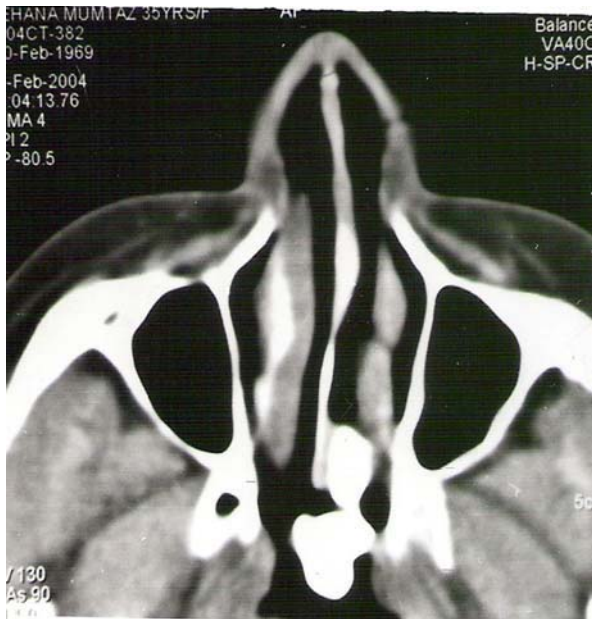


Fig. 1 CT Scan – axial Section showing rhinolith in nasopharynx

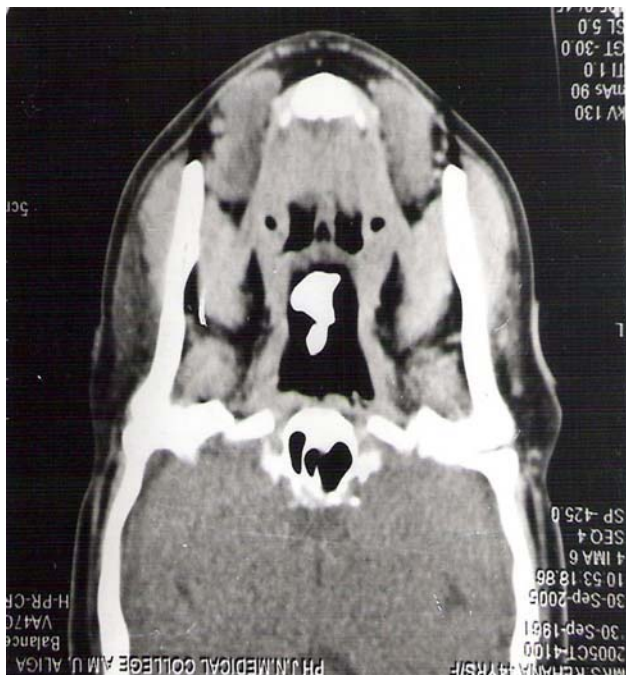

Fig. 2 CT Scan – coronal section showing rhinolith in nasopharynx

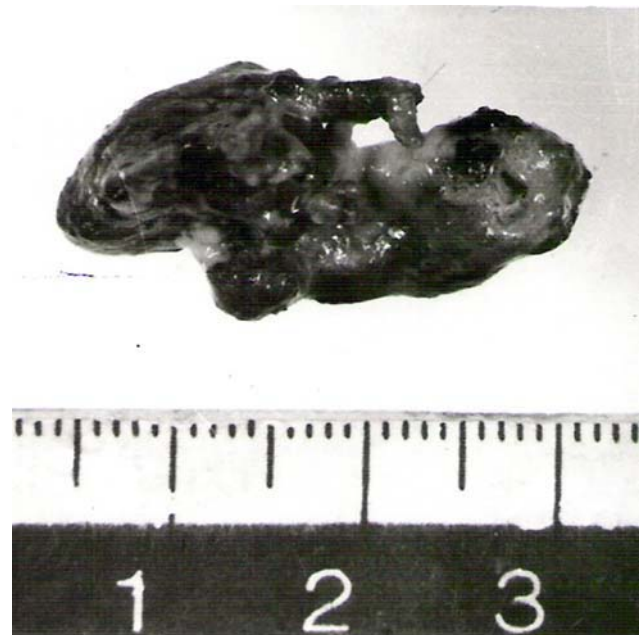

Fig. 3 Staghorn shaped rhinolith

It is necessary for the foreign material to evoke sup-puration following acute or chronic inflammation. Further requirements are precipitation of salts (mostly calcium and magnesium), obstruction and stagnation. The latter two prerequisites were underlined by Worgans [3] case, which may shed some light on the origin of endogenous rhinoliths. In a unilateral choanal atresia and subsequent infections, inflammations and fibrosis eventually produced a rhinolith, probably secondary to choanal atresia. Air currents, which probably help concentration and crystallization, are also needed. This was emphasized by Bowerman [4] who pointed out that maxillary calcified bodies (antroliths) are extremely rare although foreign bodies in the antra are not uncommon. Time seems to be an important factor it is not known how long is required for a foreign material to become encrusted, but most authors speculate in years. The symptoms at the time of lodgment are usually minor and are long forgotten by the patient. However, sooner or later most rhinoliths will make their presence known, although chance findings sometimes occur. The most frequent symptoms and signs after a latent period are unilateral nasal discharge (blood stained) obstruction and a feeling of blockage, epistaxis, slight to moderate swelling, headache, sinusitis, epiphora, and perforation of nasal.

The symptoms at the time of lodgment are usually minor and are often long forgotten by the patient as in our case. The most frequent symptoms and sign after a latent period are unilateral nasal discharge (often blood stained) obstruction and a feeling of blockage, epistaxis, slight to moderate swelling, headache, sinusitis, epiphora (rare), and perforation of the nasal septum or palate.

The diagnosis of rhinolith may be suspected if there is a possible history of a foreign body, although this is rarely the case. Clinical findings and radiographs showing a calcified mass should raise the suspicion of a rhinolith. Computed Tomography can be very useful. The differential diagnosis includes space-occupying lesion in the nose that gives the picture of a calcified mass on radiography, such as calcified nasal polyp, ossifying fibroma, odontoma, osteoma, osteosarcoma, chondroma, chondrosarcoma, or calcifying angiofibroma.

The significance of computed tomography of paranasal sinuses was confirmed in coronal lines, as the most valid radiological analysis, which provides adequate diagnosis, differential diagnosis and helps in making the decision on

surgical treatment. Surgery is obligatory and in most cases it is endonasal endoscopy. Bigger nasal stones progressing into the surrounding anatomic structures are treated using lateral rhinotomy and Caldwell luc.

Reference

1. Med. Pregl. 2004 Sept-Oct; 57(9–10):493–497
2. Andras Rhinolith Annal Otorhinol. Laryngol 106:1997
3. Worgan D (1966) Unilateral Choanal Atesia Associated with a Rhinolith. J Laryngol Otol 86:418–421
4. Bowerman JE (1969) The Maxillary Antrolith. J Laryngol Otol 83:873–882