

# ENDOSCOPIC TRANSCANAL MYRINGOPLASTY - A STUDY

Anoop Raj<sup>1</sup>, Ravi Meher<sup>2</sup>

**ABSTRACT :** *Aim of this study was to evaluate the role of rigid endoscope in the management of dry central perforation of the tympanic membrane and to compare the results of endoscopic myringoplasty with that of conventional myringoplasty using microscope. In endoscopic group there was 90% graft uptake rate as compared to 85% in microscopic group. The results of endoscopic myringoplasty are comparable to the conventional myringoplasty done under operating microscope and there is no significant difference between the gain in A-B gap in either group*

## INTRODUCTION

Till now myringoplasty was being done under operating microscope that has its own limitations. With the introduction of the endoscope into other branches of surgery, there have been attempts at its utilization in otology. We already know the diagnostic and teaching role of the endoscope for examining the tympanic membrane and the ear canal. Very few studies have been done previously in which endoscopes were used in ear surgery. So a study was conducted in which endoscopes were used to do myringoplasty.

## MATERIALS AND METHODS

A total of 40 patients were selected having central perforation of tympanic membrane. These 40 patients were divided into two equal groups of 20 patients each. All the patients underwent myringoplasty under local anaesthesia. In the first group, endoscope was used and in the second group microscope was used to do myringoplasty. Tragal perichondrium was used as a graft material. The patients were kept in follow-up for 10 weeks.

The intactness of graft was assessed and postoperative pure tone audiograms were compared with preoperative pure tone audiograms.

Techniques : The rigid endoscopes (0,30,70 degree and 4mm diameter) were passed through the perforation (transcanal route) to visualize the status of ossicles, eustachian tube orifice and the status of middle ear mucosa. Also the presence of any granulations and cholesteatoma flakes were noted and if found, these cases were excluded from the study. The edges of the perforation were excised with a sickle knife. The medial surface of the tympanic

remnant in the vicinity of the perforation was carefully scarified by the serrated circular knife to prepare the bed for the graft. A perichondrium graft taken from the tragus was trimmed in an oblong shape and then inserted to overlap the medial surface of the drum remnant by at least 2 mm. The gel foam bed was prepared prior to insertion of the graft to prevent medialization of the graft. The graft was kept in position by small gelfoam pieces soaked in antibiotic solution. The ear canal was then lightly packed with antibiotic gauze pack. Similarly, twenty patients were operated under operating microscope using same technique.

## RESULTS

The mode of onset in majority of cases was otitis media (95%). In 5% of the cases history of trauma was present.

In both the groups, 15% of the patients had grade I, 65% had grade II and 20% had grade III perforations. In the endoscopic group, there was 90% uptake of graft and in microscopic group it was 85%. No major complication was observed in the study. There was residual perforation in 3 patients ( 2 in endoscopic group

**Table I**

A-B Gap (Decibels)	Pre op A-B Gap		Post op A-B Gap		Gain in A-B Gap	
	E	M	E	M	E	M
0-10	2	2	12	11	14	16
11-20	6	9	6	6	6	3
21-30	10	7	1	2	0	1
31-40	2	2	1	1	0	0

E = Endoscopic group, M = Microscopic group.

and 1 in microscopic group) that healed on cautery with carbolic acid. Medialization of the graft was seen in 1 patient (microscopic group). There were 5 cases of graft failure (2 in endoscopic group and 3 in microscopic group), out of which 4 were in grade III, and 1 in grade II perforation.

Student's t-test was used for statistical analysis for comparing the results (gain in A-B gap) of two groups, t value was calculated and found to be 0.09, which is less than  $t_{5\%}$  for 6 degrees of freedom, that is, 2.44. Hence there is no significant difference in the gain in A-B gap between the two groups.

## DISCUSSION

The rod lens scope, first developed by Hopkins, uses rod-shaped glass lenses in the relay system. The lenses are thick and the air spaces are small. The rod lens provides for a wider viewing angle and exceptional resolution and brightness. Most sinus endoscopes<sup>1</sup> and smaller endoscopes belong to this category.

There are 2 major safety concerns with endoscopic ear surgery. One is excessive heat dissipation. This was evident only when a xenon light source was used. Adequate illumination of the middle ear space can be accomplished with lower settings on the regular light source (because of the size of the cavity) without the need of the xenon systems. Also, the tip of the endoscope requires continuous cleaning with antifog solution, which probably helps in cooling the endoscope. The other safety concern is accidental patient movement with secondary direct trauma by the tip of the endoscope. The relatively large diameter of the endoscope (4mm) used in the study and the anatomy of the ear canal and middle ear space will usually preclude the introduction of the endoscope beyond the tympanic ring.

The endoscope offers the following advantages :

- 1) It visualizes the whole tympanic membrane<sup>2</sup> and the ear canal without having to manipulate the patient's head or the microscope.
- 2) It extends the operative field in transcanal procedures into structures usually hidden under the microscope (anterior tympanic perforation, posterior pocket, facial recess, and hypotympanum).
- 3) To visualize structures from multiple angles as opposed to the microscope's single axis along the ear canal.
- 4) It provides extremely sharp image with high resolution.

Disadvantages of the endoscope include the one-handed surgical technique, a loss of depth perception, limited magnification and the need for training. The endoscope holds the greatest promise in tympanoplasty and cholesteatoma surgery<sup>3,4,5</sup> and should increase the utilization of transcanal over postauricular procedures.

In our study, endoscopes allowed us close inspection and photodocumentation<sup>6,7,8,9,10</sup> of the tympanic membrane perforation, the drum remnant, the eustachian tube orifice, the middle ear mucosa and ossicular chain without elevation of tympanomeatal flap. The anatomical variations (tortuous or stenotic ear canal, anterior meatal overhang etc.) that hamper the view of entire tympanic membrane during ear surgery were overcome by the use of endoscopes. Moreover, the permeal route avoided post auricular incision, resulting in less operative time and postoperative pain and morbidity. The patients were discharged on the same day. The results of endoscopic myringoplasty are comparable to the conventional myringoplasty done under operating microscope. There was 90% graft uptake rate in endoscopic group as compared to 85% in microscopic group. Also the mean A-B gap gain in patients who had undergone endoscopic myringoplasty was 8.0 dB, while in microscopic group it was 7.5 dB. Postoperative air bone gap was less than 10dB in 60% of the patients in endoscopic group and 55% in microscopic group. For finding out whether there is any significant difference in the gain in air bone gap in the two groups, student's t test was used and it was seen that there is no significant difference between the gain in A-B gap in either group.

The above results are consistent with the earlier studies. In 1963 Goodhill<sup>11</sup> et al did 19 cases of tympanoplasty using tragal perichondrium graft under microscope. They reported 100% graft take-up rate and in all cases dry ear was obtained in a short period of time. In another study by Quraishi et al., tragal perichondrium grafts were used permealately in 32 patients. A success rate of 94% was observed. They also reported less patient morbidity and 40% reduction in theatre time as the procedure was done permealately on day case basis. Ahmed El- Guindy<sup>12</sup> (Tanta, Egypt), has evaluated the role of the rigid endoscope in the management of 36 cases of dry central perforation of the tympanic membrane. The graft take rate was 91.7 percent and air bone gap was closed to less than 10dB in 83.3%. He used endoscope along with the manometry to evaluate the tubal function before ear surgery.

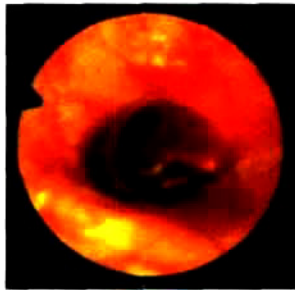


Fig. I : Tympanic membrane showing tympanosclerosis

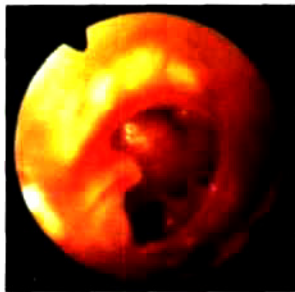

Fig. II : Tympanic membrane showing central perforation

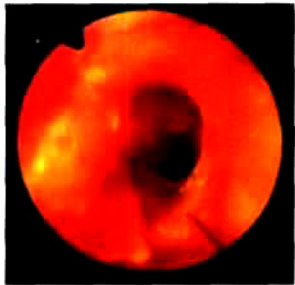


Fig. III : Margins of perforation freshened

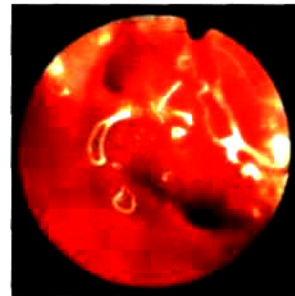


Fig. IV : Gel foam in middle ear

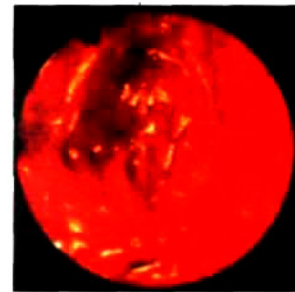


Fig. V : Graft in place

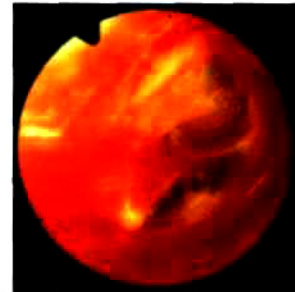


Fig. VI : Post op intact drum

## CONCLUSION

This study shows that endoscopes can be used in performing myringoplasty. There are many opportunities to utilize endoscopes in middle ear surgery like tympanoplasty, stapedectomy and cholesteatoma surgery. The endoscope offers the greater technical advantage over the microscope in tympanoplasty and cholesteatoma surgery and should increase the utilization of transcanal over postauricular procedures.

## REFERENCES

- Kennedy DW, Senior AB, Endoscopic sinus Surgery. Otolaryngologic Clinics of North America 1997, 30 : 313-330.
- Mer SB, Derbyshire AJ, Brushenko A, Pontarelli DA, Fiberoptic endoscopes for examining the middle ear. Arch Otolaryngol. 1967, 85 : 387-93.
- Thomassin JM, Korchia D, Doris JMD, Endoscopic -guided otosurgery in the prevention of residual cholesteatomas. Laryngoscope. 1993, 103 : 939-43.
- Mc Kennan KX, Endoscopic "second look" mastoidoscopy to rule out residual epitympanic - mastoid cholesteatoma. Laryngoscope. 1993, 103 : 810-814.
- Thomas JH, Tanyeri H. Surgical Techniques to Facilitate Endoscopic Second Look Mastoidectomy. Laryngoscope 1999, 109 : 1023 - 1027.
- Mann W, Munker G. A new method of Otophotography. Arch Oto Rhino Laryng 1976, 212-137-139.
- Buckingham RA, Endoscopic otophotography. Laryngoscope. 1963, 73 : 71-84.
- Fry T.L, Newton D. F., Otoscopy and Photography. Ann Otol 1979, 88 : 771-773.
- Smith HW, Rosangle RS, Yanagisawa E., Tympanic membrane photography. Arch Otolaryngol. 1974, 99 : 125-127.
- Konrad et al. Pediatric otoscopy and photography of the tympanic membrane. Arch Otolaryngol. July 1979, 105 : 431-433.
- Goodhill, V. et al Tympanoplasty with perichondrium graft. Archives of Otolaryngology. 1964, 79 : 131-137.
- Ahmed EI-Guindy. Endoscopic transcanal myringoplasty; The journal of Laryngology and Otology. 1993, 106, 493-495.