

# Histamine-containing neurons in the rat hypothalamus

(histamine/immunocytochemistry/hypothalamus/premamillary nucleus/caudal magnocellular nucleus)

P. PANULA, H.-Y. T. YANG, AND E. COSTA

Laboratory of Preclinical Pharmacology, National Institute of Mental Health, Saint Elizabeths Hospital, Washington, D.C. 20032

Contributed by Erminio Costa, January 6, 1984

**ABSTRACT** A specific antiserum against histamine was produced in rabbits, and an immunohistochemical study of histamine-containing cells was carried out in rat brain. The antiserum bound histamine in a standard radioimmunoassay and stained mast cells located in various rat and guinea pig tissues. Enterochromaffin-like cells in the stomach and neurons in the posterior hypothalamic area could be detected with this antiserum. The staining was highly specific and was not abolished by preabsorption with histidine, histidine-containing peptides, serotonin, or catecholamines, whereas preabsorption with histamine completely abolished the staining. Immunoglobulins of this antiserum purified by affinity chromatography stained the same cells as did the crude antiserum, whereas the serum fraction, which was not absorbed by histamine-affinity ligand, failed to stain any neuron. Histamine-immunoreactive neuronal cell bodies were found only in the hypothalamic and premamillary areas of colchicine-treated rats. The largest group of cells was seen in the caudal magnocellular nucleus and medially on the dorsal and ventral aspects of the ventral premamillary nucleus. Immunoreactive nerve fibers, but no cell bodies, were detected in other parts of the brain. Histamine-immunoreactive mast cells were found in the median eminence and pituitary gland. The results suggest that histamine-containing neurons are located only in a small area of the posterior hypothalamus, and these cells are probably the source of ascending and descending fibers detected in other brain areas.

During the last decade, a number of studies have indicated that histamine may function as a putative neurotransmitter in the mammalian central nervous system (1). In the brain, the highest histamine content is found in hypothalamus (2-5) and in certain areas of the mesencephalon (6). Biochemical measurements of histamine and its synthesizing enzyme, histidine decarboxylase, in various regions of intact and lesioned brains suggest that brain contains long axon histamine-containing neurons. Furthermore, although a considerable portion of brain histamine appears to be located in mast cells (4, 7, 8), its presence in synaptosomal fractions suggests its neuronal location (9-12); this is supported by the presence in brain structures of adenylate cyclase activity stimulated by histamine (13).

The immunocytochemical method that detects serotonin has been useful in revealing serotonin-containing neuronal pathways in the central nervous system (14). Attempts to develop a fluorescence histochemical method for histamine have been made (15-17), but the *o*-phthalaldehyde (OPT) method failed to detect histamine-containing neurons in the brain. Wilcox and Seybold (18) reported the presence of histamine-containing neurons in the median eminence, using antibodies against histamine. However, this study detected only a few histamine-containing cells. The present study, in which an antiserum against histamine is used, shows that

several groups of histamine-containing neurons are located in rat hypothalamus.

## MATERIALS AND METHODS

Histamine-HCl (Sigma; 10 mg) and succinylated hemocyanin (Sigma; 5 mg) were dissolved in 1.5 ml of H<sub>2</sub>O, and 0.1 ml of 1-ethyl-3-(3-dimethylaminopropyl)carbodiimide (100 mg/ml) was added. The solution was kept at room temperature and pH 5.0-6.0 overnight. The conjugate was then dialyzed against H<sub>2</sub>O, lyophilized, redissolved in saline, and emulsified in complete Freund's adjuvant. One milliliter of the emulsion containing 250  $\mu$ g of the conjugate was injected intradermally into the backs of rabbits. Subsequent injections at 2-wk intervals consisted of 125  $\mu$ g of conjugate.

One week after the sixth injection, the rabbits were bled and the antisera were tested. [2,5-<sup>3</sup>H]Histamine (Amersham) was purified by using thin-layer chromatography developed with 1-butanol/CH<sub>3</sub>COOH/H<sub>2</sub>O, 60:15:25 (vol/vol). [2,5-<sup>3</sup>H]Histamine was extracted from the plate with 0.1 M CH<sub>3</sub>COOH containing 0.1% bovine serum albumin and an aliquot containing about 10,000 cpm was incubated for 48 hr at 4°C with 0.5 ml of 0.2 M Tris buffer (pH 7.4) containing 0.1% bovine serum albumin and 0.06% dextran and with different amounts of antiserum. Separation of bound and free antigen was carried out by addition of 0.2 ml of charcoal slurry (1.5% charcoal) precoated with dextran (0.15%) in 0.9% saline, followed by centrifugation. The antiserum used in this study bound 30% of the trace amount of [2,4-<sup>3</sup>H]histamine at a dilution of 1:100. Control sera did not bind any [2,4-<sup>3</sup>H]histamine.

The antibody against histamine was purified by affinity column chromatography with histamine-Sepharose 4B. The affinity ligand histamine-Sepharose was prepared with CNBr-activated Sepharose 4B (Pharmacia). An affinity column was prepared and washed with 0.2 M Tris buffer (pH 7.4). Histamine antiserum (250  $\mu$ l) was applied, and the column was eluted with 0.2 M Tris buffer at a flow rate of 0.5 ml/min. Fractions including the 10-min eluate were pooled and lyophilized. The protein concentration of each fraction to be used in histochemistry was matched with that of diluted intact antiserum that gave positive staining for histamine in immunocytochemistry. The antibodies absorbed by the affinity column were then eluted with 0.3 M acetic acid, neutralized, lyophilized, and reconstituted with saline. They then were diluted with phosphate-buffered saline (16  $\mu$ g of protein/ml) for immunohistochemical staining. The staining obtained with these purified immunoglobulins was less intense than that obtained with the crude antiserum, but a comparable number of immunoreactive cells were detected in the same location.

Adult male Sprague-Dawley rats (250-350 g) under sodium pentobarbital anaesthesia were perfused through the left ventricle with saline followed by ice-cold 4% paraformaldehyde in 0.1 M sodium phosphate buffer (pH 7.4). Twenty rats received a single intracerebroventricular injection of colchicine (70  $\mu$ g/20  $\mu$ l) 48 hr before paraformaldehyde perfusion. The brains were immersed in 4% paraformaldehyde

in 0.1 M sodium phosphate buffer for 2 hr and then were transferred to 0.1 M sodium phosphate buffer (pH 7.4) containing 15% sucrose for at least 24 hr.

Cryostat sections (thickness, 25  $\mu\text{m}$ ) were cut, and free-floating sections were first treated with 20% normal swine serum diluted in phosphate-buffered saline (pH 7.4) to decrease nonspecific background staining. The peroxidase-antiperoxidase method of Sternberger *et al.* (19) was then used to demonstrate immunoreactivity to histamine in various areas of rat brain. All antisera dilutions were made in phosphate-buffered saline containing 0.25% Triton X-100. In preliminary experiments, the anti-histamine antiserum was tested by using dilutions from 1:100 to 1:10,000. The specific staining in the hypothalamus decreased with increasing dilutions of antiserum. The best reaction was obtained at antiserum dilutions of 1:500 to 1:2000, which were used in this study. Incubation with the histamine antiserum was carried out at 4°C for 48 hr. The samples were washed twice with phosphate-buffered saline for 20 min and incubated with swine anti-rabbit immunoglobulins (DAKO, Copenhagen, Denmark) diluted 1:100 for 30 min. After two washes they were incubated with a soluble complex of horseradish peroxidase-rabbit antihorseradish peroxidase (DAKO) diluted 1:100 for 30 min at room temperature. Washing with 0.05 M Tris buffer (pH 7.6) then was followed by treatment with 3,3'-diaminobenzidine tetrahydrochloride (50 mg/100 ml; Sigma) and 0.003% hydrogen peroxide in 0.05 M Tris buffer, pH 7.6. After being washed with 0.05 M Tris buffer, the sections were mounted on slides, dried in air, and embedded in Permount.

Control sections were treated similarly but the histamine antiserum was replaced by serum obtained prior to immunization (preimmune serum) eluted from the histamine affinity column or by preabsorbed antiserum. Preabsorption was carried out by incubating different amounts of histamine or related substances with diluted antiserum for 24 hr before its incubation with brain slices.

## RESULTS

Hypothalamic neurons exhibited immunoreactivity to histamine only after colchicine pretreatment, whereas immunore-

active mast cells were found in the median eminence of all rats. Hence, all subsequent studies on the location of histamine-containing neurons were performed in colchicine-treated rats. Histamine-immunoreactive neurons were detected exclusively in areas of the posterior hypothalamus. The largest group of histamine-immunoreactive neurons was found in the caudal magnocellular nucleus at the level of the pre-mammillary nuclei. These histamine-containing neurons extended medially to the dorsal and ventral aspects of the ventral pre-mammillary nucleus (Fig. 1). At the most anterior level, immunoreactive neurons were first seen in basal hypothalamus between the medial forebrain bundle and ventromedial nucleus. At the same level, a small group of histamine-containing cells was consistently found bilaterally near the tip of the third ventricle (Fig. 2A). Here and at slightly posterior levels, scattered histamine-containing neurons were found between the dorsomedial nucleus and the medial forebrain bundle. At the level of the mammillary nuclei, histamine-immunoreactive cells were found as a thin plate in the basal hypothalamus, and a small group was located in the dorsolateral part of the lateral mammillary nucleus (Fig. 2B).

No immunoreactive cells were seen in arcuate nucleus and median eminence. However, intensely stained mast cells were consistently seen at all levels of the median eminence, immediately beneath the meninges (Fig. 2C). At high magnification, these cells exhibited granular reaction deposits and typical morphological features of mast cells. Immunoreactive nerve fibers, but no immunoreactive nerve cell bodies, were seen in other parts of the brain including layers I and II of the cerebral cortex, hippocampus, and some mesencephalic and pontine nuclei. Histamine-containing fibers were also seen in the basal hypothalamus, supraoptic and arcuate nuclei. Few fibers were seen in the median eminence. Dense bundles of immunoreactive fibers were not found anywhere in the brain.

The specificity of the antibody-antigen reaction was established by affinity chromatographic purification and standard blocking controls with a variety of substances. When antibodies directed toward histamine were removed from the antiserum with an affinity column (histamine-sepharose 4B), the fractions that were not absorbed by the affinity ligand

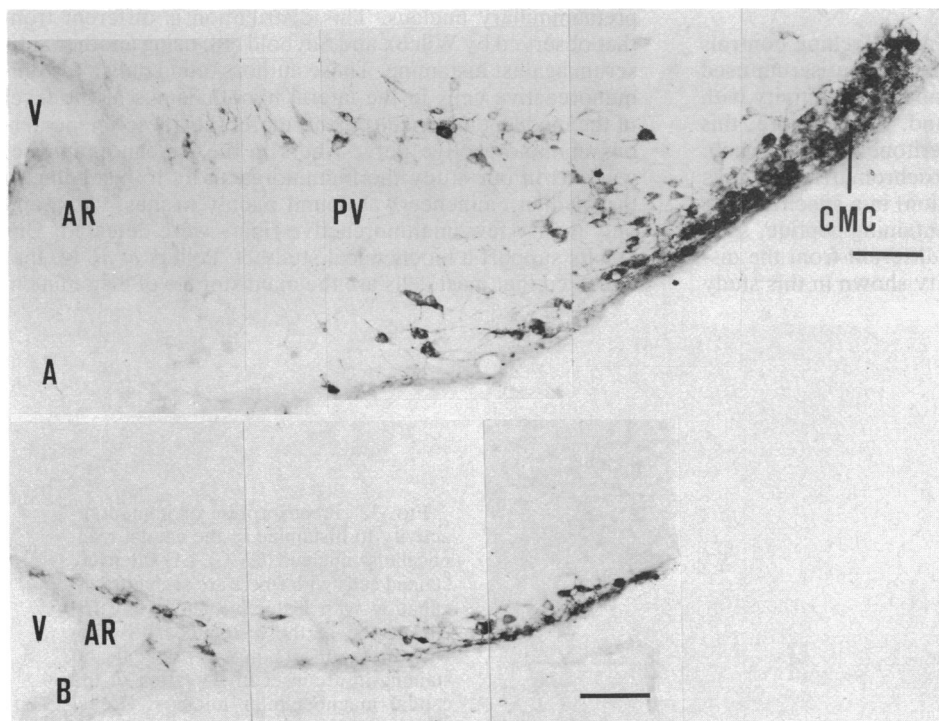


FIG. 1. Photomontages of histamine-immunoreactive neurons at two different levels of the hypothalamus. (A) The caudal magnocellular nucleus (CMC) is densely packed with immunoreactive neurons. Large immunoreactive neurons surround the ventral pre-mammillary nucleus (PV), and many of them send processes to the dorsomedial direction (Level 4F.) (B) Immunoreactive cells in the basal hypothalamus also display neuronal morphology with extensive processes. (Level 4G-H.) AR, arcuate nucleus; V, third ventricle. (Bar = 100  $\mu\text{m}$ .)

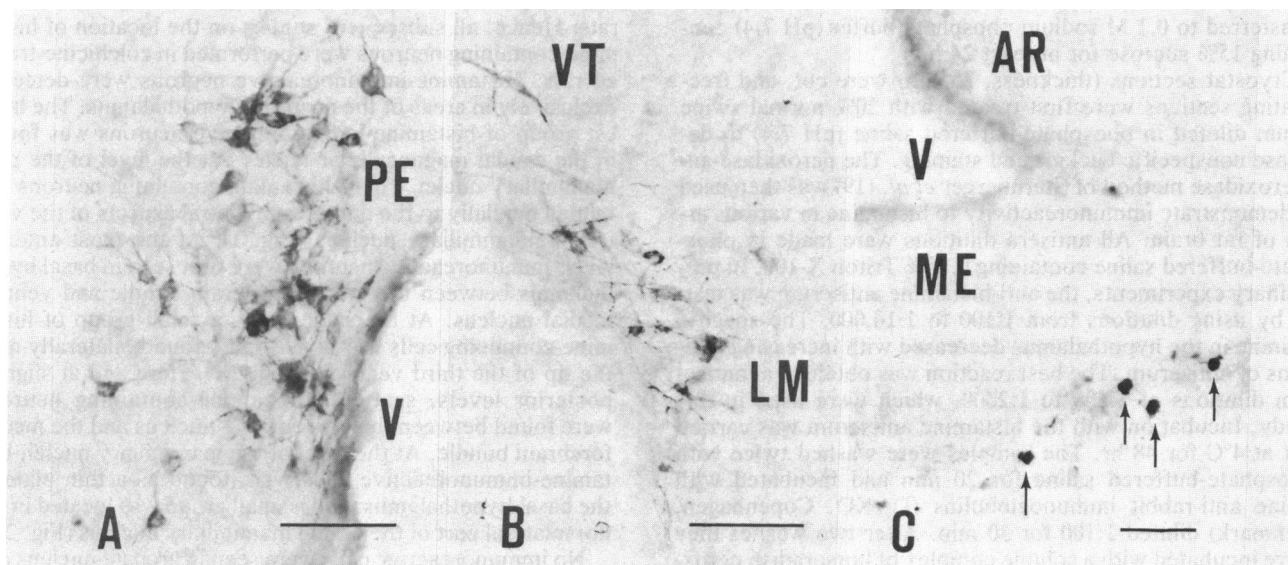


FIG. 2. Characteristic small groups of medium-sized histamine-immunoreactive neurons are located near the tip of the third ventricle (V) at level 4D (A) and in the dorsolateral corner of the lateral mammillary nucleus (LM) near the ventral tagmentum (VT) at level 4H (B). (Bar = 100  $\mu\text{m}$ .) Heavily stained mast cells (arrows in C) were detected in the median eminence (ME) of the rat at level 4A. (Bar = 50  $\mu\text{m}$ .) AR, arcuate nucleus; PE, periventricular nucleus.

failed to stain hypothalamic neurons, whereas the crude antiserum used at the same protein concentration gave intense staining. When diluted antiserum was preabsorbed with histamine (1 mg/ml), the immunostaining was abolished completely (Fig. 3). Serotonin, L-histidine, D-histidine, beta-alanyl-L-histidine, L-histidyl-L-leucine, and thyrotropin-releasing hormone (pGlu-His-Pro-NH<sub>2</sub>) had no effect on the intensity of the immunohistochemical reaction when applied at 1 mg/ml or 10 mg/ml. A slight decrease in staining intensity was seen when *tele*-methylhistamine (1 mg/ml) was used in preabsorption. The distribution of histamine-like immunoreactivity throughout the hypothalamus is shown in Fig. 4.

### DISCUSSION

Solid-phase immunoabsorption tests and blocking controls indicate that the staining with the histamine antiserum used in this study is due to histamine, and no crossreactivity with histidine-containing peptides was found. Furthermore, this antiserum stained mast cells in the peritoneal fat, stomach, and posterior pituitary as well as enterochromaffin-like cells in the stomach (unpublished observation) in a specific manner. The distribution of a histidine-containing peptide, such as thyrotropin-releasing hormone, is different from the distribution of histamine immunoreactivity shown in this study

(21–23), suggesting that our antiserum fails to detect histidine-containing peptides.

Histamine-immunoreactive neuronal cell bodies could be detected only after treatment of the animals with intracerebroventricular colchicine. This suggests that inhibition of the fast axonal transport is necessary for the demonstration of immunoreactive cell bodies. Immunoreactive nerve fibers were detected in several brain regions, including the hypothalamus, cortex, and hippocampus in normal and colchicine-treated animals.

Our findings suggest that histamine-containing neurons are located exclusively in a relatively small area of the posterior basal hypothalamus, in the caudal magnocellular nucleus, in the lateral mammillary nucleus, and around the ventral premammillary nucleus. This distribution is different from that observed by Wilcox and Seybold (18) using another antiserum against histamine. These authors found only a few immunoreactive cells in the lateral hypothalamus at the level of the median eminence. Furthermore, they describe numerous immunoreactive nerve fibers in the median eminence, whereas in our study the immunoreactivity to histamine in the median eminence was found mainly in mast cells, and only a very few immunoreactive fibers were detected. Our results support a biochemical study by Pollars *et al.* (4) that indicated that mast cells are the main storage of histamine in

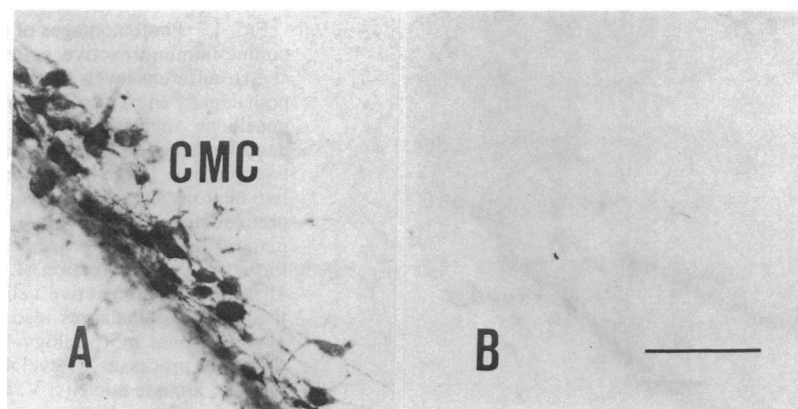


FIG. 3. Preabsorption of immunoreactivity to histamine in the caudal magnocellular nucleus (CMC). (A) Intensely stained cells with fibers are seen after incubation with histamine antiserum. (B) Absorption of the histamine antiserum with histamine (1 mg/ml) reveals no staining in a consecutive section of the caudal magnocellular nucleus. (Level 4F; Bar = 50  $\mu\text{m}$ .)

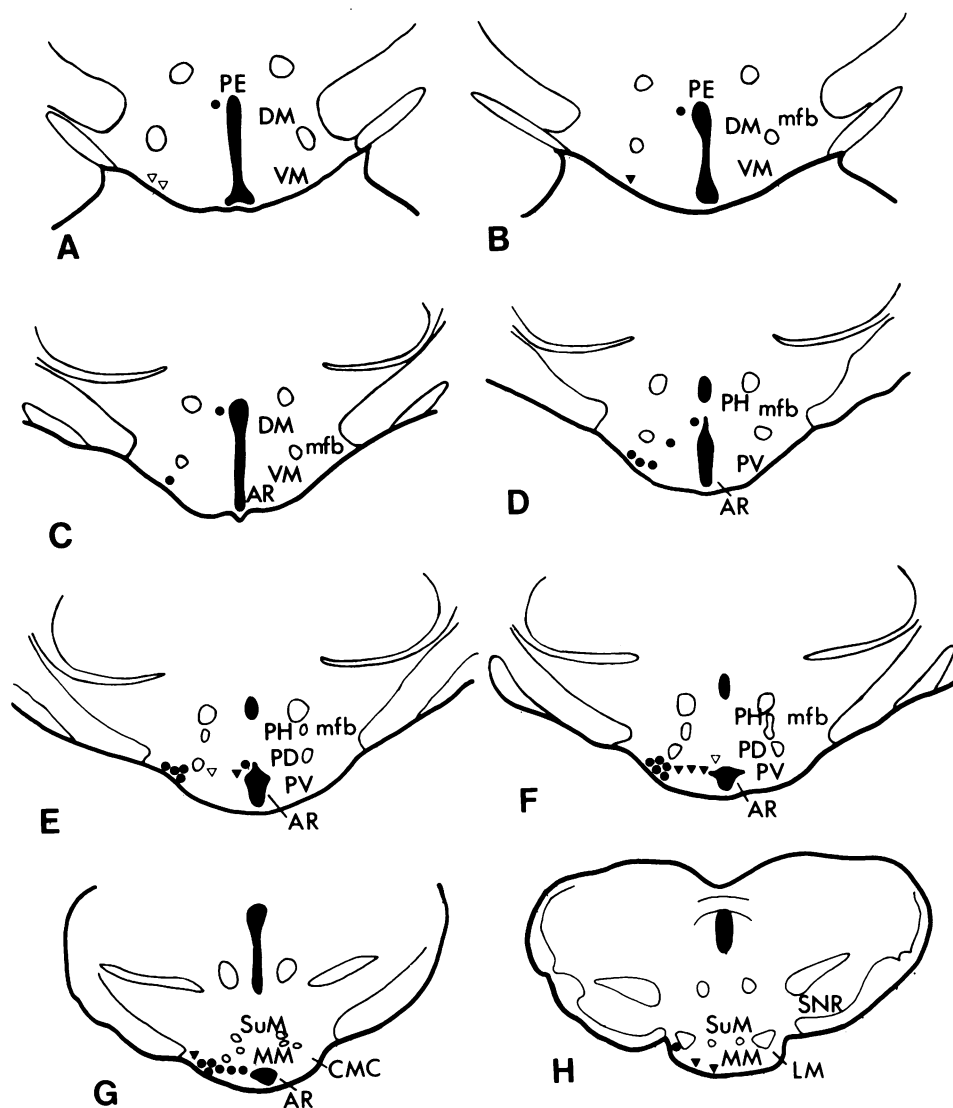


FIG. 4. Schematic drawings demonstrate the distribution and number of histamine-immunoreactive nerve cell bodies in the basal hypothalamus (*Left*) and the corresponding nuclei (*Right*). The number of cells is the mean found in all brains studied ( $\nabla$ , 1 cell;  $\blacktriangledown$ , 5 cells;  $\bullet$ , 10 cells per section). The sections correspond to the following levels of the atlas of König and Klippel (20): 4230 (A), 4110 (B), 3990 (C), 3750 (D), 3430 (E), 3290 (F), 3180 (G), and 2580 (H). AR, arcuate nucleus; CMC, caudal magnocellular nucleus; DM, dorsomedial nucleus; LM, lateral mammillary nucleus; mfb, medial forebrain bundle; MM, medial mammillary nucleus; PD, dorsal premammillary nucleus; PE, periventricular nucleus; PH, posterior hypothalamic nucleus; PV, ventral premammillary nucleus; PHn, posterior hypothalamic nucleus; SuM, supramammillary nucleus; V, third ventricle; VM, ventral premammillary nucleus; VT, ventral tegmentum.

the median eminence, while elsewhere in the hypothalamus histamine is mainly neuronal.

Our results are slightly different from those obtained with antibodies against histidine decarboxylase, the histamine-forming enzyme. Tran and Snyder (24) found histidine decarboxylase-like immunoreactivity in the parietal cells of the stomach, in the bed nucleus of the stria terminalis as well as hypothalamic and mammillary areas. Watanabe *et al.* (25) detected histidine decarboxylase-like immunoreactivity in the enterochromaffin-like cells of the stomach in agreement with our results with antiserum against histamine, but they report neuronal cell bodies in the arcuate nucleus, which in our study was devoid of histamine-immunoreactive cells. We found the cells more laterally in the caudal magnocellular nucleus and around the ventral premammillary nucleus.

So far we failed to detect histamine-immunoreactive cell bodies in other brain areas. Though more extensive studies are needed to conclude that histaminergic neurons are located exclusively in the hypothalamic areas described in this study, the possibility exists that most if not all of the histaminergic fibers in the brain derive from the posterior hypothalamic nuclei described in this study. Thus, the histaminergic neuronal system would resemble the serotonergic and catecholaminergic systems that are formed by a relatively small number of cell bodies generating extensive fiber projections to forebrain and hindbrain areas. Although histamine is present in midbrain and hindbrain nuclei (6, 5), specific lesions of these nuclei have failed to reduce the histamine or

histidine decarboxylase concentrations in the forebrain areas thought to receive histaminergic innervation. Local lesions placed in the posterior hypothalamus decreased histidine decarboxylase activity in the brain stem, suggesting that there is a descending histaminergic pathway from posterior hypothalamus to hindbrain areas (4). An ascending histamine-containing pathway has been suggested by Garbarg *et al.* (26, 27) based on biochemical studies after lesions of the medial forebrain bundle at the level of the lateral hypothalamus. However, such a lesion might have destroyed the histamine-containing neurons in the premammillary area; thus, the decrease of histidine decarboxylase activity in the cortex, striatum, hippocampus, and anterior hypothalamus observed by Garbarg *et al.* (26, 27) might be due to destruction of premammillary histamine-containing cells. This conclusion is supported by a recent study by Vincent *et al.* (28), which showed that GABAergic neurons in the caudal magnocellular nucleus project to the cerebral cortex. It should be of interest to study whether L-glutamate decarboxylase, a specific marker for GABAergic neurons, coexists with histamine in the neurons of the caudal magnocellular nucleus. This is possible with our immunohistochemical method, which enables combined studies with both tracers to characterize further the histamine-containing neurons described herein.

2. Adam, H. M. & Hye, K. A. (1966) *Br. J. Pharmacol.* **28**, 137-152.
3. Brownstein, M. J., Saavedra, J. M., Palkovits, M. & Axelrod, J. (1974) *Brain Res.* **77**, 151-156.
4. Pollard, H., Bischoff, S., Llorens-Cortes, C. & Schwartz, J. C. (1976) *Brain Res.* **118**, 509-513.
5. Taylor, K. & Snyder, S. (1971) *J. Pharmacol. Exp. Ther.* **173**, 619-633.
6. Pollard, H., Llorens-Cortes, C., Barbin, G., Garbarg, M. & Schwartz, J. C. (1978) *Brain Res.* **157**, 178-181.
7. Grzanna, R. & Shultz, L. D. (1982) *Life Sci.* **30**, 1959-1964.
8. Yamatodani, A., Maeyama, K., Watanabe, T., Wada, H. & Kitamura, Y. (1982) *Biochem. Pharmacol.* **31**, 305-309.
9. Carlini, E. A. & Green, J. P. (1963) *Br. J. Pharmacol.* **20**, 264-277.
10. Kataoka, K. & DeRobertis, E. (1967) *J. Pharmacol. Exp. Ther.* **156**, 114-125.
11. Kuhar, M. J., Taylor, K. M. & Snyder, S. H. (1971) *J. Neurochem.* **18**, 1515-1527.
12. Michaelson, I. A. & Coffman, P. R. (1967) *Biochem. Pharmacol.* **16**, 2085-2090.
13. Hegstrand, L. R., Kanof, P. D. & Greengard, P. (1976) *Nature (London)* **260**, 163-165.
14. Steinbusch, H. W. M., Verhofstad, A. A. J. & Joosten, H. W. J. (1978) *Neuroscience* **3**, 811-819.
15. Aures, D., Håkanson, R., Owman, C. & Sporrang, B. (1968) *Life Sci.* **7**, 1147-1153.
16. Ehringer, B. & Thunberg, R. (1967) *Exp. Cell. Res.* **47**, 116-122.
17. Juhlin, L. & Shelley, W. B. (1966) *J. Histochem.* **14**, 525-528.
18. Wilcox, B. J. & Seybold, V. S. (1982) *Neurosci. Lett.* **29**, 105-110.
19. Sternberger, L. A., Hardy, P. H., Cuculis, J. J. & Meyer, H. G. (1970) *J. Histochem. Cytochem.* **18**, 315-333.
20. König, J. F. R. & Klippel, R. A. (1967) *A Stereotaxic Atlas of the Forebrain and Lower Parts of the Brain Stem* (Williams & Wilkins, New York), pp. 95-113.
21. Brownstein, M. J., Palkovits, M., Saavedra, J. M., Bassiri, R. M. & Utiger, R. D. (1974) *Science* **185**, 267-269.
22. Hökfelt, T., Fuxe, K., Johansson, O., Jeffcoate, S. & White, N. (1975) *Eur. J. Pharmacol.* **34**, 389-392.
23. Winokur, A. & Utiger, R. D. (1974) *Science* **185**, 265-267.
24. Tran, V. T. & Snyder, S. (1981) *J. Biol. Chem.* **256**, 680-686.
25. Watanabe, T., Taguchi, Y., Hayashi, H., Tanaka, J., Shio-saka, S., Tohyama, M., Kubota, H., Terano, Y. & Wada, H. (1983) *Neurosci. Lett.* **39**, 249-254.
26. Garbarg, M., Barbin, G., Bischoff, S., Pollard, H. & Schwartz, J. C. (1976) *Brain Res.* **106**, 333-348.
27. Garbarg, M., Barbin, G., Feger, J. & Schwartz, J. C. (1974) *Science* **186**, 833-835.
28. Vincent, S. R., Hökfelt, T., Skirboll, L. & Wu, J.-Y. (1983) *Science* **220**, 1309-1310.