

Peripheral Ameloblastoma Involving Tongue-A Rare Case

B. C. Rajesh, P. G. in ENT, A. R. Vinayakumar, Asst. Professor of ENT,
John Mathai, Asst. professor of ENT, S. Valsaladevi, Professor of Pathology,
P. Prathapan Nair, Professor of ENT,
Medical College, Kottayam, Kerala.

Abstract

Peripheral ameloblastoma is a rare tumour of oral cavity. It presents as a mass without bony continuity. Here we report a unique case of peripheral ameloblastoma involving tongue, with review of relevant literature.

Ameloblastoma is an odontogenic tumour commonly occurring in relation with mandible. Peripheral (extra-osseous) ameloblastoma, which is not having a bony attachment or continuity is a rare entity. Here we report a case of peripheral ameloblastoma involving base of tongue.

Case Report

A 38 year old male came to our outpatient department in July 1996 with history of difficulty in swallowing and muffled voice. It was an obstruction both for solids and liquids. There was no throat pain or breathing difficulty.

Clinical examination revealed a smooth surfaced midline swelling in base of tongue. Hypopharynx and larynx were normal. Thyroid gland was present in normal site. No neck nodes were palpable. Systemic examination did not reveal any abnormality.

Routine examination of urine and blood were within normal limits. X-ray chest ECG and thyroid function tests were normal. FNAC from the swelling was done and report was inconclusive.

CT Report

"A lobulated lesion arising from the posterior part of tongue and floor of mouth extending upto the upper part of hyoid bone. Possibility of lingual thyroid may be considered. Thyroid gland with both lobes and isthmus seen in normal position."

With the available data he was posted for excision of the mass/GA by mandible splitting translingual pharyngotomy approach. A well encapsulated solid mass of size 6cm X 4cm X 3cm. was taken out with finger dissection. In one area the mass was continuous with surface mucosa. No continuity with nerves, vessels or muscles of tongue. Post operative period was uneventful. Patient was discharged on 12th post operative day. He is coming for regular, periodic followup. No recurrence in primary or any other site.

Histopathology Report

"Section from a tissue lined by squamous epithelium. Sub epithelial region showed a neoplasm composed of islands and groups of round / oval cells with small

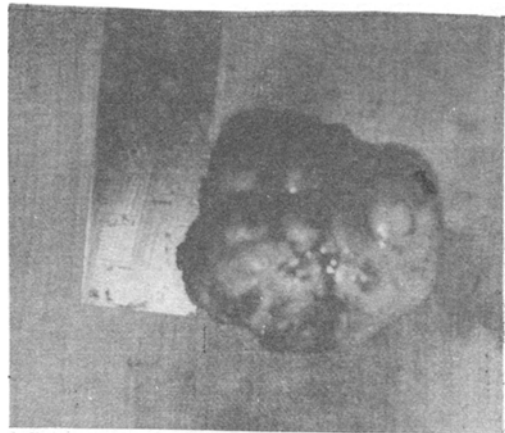

Fig. 1. Gross specimen

nuclei, separated by abundant fibro collagenous stroma. Periphery of cell groups showed palisading. Centre of zone of cell groups showed stellate reticulum and microcyst formation. Some of the cystic space contain mucous material. In some areas the cells have a vacuolated appearance. In one or two areas epithelial cell groups are seen arising from surface epithelium. All these features are suggestive of peripheral ameloblastoma.”

Discussion

In this case the tumour was situated in the posterior part of tongue and floor of mouth without any bony continuity.

occured in the gingiva. In some cases the tumour exhibits one or more areas of continuity with surface epithelium, while in other cases no evidence of continuity between the two can be found.

Stanley and Krogh (1959) were the first to provide acceptable evidence supporting this case. Klijn and Mc Manis (1969) reported a tumour in buccal mucosa and Russel (1966) and Wallen (1972) a tumour in maxillary tuberosity area. Lee and colleagues (1970) and Simpson (1974) reported tumour in the gingiva and floor of oral cavity. The possible source of origin for these tumours are the oral mucosa or cell rests of Serre.

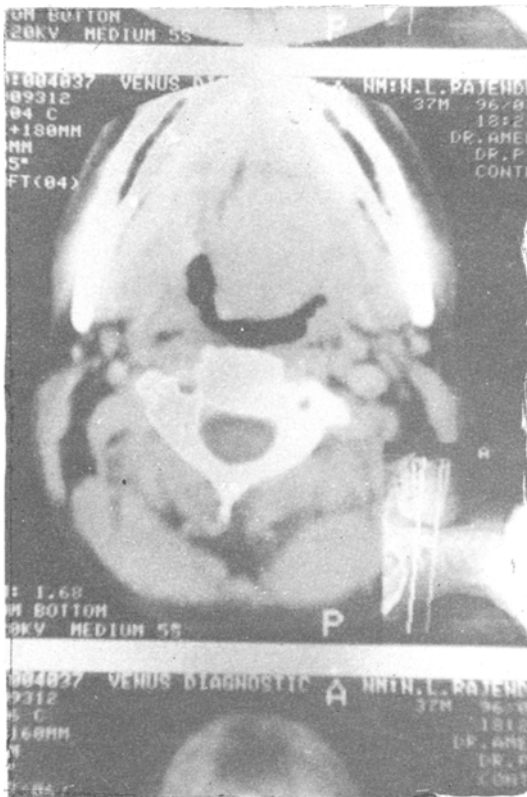


Fig. 2. CT Picture of the mass in posterior part of the tongue and floor of oral cavity.

Peripheral ameloblastoma is a tumour of the oral cavity, not involving bone, but exhibiting microscopic features of ameloblastoma. Most of the reported cases have

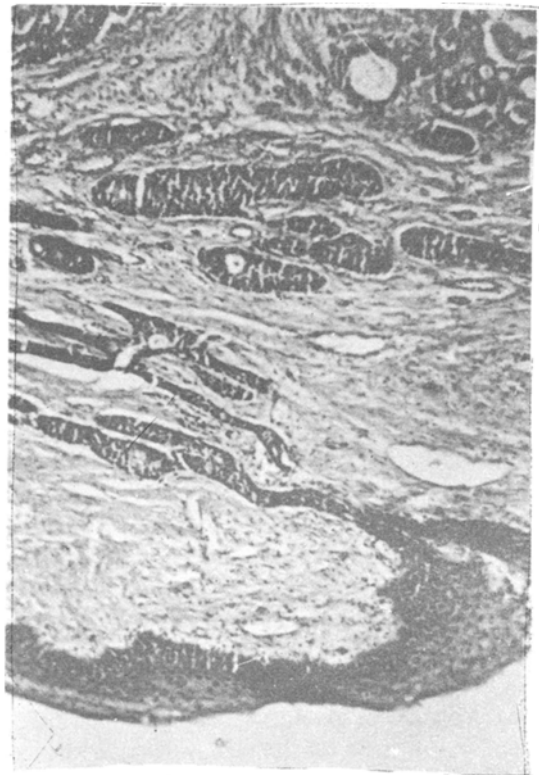

Fig. 3. Photograph of slide (x50) Shows neoplasm arising from surface squamous epithelium. Nests and trabeculae of cuboidal or oval cells with cystic spaces with centre of some of the cell groups. Stroma is desmoplastic.

A number of authors have observed that an ameloblastoma may show a connection with the oral mucosa. Seigmund and Weber (1926) illustrated some

cases of this type, but they consider that the tumour might equally well have grown up to and establish connection with the surface epithelium and have originated from it. Most authors have taken the view that the connection between mucosa and tumour epithelium could be incidental.

Gardner reviewed the literature, adding seven additional unpublished cases for a total of 21 examples of peripheral ameloblastoma. According to Gardner there is a slight predilection for occurrence in males and incidence is more between 30 and 50 years. Greer and Hammond have studied the ultrastructural characteristics and found the electron microscopic

appearance to be similar to that of intra osseous ameloblastoma.

One of the most important aspects of peripheral ameloblastoma to separate it from intra osseous counterpart is the difference in clinical behaviour. Peripheral lesion lacks the invasiveness of intra-osseous lesion and has very limited tendency for recurrence. So it may be excised locally.

Conclusion

Peripheral ameloblastoma is a rare tumour of oral cavity. This tumour arising from tongue is not reported in the literature. Here we report a unique peripheral ameloblastoma involving base of tongue.

Reference

1. *Ackerman's Surgical Pathology -Juan Rosai, Vol. 1, 7th Edn. (page 189), The C. V. Mosby Company. St. Louis Toronto. Washington. 1989.*
2. *A Text Book of Oral Pathology- Shafer, Hine, Levy (Page 276-285). W.B. Saunders Company. Igaku-Shoin/Saunders 1983.*
3. *Operative Surgery-Fundamental International Techniques, Nose and Throat, 3rd Edn. (Page 196-199). Charles Rob and Sir Rodney Smith. Butter Worth.*
4. *Pathology of Tumours of Oral Cavity-RB Lucas, 3rd Edn. (Page 50-51). Churchill Livingstone. Edinburgh, London, New York (1976).*

Conference News

1st Advanced Micro Ear Surgery Course

First Micro Ear Surgery Course was conducted on 30th May to 1st June 1998 in joint collaboration of ENT & Head Neck Surgery Deptt. of RNT Medical College, Udaipur & Rotary Club, Udaipur, On 29th May a deafness relief camp was organized in ENT OPD where approximately 800 patients were screened for various ailments & managed accordingly. Camp was inaugurated by Dr. D.S. Rathore, Principal & Controller. 10 hearing aids to needy persons were distributed free of cost & many needy persons were distributed hearing aids at subsidized rates.

1st Advanced Micro Ear Surgery Course was organised from 30th May to 1st June 1998 which was conducted by Dr. A.K. Gupta, Prof. & Head, Deptt. of ENT & Supdt of M.B.G. Hospital. Guest Faculty were Dr. Pedro Claros from Spain, Dr. Bebear from France & Dr. S. Maheswari from New Delhi. Approximately 40 participants from various parts of India attended the course. On 30th May course was inaugurated by Div. Commissioner Sh. C.M. Meena & Dr. D.S. Rathore in paediatric seminar room.

Approximately 28 cases were operated in ENT Operation Theatre by them for various ailments. One case of total ossicular replacement was unique as it had been performed for the first time.

All surgical procedures were demonstrated live on Videoscope for participants where team of experts were on direct dialogue with operating surgeons.

Stalls from various scientific instruments companies displayed there latest introductions in this field.