

Recurrent solitary hydatid cyst of the subcutaneous tissue

Sumitoj Singh · Sudhir Khichy · Manjit Singh · Jatinder Singh Gill

Received: 20 August 2008 / Accepted: 27 August 2008
© Association of Surgeons of India 2009

Abstract A 28-year-old male patient presented with a recurrent swelling in the left lateral chest wall just below the left axilla since seven years. Patient was operated for the same swelling eight years back and its biopsy report showed hydatid cyst. Patient had not taken any antihelminthic post operatively. Based on this, diagnosis of recurrent subcutaneous hydatid cyst was made and total cystectomy was done. Post operatively patient was started on albendazole. On follow up of one year there is no recurrence. Hydatid cyst is caused by the larval stage of *Echinococcus*. Four species of the *Echinococcus* tapeworm can produce infection in humans. *E. granulosus* and *E. multilocularis* are the most common, causing cystic and alveolar echinococcosis respectively, while *E. vogeli* and *E. oligarthrus* have rarely been associated with human infection. Hydatid cyst of the subcutaneous is extremely rare. This case report highlights the rare location of the hydatid cyst as well its recurrence in rare location.

Keywords Hydatid cyst · Subcutaneous tissue

Introduction

Human hydatid disease is commonly caused by the parasite *E. granulosus* that has dog as the definitive host and sheep as the intermediate host. Humans are the accidental hosts. Once within the intermediate host, the ingested eggs hatch in the small intestine, where the parasites penetrate the mucosal wall and enter veins or lymphatics. They reach the liver via portal vein and it acts as an effective filter for the most of the larvae and therefore, the liver is the most frequently involved organ (70%). The larvae which passed through this first filter, reach the lung via right heart and thus lung is the second most frequently involved site (10–15%). If worm is not trapped in either the liver or lungs, or if it travels in lymphatics and bypasses the liver, it may lodge virtually anywhere in the body, most commonly in the peritoneum (10–16%), spleen (2–3%), kidneys (1–4%), uterus & adenexae (0.5–1.5%), pancreas (0.3–0.8%), others (0.1–3%) [1]. In different series, the frequency of the subcutaneous tissue involvement was approximately 1–2% [2–4].

Case report

A 28-year-old patient presented in surgical OPD of GGS Medical College and Hospital Faridkot, with chief complaint of swelling in the left lateral chest wall just below the left axilla since seven years. He was operated for similar swelling at the same site 8 years back at some hospital. Histopathological examination of the swelling at that time was hydatid cyst. Patient noticed swelling at the same site after about one year of surgery. Swelling was painless, progressively increasing in size and was not associated with any other symptom. There was no history of any similar

S. Singh · S. Khichy · M. Singh · J. S. Gill
Department of surgery,
Guru Gobind Singh Medical College & Hospital,
Faridkot, Punjab, India

S. Singh (✉)
E-mail: Sumitoj@rediffmail.com; Sumitoj.singh@gmail.com

swelling in any other part of the body. On examination well healed surgical scar mark was present over the swelling. Swelling was about 10×8 cm in size, globular in shape, non tender, firm in consistency and movement of swelling was restricted in all directions (Fig. 1). Hematological investigations were within normal limits. Ultrasound examination of abdomen was also normal. With the clinical diagnosis of recurrent solitary hydatid cyst, patient was undertaken for surgery. Total cystectomy was done under general anesthesia. There were dense pericystic adhesions and on cut section of the cyst clear fluid with laminated membranes was present (Fig. 2). Histopathological report was consistent with the diagnosis of hydatid cyst. Post operative period was uneventful. Patient was started on albendazole orally and discharged. On follow up of one year there is no recurrence.

Discussion

Subcutaneous hydatid cyst is usually associated with involvement of other structures [5]. It is difficult to explain how the larvae pass through two filter sites i.e. liver and lungs and form solitary cysts. Although no route other than the portal route has been proven in humans, it is strongly suggested that systemic dissemination via the lymphatic route may be responsible for cases with solitary cyst in uncommon sites [2]. Hydatid cyst is usually asymptomatic and it grows slowly. The annual growth rate of the cyst is about 1–3 cm in diameter. The size and location of cyst determines the degree of symptoms. Routine laboratory tests do not show specific results except for eosinophilia. A slow growing, painless mass in the subcutaneous was the only symptom in our case. Various serological tests are done for diagnosis, screening and post operative follow-up for recurrence. Indirect haemagglutination test (IHA) and Latex agglutination test are highly sensitive and Immunoelectrophoresis, Double diffusion test (DD test), Enzyme linked immunosorbent assay (ELISA), Radioallergosorbent test (RAST) are highly specific [1]. Ultrasound and CT-scan are useful for delineating the location of the cyst but the findings are nonspecific. Hypo intense peripheral rim with multicystic mass (cyst inside cyst) is a distinctive feature of hydatid cyst on MRI [3]. We did not perform any serological test or any imaging of subcutaneous tissue in our case as patient was biopsy proven case of hydatid cyst.

The treatment of both primary and recurrent hydatid cyst is mainly surgical. Anthelmintic chemotherapy alone is effective in only 30–40% of patients. It is most effective for pulmonary and essentially ineffective for the infection in other sites [1]. It is best treated by complete excision of the cysts. If it is impossible to excise a large cyst en-block, the cyst has to be drained intraoperatively, irrigated with a scolecidal agent and then partially excised. Rupture of cyst wall increases the likelihood of recurrent infestation [6].

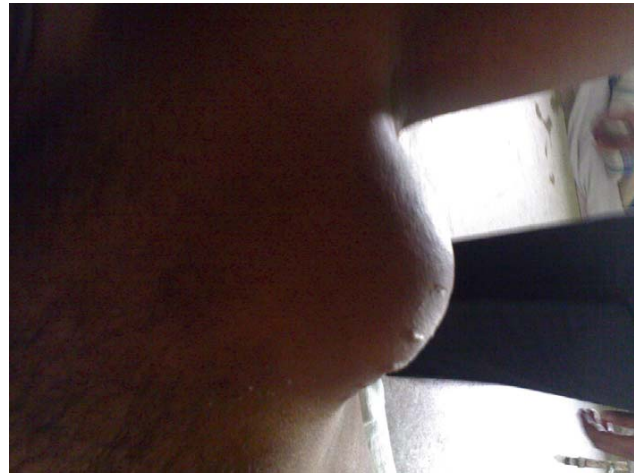


Fig. 1 Subcutaneous swelling in left lateral chest wall

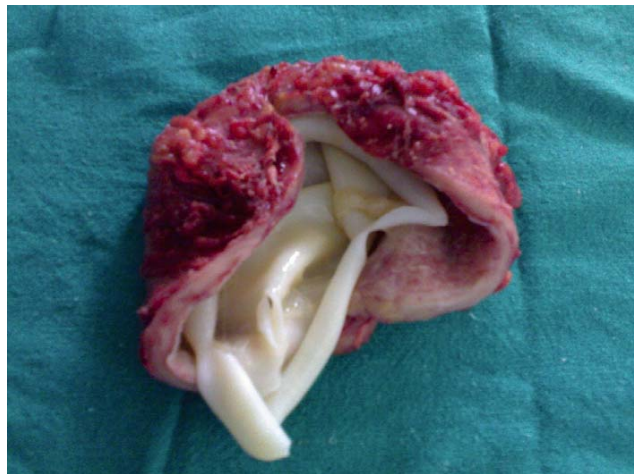


Fig. 2 Cut section of the hydatid cyst

Total cystectomy without any rupture of cyst was done in our case.

Recurrent hydatid cyst is defined as a new growth of an echinococcus cyst after complete surgical removal of the primary one [7] and its incidence has been reported as high as 23.3% [8].

In conclusion, although subcutaneous hydatid cyst is rare, it should be considered in the differential diagnosis of any cystic mass. So that preoperative and intraoperatively precaution can be taken to prevent any recurrence due to incomplete surgery or due to spillage of the cystic fluid.

Conflict of interest The authors do not have any disclosable interest.

References

1. Palanivelu C (2007) Laparoscopic management of hydatid cysts of the liver. *Art of laparoscopic surgery – Text book and Atlas*. Jaypee Publishers pp 757–783

2. Ok E, Sözüer EM (2000) Solitary subcutaneous hydatid cyst: a case report. *Am J Trop Med Hyg* 62(5):583–584
3. Chevalier X, Rhamouni A, Bretagne S, Martigny J, Larget-Piet B ((1994)) Hydatid cyst of the subcutaneous tissue without other involvement: MR imaging features. *Am J Roentgenol* 163(3):645–6
4. Zulfikaroglu B, Koc M, Ozalp N, Ozmen MM (2005) A rare primary location of echinococcal disease: report of a case. *Ups J Med Sci* 110(2):167–171
5. Munoz Sanz A, Idefonso JA, Saenz De Santamaria FJ. (1985) Hidatidosis de tejdo celular subcutaneo. *Med Clin (Barc)* 51: 645
6. Orhan Z, Kara H, Tuzuner T, Sencan I, Alper M (2003) Primary subcutaneous cyst hydatid disease in proximal thigh: an unusual localisation: a case report. *BMC Musculoskelet Disord* 4:25
7. Michail OP, Georgiou C, Michail PO, Felekouras E, Karavokyros I, Marinos G, Giannopoulos A, Griniatsos J (2007) Disappearance of recurrent intra-abdominal extrahepatic hydatid cyst following oral albendazole administration. *West Indian Med J* 56(4):372–375
8. Tsaroucha AK, Polychronidis AC, Lyrantzopoulos N, Pitiakoudis MS, Karayiannakis J, Manolas A et al. (2005) Hydatid disease of the abdomen and other location. *World J Surg* 29(9):1161–1165