

# Varicose veins: clinical presentation and surgical management

Goutham Reddy Kompally · R. N. Satish bharadwaj · Gurjit Singh

Received: 29 January 2009 / Accepted: 8 March 2009  
© Association of Surgeons of India 2009

## Abstract

**Background** Varicose vein is a common surgical problem. We studied clinical presentation of varicose veins and its surgical treatment.

**Material and methods** All patients with varicose veins presented to our hospital were included in the study. All patients in our study were assessed by clinico etiological Anatomical and pathological (CEAP) classification. Diagnosis was further confirmed by Duplex ultrasonography

**Results** Surgery was preferred for 34 out of 40 patients. Remaining 6 patients were treated conservatively because 3 patients were pregnant and 3 had deep vein thrombosis (DVT). We have used Trendelenburg's operation with stripping in 30 out of 34 cases. We find this method to be satisfactory.

**Conclusion** Meticulous clinical examination and surgical technique followed by closely monitored post operative management is required to reduce morbidity of varicose veins. Trendelenburg's operation with subfascial ligation has given good results in our set up.

**Keywords** Varicose veins · Venous ulcer · Thrombophlebitis · Lipodermatosclerosis.

## Introduction

Varicose veins are present in 20 to 25% of adult females and 10 to 15% of men in western countries [1]. This disease has attained national and industrial importance in western world because of its high prevalence. The disease is neglected by Indians. Moreover, dark complexion, costume habits of covering legs and disregard for aesthetic appearance and delay in seeking medical help adds to low incidence of reporting and protracted morbidity.

## Material and methods

All patients with varicose veins presented to our hospital were included in the study. All patients in our study were assessed by clinico etiological anatomical and pathological (CEAP) classification [2]. Diagnosis was further confirmed by Duplex ultrasonography.

## Results

Symptomatology of varicose veins varies greatly. Patients may present with complications like venous ulcer, bleeding or thrombophlebitis. In our study heaviness in legs was the most common symptom, 75% patients presented with it. Heaviness, itching & cramping were the common symptoms. This finding correlates with Edinburgh's vein study [3], which describes aching/ heaviness as the commonest symptom in women and itching as the commonest symptom in men.

---

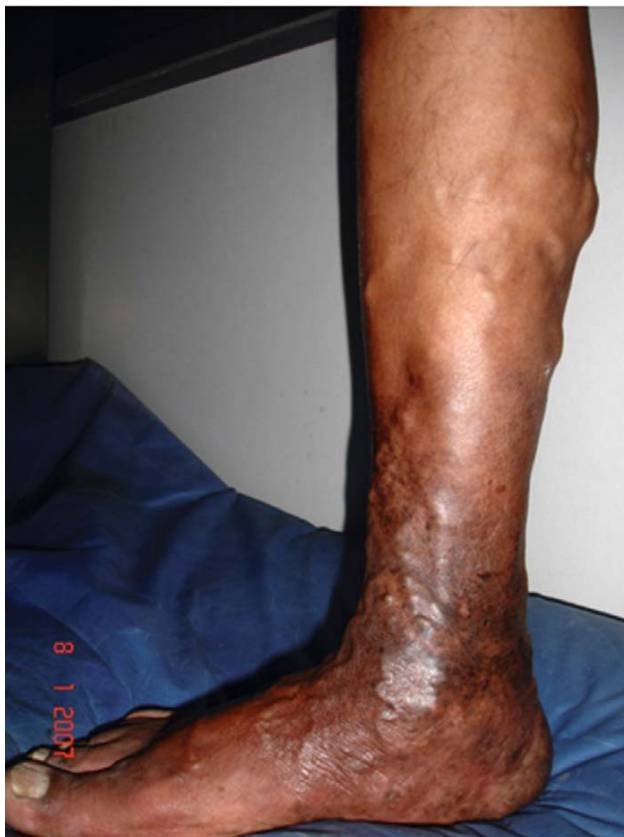G. R. Kompally · R. N. S. bharadwaj · G. Singh  
Department of Surgery,  
DY Patil Medical College Pimpri,  
Pune, India

G. R. Kompally (✉)  
E-mail: gouthamkompally@yahoo.com

In our study 32 patients presented with skin changes such as oedema, pigmentation (Fig. 1), eczema and ulcer. We noted that patients with skin changes were willing for treatment whereas only 4 patients came to hospital for cosmetic reasons. This is in contrast to western countries where significant number of patients come for cosmetic reasons.

**Table 1** Presenting symptoms

Symptoms	No. of cases	Percentage (%)
Aching	28	70
Heaviness	30	75
Itching	14	35
Cramping	20	50
Oedema	06	15
Pigmentation	10	25
Eczema	04	10
Ulcer	12	30
Cosmetic	04	10
Bleeding	-	-
Thrombophlebitis	1	2.5
Deep vein thrombosis	-	-
Pulmonary embolism	-	-



**Fig. 1** Varicose veins with pigmentation and lipodermatosclerosis over lower 1/3 rd of leg

Only one patient presented with thrombophlebitis. He was managed conservatively with antibiotics, analgesics, leg elevation and crepe bandage. He was operated 15 days later for varicose veins.

All the patients in our study were assessed by CEAP classification. CEAP system was found to be most practical and clinically important.

According to CEAP classification, class 2 & 3 patients with clinically and Doppler detected reflux underwent surgical treatment. All patients of Class 4, 5, 6 needed surgical treatment.

Duplex ultrasound examination was invariably used in all the 40 cases (unilateral in 30 cases and bilateral in 10 cases) and study reveals perforators incompetence as the commonest finding in 36 legs.

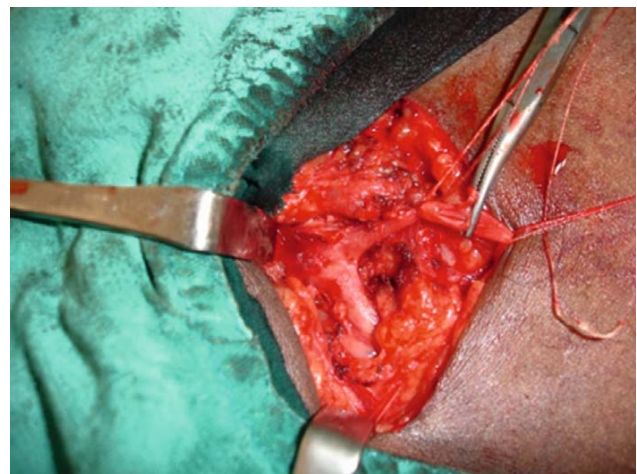
Thirty-four out of 40 patients were treated by surgery. Remaining 6 patients were treated conservatively because 3 patients were pregnant and 3 had DVT.

We have not used Trendelenburg's operation alone for superficial vein incompetence because high ligation of great saphenous vein without its removal will lead to high rate of recurrence [4]. Worldwide, Trendelenburg's operation is combined with other operations, commonest being stripping. Trendelenburg's operation is considered essential component of surgeries for all the superficial vein incompetence.

We have used Trendelenburg's operation (Fig. 2) with stripping in 30 out of 34 cases. We find this method to be satisfactory. Subfascial ligation was done in 4 patients in

**Table 2** Operations performed

Operation	No. of cases
Trendelenburg's operation + stripping + sub fascial ligation	27
Trendelenburg's operation +stripping	3
Sub fascial ligation	4



**Fig. 2** Saphenofemoral junction

patients with calf perforator incompetence with sapheno-femoral junction competence. Immediate success on the day of treatment was noted in 100% in patients treated with ligation and stripping [5].

Commonest complications in our series were wound infection in 4 patients, seroma formation in 4 patients and hematoma in 2 patients.

## Discussion

Varicose vein is a common surgical problem. The incidence of varicose veins varies among different populations. This condition is considered a national health problem in western countries. According to Callam [1], prevalence of varicose veins is 10–15% in men & 20–25% in women. We do not have statistical data of varicose veins in India but incidence in India is on the rise. This could be because of environmental factors and life style changes.

Patients with large varicose veins or patients with skin changes should be offered treatment specifically designed to avoid future ulceration. Peripheral arterial disease should be ruled out as a cause of patient's symptoms. Successful treatment of varicose veins requires a balance between their complete removal with treatment of underlying etiology and an optimal cosmetic outcome. So complete treatment of clinically symptomatic varicose veins must involve treatment of the saphenous vein reflux as well as the varicosities [4]. Superficial veins acts as collaterals in DVT. So, DVT is absolute contraindication to varicose vein surgery.

The presence of symptoms such as heaviness, aching or swelling and clinical or ultrasound evidence of saphenous vein reflux is generally accepted as indications for surgery. Obvious indications for surgery are skin changes ascribed to varicose veins, superficial thrombophlebitis and bleeding. According to British Vascular Surgical Society, the commonest indications are symptomatic and complicated varicose veins, 55% surgeons also perform surgery for cosmetic reasons [6].

In our study, out of 34 cases that had undergone varicose vein surgery, 26 reported back for follow up of upto 12–18 months. 4 patients had recurrence of varicose veins i.e. 12.5%. All the follow up cases were evaluated with color Doppler ultrasound studies. In recurrent cases 2 had incompetence of sapheno femoral junction who were treated with subfascial ligation during first time for calf perforators, were then treated with Trendelenburg's operation and stripping. Two patients, who had undergone Trendelenburg's operation and stripping during first time, underwent subfascial ligation for ankle perforators subsequently. Approximately 20% of varicose vein operations are performed for recurrent varicosities [7].

Trendelenburg's operation is an essential component of all varicose vein surgery and is done by flush ligation and division of tributaries (Fig. 2).

Important things to remember are

- Flush ligation to sapheno femoral junction/sapheno popliteal junction with least possible stump of great saphenous vein/short saphenous vein.
- Note anatomical variations and divide all the tributaries.

Stripping doesn't treat varicosities of tributaries. New varicosities develop at new sites which were not involved at the time of first treatment. Recurrence of reflux in a previously operated (high tie and stripping) great saphenous vein is due to revascularization of the strip track leading to further venous disease [8]. Successful treatment of varicose veins requires a balance between their complete removal with treatment of underlying etiology and an optimal cosmetic outcome. So complete treatment of symptomatic varicose veins must therefore involve treatment of the saphenous vein reflux as well as the varicosities [4].

The review of literature shows change in trend that surgeons taking help of the hand held Doppler for assessment of varicose veins as the clinical tests may be inaccurate [9, 10]. Hand held Doppler and Duplex ultrasonography provides details of distribution of varicosities and indicates whether reflux is present or not. While hand held Doppler is simple and inexpensive, it is easy to use in the outpatient department to check the venous system.

Newer techniques such as radio frequency ablation (RFA), Endovenous laser treatment (EVLT) and Transilluminated powered phlebectomy (TIPP) are available for the treatment of varicose veins. But these procedures are operator dependent and there is a definite learning curve necessary to achieve good results. Some of these new techniques may not prove to be effective in the hands of all treating specialists [4]. Expensive equipment required to perform these techniques is also a major limitation in developing countries like India.

Other method of treatment like stab avulsion phlebectomy is also available for treatment of symptomatic varicose veins. This can be used in patients presenting with incompetent perforators. We did not subject any patient to stab avulsion phlebectomy.

## Conclusion

Varicose vein is a chronic morbid condition. Most people present to us only after complications like pigmentation, eczema, lipodermatosclerosis and ulcer development.

Preoperative evaluation by colour Doppler ultrasound is essential and should be routinely done as it helps in planning surgery and reducing incidence of recurrence.

Meticulous clinical examination and surgical technique followed by closely monitored post operative management is required to reduce morbidity of varicose veins. Though newer techniques such as Endovenous laser treatment

(EVLV), Transilluminated powered phlebectomy (TIPP) and Radio frequency ablation (RFA) are available, Trendelenburg's operation with subfascial ligation has given good results in our set up.

Patient should always be followed up for detection of any recurrent or residual varicosities.

**Conflict of interest** The authors do not have any disclosable interest

## References

1. Callam MJ (1994) Epidemiology of varicose veins. *Br J Surg* 81 (2):167–173
2. Niren Angle, Julie A. Freischlag (2004) Venous disease. Sabiston Text book of surgery. 17th edition. Elsevier publishers, India, pp. 2053–2070
3. Bradbury A, Evans C, Allan P et al. (1999) What are the symptoms of varicose veins? Edinburg vein study cross sectional population survey. *Br M J* 318 (7180):353–356
4. Teruya TH, Ballard JL (2004) New approach for the treatment of varicose veins. *Surg Clin N Am* 84:1397–1417
5. Lurie F, Creton D, Eklof B et al. (2003) Prospective randomized study of endovenous radiofrequency obliteration versus ligation and stripping – EVOLVES Study. *J Vasc Surg* 38: 207–214
6. Lees TA, Beard JD, Ridler BM et al. (1999) A survey of the current management of varicose veins by members of the vascular society. *Ann R Coll Surg Engl* 81(6): 407–417
7. Perrin MR, Guex JJ, Ruckley CV et al. (2000) Recurrent varices after surgery (REVAS) – a consensus document REVAS group. *Cardiovasc Surg* 8 (4): 233–245
8. Munasinghe A, Smith C, Kianifard B et al. (2007) Strip track revascularisation after stripping of the great saphenous vein. *Br J Surg* 94:840–843
9. Kim J, Richards S, Kent PJ (2000) Clinical examination of varicose veins – a validation study. *Ann R Coll Surg Engl* 82 (3):171–175
10. Singh S, Lee TA, Donlon M et al. (1997) Improving the preoperative assessment of varicose veins. *Br J Surg* 84 (6): 801–802