

Has experience changed the scenario in laparoscopic adrenalectomy?

Abhay N. Dalvi · Pinky M. Thapar · Nalini S. Shah · Padma S. Menon

Received: 18 September 2008 / Accepted: 15 February 2009
© Association of Surgeons of India 2009

Abstract

Background Laparoscopic adrenalectomy (LA) is a relatively uncommon operation performed by surgeons with a specific interest in endocrine surgery as well as advanced laparoscopic surgery. LA is technically difficult and it is recommended to tackle small glands first till adequate experience is reached [1]. A minimum of 30 cases are required to master the technique [2]. The present study reviews data of 60 laparoscopic adrenalectomies comparing the later results with the first 30 cases.

Material and methods Starting 2001, patients diagnosed to have adrenal disorders were subjected to laparoscopic approach in a graded manner. A database was maintained with respect to age, sex, duration of symptoms, co-morbid conditions, diagnosis, size of tumor, weight of tumor, blood loss, duration of surgery, conversion to open, in-hospital stay, referral pattern, morbidity (both early and late) and mortality. The database was divided into two groups. First 30 patients constituted Group A, Group B constituted the next 30 adrenalectomies and deviation in the two was noted. Statistical analysis was performed to determine the importance of deviation of factors.

Results Sixty adrenalectomies were performed in 49 patients (11 being bilateral) between February 2001 and July 2008. Age group varied from 12–54 years with mean of 30.73 years, Twenty four were males. Thirty-one right and 29 left LA were performed. The comparison of factors in relation to the two groups (Group A and B respectively) revealed an increase in number of adrenalectomies performed (0.4 v/s 0.76) in relation to timeline, increased incidence of pheochromocytoma (6 v/s 18) and incidentalomas (zero v/s 8), larger tumor size (4.17 cm v/s 6.6 cm), comparable blood loss (72 cc v/s 98.3 cc) and duration of surgery (122 min v/s 112 min), increased conversion to open surgery (1 v/s 6) leading to increased in-hospital stay (2.8 days v/s 3.37 days) but a comparable morbidity (2 v/s 1) and no mortality.

Conclusion Though technically difficult, with increasing experience and focused approach, laparoscopic skills in adrenalectomy improves. The spectrum of indications broadens, thus making laparoscopic interventions for vascular and large adrenal glands safe and patient friendly.

Keywords Laparoscopic adrenalectomy. Pheochromocytoma. Large adrenal tumours

A. N. Dalvi¹ · P. M. Thapar¹ · N. S. Shah² · P. S. Menon²

¹Department of General Surgery,

²Department of Endocrinology,

King Edward VII Memorial Hospital and Seth G. S. Medical College,

Mumbai - 400 012, India

A. N. Dalvi (✉)

E-mail: abhaydalvi@hotmail.com

Introduction

Adrenalectomy is usually performed by surgeons with a specific interest or specialty training in endocrine surgery. The deep retro peritoneal location and close relation to vital structures makes this organ, the most feared of all. Open technique has a reported high morbidity and mortality. Since its description in 1992 [1]; laparoscopic

adrenalectomy (LA) is now an accepted modality of treatment in most adrenal disorders with advantages of less morbidity and decreased in-hospital stay. LA is technically demanding and requires advanced laparoscopic skill. It was therefore suggested that small glands should be tackled first till adequate experience is reached [1]. Goitein et al. [2] have suggested a minimum of 30 cases to master the technique of LA. A graded approach to achieve expertise also has been suggested [3]. The present study reviewed data of 60 adrenalectomies comparing the change of pattern in indications, size of tumor, duration of surgery, blood loss, morbidity and mortality after first 30 cases.

Material and methods

This study includes patients diagnosed with adrenal disorder requiring surgical intervention, who were subjected to LA from February 2001 to July 2008. The department of endocrinology primarily evaluated these patients.

From the surgical point, contrast-enhanced computerized tomography (CECT scan) or magnetic resonance imaging (MRI) were done in all cases to look for the size of the gland, relation to IVC on right side and renal vein on left side and presence or absence of lymph nodes.

Patients who have been excluded till date are with very large malignant tumors (> 15 cm), invasion of adjacent organs, recurrent adrenal tumors and patients who were in high risk due to cardiopulmonary disease. All the patients who were excluded for laparoscopic approach were operated by an anterior trans-abdominal approach.

After anesthesiology clearance, all patients were operated laparoscopically by lateral trans-abdominal flank approach. Electrocautery – predominantly monopolar coagulation, clips and recently harmonic scalpel were used for hemostasis. Regular follow up was done and delayed complications or after-effects of adrenalectomy were recorded.

A database was maintained with respect to age, sex, duration of symptoms, co-morbid conditions, diagnosis, size of tumor, weight of tumor, blood loss, duration of surgery, conversion to open, morbidity (both early and late) and mortality.

The database was divided into two groups:

1. Group A constituted the early experience – first 30 adrenalectomies
2. Group B constituted the next 30 adrenalectomies.

The database was analyzed comparing the two groups to see whether there is any deviation from our early experience with LA in Group A.

The factors analyzed for deviation were diagnosis, size of tumor, duration of surgery, blood loss, in-hospital stay, conversion to open surgery, morbidity (intra-operative and postoperative) and mortality. Intra operative morbidity included relevant episodes leading to conversion to open

surgery. Post operative morbidity included wound complications such as infection and herniation.

Statistical analysis was performed using chi-square test and student “t” test whichever when applicable.

Results

A total of 60 adrenalectomies were performed in 49 patients between February 2001 and July 2008. Of these, thirty-one were right adrenal tumors. There were 24 males and 25 females with a mean age of 30.73 years (range 12–54).

Eleven patients (n = 22) underwent bilateral laparoscopic adrenalectomy (BLA). Ten patients in Group A and 1 in Group B underwent BLA. The patient in Group B underwent simultaneous right adrenalectomy with cortical sparing left adrenalectomy for bilateral pheochromocytoma (n = 2).

Patients with Cushing’s disease/syndrome had smaller, normovascular glands and constituted major bulk (n = 20) in Group A. In comparison, Group B constituted more pheochromocytomas (n = 18) and incidentalomas (n = 8). The details of indications in each group are given in Table 1.

The first 30 patients (Group A) were operated over a period of 50 months (February 2001 to April 2005) resulting in an average operative rate of 0.4 adrenals a month in time line. The same changed to 0.76 (30 adrenalectomies in 38 months) from May 2005 July 2008 (p = 0.46), (Fig. 1).

The average size of the gland operated in Group A was 4.17 cm (range 3–6 cm) in diameter as compared to 6.6 cm (range 3–15 cm) in Group B; (p = 0.0001), (Fig. 2)

The mean duration of surgery in Group A was 122 min (range 40–270) as compared to 112 min (range 45–210) in Group B (p = 0.48), (Fig. 3).

The average blood loss in Group A was 72 cc (range 20–400 cc) as compared to 98.3 cc (range 20–300 cc) in

Table 1 Indications of LA

	Indication (patients)	Group A	Group B	Total
1.	Cushings disease* (n = 8)	16	nil	16
2.	Cushing’s syndrome			
	Solitary Adenoma	2	1	03
	Ectopic ACTH secreting* (n = 1)	2	nil	02
3.	Congenital Adrenal hyperplasia* (n = 1)	2	nil	02
4.	Pheochromocytoma			
	Unilateral	6	16	22
	Bilateral* (n = 1)	nil	02	02
5.	Conn’s syndrome	2	03	05
6.	Incidentaloma > 6cm	nil	08	08

*Bilateral adrenalectomy

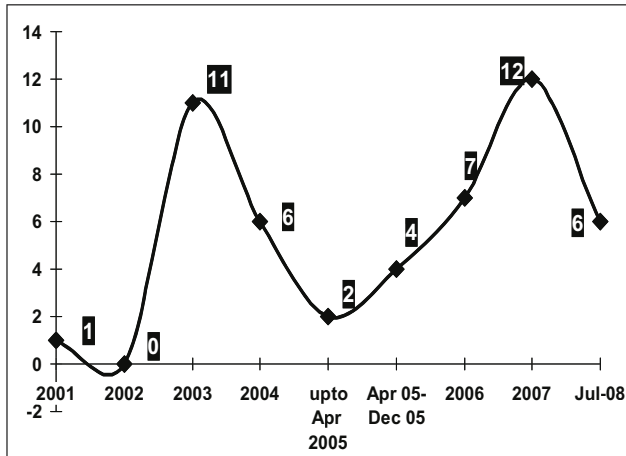


Fig. 1 Referral pattern – Timeline

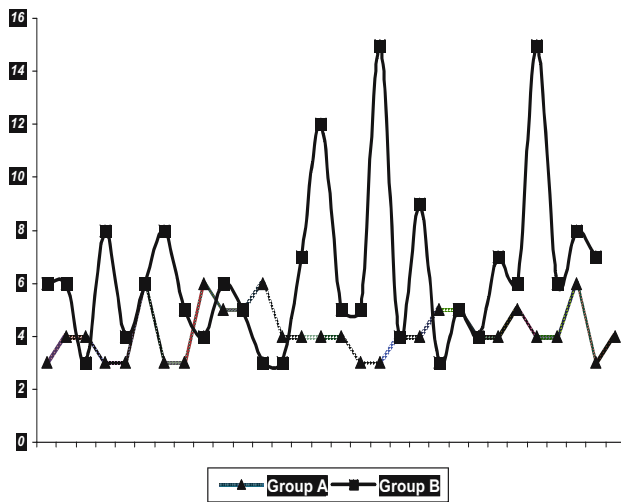


Fig. 2 Size of gland (cm)

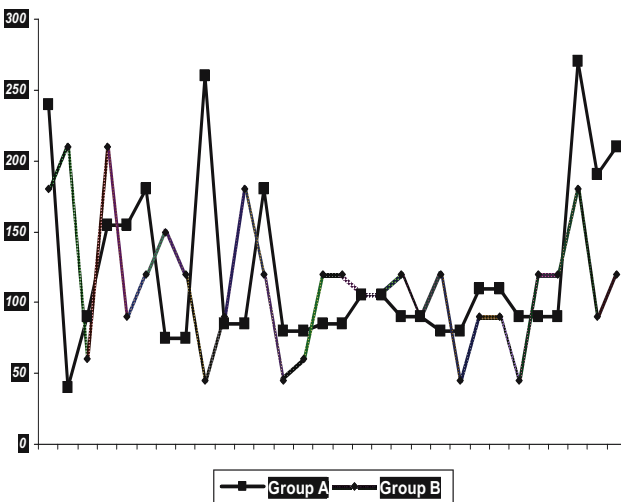


Fig. 3 Duration of surgery (min)

Group B ($p = 0.27$). Intra operative single unit of blood was transfused to three patients in Group A and four patients in Group B as desired by the anesthesiologist. Bleeding was the cause for conversion in one case in group A. In Group B, six patients were categorized as converted. One was pregnant female in second trimester of pregnancy that was converted early to prevent excessive blood loss that would harm the fetus. One patient had 15 cm tumor with renal artery encasement not reported on CT scan, hence converted; histopathology was adrenocortical sarcoma. One patient had paraganglioma in aorta caval window which was converted after major dissection to avoid injury to inferior vena cava and left renal vein which was in close proximity. Two of the patients with tumor size > 12 cm required an incision for intact retrieval and deemed converted, hence actual conversion being 4 in Group B ($p = 0.196$).

The surgical in hospital stay was comparable in both the Groups – one to four days in Group A (mean 2.8 days) and one to six days in Group B (mean 3.37 days), ($p = 0.014$). The results with statistical analysis of all the factors are depicted in Table 2.

Minor complications like wound infection were observed in two patients (both Group A), while one patient developed a port site hernia in Group B. This patient had adrenal abscess and developed the hernia at specimen delivery port.

Discussion

Since the initial report of laparoscopic adrenalectomy in 1992 [4], indications for laparoscopic intervention have evolved. The contraindications of yesteryears have been categorized as indications today. Tsuru et al. [5] state that LA is now the gold standard in treatment of most adrenal tumors. Large malignant tumors that were a relative contraindication have now been tackled laparoscopically [6, 7].

Anatomical location and important surrounding structures renders a real challenge to a laparoscopic surgeon. A special interest in adrenal surgery coupled with advanced laparoscopic skills is required to achieve better results. Gagner had suggested that smaller glands be tackled before advancing on to larger tumors due to steep learning curve [1]. Goiten et al. echoed Gagner’s suggestion and recommended at least thirty cases for mastery of the procedure [2]. In this study therefore, outcome of Group A that consisted first thirty adrenalectomies is compared with the following 30 cases that have been done till date.

Gagner’s policy of graded interventions was adopted during the initial period of learning curve and the authors after first thirty cases (Group A) embarked onto more vascular and larger tumors. The infrequent occurrence of adrenalectomy even at tertiary care hospitals is partly responsible for ample time required to gain experience in this surgery [8]. The study reveals that while it took us 50 months to do our

Table 2 Summary of results

Factors	Group A (n = 30)	Group B (n = 30)	Chi – sq/ “t” test	P VALUE P</0.05
Frequency of referral (per month)	0.4	0.76	–0.79	0.46 (NS)
Average size of tumor (cm)	4.17	6.6	–4.09	0.0001 (S)
Average duration of surgery (min)	122	112	0.719	0.48 (NS)
Average blood loss (ml)	72	98.3	–1.11	0.27 (NS)
Average in-hospital stay (days)	2.8	3.37	–2.57	0.014 (S)
Conversion to open surgery	1	4	1.665	0.196 (NS)
Pheochromocytomas	6	18	4.375	0.0365 (S)
Incidentalomas (> 6 cm)	0	8	7.158	0.0075 (S)\

S- Statistically significant: tumor size, In hospital stay, Pheochromocytoma, Incidentalomas

NS- Statistically not significant: Frequency of referral, duration of surgery, blood loss, conversion

first 30 cases that comprised Group A (giving an average of 0.4 adrenals a month), the next 30 cases of Group B have been performed in 38 months (average 0.76 a month). By increase in referrals and frequency of surgery, an increased demand for laparoscopic approach is well underlined. This reflects that increasing experience improves the proficiency of a laparoscopic surgeon in the procedure of LA.

The change in pattern of indications for which patients were subjected to LA in the two Groups is well seen. There were more of Cushing’s and other disorders which have smaller glands in Group A. In fact 20 of the 30 (66.6%) adrenalectomies in Group A were for Cushing’s. Of these 20, 18 adrenalectomies were performed in 9 patients for Cushing’s syndrome. Due to 30% incidence of Nelsons syndrome and availability of newer and better medical management, it was collectively decided not to offer bilateral laparoscopic adrenalectomy as a modality to patients of Cushing’s disease. Attainment of skills to perform laparoscopic LA was completed however. Similar changes in indications and frequency of referral pattern has also been observed in series of 75 laparoscopic adrenalectomies by Maccabee et al. [8].

Pheochromocytoma is highly vascular tumor of the adrenal gland. It also evokes a desmoplastic reaction making dissection difficult and prone to bleeding. There are parasitic vessels which may bleed inspite of control over adrenal artery and vein. Poulin and colleagues have shown that worst outcomes in LA are associated with removal of pheochromocytomas [9]. As is seen from the study, with experience, 18 pheochromocytomas were successfully operated in Group B as compared to 6 in Group A. ($p = 0.0365$) Optimization of preoperative condition in the form of α and β blockers and adequate peri-operative hydration is the key to success in tackling pheochromocytomas.

Incidentalomas are incidentally detected tumors of the adrenals that are non-secretory in nature. Tumors greater than 6 cm are potentially malignant and hence require removal [10]. In this study, it is evident that tumors greater than 6 cm were tackled only after the first thirty adrenalectomies ($p = 0.0001$). Of these 8 cases, one patient had adre-

nocortical sarcoma, rest seven were benign. Histopathology showed adenomyolipoma in four patients, adrenal abscess, schwannoma, and tuberculosis (one each) in the remaining three cases.

The average size of adrenal gland removed in Group A was 4.17 cm as compared to 6.6 cm in Group B. The largest tumor tackled was 15 cm in diameter. Overall 22 patients had tumor size 6 cm and above; 4 patients in group A and 18 in Group B. It is clear that after the initial success in small adrenal tumors, authors were able to tackle larger and more vascular tumors and was in concurrence with Gagner’s suggestion [1]. Size of the gland is a relative contraindication, laparoscopic intervention in tumor 15 cm or greater though contraindicated in some series, has been reported by Hamilton and Prinz [11, 12]. We observed that large adrenal tumors overhang and lie in close proximity to renal vessels; and even if one tackles the adrenal vein early in the course of dissection, manipulation and separation in this plane is technically difficult. This is especially true for left sided adrenal tumors. Specimen retrieval in large adrenal masses (suspected to be malignant) is challenging since there should not be any breach in capsule of the tumors [13]. Hence we extend the lateral one or two ports for safe and easy retrieval preventing any capsular rupture during retrieval that has been included in “overall” conversion to open in two cases.

The mean operating time for LA is reported to be anywhere between 107 to 288 min [14, 15]. Chan et al. [16] have compared the operative times for different adrenal pathologies and found no statistical significance. In the present study, it is seen that the mean operative times in both the groups have been comparable to literature reports and are consistent irrespective of pathology or the size of the tumor. It is evident that more difficult adrenals (Group B) can be tackled within an acceptable time frame of experience.

The average blood loss in Group A was 72 cc when compared to 98.3 cc in Group B. Though not significant, it is important to note that the indications for which patients were subjected to adrenalectomies in Group B were more challenging when compared to those in Group A. Though

pheochromocytomas are vascular tumors, laparoscopic excision is safe with acceptable blood loss and less hemodynamic instability. Similar positive outcome has also been documented by Kercher et al. in their series of 80 cases of pheochromocytomas [17].

Various series of unilateral adrenalectomies have reported a conversion rate of 0 to 11% [14,18]. The overall conversion rate in this study was 11.66% that is comparable with literature. There was one conversion due to bleeding in Group A (3.33%). The conversion in Group B was deemed to be 20% (6 in 30 cases). Bleeding was the cause of conversion in two patients of large pheochromocytomas (size 8 cm), technical difficulty in one patient of paraganglioma in the aorta caval window and local invasion in patient of sarcoma. Two patients were deemed as converted since they required incisions for intact retrieval of large tumors. Therefore, true conversion was 13.33% in Group B (four of 30 adrenalectomies), that is comparable to literature reports for large tumors [19]. Technical difficulty in large adrenal masses due to size, parasitic vessels and compromised working space is also echoed by Rosoff et al. [20]. Hand assisted laparoscopic adrenalectomy has been recommended by Shen et al. [21] in his series of 261 cases where this option benefited in large, adherent, or malignant adrenal masses. Retrospectively, we feel that hand assisted approach could have been used in two of our cases. We recommend that large adrenal masses should be tackled only by experienced laparoscopic surgeons and there should be low threshold for conversion or use of hand port.

The average surgical in-hospital stay differed in the two groups. The increased stay in Group B was due to need for incision in large tumors in this group. No additional difference in post operative course and outcome in patients with large adrenal tumors was seen in our study and as seen by Parnaby et al. [22].

Various complications ranging from hemorrhage to adjacent organ injury either due to adrenal disease or minimally invasive technique have been reported in literature [23]. In this series of 60 patients, we did not encounter any major complication. Minor complications were observed in three of 60 adrenalectomies performed in 49 patients (5%) that were comparable to reported studies [2, 3, 24]. Two patients in Group A developed wound infection that was treated with antibiotics while one patient in Group B developed incisional hernia. There was no mortality in the present series.

Co-ordination between single team of advanced laparoscopic surgeons, endocrinologist and anesthesiologists with interest in LA helps to minimize complications.

Conclusion

Though technically difficult, with increasing experience, there seems to be a change in frequency of referral of patients with adrenal disorders for laparoscopic intervention.

The spectrum of indications broadens with increased laparoscopic interventions for vascular and large glands. Size of the tumor does not become a bar to laparoscopic intervention. Average duration of surgery and blood loss remain comparable. Though chances of requirement of hand-assist or open surgery thru limited incision in larger tumors may increase, the overall morbidity remains same; thus giving the benefit of minimal access to most patients with large and vascular adrenal tumors. We conclude that, with commitment and increased volume of work, proficiency and end point in laparoscopic adrenalectomy improves.

Conflict of interest The authors do not have any disclosable interest

References

- Gagner M, Pomp A, Heniford BT, Pharand D, Lacroix A (1997) Laparoscopic adrenalectomy: Lessons learned from 100 consecutive procedures. *Ann Surg* 226:238–246
- Goitein D, Mintz Y, Gross D, Reissman P (2004) Laparoscopic adrenalectomy: ascending the learning curve. *Surg Endosc* 18:771–773
- Dalvi AN, Thapar PM, Vijay KK, Kamble RS, Rege SA, Deshpande AA et al. (2006) Laparoscopic adrenalectomy: Gaining experience by graded approach. *J Min Access Surg* 2:59–66
- Gagner M, Lacroix A, Bolte E (1992) Laparoscopic adrenal-ectomy in Cushing's syndrome and pheochromocytoma. *N Eng J Med* 327:1033
- Tsuru N, Suzuki K (2005) Laparoscopic adrenalectomy. *J Min Access Surg* 1:165–172
- Moinzadeh A, Gill IS (2005) Laparoscopic radical adrenal-ectomy for malignancy in 31 patients. *J Urol* 173:519–525
- Naya Y, Suzuki H, Komiya A, Nagata M, Tobe T, Ueda T, et al. (2005) Laparoscopic adrenalectomy in patients with large adrenal tumors. *Int J Urol* 12:134–139
- Maccabee DL, Jones A, Domreis J, Deveney CW, Sheppard BC (2003) Transition from open to laparoscopic adrenalectomy: The need for advanced training. *Surg Endosc* 17:1566–1569
- Poulin EC, Schlachta CN, Burpee SE, Pace KT, Mamazza J (2003) Laparoscopic adrenalectomy: pathologic features determine outcome. *Can J Surg* 46:340–344
- NIH state-of-the-science statement on management of the clinically inapparent adrenal mass ('incidentaloma') (2002) *NIH Consens State Sci Statements* 19:1–25
- Hamilton BD (2001) Trans peritoneal laparoscopic adrenalectomy. *Urol Clin North Am* 28:61–70
- Prinz RA (1995) A comparison of laparoscopic and open adrenalectomies. *Arch Surg* 130:489–494
- Palazzo FF, Sebag F, Sierra M, Ippolito G, Souteyrand P, Henry JF (2006) Long-term outcome following laparoscopic adrenalectomy for large Solid adrenal Cortex tumors. *World J Surg* 30:893–898
- Castilho LN (2004) Laparoscopic adrenalectomy—experience of 10 years. *Arq Bras Endocrinol Metab* 48: 776–783

15. Fernandez-Cruz L, Saenz A, Benarroch G, Astudillo E, Taura P, Sabater L (1996) Laparoscopic unilateral and bilateral adrenalectomy for Cushing's syndrome. Trans peritoneal and retro peritoneal approaches. *Ann Surg* 224:727–736
16. Chan JE, Meneghetti AT, Meloche RM, Panton ON (2006) Prospective comparison of early and late experience with laparoscopic adrenalectomy. *Am J Surg* 191:682–686
17. Kercher KW, Novitsky YW, Park A, Matthews BD, Litwin DE, Heniford BT (2005) Laparoscopic curative resection of pheochromocytomas. *Ann Surg* 241:919–926
18. Rossi H, Kim A, Prinz RA (2002) Primary hyperaldosteronism in the era of laparoscopic adrenalectomy. *Am Surg* 68: 253–256
19. Shen Z.J, Chen S.W, Wang S, Jin X.D, Chen J, Zhu Y, Zhang RM (2007) Predictive factors for open conversion of laparoscopic Adrenalectomy: A 13 year review of 456 cases. *J Endourol* 21:1333–1337
20. Rosoff JS, Raman JD, Del Pizzo JJ (2008) Laparoscopic adrenalectomy for large adrenal Masses. *Curr Urol Rep* 9: 73–79
21. Shen WT, Kebebew E, Clark OH, Duh QY (2004) Reasons for conversion from laparoscopic to open or hand-assisted laparoscopic adrenalectomy: Review of 261 laparoscopic adrenalectomies from 1993 to 2003. *World J Surg* 28: 1176–1179
22. Parnaby CN, Chong PS, Chisholm L, Farrow J, Connell JM, O' Dwyer PJ (2008) The role of laparoscopic adrenalectomy for adrenal tumors of 6cm or greater. *Surg Endosc* 22:617–621
23. Strebel TR, Muntener M, Sulser T (2008) Intra operative complications of laparoscopic adrenalectomy *World J Urol* May 15 (Epub ahead of print)
24. Assalia A, Gagner M (2004) Laparoscopic adrenalectomy. *Br J Surg* 91:1259–1274