

Atypical case of periapical adenomatoid odontogenic tumour

Received: 24 October 2008 / Accepted: 05 January 2010
© Association of Oral and Maxillofacial Surgeons of India 2009

Abstract The Adenomatoid Odontogenic Tumour (AOT) is a progressively growing asymptomatic benign non-invasive lesion. A rare subvariant of the extrafollicular type of AOT may mimic periapical disease radiographically. We report a 45-year-old male with a periapical radiolucent lesion affecting maxillary central incisor tooth. Initially suspicious of periapical pathology, although clinical findings seemed to indicate a nonendodontic cause. The lesion was surgically explored and histopathological examination revealed the presence of AOT. This particular subvariant is very rare indeed, as available literature only 8 cases have been reported.

Keywords AOT · Extrafollicular · Periapical type · Superimposed extrafollicular AOT

Introduction

Adenomatoid Odontogenic Tumour (AOT) is a relatively uncommon distinct odontogenic neoplasm that was first described by Steenland in 1905 [1]. Steenland's report from 1905 of 'Epithelioma adamantinum' represents the earliest publication of an AOT [2]. However, a variety of terms have been used to describe this tumour. Unal et al. produced a list containing all nomenclatures for AOT reported in the literature. Many different names like adenoameloblastoma, ameloblastic adenomatoid tumour, adamantinoma, epithelioma adamantinum or teratomatous odontoma have been used before to define the lesion currently called AOT. Pindborg JJ et al. 1971 reported that Philipsen and Birn [3] introduced the above term (AOT), which adopted by the WHO classification in 1971.

Adenomatoid Odontogenic Tumour (AOT) is a progressively growing benign non-invasive lesion accounts for 2.2–13% of all odontogenic tumours. AOT usually affects young patients, mostly during their second decade of life. There is a slightly higher tendency to affect females.

Male : female ratio 1:2 [4].

The benign non-invasive AOT appears in 3 variants:

1. Follicular, 2. Extrafollicular, 3. Peripheral types.

Follicular and extrafollicular variants which accounts for 97% of all the AOT's are both intrabony and central tumours. Follicular type forms the majority in the intrabony type. The extrafollicular variant is not associated with an unerupted tooth like the follicular variant. The unilocular radiolucency in extrafollicular variant is found between, above, or superimposed on the roots of erupted teeth. This atypical subvariant mimics periapical lesion and usually located palatal to the involved tooth [3]. It has been theorized that the complex system of the dental laminae or its remnants is the likely origin of the AOT mimicking a periapical radiolucent lesion of the maxillary incisor area [5].

Case report

A 45-year-old male patient reported to Oral Medicine Clinic of our Institute with a complaint of 10 months old asymptomatic swelling in his left periapical region of the jaw which was gradually increasing and attained the present size (Fig. 2). Intra-oral clinical examination revealed a firm, non fluctuant and non tender sessile, predominantly normally colored, smooth surfaced, 2 cm swelling associated with the

Avinash Tejasvi ML¹✉ · Prashanth Shenai K² · Laxmikanth Chatra³

¹ Senior Lecturer, Kamineni Institute of Dental Sciences, Andhra Pradesh

² Professor

³ Senior Professor and HOD

Dept. of Oral Medicine and Radiology, Yenepoya Dental College, Mangalore

Address for correspondence:

Avinash Tejasvi ML
Senior Lecturer
Dept. of Oral Medicine and Radiology
Kamineni Institute of Dental sciences
Narketpally, Nalgonda dist
Andhra Pradesh, India
Ph: 09246916062
E-mail: avinash_tejaswi@yahoo.co.in

left maxillary central incisor. Tooth did not show any coronal pathologic condition and electric pulp testing did not show any response which proved the tooth to be non vital. Patient's medical history was noncontributory. Occlusal radiograph (Fig. 3) showed a well-defined, round to oval radiolucent lesion involving the periapical area of left maxillary central incisors. However the lamina dura related to the affected tooth was interrupted. Periapical pathology was considered and a differential diagnosis of radicular cyst was considered and advised surgical excision of the lesion. An exploratory surgical approach was chosen. Under local anesthesia, mucoperiosteum flap was reflected, cortical bone was perforated and a solid, noncystic tissue mass was removed. Perforation of the facial bone plate by the lesion was not observed during the surgical procedure. Excised specimen was sent for histopathologic examination which proved to be an AOT. Healing was uneventful, histologically a typical lesion composed of odontogenic epithelial cells arranged in ductal pattern. A capsule surrounding these cells is also seen (Fig. 4) and odontogenic epithelial cells arranged in ductal forms. The presence of eosinophilic coagulum and proliferation of spindle cells are evident. Highly cellular fibrous stroma is also seen which typically suggested AOT (Fig. 5). A

six month follow-up was done which showed normal bone healing (Fig. 6).

Discussion

In the reported case of AOT the clinical, radiographic, and surgical features show that it was located within the periapical region of left maxillary central incisors. The benign (hamartomatous) noninvasive AOT appears in 3 clinicotopographic variants: follicular, extrafollicular, and peripheral [6]. Radiographical representation of these variants are shown in the Fig. 1 as follows.

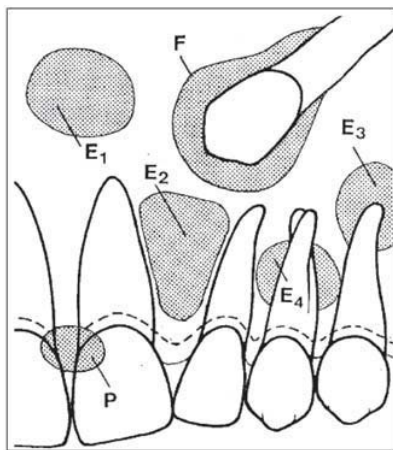


Fig. 1 Radiographic appearance of Adenomatoid odontogenic tumour (AOT) Intraosseous variants

F: Follicular type: The tumour is located around the crown and often as shown here including part of the root of an unerupted tooth
E1–E4: Extrafollicular types

E1: Without relation to tooth structures neither erupted nor unerupted

E2: Inter-radicular; adjacent roots diverge apically due to tumour expansion

E3: Superimposed at root apex level (radicular/periapical)

E4: Superimposed at mid-root level.

Extraosseous variant

P: Peripheral or epulis type (with slight erosion of bone)

Courtesy: H.P. Philipsen, P.A. Reichart/ Oral Oncology 35 (1998) 125–13.

Follicular variety is associated with unerupted teeth. The extrafollicular type is, on the other hand, not associated with an unerupted tooth and a well defined, unilocular radiolucency is found between, above or superimposed upon the roots of erupted, permanent teeth. These locations often lead to the preoperative, tentative diagnosis of a residual, radicular, globulo-maxillary or lateral periodontal cyst depending on the actual intraosseous site of the lesion. The

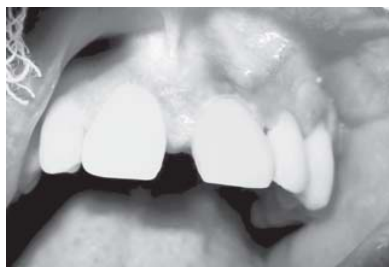

Fig. 2 Intra-oral swelling in the labial vestibule in relation to left maxillary central incisor

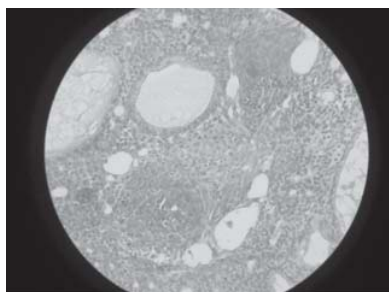


Fig. 4 Photomicrograph showing typical lesion composed of odontogenic epithelial cells arranged in ductal pattern. A capsule surrounding these cells is also seen

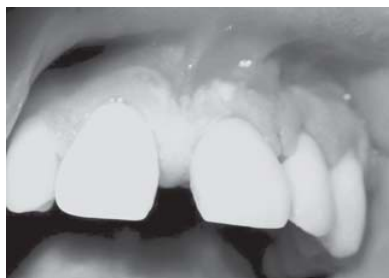

Fig. 6 Postoperative appearance of the surgically explored site after 6 months

current case had a classic feature of periapical variant of extrafollicular AOT. Philipsen HP et al. (2002) stated a case report of periapical variety of AOT along with the supported literature of 7 cases [6]. Growth of the intrabony variants commonly results in cortical expansion. Displacement of neighboring teeth due to tumour expansion is much more common than root resorptions. Radiographically reported case neither was causing bone expansion nor resorption. The peripheral variant appears as a gingival fibroma or epulis attached to the labial gingiva. This type of AOT may show slight erosion of the alveolar bone crest but radiographic changes are often difficult to detect [8].

It is some time referred to as two thirds tumour because about two thirds occur in maxilla, two thirds occur in

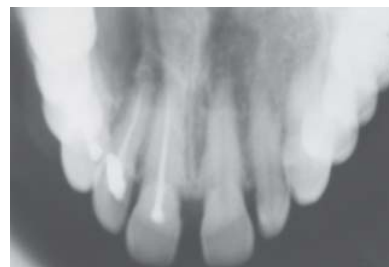

Fig. 3 An occlusal radiograph showing well defined radiolucency at the periapical area of left maxillary central incisors

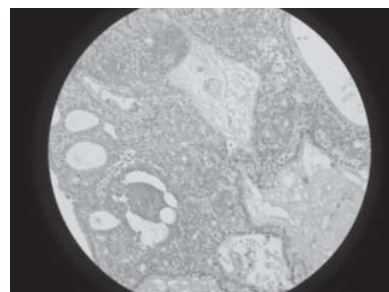


Fig. 5 Photomicrograph showing odontogenic epithelial cells arranged in ductal forms. The presence of eosinophilic coagulum and proliferation of spindle cells is evident. Highly Cellular fibrous stroma is also seen

young women (preteen and teenage years) but both was not present in our case which was unique, two thirds are associated with and unerupted tooth and two thirds of those teeth are canine teeth. The two thirds statistics vary slightly but the rough distribution is accurate [9].

Since the Adenomatoid Odontogenic Tumour (AOT) is a benign tumour that presents with a non-aggressive, progressive growth, small frequency of recurrence, absence of invasion, and the frequent presence of a connective tissue capsule, the treatment should consist of enucleation and curettage [10]. In this case surgical enucleation was carried out after reflection of a mucoperiosteal flap. Enucleation was achieved by separation of the lesion from bone without perforating the capsule.

Conclusion

The fact that this particular subvariant is very rare indeed makes this case a special one. Adequate diagnostic procedures and accurate interpretation of clinical and radiographic findings may result in an appropriate diagnosis, which otherwise may result in unnecessary endodontic treatment.

References

1. Steenland HS (1905) Epithelioma adamantinum. *J Exp Med* 6(4–6): 377–389
2. Unal T, Cetingul E, Gunbay T (1995) Peripheral Adenomatoid odontogenic tumour: Birth of a term. *J Clin Pediatr Dent* 19(2): 139–142
3. Pindborg JJ, Kramer IRH (1971) WHO International histological classification of tumours. no. 5. Histological typing of odontogenic tumours, jaw cysts and allied lesions. 1st ed. Berlin: Springer Verlag
4. Jham BC, Passos JB, Carmo MAV, Gomes CO, Mesquita RV (2006) Adenomatoid Odontogenic tumour originated in the periodontal ligament. *Oral Oncology Extra* 42(7): 268–271
5. Dare A, Yamaguchi A, Yoshiki S, Okano T (1994) Limitation of Panorami Radiography in Diagnosing Adenomatoid odontogenic tumours. *Oral Surg Oral Med Oral Pathol* 77(6): 662–668
6. Philipsen HP, Srisuwan T, Reichart PA (2002) Adenomatoid Odontogenic tumour mimicking a periapical (radicular) cyst: A case report. *Oral Surg Oral Med Oral Pathol Oral Radiol Endod* 94(2): 246–248
7. Dare A, Yamaguchi A, Yoshiki S, Okano T (1994) Limitation of panoramic Radiography in diagnosing Adenomatoid odontogenic tumours. *Oral Surg Oral Med Oral Pathol* 77(6): 662–668
8. Philipsen HP, Reichart PA (1998) Adenomatoid odontogenic tumour: facts and figures. *Oral Oncol* 35(2): 125–131
9. Marx ER (2003) Oral maxillofacial pathology A Rationlae for diagnosis and Treatment Quintessence publishing co, inc
10. Shetty K, Vastardis S, Giannini P (2005) Management of an unusually large Adenomatoid odontogenic tumour. *Oral Oncology Extra* 41(10): 316–318

Source of Support: Nil, **Conflict of interest:** None declared.