J Maxillofac Oral Surg 8(1):22–26

TECHNICAL NOTE

Alveolar bone grafts distal to the lower second molar

Coceancig PLG ✉

Specialist, Oral and Maxillofacial Surgeon, Australia

Received: 07 May 2008 / Accepted: 15 January 2009
© Association of Oral and Maxillofacial Surgeons of India 2009

Abstract
Introduction This paper presents case and technique reports on the use of Bio-Oss® and Bio-Gide® implantable material for the establishment of a mineral and protein scaffold for reconstruction of the distal alveolus of the lower distal second molar (lower dM2).
Methods Such 'alveolar bone grafts' were undertaken immediately following the removal of deep horizontal or mesio-angular impacted wisdom teeth, and which had the following associations. 1) Partial eruption of the third molar, 2) Preoperative radiographic (OPG) evidence of loss of bone height (≥3mm) below the distal Cemento-Enamel Junction (CEJ) of the lower dM2, and 3) Patient aged ≥26 years of age. Following a presentation of radiographs (in three patients) taken preoperatively and postoperatively (at ~6 months), a brief description of the technique is offered as well as a brief literature review on the subject.
Conclusion The author suggests that for older patients (≥26 years) were there is the presence of partially exposed deep mesio-angular or horizontal impacted wisdom teeth, and which are associated with the radiographic appearance of bone loss to the distal surface of the lower second molar tooth, then alveolar bone grafting utilising Bio-Oss® and Bio-Gide® is an effective and stable treatment option to prevent development of periodontal pocketing in the area. The author advises for more guided and systematised study in this area.

Keywords Alveolar bone graft · Bio-Oss® · Bio-Gide® · Lower dM2 · Distal second molar

Address for correspondence:

Coceancig PLG
Suite 4, 2nd Floor, Boardwalk North
1 Honeysuckle Drive
Newcastle 2300, Australia
Ph: +61 2 4927 5177
Fax: +61 2 4927 5996
Email: manager@oceansurgical.com.au

Introduction

The risk for development of periodontal defects to the distal surface of the lower second molar tooth (dM2) from impacted lower wisdom teeth is usually difficult to predict for, and equally difficult to treat once established. There is widespread belief that the established or potential dM2 pocket will spontaneously resolve from removal of an impacted third molar, or if they do develop are amenable to traditional therapy provided through periodontology. What formal research existing in this regard has determined that periodontal defects to the lower dM2 are widespread following late removal of wisdom teeth (in patients aged ≥26 years), and that such defects are not preventable through simple third molar removal, or with concurrent surgical therapy such as traditional root planning, Guided Tissue Regeneration (GTR), or simple local curettage and debridement.

General dental practitioners are at the forefront of diagnosing for occult and asymptomatic dental disease, and which includes screening for occult impacted teeth. Early (≤20 years) removal of (the impacting) third molar is definitively associated with a decreased rate of persisting periodontal defects to the dM2 [18]. By contrast, late removal (age ≥26 years) is definitively associated with the development of lower dM2 pockets, especially where there is partial eruption of the third molar, and where there is either mesio-angular or horizontal impaction leading to loss of bone below the lower dM2 Cemento-Enamel Junction (CEJ).

Case descriptions

Case 1

A 31-year-old male had a deep horizontally impacted 38 (lower left mandibular 3rd molar) tooth, with overlying pericoronitis and gingival breakdown, and partial eruption of the disto-occlusal 38 crown. OPG demonstrated loss of the coronal 2/3rds of the 37 disto-buccal bone. Operation to remove the third molar was followed by local alveolar bone graft (0.25gm Bio-Oss® and overlay 13 x 25mm Bio-Gide® membrane). Follow up OPG was at 5 months, with asymptomatic 37 (left lower second molar) and normal disto-buccal mucosa and probing depth, with regeneration of at least 80% of lost distal alveolar height.

Case 2

A 28-year-old male patient had mesio angular impacted 38 (left mandibular third molar) tooth on background of recurrent periocoronitis, and partial exposure of the 38 occlusal face. OPG demonstrated apical bone loss beneath the mesial aspect of the 38, affecting the distal bone integrity to the 37. Operation to remove the 38 was followed with local alveolar bone graft (0.25gm Bio-Oss® and overlay 13 x 25mm Bio-Gide® membrane). Follow up at 10 months demonstrated normal disto-buccal mucosa, and probing depth, and an asymptomatic and healthy 37.

Case 3

A 34-year-old female patient presented with a substantially deep mesio angular impacted 48 tooth. OPG showed bone loss extending half way down the distal surface of the 47 tooth which was sensitive to cold. The 48 tooth was removed and alveolar bone graft followed (using 0.25gm Bio-Oss® and overlay 13 x 25mm Bio-Gide® membrane). At 6 month review, there was normal consolidation of bone to the height of the distal CEJ, and normal probing depths alongside the disto-buccal mucosa.

Technique description

A buccal envelope flap, with the sulcular incision to the mid-buccal portion of the lower second molar is made, and exposure is to the distal alveolus behind the impacted lower third molar. A small lingual flap is raised, to expose the lingual rim of alveolus. Aim was to remove the lower third molar in as many portions as possible, with minimal loss of surrounding bone. The lower dM2 area and the pericoronal alveolus should be thoroughly debrided of all epithelial and follicular remnants with a sharp curette. The author suggests co-use of 4x magnification loupes (at 50 cm focal depth) in this regard.

The technique utilises 0.25gm of Bio-Oss® and 13 x 25mm sheeting of Bio-Gide® per defect. The aim in using Bio-Oss® is to provide an even dispersal (or colloidal suspension) of mineral throughout the blood clot, so dense packing is not necessary. Capillary budding into the mineral held blood clot will be prevented if packing is too dense. There is rarely an indication to use more than the amounts suggested (except for very deep or large defects).

Overlay by the 13 x 25 mm collagen sheeting is transverse, and each end is tucked down the lingual and under the buccal flaps. Suture is by 3–0 silk on a cutting needle, and care should be made not to over-tighten sutures, or to have the sutures too close to the wound margin in order to prevent wound breakdown. Usually three (or four) interrupted sutures are required, and postoperative care includes clindamycin 300mg bd 6/7 and use of 0.2% chlorhexidine mouth 'soaks' thrice daily. Sutures are removed on the 10–12th day postoperatively, and if there is an indication of local wound breakdown, clindamycin is recommenced for a further 6/7. Postoperative radiographic follow up is at 6/12.

Discussion

Following third molar removal, formation of bone within the confines of the socket is determined by the stability of the subsequent blood clot, the degree of overlying coverage of the confining mucosa, and the transformation of progenitor cells into osteoblasts both within the clot, and alongside the walls of the bony defect. It is generally believed that normal tooth socket fill in is at 2/3rds at day 28, and is maximal at 100 days. That bone formation will spontaneously and completely occur against the distal root surface of the lower second molar without developmental or surgical guidance is unlikely. Further, this possibility is diminished in older patients and where there is established pericoronal or periodontal disease, and where there is absolute loss of local bony architecture.

When assessing for the scientific validity of providing actively for alveolar bone grafts to the lower dM2, and following immediately on from the surgical removal of adjacent lower wisdom teeth, the following questions arise:

1. Do periodontal defects occur to the lower dM2 from adjacent impacted wisdom teeth?
2. Do these periodontal defects spontaneously resolve from removal of the third molar?
3. Are there risk factors (age, degree of impaction, history of pericoronitis, bone appearance on OPG, probing depths etc) that predicts for the development of periodontal pockets to the lower dM2?
4. Are there long term studies on periodontal health of dM2s post lower wisdom teeth removal, and if there is long term disease, had this been related back to their third molar surgical history?
5. Are periodontal pockets to the lower dM2 remedial to traditional forms of acute or ongoing periodontal therapy?
6. Is it possible to clinically predict the development of periodontal pockets to the dM2 from third molar removal?
7. If it is possible to predict such an outcome, what reliable treatments are available and how do such treatments compare to control (untreated groups) in patients where they are identified as 'high risk'.

Periodontal defects to the dM2 are established complications of third molar removal, and were first discussed by Ash et al. in 1962 [16]. Subsequently Peng et al. [3] determined that there was more radiographic bone loss found at sites adjacent to where a third molar had been surgically removed (more than 5 years ago), than compared with (the distal surfaces of) lower second molar teeth that had had no surgical treatment (i.e., congenitally absent third molars) [3]. Elter et al. [9] concluded that that there were more severe periodontal defects to the distal surface of the lower 2nd molar where there was a 'visible third molar', and that in young adults 'third molars have a negative impact on periodontal health' [12]. Kugelberg reporting from a large 1990 Swedish epidemiological study confirmed that 14% of those aged ≤20 years had a dM2 intra bony defect post surgery of ≥4mm, compared to 47% in those aged ≥30 years at time of surgery (regardless of type of impaction) [18].

Established periodontal defects to the lower dM2 are not likely to spontaneously resolve following third molar removal. Kugelburg et al. (1990) [8] looked at the periodontal health of the lower dM2 two years after the surgical removal of impacted lower third molars. They determined that 43.3% of dM2s had ≥7mm probing depths, and 32.1% showed intra-bony defects exceeding 4mm [7]. Marmary et al. [15] determined that there was a net average gain in alveolar height of only 2.15mm against the dM2 at 6 months following third molar removal.

The various preoperative risk factors found to definitively predict higher rates of lower dM2 periodontal defects after third molar surgery are:

1. Large angulation of the impaction
2. Close positional relationship to the dM2 [6,10]

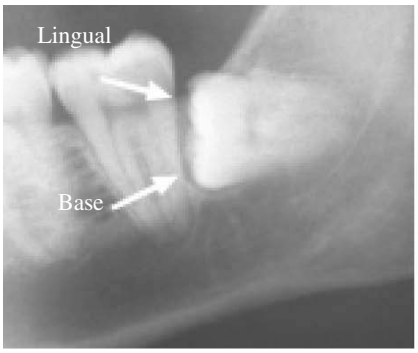

Case 1 Preoperative film of 37 and impacted 38 teeth

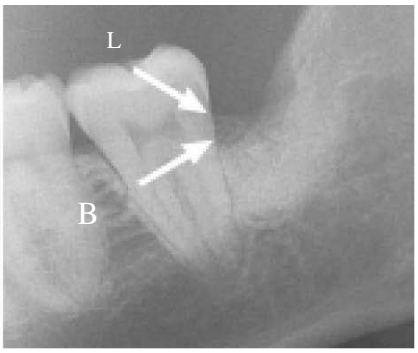

Case 1 Postoperative digital OPG film showing consolidation of bone with normal periodontal ligament width 23 weeks after surgery

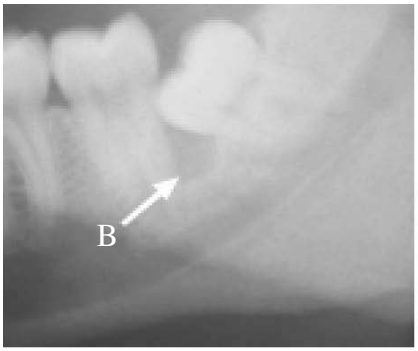

Case 2 Preoperative film of 37 and impacted 38 teeth

Case 2 Postoperative digital OPG film showing consolidation of bone with normal periodontal ligament width 45 weeks after surgery

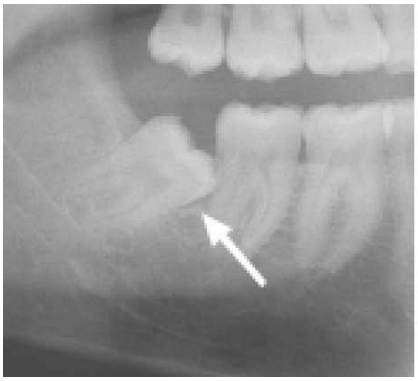

Case 3 Preoperative film of 47 and impacted 48 teeth

Case 3 Postoperative digital OPG film showing consolidation of bone and evidence of a distal periodontal ligament, 27 weeks after surgery

3. The visibility or partial eruption of the third molar (1.5 times higher risk of a periodontal pocket >5mm) [12].

Kan et al. [4] found that in their large study that lower dM2 periodontal breakdown created by a mesio-angular impacted third molar, with evidence of pre-extraction crestal radiolucency, and in association with inadequate plaque control after extraction can predispose to a persistent localised periodontal problem after the removal of the third molar (as measured at 6–36 months post treatment) [4]. Kugelburg (1990) looked at probing depths of lower dM2s, at first 2 then 4 years following third molar removal. At 2 years, 16.7% of those aged ≤25 years (at time of surgery) had intra-bony defects exceeding 4mm, compared with 40.7% in the group where the age was ≥26 years at time of operation. At 4 years post surgery, these figures were 4.2% and 44.4% respectively [8]. Dodson (2004) [2] attempted to definitively answer the question 'what is the risk of having periodontal defects on the distal aspect of the mandibular 2nd molar following third molar surgery?' through a critical review of the available literature. This paper specifically excluded papers using radiographic measurements of distal bone loss in favour of papers that used clinical assessments of probing depths or attachment levels (PD and AL). He concluded that periodontal ligament degeneration was likely to worsen as a result of third molar removal but more so in the older (≥26 years) patient. For asymptomatic third molar impactions, the established available (prophylactic) treatments did not predictably prevent periodontal pocket formation, from which the author advised caution in recommending removal [14].

Traditional remedial therapies of the established pocket have included Guided Tissue Regeneration (GTR). Oxford et al. found inconsistent improvement to dM2 periodontal probing with use of GTR immediately following lower third molar removal [20]. Pecora et al. also used e-PTFE with lower dM2 root planing at time of surgery, reporting good prevention of periodontal pocketing, but at the expense of developing increased (and sometimes severe) lower dM2 recession [19]. As corollary to this, Osborne et al. [11] found that there was minimal benefit from root planing and curettage of mandibular second molars 'immediately following removal of adjacent third molars.' They determined that the 'best means of preserving periodontal attachment on mandibular second molars may be the preventive removal of the third molars at an early stage of development'. Motamadi [17] described a technique of lateral trephination to remove the deep horizontal and fully embedded lower third molar, in order to preserve overlying crestal bone, and to prevent lower dM2 periodontal breakdown. The technique is however not a prospect for partially exposed teeth.

For treatment of established pockets, Karapataki et al. in a small study considered the effects of using either a resorbable GTR (using polylactic acid, PLA), or non-resorbable GTR (using polytetrafluoroethylene, e-PTFE) treatment to the lower dM2 on 5-year-old defects that occurred from lower 3rd molar removal. The study determined significant improvement in bone fill and probing depths regardless of either treatment modality [6].

There are some treatments that have been trialled for pro-active treatment of lower dM2s at high risk of developing periodontal defects from third molar removal. Where there was a large angulation and close positional relationship of the developing third molar to the lower dM2, the most conservative treatment was suggested by Kugelberg who definitively showed that 'early removal proved to have a beneficial effect on periodontal health' [8]. Dodson was amongst the first to actively use bone reconstruction techniques in 1996. His original pilot study determined that there may be a decreased attachment loss on the distal aspect of the lower second molar after removal of the adjacent 3rd molar by treating the extraction socket with Demineralised Bone Powder (DBP) [1]. Throndson and Sexton in 2002 used bioactive glass (BioGran), and determined that it significantly altered the clinical attachment level, but not the level of osseous fill distal to the second molars after 1 year [5].

The first describes a controlled clinical study which compared 3 groups in determining the effect of active treatment to enhance periodontal healing of the distal 2nd molar following third molar removal. The three groups compared were a non treatment group, a Guided-Tissue Regeneration (GTR) group, and a demineralised bone powder group. Comparisons in probing depths were made at pretreatment and 6 months postoperatively. This study determined there was no significant benefit other than the treatment to remove the third molar (i.e. neither GTR nor DBP offered a treatment benefit) in improving probing levels [13]. A subsequent study in 2004 looked at whether no-treatment or active treatment (using either DBP, or guided tissue regeneration) at the time of third molar removal, altered the risk for development of post extraction dM2 periodontal defects in high risk patients (age >26 years, pre-existing periodontal defects, and mesio angular or horizontal impaction of the 3rd molar). The study showed little outcome difference between using GTR vs control at time of third molar removal, but there was a significant benefit to attachment level when DBP was used (a reduction in attachment level of atleast 2/3rds) [14].

Bio-Oss® is marketed as a resorbable anorganic porous bovine hydroxy-apatite scaffold. In particulate form it is used to provide a colloidal suspension of hydroxy-apatite particles within the organising blood clot, and therefore provides for osteo-conduction and induction by allowing for local $CaPO_4$ seepage into organising connective tissue and for subsequent calcification of developing osteoid. Bio-Gide® is a resorbable (Type I and III) bi-layer porcine collagen membrane that resists ingrowth of overlying mucosal epithelium into the underlying Bio-Oss® supplemented blood clot. The use of both products is specifically indicated for use with periodontal bone graft surgery, for re-establishment of normal alveolar contouring, and for management of osseous defects following oral surgical procedures [21].

The combination of both these materials also allows for the engineering of a hard tissue scaffold underlying a healing distal mucosal membrane and therefore for alveolar bone development against the lower dM2. The healed product in turn allows for the establishment and support of a normal junctional epithelial attachment in the region of the distal CEJ. Whilst full resorption of the collagen membrane may take 26 weeks, full conversion of the Bio-Oss® particles is likely to evolve over several years to complete normal alveolar architecture.

Conclusion

Alveolar bone grafting is a common oral surgical procedure utilised for periodontal, peri-implant, and pre-prosthetic surgery. Established local bone grafting techniques are easily adaptable to management of potential periodontal pockets of the lower distal second molar following third molar surgery. To date no specific papers exist describing the use of Bio-Oss® and Bio-Gide® in the treatment of dM2s at risk of developing periodontal pockets following lower third molar removal.

The author believes that periodontal probing of the dM2 pre-operatively is not an effective determinant for assessment of the risk of development of later periodontal pocketing from his wide personal clinical experience. 1) Late age at presentation (≥26 years), 2) Radiographic evidence of crestal bone loss ≥3mm below the dM2 CEJ, and 3) Evidence of breakdown of gingival attachment above the impacted tooth against the lower dM2 has co-support in the literature as being high risk factors for the development of postoperative dM2 periodontal lesions. To date there are no papers looking at the benefit of using de-proteinated bone mineral powder (Bio-Oss®) and Type 1/III collagen sheeting (Bio-Gide®) as a scaffold matrix in the development of a normal crestal bone height (level with the dM2 CEJ) following removal of impacted lower wisdom teeth, and therefore long-term stabilisation of the normal dM2 gingival attachment. Three case studies are presented demonstrating that use of these materials can regenerate a normal lower dM2 alveolar height and which is stable, and which effectively prevents development of periodontal pocketing after deeply impacted lower third molar removal.

The author suggests that further research into the Australasian epidemiology of lower dM2 periodontal defects following third molar removal, as well as long term double blinded studies on active alveolar bone grafting. Both should provide definitive answers as to the therapeutic role of this technique in conjunction with lower third molar surgery.

References

1. Dodson TB (1996) Reconstruction of alveolar bone defects after extraction of mandibular third molars: a pilot study. Oral Surg Oral Med Oral Pathol Oral Radiol Endod 82(3): 241–247
2. Dodson TB (2004) Management of mandibular third molar extraction sites to prevent periodontal defects. J Oral Maxillofac Surg 62(10): 1213–1224
3. Peng KY, Tseng YC, Shen EC, Chiu SC, Fu E, Huang YW (2001) Mandibular second molar periodontal status after third molar extraction. J Periodontol 72(12): 1647–1651
4. Kan KW, Liu JK, Lo EC, Corbet EF, Leung WK (2002) Residual periodontal defects distal to the mandibular second molar 6–36 months after impacted third molar extraction. J Clin Periodontol 29(11): 1004–1011
5. Throndson RR, Sexton SB (2002) Grafting mandibular third molar extraction sites: a comparison of bioactive glass to a non-grafted site. Oral Surg Oral Med Oral Pathol Oral Radiol Endod 94(4): 413–419
6. Karapataki S, Hugoson A, Falk H, Laurell L, Kugelberg CF (2000) Healing following GTR treatment of intra-bony defects distal to mandibular 2nd molars using resorbable and non-resorbable barriers. J Clin Periodontol 27(5): 333–340
7. Kugelberg CF, Ahlstrom U, Ericson S, Hugoson A (1985) Periodontal healing after impacted lower third molar

surgery. A retrospective study. Int J Oral Maxillofac Surg 14(1): 29–40
8. Kugelberg CF (1990) Periodontal healing two and four years after impacted lower third molar surgery. A comparative retrospective study. Int J Oral Maxillofac Surg 19(6): 341–345
9. Elter JR, Cuomo CJ, Offenbacher S, White RP Jr (2004) Third molars associated with periodontal pathology in the Third National Health and Nutrition Examination Survey. J Oral Maxillofac Surg 62(4): 440–445
10. Kugelberg CF, Ahlstrom U, Ericson S, Hugoson A, Kvint S (1991) Periodontal healing after impacted lower third molar surgery in adolescents and adults. A prospective study. Int J Oral Maxillofac Surg 20(1): 18–24
11. Osborne WH, Snyder AJ, Tempel TR (1982) Attachment levels and crevicular depths at the distal of mandibular second molars following removal of adjacent third molars. J Periodontol 53(2): 93–95
12. Elter JR, Offenbacher S, White RP, Beck JD (2005) Third molars associated with periodontal pathology in older Americans. J Oral Maxillofac Surg 63(2): 179–184
13. Dodson TB (2007) Is there a role for reconstructive techniques to prevent periodontal defects after third molar surgery? Oral Maxillofac Surg Clin North Am 19(1): 99-104, vii
14. Dodson TB, Richardson DT (2007) Risk of periodontal defects after third molar surgery: An exercise in evidence based clinical decision making. Oral Maxillofac Surg Clin North Am. 19(1): 93-8, vii
15. Marmary Y, Brayer L, Tzukert A, Feller L (1986) Alveolar bone repair following extraction of impacted mandibular third molars. Oral Sug Oral med Oral Pathol 61(4): 324–326
16. Ash MM Jr, Costich ER, Hayward JR (1962) A study of periodontal hazards of third molars. J Periodontol. 33: 209–219
17. Motamedi MH (1999) Preventing periodontal pocket formation after removal of an impacted mandibular third molar. J Am Dent Assoc 130(10): 1482–1484
18. Kugelberg CF (1990) Impacted lower third molars and periodontal health. An epidemiological, methodological, retrospective and prospective clinical, study. Swed Dent J Suppl 68: 1–52
19. Pecora G, Celleti R, Davapanah M (1993) The effects of guided tissue regeneration on healing after impacted mandibular third molar surgery: 1–Year results. Int J Periodont Restor Dent 13: 397
20. Oxford GE, Quintero G, Stuller CB Gher ME (1997) Treatment of 3rd molar induced periodontal defects with guided tissue regeneration. J Clin Periodontol. 24(7): 464–469
21. Bio-Oss® and Bio-Gide® (2002) product guides. Osteohealth Company. 2002; April.

® Bio-Oss® and Bio-Gide® are registered product names with the Osteohealth Company, 1 Luitpold Drive, Shirley, New York 11967, USA, Tel.: +1 631 924 4000, Fax.: +1 631 924 1731.

The author asserts there is no relationship between himself and the manufacturers or suppliers of Bio-Oss® or Bio-Gide®.

Source of Support: Nil, **Conflict of interest:** None declared.