

Frank J. Rühli
Maciej Henneberg

Clinical perspectives on secular trends of intervertebral foramen diameters in an industrialized European society

Received: 15 July 2003
Revised: 21 November 2003
Accepted: 17 January 2004
Published online: 1 April 2004
© Springer-Verlag 2004

F. J. Rühli
Clinical Paleopathology Unit,
Orthopedic University Clinic Balgrist
and Institute for the History of Medicine,
University of Zurich,
Hirschengraben 82,
8001 Zurich, Switzerland

F. J. Rühli · M. Henneberg
Department of Anatomical Sciences,
The University of Adelaide,
Adelaide, Australia

F. J. Rühli (✉)
Institute of Anatomy,
University of Zurich,
Winterthurerstrasse 190,
8057 Zurich, Switzerland
Tel.: +41-1-6355315,
Fax: +41-1-6355702,
e-mail: frank.ruhli@anatom.unizh.ch

Abstract Low back pain origins have been a matter of great controversy. While spinal stenosis is now radiologically traceable, the alteration of intervertebral foramen is less clear. The aim of this study was to assess “secular trends” – alterations occurring from one generation to the next – in osseous intervertebral foramina of the major vertebral segments in an industrialized society, and to discuss their possible clinical implication. The macerated “maximum intervertebral foramen width” and “intervertebral foramen height” of all major vertebral levels in 71 non-pathologic Swiss adult skeletons from the nineteenth and early twentieth century, with known individual age and sex and similar geographic and socio-economic background, were measured by sliding caliper at validated landmarks. A secular trend of the increase in “maximum intervertebral foramen width” is found for most levels, with females showing a more prominent alteration. Additionally, the non-pathologic “maximum intervertebral foramen width” does not change with respect to indi-

vidual age, nor is a significant side difference detectable. “Intervertebral foramen height,” hereby defined as the difference of the dorsal vertebral body height minus pedicle height, demonstrates for most levels, and either sex, an insignificant negative secular trend. Neither stature nor skeletal robustness vary significantly through time within this particular sample. The results of this study, despite obvious inadequacies of methods used, exclude secular narrowing of the “maximum intervertebral foramen width” as the only cause of radiculopathy or spinal stenosis. Furthermore, we found a mild insignificant decrease of the clinically more relevant “intervertebral foramen height.” Nevertheless, the detected short-time variability of the bony intervertebral foramen, independent of individual stature, skeletal robustness or age, argues for an enhanced focus on the understanding of clinically relevant changes of spinal morphology from generation to generation.

Keywords Backache · Bone · Pain · Paleopathology · Spinal cord

Introduction

The alteration of the intervertebral foramen plays a significant role in the pathophysiology of main back pain etiologies [2, 9, 12, 19, 47, 58], such as radiculopathy or spinal stenosis; therefore, the assessment of the intervertebral foramen size and shape is worth surveying, especially as

back pain disabilities have risen more quickly than other pathologies and cause enormous health care costs [32, 38]. Surprisingly, no study exploring a possible secular alteration of the intervertebral foramen in industrialized societies exists. Since the teardrop-like shape of the superior and inferior soft tissue parts of the foramen space are different from its osseous outline, clinical or cadaver measurements [7, 25, 40, 52] cannot be easily reproduced on

dry bone specimens, which would form the basis of comparative historic studies. Whereas microevolutionary surveys of human spinal pathologies [22, 24], vertebral body [28], or neural canal size [44, 54] have been published, established osteometric schemes [20, 39] do not include intervertebral foramen diameters. Hitherto, the assessment of the macerated intervertebral foramen was surprisingly done for just one or two of the three main spinal regions [1, 6, 10, 13] and explored in one prehistoric sample (950–1300 A.D.) only [10].

The aim of this article is to present for the first time “secular” (which derives linguistically from *saeculum* meaning century or generation and is commonly used in biological/anthropological literature to describe short-time alterations occurring within a few succeeding generations such as, e.g., the widely found increase in adult body height in the twentieth century A.D.) trend data of the upper part of the osseous intervertebral foramen at all major spinal levels, and to discuss its possible clinical implications.

Materials and methods

Well-preserved adult skeletons were selected due to their excellent historic documentation with known sex and age at death (Table 1). No gross morphologic abnormalities were visible on the specimens, which represent in historic terms early-industrialization and current life style (“St. Johann” graveyard, Basel: $n=37$; born 1772–1837 A.D.; mean age at death 42.4 years; Museum of Natural History, Basel; and rural cemeteries in Apples, Bex, La Sarraz, St. Prex – Western Switzerland: $n=34$; 1865–1934 A.D.; mean age at death 57.0 years; Department of Anthropology, University of Geneva). The samples show similar geographic origin – located within approximately 150 km in comparable climate at Swiss low plains – and, according to individual death records, similar socio-economic background of mainly low- and middle class occupations, e.g., peasants or industrial workers [15, 16].

Intervertebral foramen were assessed bilaterally at vertebral level C3, C7, Th1, Th6, Th10, L1, and L5. Osteometric definitions were as follows (Fig. 1):

Maximum intervertebral foramen width: shortest horizontal distance between the inferior posterior edges of the vertebral body and the corresponding anterior aspect of the inferior articular process

Intervertebral foramen height: dorsal vertebral body height [39] minus pedicle height [51]

Femur maximum lengths, as a representation of individual stature [56], and femur mid-shaft circumferences [39], both from the right

Table 1 Sample composition ($n=71$; mean age 49.4 years, standard deviation SD 18.4 years)

| Age group (years) | No. of males ^a | No. of females ^b |
|-------------------|---------------------------|-----------------------------|
| 20–39 | 13 | 15 |
| 40–59 | 14 | 8 |
| >60 | 14 | 7 |

^a $n_{total}=41$; mean age 51.9 years, SD 18.6 years

^b $n_{total}=30$; mean age 45.9 years, SD 18.3 years

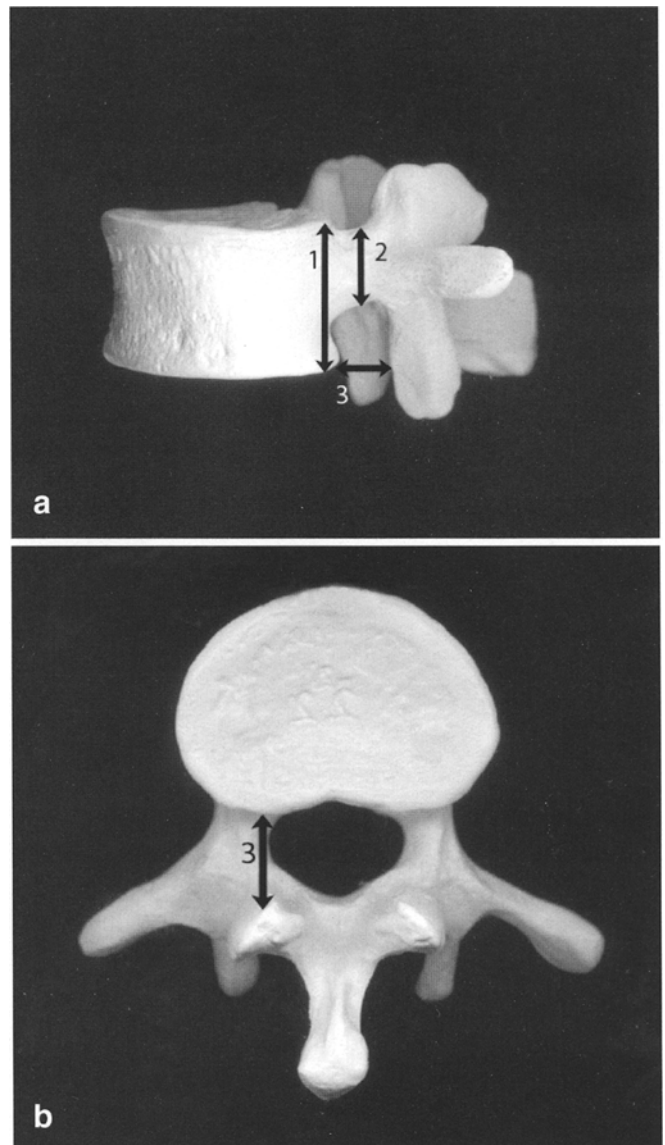


Fig. 1a, b Lateral and caudal view of a vertebra with definition of macerated intervertebral foramen height (1 minus 2) and maximum intervertebral foramen width (3)

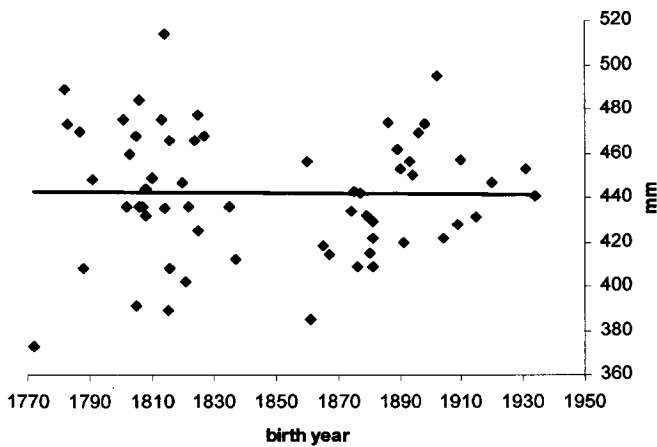
side, if preserved, were assessed, too. Femur robustness was defined as mid-shaft circumference divided by maximum length [39]. One observer (F.J.R.) performed all vertebral measurements twice with a sliding caliper to the nearest 0.1 mm. Statistical analyses were done by using primarily SPSS 11.0 (SPSS, Chicago, Ill.) or Microsoft Excel 2000 (Microsoft, Redmond, Wash.). Linear regression was used for data analysis and level of significance was defined at $p<0.05$, with Bonferroni’s correction applied for multiple comparisons. When a significant correlation with birth years was found, a secular trend was detected. Paired t test was used for analysis of side differences. The comparison of the measurements of the intervertebral foramen with previous reports [1, 6, 13, 31, 37, 46] as well as their correlation with various osseous spinal landmarks will be addressed elsewhere.

Results

Neither stature (Fig. 2A) nor femoral robustness (Fig. 2B) show a significant secular trend and both sexes show no significant difference in age at death between the samples (r for females=0.05, r for males=0.03).

We found a positive secular trend (an increase) for nearly all selected levels of the maximum intervertebral foramen width, with females demonstrating mostly a stronger tendency. For females, at level C3 left side (Fig. 3A), and bilateral on L1 ($r_{\text{right}}=0.60$, $r_{\text{left}}=0.61$) the increase was significant. Other secular trends, significant only before application of Bonferroni's correction, were in females bilateral at C7 ($r_{\text{right}}=0.48$, $r_{\text{left}}=0.45$), bilateral at Th1 ($r_{\text{right}}=0.39$, $r_{\text{left}}=0.52$), at Th6 right side (Fig. 3B), and in males at C7 right side ($r=0.37$), at Th1 bilateral (right side: Fig. 4A; $r_{\text{left}}=0.33$), and at L5 left side (Fig. 4B).

A, femur length, $r=0.02$, $N=62$;



B, femur robusticity, $r=0.21$, $N=68$;

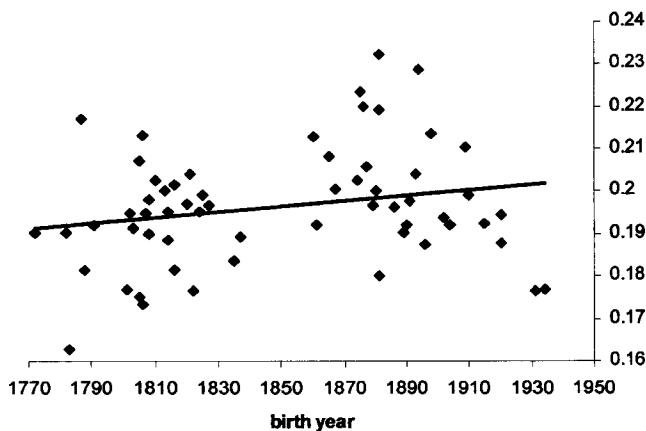
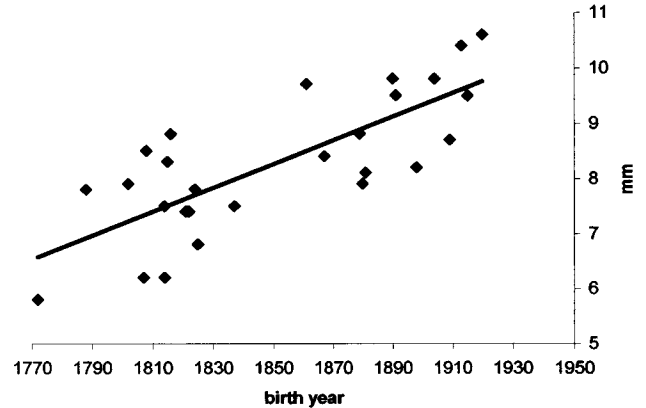


Fig. 2a, b Femur length and femur robustness showing no secular trend (sexes combined)

A, C3 left, $r=0.77$, $N=27$;



B, Th6 right, $r=0.46$, $N=25$;

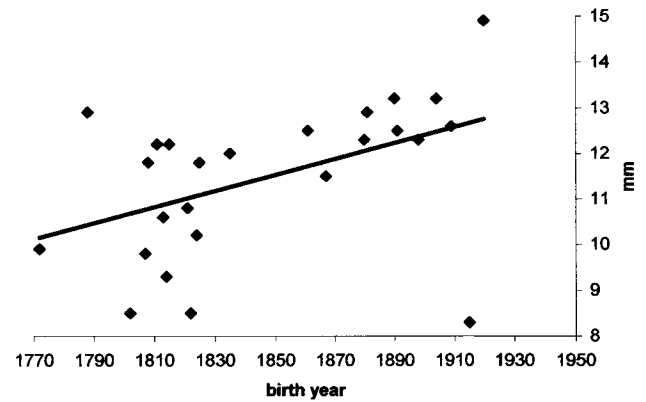


Fig. 3a, b Female maximum intervertebral foramen widths at selected vertebral levels and sides showing significant secular trends

Furthermore, the non-pathologic maximum intervertebral foramen width does not change with respect to individual age and there is also no significant side difference (Tables 2, 3).

Intervertebral foramen height shows mostly a negative insignificant secular trend in both sexes, in females for level C7 bilateral ($r_{\text{right}}=-0.40$, $r_{\text{left}}=-0.42$; Fig. 5A) and in males for level C7 on the right side ($r=-0.35$; Fig. 5B). Intervertebral foramen height at level Th10 in females and at Th10, L1, and L5 in males, all bilateral, demonstrate an insignificant, positive secular trend.

Discussion

The osteometric assessment of the intervertebral foramen is just an approximation of its *in vivo* size, which crucially depends on dynamic soft tissue components [3, 5, 7, 8, 11, 14, 18, 21, 23, 26, 29, 33, 34, 36, 37, 40, 41, 43, 50,

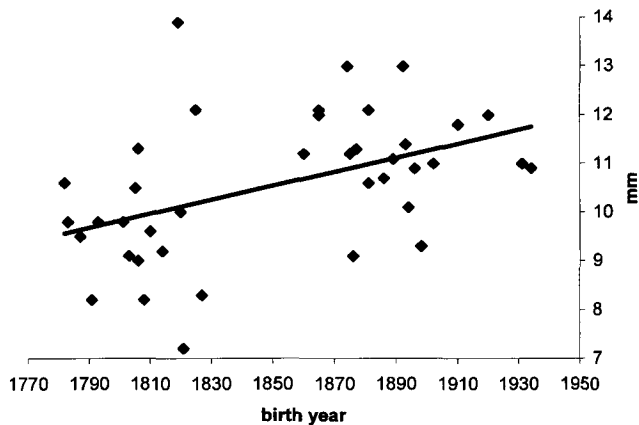
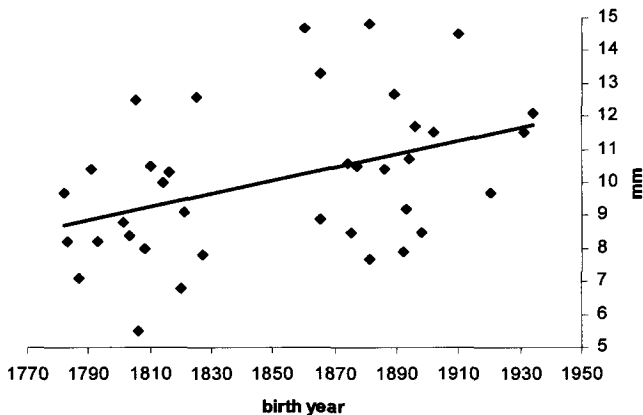
A, Th1 right, $r=0.46$, $N=39$;B, L5 left, $r=0.42$, $N=37$;

Fig. 4a, b Male maximum intervertebral foramen widths at selected vertebral levels and sides showing significant secular trends

52, 53, 57, 59, 61, 62] such as, for example, the intervertebral disc. The intervertebral foramen is delimited by the postero-lateral region of the vertebral body at level "X" and the anterior aspect of the superior articular process at level "X+1". The thickness of the intervertebral disc between level "X" and "X+1" contributes substantially, too, as well as does the angle of the articular process at level "X+1". Unfortunately, the latter one was beyond the scope of this study, since no angles of any spinal structures were assessed. In future projects this should be an essential part of analysis and could be done with the use of the geometric morphometric software package "Morphologica" (developed by O'Higgins et al. at University College London, UK) [42]. Average intervertebral disc sizes are known [17, 27, 30, 55] and could, theoretically, be added to the osseous data. Nevertheless, even this may not represent the real living dimensions; however, our approach allows at least reliable comparative studies of the non-pathologic

Table 2 Means and t values of maximum intervertebral foramen widths showing no significant side difference

| Level/side | Males | | | Females | | |
|------------|-----------|------|----|-----------|------|----|
| | Mean (mm) | t | n | Mean (mm) | t | n |
| C3 left | 8.2 | — | 35 | 8.3 | — | 27 |
| C3 right | 8.2 | 0.04 | 35 | 8.1 | 0.40 | 26 |
| C7 left | 10.1 | — | 38 | 10.0 | — | 26 |
| C7 right | 10.1 | 0.15 | 37 | 9.8 | 0.45 | 24 |
| Th1 left | 10.9 | — | 39 | 10.3 | — | 27 |
| TH1 right | 10.6 | 0.93 | 39 | 10.4 | 0.22 | 27 |
| Th6 left | 13.3 | — | 32 | 12.4 | — | 24 |
| Th6 right | 12.7 | 1.79 | 32 | 11.5 | 1.85 | 25 |
| Th10 left | 13.1 | — | 38 | 12.7 | — | 28 |
| Th10 right | 12.9 | 0.28 | 37 | 12.6 | 0.15 | 27 |
| L1 left | 13.1 | — | 34 | 13.6 | — | 27 |
| L1 right | 13.0 | 0.12 | 34 | 13.4 | 0.33 | 27 |
| L5 left | 10.1 | — | 37 | 11.3 | — | 27 |
| L5 right | 9.8 | 0.64 | 36 | 11.3 | 0.07 | 27 |

Table 3 Correlation coefficients of maximum intervertebral foramen widths with individual age showing no significant dependency

| Level/side | Males | | Females | |
|------------|-------|----|---------|----|
| | r | n | r | n |
| C3 left | -0.04 | 35 | -0.05 | 27 |
| C3 right | 0.01 | 35 | 0.02 | 26 |
| C7 left | 0.16 | 38 | 0.30 | 26 |
| C7 right | 0.14 | 37 | 0.24 | 24 |
| Th1 left | 0.12 | 39 | 0.19 | 27 |
| TH1 right | 0.16 | 39 | 0.31 | 27 |
| Th6 left | 0.16 | 32 | 0.11 | 24 |
| Th6 right | 0.11 | 32 | 0.15 | 25 |
| Th10 left | 0.03 | 38 | 0.12 | 28 |
| Th10 right | -0.01 | 37 | 0.19 | 27 |
| L1 left | 0.07 | 34 | -0.05 | 27 |
| L1 right | 0.22 | 32 | 0.13 | 27 |
| L5 left | 0.09 | 37 | 0.21 | 27 |
| L5 right | -0.15 | 36 | 0.14 | 27 |

macerated intervertebral foramen. Unfortunately, the osseous sagittal intervertebral foramen width seems to be independent from intervertebral disc alterations [8].

In the present study the so-called intervertebral foramen height reflects *de facto* only the difference between the height of the vertebral body at level "X" minus the height of the pedicle at level "X" and does not represent in any form the influence of the intervertebral disc, which may actually undergo secular trends of any sort, too. Finally, for the spines studied herein at least major taphonomic alterations seem to be negligible.

Although previous reports detected no secular trend of the foramen size by focusing on influences of prehistoric

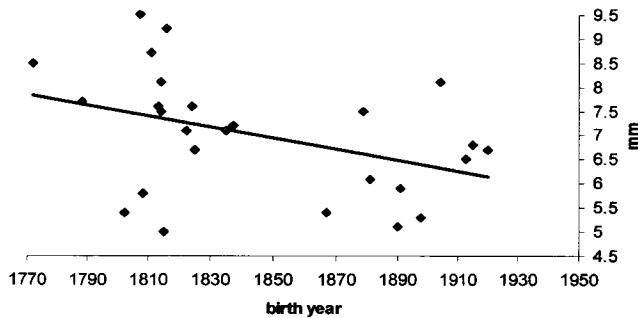
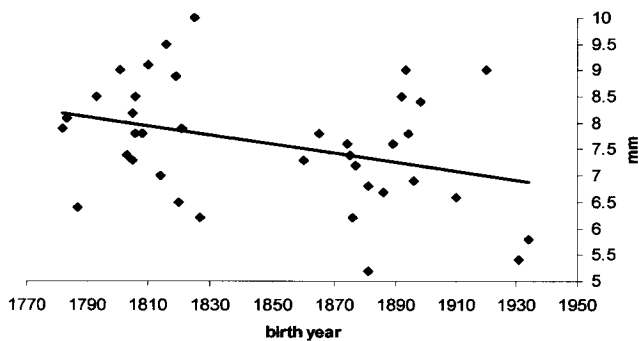
A, Females, $r=-0.40$, $N=28$;B, Males, $r=-0.35$, $N=38$ 

Fig. 5a, b Intervertebral foramen height at vertebral level C7, right side, showing insignificant negative secular trends

lifestyle changes [10], the samples from industrialized societies presented herein demonstrate a mild secular alteration of the intervertebral foramen even without an apparent major shift in culture. Possible causes of these findings may be, as pointed out in previous microevolutionary spinal studies [22, 24, 48], of genetic or environmental nature, e.g., nutrition. Additionally, we found no correlation between the upper part of the osseous maximum intervertebral foramen width and individual age at death, unlike previous clinical reports [25]. Changes in general bony robustness, as expressed by femoral robustness rather than stature, could partially explain secular alterations of the intervertebral foramen size. This is not the case in this particular sample showing an insignificant positive increase in robustness, which would likely oppose a secular enlargement of the mostly bone-enclosed foramen.

The mild secular trend of the intervertebral foramen diameters may not correlate with clinical presentation, since previous studies focusing on possible links between altered spinal neural pathways and symptoms report equivocally [4, 21, 25, 60] and dynamic and day-time-related alterations of its size are known, too [18]. Furthermore, this study found that stronger secular trends in females lack an evident interpretation and need further exploration, especially given that in a recent sample intervertebral foramen and spinal canal size showed mostly no significant sex difference [13, 35]. Apparently, the upper part of the osseous intervertebral foramen becomes wider and lower in cranio-caudal direction towards most modern times, independent of factors such as stature, skeletal robustness, or age. The question as to whether this reshaping was compensated by an adaptation of, for example, the omnipresent fat tissue and blood vessels [23, 53] remains unanswered. If not, this reforming could prompt clinical symptoms, since it is known that the dorsal root ganglion and the spinal nerve occupy supero-lateral and inferior sections, respectively, of the root canal [34, 53]; however, the sagittal and vertical intervertebral foramen diameters at least reflect well its overall dimension [8]. Furthermore, the assessment of the intervertebral foramen dimensions by caliper and on dried vertebrae produces less inter-observer variability and lower standard errors than other methods using fresh cadaveric samples with soft tissues still present [8].

Conclusion

Our results contradict a secular narrowing of the maximum intervertebral foramen widths as a possible microevolutionary precondition of increasing incidence of radiculopathy or spinal stenosis. Nevertheless, the presented data, though collected using a method that has serious limitations, reveal a remarkable secular variability of the upper part of the osseous outline of the intervertebral foramen, independent of individual age, stature, and robustness. Our challenging preliminary results will hopefully stimulate the debate, which assesses spinal morphology changes by using a broad historic perspective [6, 10, 22, 24, 28, 45, 49, 54] and may represent a pilot approach for further investigations on changing clinical entities in modern societies.

Acknowledgement This study was supported by an International Postgraduate Research Scholarship of the University of Adelaide awarded to F.J.R.

References

1. Amonoo-Kuofi HS (1985) The sagittal diameter of the lumbar vertebral canal in normal adult Nigerians. *J Anat* 140: 69–78
2. Arnoldi CC, Brodsky AE, Cauchoix J et al. (1976) Lumbar spinal stenosis and nerve root entrapment syndromes. Definition and classification. *Clin Orthop* 115:4–5
3. Bailey P, Casamajor L (1911) Osteoarthritis of the spine as a cause of compression of the spinal cord and its roots. *J Nerv Ment Dis* 38:588–609
4. Boden SD, Davis DO, Dina TS, Patronas NJ, Wiesel SW (1990) Abnormal magnetic-resonance scans of the lumbar spine in asymptomatic subjects. A prospective investigation. *J Bone Joint Surg Am* 72:403–408
5. Bose K, Balasubramaniam P (1984) Nerve root canals of the lumbar spine. *Spine* 9:16–18
6. Boszczyk BM, Boszczyk AA, Putz R (2001) Comparative and functional anatomy of the mammalian lumbar spine. *Anat Rec* 264:157–168
7. Chung SS, Lee CS, Kim SH, Chung MW, Ahn JM (2000) Effect of low back posture on the morphology of the spinal canal. *Skeletal Radiol* 29:217–223
8. Cinotti G, Santis P de, Nofroni I, Postacchini F (2002) Stenosis of lumbar intervertebral foramen. *Spine* 27: 223–229
9. Ciric I, Mikhael MA, Tarkington JA, Vick NA (1980) The lateral recess syndrome. A variant of spinal stenosis. *J Neurosurg* 53:433–443
10. Clark GA, Panjabi MM, Wetzel FT (1985) Can infant malnutrition cause adult vertebral stenosis? *Spine* 10: 165–170
11. Crock HV (1981) Normal and pathological anatomy of the lumbar spinal nerve root canals. *J Bone Joint Surg Br* 63B:487–490
12. Dorwart RH, Vogler JB, Helms CA (1983) Spinal stenosis. *Radiol Clin North Am* 21:301–325
13. Ebraheim NA, An HS, Xu R, Ahmad M, Yeasting RA (1996) The quantitative anatomy of the cervical nerve root groove and the intervertebral foramen. *Spine* 21:1619–1623
14. Epstein JA, Epstein BS, Lavine L (1962) Nerve root compression associated with narrowing of the lumbar spinal canal. *J Neurol Neurosurg Psychiaty* 25:165–176
15. Etter HF (1988) Der äussere St. Johann Gottesacker in Basel. Was ein Spitalfriedhof des 19. Jahrhunderts verrät. *CH-Forschung* 11:23–28
16. Etter HF, Lörcher M (1993) *Armut, Krankheit, Tod im frühindustriellen Basel*. Cratander, Basel
17. Frobin W, Brinckmann P, Biggemann M (1997) Objektive Messung der Höhe lumbaler Bandscheiben aus seitlichen Röntgen-Übersichtsaufnahmen. *Z Orthop Grenzgeb* 135:394–402
18. Fujiwara A, An HS, Lim TH, Haughton VM (2001) Morphologic changes in the lumbar intervertebral foramen due to flexion-extension, lateral bending, and axial rotation: an in vitro anatomic and biomechanical study. *Spine* 26:876–882
19. Gaskill MF, Lukin R, Wiot JG (1991) Lumbar disc disease and stenosis. *Radiol Clin North Am* 29:753–764
20. Hasebe K (1913) Die Wirbelsäule der Japaner. *Z Morphol Anthropol* 15:259–380
21. Hasegawa T, An HS, Haughton VM, Nowicki BH (1995) Lumbar foraminal stenosis: critical heights of the intervertebral discs and foramina. A cryomicrotome study in cadavera. *J Bone Joint Surg Am* 77:32–38
22. Henneberg RJ, Henneberg M (1999) Variation in the closure of the sacral canal in the skeletal sample from Pompeii, Italy, 79 A.D. *Persp Hum Biol* 4:177–188
23. Hoyland JA, Freemont AJ, Jayson MI (1989) Intervertebral foramen venous obstruction. A cause of periradicular fibrosis? *Spine* 14:558–568
24. Hukuda S, Inoue K, Nakai M, Katayama K (2000) Did ossification of the posterior longitudinal ligament of the spine evolve in the modern period? A paleopathologic study of ancient human skeletons in Japan. *J Rheumatol* 27:2647–2657
25. Humphreys SC, Hodges SD, Patwardhan A, Eck JC, Covington LA, Sartori M (1998) The natural history of the cervical foramen in symptomatic and asymptomatic individuals aged 20–60 years as measured by magnetic resonance imaging. A descriptive approach. *Spine* 23:2180–2184
26. Inufusa A, An HS, Lim TH, Hasegawa T, Haughton VM, Nowicki BH (1996) Anatomic changes of the spinal canal and intervertebral foramen associated with flexion-extension movement. *Spine* 21:2412–2420
27. Jacobi H (1927) Messungen der Brust- und oberen Lendenwirbelsäule unter Berücksichtigung der Veränderungen an Bandscheiben und Wirbelkörpern. *Beitr Pathol Anat* 78:303–314
28. Jankauskas R (1994) Variability of vertebral column measurements in Lithuanian paleopopulation. *Int J Anthropol* 9:137–151
29. Jones RA, Thomson JL (1968) The narrow lumbar canal. A clinical and radiological review. *J Bone Joint Surg Br* 50:595–605
30. Kandziora F, Pflugmacher R, Scholz M et al. (2001) Comparison between sheep and human cervical spines: an anatomic, radiographic, bone mineral density, and biomechanical study. *Spine* 26:1028–1037
31. Karaikevic EE, Daubs MD, Madsen RW, Gaines RW Jr. (1997) Morphologic characteristics of human cervical pedicles. *Spine* 22:493–500
32. Kelsey JL, White AA (1980) Epidemiology and impact of low-back pain. *Spine* 5:133–142
33. Larmon WA (1944) An anatomic study of the lumbosacral region in relation to low back pain and sciatica. *Ann Surg* 119:892–896
34. Lee CK, Rauschnig W, Glenn W (1988) Lateral lumbar spinal canal stenosis: classification, pathologic anatomy and surgical decompression. *Spine* 13:313–320
35. Lee HM, Kim NH, Kim HJ, Chung IH (1995) Morphometric study of the lumbar spinal canal in the Korean population. *Spine* 20:1679–1684
36. Lu J, Ebraheim NA, Huntoon M, Haman SP (2000) Cervical intervertebral disc space narrowing and size of intervertebral foramina. *Clin Orthop* 370:259–264
37. Magnuson PB (1944) Differential diagnosis of causes of pain in the lower back accompanied by sciatic Pain. *Ann Surg* 119:878–891
38. Maniadakis N, Gray A (2000) The economic burden of back pain in the UK. *Pain* 84:95–103
39. Martin R (1928) *Lehrbuch der Anthropologie*. Gustav Fischer, Jena
40. Mayoux-Benhamou MA, Revel M, Aaron C, Chomette G, Amor B (1989) A morphometric study of the lumbar foramen. Influence of flexion-extension movements and of isolated disc collapse. *Surg Radiol Anat* 11:97–102
41. Nowicki BH, Haughton VM, Schmidt T et al. (1996) Occult lumbar lateral spinal stenosis in neural foramina subjected to physiologic loading. *Am J Neuroradiol* 17:1605–1614
42. Pan R, Wei F, Li M (2003) Craniofacial variation of the Chinese macaques explored with morphologica. *J Morphol* 256:342–348
43. Panjabi MM, Takata K, Goel VK (1983) Kinematics of lumbar intervertebral foramen. *Spine* 8:348–357
44. Piontek J, Budzynska J (1972) Zmienność Cech Metrycznych Kregoslupa. *Przegląd Antropol* 38:17–26

45. Porter RW, Pavitt D (1987) The vertebral canal: I. Nutrition and development, an archaeological study. *Spine* 12:901-906
46. Postacchini F, Ripani M, Carpano S (1983) Morphometry of the lumbar vertebrae. An anatomic study in two caucasoid ethnic groups. *Clin Orthop* 172:296-303
47. Resnick D (1985) Degenerative diseases of the vertebral column. *Radiology* 156:3-14
48. Rothschild BM, Rothschild C (1996) Is there an epidemic/epizootic of spondyloarthropathy in baboons? *J Med Primatol* 25:69-70
49. Rühli FJ, Schultz M, Henneberg M (2002) Microevolution of the central European human vertebral column since the Neolithic: preliminary osteometric assessment and interpretations. *Am J Phys Anthropol (Suppl)* 34:134-135
50. Schmid MR, Stucki G, Duewell S, Wildermuth S, Romanowski B, Hodler J (1999) Changes in cross-sectional measurements of the spinal canal and intervertebral foramina as a function of body position: in vivo studies on an open-configuration MR system. *AJR* 172:1095-1102
51. Shapiro L (1993) Evaluation of "unique" aspects of human vertebral bodies and pedicles with a consideration of *Australopithecus africanus*. *J Hum Evol* 25:433-470
52. Stephens MM, Evans JH, O'Brien JP (1991) Lumbar intervertebral foramina. An in vitro study of their shape in relation to intervertebral disc pathology. *Spine* 16:525-529
53. Swanberg H (1915) The intervertebral foramina in man. *Med Rec* 87:176-180
54. Tatarek NE (2001) Variation in the lumbar neural canal. *Am J Phys Anthropol (Suppl)* 32:147
55. Tribus CB, Belanger T (2001) The vascular anatomy anterior to the L5-S1 disk space. *Spine* 26:1205-1208
56. Trotter M, Gleser GC (1952) Estimation of stature from long bones of American whites and negroes. *Am J Phys Anthropol* 10:463-514
57. Vanderlinden RG (1984) Subarticular entrapment of the dorsal root ganglion as a cause of sciatic pain. *Spine* 9:19-22
58. Verbiest H (1954) A radicular syndrome from developmental narrowing of the lumbar vertebral canal. *J Bone Joint Surg Br* 36:230-237
59. Vital JM, Lavignolle B, Grenier N, Rouais F, Malgat R, Senegas J (1983) Anatomy of the lumbar radicular canal. *Anat Clin* 5:141-151
60. Wiesel SW, Tsourmas N, Feffer HL, Citrin CM, Patronas N (1984) A study of computer-assisted tomography. I. The incidence of positive CAT scans in an asymptomatic group of patients. *Spine* 9:549-551
61. Yoo JU, Zou D, Edwards WT, Bayley J, Yuan HA (1992) Effect of cervical spine motion on the neuroforaminal dimensions of human cervical spine. *Spine* 17:1131-1136
62. Yoshida M, Shima K, Taniguchi Y, Tamaki T, Tanaka T (1992) Hypertrophied ligamentum flavum in lumbar spinal canal stenosis. Pathogenesis and morphologic and immunohistochemical observation. *Spine* 17:1353-1360