

Matthias Wiese · Frank Rubenthaler ·
Roland Ernst Willburger · Sabine Fennes · Rolf Haaker

Early results of endoscopic trochanter bursectomy

Received: 3 March 2004 / Accepted: 28 April 2004 / Published online: 9 June 2004
© Springer-Verlag 2004

Abstract Between 1995 and 2000, we performed 45 endoscopic bursectomies in 42 patients (average age 51, range 17–61 years). All patients had at least 6 months of failed conservative treatment, and all responded positively to a sonographic-guided injection with Mepivacaine 0.5%. The bursa was removed using a synovial resector. An additional tractopexie was performed in four cases. We followed 37 patients for 12–48 months. Pre-operatively, the mean modified Japanese Orthopaedic Association (JOA) disability hip score was 40.5 points. It improved to 72.6 points after a mean of 25 months. Severe complications did not occur. The minimally invasive technique requires only stab incisions, and immobilisation and hospitalisation are minimal.

Résumé Entre 1995 et 2000 nous avons exécuté 45 bursectomies endoscopiques chez 42 malades âgés en moyenne de 51 ans (17–61). Tous les malades avaient eu au moins six mois de traitement conservateur sans effet et tous ont répondu positivement à une injection de Mepivacaine 0,5% sous guidage sonographique. La bourse a été excisée en utilisant un résecteur synovial. Un tractopexie supplémentaire a été exécuté dans quatre cas. Nous avons suivi 37 malades pendant 12 à 48 mois. Le score (JOA) d'invalidité de la hanche modifié était, en préopératoire de 40,5 points en moyenne. Il a été amélioré à 72,6 points après 25 mois. Il n'y a pas eu de complication grave. La

technique mini-invasive n'exige que des incisions ponctuelles avec une immobilisation et une hospitalisation sont minimales.

Introduction

Bursitis of the greater trochanter is a common clinical problem. It is sometimes seen in patients with chronic low back pain [6]. It is often associated with a coxa saltans [4], and it is seen as a complication after osteotomies, total hip replacement or in patients with chronic polyarthritis. It is often observed in patients regularly doing long-distance running [5]. Trochanteric bursitis is characterised as a regional pain syndrome with chronic, intermittent, arching pain over the lateral aspect of the hip. The incidence is highest between the fourth and sixth decades of life [16].

The majority of cases respond to conservative treatment, such as physical therapy, physiotherapy with stretching of the M. tensor fasciae latae and the iliotibial band, analgetics or non-steroidal anti-inflammatory medication. Local injections with corticosteroids and lidocaine have been shown to be an effective therapy with prolonged benefit [17]. When conservative treatment fails after a minimum period of 6 months, a number of operative procedures have been described [3, 7, 9, 18, 19]. The endoscopic approach to the bursa of the greater trochanter has been described by Sampson [2, 15]. There are only short descriptions of the procedure and the technique. To our knowledge, there exist no short-term follow-up studies on a greater number of patients who underwent bursectomy using a minimally invasive technique. In our hospital, an open procedure for revision of the greater trochanteric bursa was applied in 17 patients up to 1995. This led to a mean scar length of 10 (7.5–14.0) cm and an average period of hospitalisation of 10 (6–15) days.

M. Wiese (✉) · F. Rubenthaler · R. E. Willburger · S. Fennes
Department of Orthopaedic Surgery, Ruhr-University-Bochum,
St Josef-Hospital,
Gudrunstr. 56,
44791 Bochum, Germany
e-mail: matthias.wiese@ruhr-uni-bochum.de
Tel.: +49-234-6120
Fax: +49-234-612295

R. Haaker
Department of Orthopaedic Surgery, St Vincent-Hospital,
Danziger Str. 17,
33034 Brakel, Germany

Materials and methods

Between June 1995 and 2000, we performed 45 endoscopic bursectomies in 42 patients (33 women and nine men). Their average age was 51 (17–61) years. Six patients had a previous total hip replacement for osteoarthritis. Two other patients had undergone unsuccessful open *Z* lengthening of the iliotibial tract. All patients had failed conservative treatment of at least 6 months. According to a standardised protocol, ultrasonography and an AP radiograph of the hip were performed. The diagnosis was confirmed by an intra-bursal injection with 5–10 ml Mepivacaine 0.5% under sonographic control. The test was considered positive if the patient remained pain free between 1 and 4 h.

We used a standardised approach [13, 14] (Fig. 1) and the technique was previously described by Haaker et al. 2000 [11]. In four cases with coxa saltans, the iliotibial tract was sutured to the greater trochanter using absorbable anchors.

Thirty-seven patients were re-examined after 12–48 months. We used a modified Rating Scale for Hip Disabilities of the Japanese Orthopaedic Association (JOA) [12] and a visual analogue scale for pain and disability. The JOA score was modified at two points. Sitting on a straw mat and bowing while sitting on a straw mat were replaced with the ability to lie on the affected side. Forty points were awarded to pain and walking ability with 10-point increments. Daily life activities were rated with 0–2 points.

Results

The average time for surgery was 41 (25–56) min. Additional fixation of the iliotibial tract took another 18 (13–22) min. An amber-coloured exudation was found in the bursa of two patients. In two other cases, osteophytes of the trochanter were smoothed down by an acromionizer in order to avoid mechanical irritation and recurrent bursitis. During endoscopic bursectomy, haemorrhage had to be controlled using the electric cautery knife in eight cases. Pre-operatively, an average JOA score of 40.5 points was recorded. At a medium follow up of 25 (12–48)

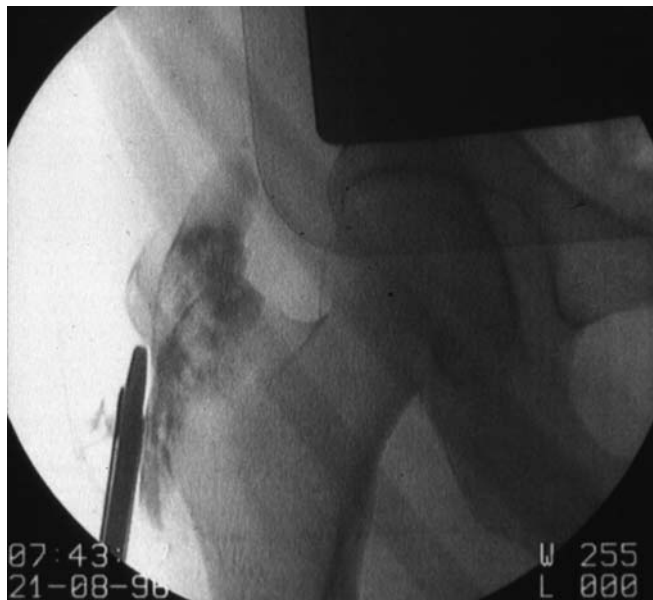

Fig. 1 Fluoroscopy after filling of the cavity with a radiopaque material and introducing a synovial resector into the bursa of the greater trochanter

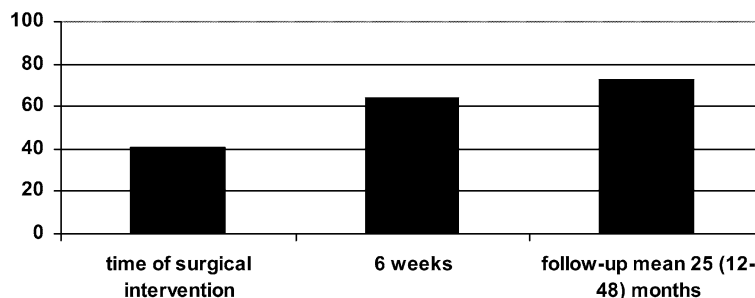
months in 37 patients, the score improved to as high as 72.6 points (Fig. 2). Patients who had undergone other surgical procedures previously improved on an average 37 points. With 38 points, their pre-operative score was slightly lower than the average. The only patient who did not improve had previously undergone an open *Z* lengthening of the iliotibial tract without success. This patient was revised by an open surgical procedure during follow-up. There were no significant age-related differences between patients in improvement. Younger patients under the age of 30 had higher pre-operative ratings in activities such as walking distance and everyday life. These differences persisted after surgery. Looking at the intra-operative findings, it is obvious that patients who had osteophytes of the greater trochanter or an exudation in the bursa showed greater improvement after surgery compared to other patients. Comparing everyday life activities, the greatest improvement was found “when the possibility of lying on the affected side” was evaluated. An improvement was found from an average 15% pre-operatively up to an average of 75% post-operative. Significant changes in pain and disability were seen. The pre-operative average rating on the visual analogue scale was 7.2 points. After surgery, this parameter improved to 5.7 points. At the follow-up examination, there was further improvement to 3.8 points (Fig. 3). Four patients developed haematoma. There was no relation between intra-operative bleeding, the use of an electric cautery knife, and the post-operative haematoma. Severe complications did not occur.

Discussion

Trochanteric bursitis is a very common disease. The incidence is high between the fourth and sixth decades of life [16]. Pain is typically located posterolaterally over the trochanter without radiation and is usually worsened by passive adduction and internal rotation. Other diagnoses, such as degenerative disk diseases with or without irritation of the nerve root or degenerative hip diseases, have to be ruled out. Bursitis is often associated with a coxa saltans [4]. It is also seen as a complication after operative treatment of the hip or in patients with chronic polyarthritis. A high incidence is seen in patients regularly performing sporting activities such as long distance running. A pathophysiological explanation has been given by Clancy [5] in 1980. The bursitis is thought to be caused by repeated micro-trauma due to friction between the greater trochanter and the iliotibial band during active flexion and extension of the hip. The iliotibial band can snap over the trochanter and lead to secondary bursitis. This, however, occurs rather seldom. In our study, only in four out of 45 surgery patients required a tractopexie.

The majority of patients respond to conservative treatment, such as physical therapy, physiotherapy with stretching of the *M. tensor fasciae latae* and the iliotibial band, analgetics or non-steroidal anti-inflammatory medication. For patients who do not respond to any mode of

Fig. 2 Pre-operative and post-operative Japanese Orthopaedic Association (JOA) hip score



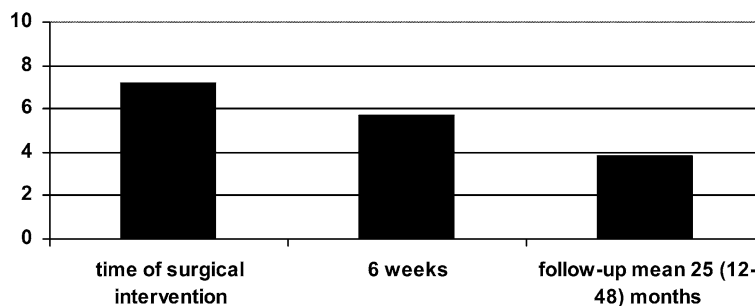
conservative treatment after a minimum of 6 months, a number of operative procedures have been described [1, 3, 16, 18, 19]. Brooker [3] reported on five patients who underwent bursectomy and T-shaped incision of the iliotibial band. There have been reports on contracted iliotibial band in addition to the bursitis. Therefore, bursectomies are combined with a longitudinal incision of the iliotibial band. Zoltan et al. reported on a series of ellipsoid excisions of the iliotibial band over the trochanter for snapping hip syndrome [19]. Slawski reported on a group of seven patients who underwent open revision of the bursa in 1997 [18]. Féry and Sommelet reported on long-term results of an open cruciate incision in the iliotibial band over the greater trochanter in 35 hips. They found disappointing results with 30% recurrence of symptoms and over 60% continuing pain of varying degrees. Only 30% of the patients had a successful result [7]. Govaert et al. reported in 2003 on a new operative procedure for refractory trochanteric bursitis. They used a reduction osteotomy of the greater trochanter in 12 hips. Six patients showed great improvement, five did not respond satisfactorily, and one showed fair improvement. No specific complications, such as non-union of the osteotomy, have been seen so far. Due to the invasive technique, patients needed partial weight bearing for 6 weeks on two crutches. Full weight bearing and return to normal daily activities was possible 6–8 weeks later [9].

Today, minimally invasive procedures are no longer limited to joints. There exist some short descriptions of the procedure and the technique of the endoscopic approach to the bursa of the greater trochanter [10, 15]. Bradley and Dillingham reported on a single patient treated successfully with bursectomy and bursectomy on both hips [2]. There was one short publication by Fox in 2002 who reported on 27 patients who underwent endoscopic bursectomy with a follow up of 5 years in 22 cases. Twenty-three of the 27 patients had good or excellent

results immediately following the procedure. After 1 year one patient and after 5 years two patients had recurrence symptoms [8]. To our knowledge, there are no short-term follow-up studies of a minimally invasive technique for endoscopic bursectomy on a greater number of patients. Our technique conforms to techniques described for other non-performed cavities like the prepatellar bursa or the bursa olecrani [13, 14]. The approach to the bursa trochanterica is impeded by the varying thickness of the soft tissue and the tension of the iliotibial band. Both factors require a large incision in an open approach. The minimally invasive procedure has the advantage of stab incisions for the working portals. Compared to an average incision of the open procedure with a 10.8 cm scar length (7.5–14.0 cm), we only needed two incisions of 1.5 cm. The average period of hospitalisation dropped from 10 days in open surgery (6–15 days) to 7 days (3–12 days). Early functional aftercare starting on the day after surgery was possible, as only a compressive dressing was applied. Therefore, risks are lower, immobilisation and stay in hospital are shorter and rehabilitation is faster in endoscopic bursectomy compared to the open procedure. Compared to surgical techniques like reduction osteotomies, there is no need for longer partial weight bearing [9]. In our follow-up series, arthroscopic trochanteric bursectomy proved to be an effective, minimally invasive treatment for refractory bursitis that failed conservative treatment in 36 cases. In four patients, the treatment had to be combined with an endoscopic tractopexie to be effective.

We do not recommend endoscopic bursectomy in infectious bursitis or in rheumatoid patients with concomitant synovitis of the coxofemoral joint. Often, a link between the hip joint and the bursa exists; therefore, a radical synovectomy of the hip joint is often necessary to prevent a recurrence of the bursitis. Further work needs to

Fig. 3 Pre-operative and post-operative pain and disability score



be done to continue development of this procedure and to evaluate the results by long-term follow up.

References

1. Anderson TP (1958) Trochanteric bursitis—diagnostic criteria and clinical significance. *Arch Phys Med Rehabil* 39:617–622
2. Bradley DM, Dillingham MF (1998) Bursoscopy of the Trochanteric Bursa. *Arthroscopy* 14:884–887
3. Brooker AF (1979) The surgical approach to refractory trochanteric bursitis. *John Hopkins Med J* 25:86–89
4. Brückel R (1992) Angeborene und Erworbene Deformitäten im Bereich des Hüftgelenkes. In: Jäger M, Wirth CL (eds) *Praxis der Orthopädie*, 2nd edn. Thieme, Stuttgart, pp 854–926
5. Clancy WG (1980) Runners' injuries part two. Evaluation and treatment of specific injuries. *Am J Sports Med* 8:287–289
6. Colle G, Dijkmans BA, Vandenbroucke JP, Cats A (1991) Greater Trochanteric pain syndrom (trochhanteric bursitis) in low back pain. *Scand J Rheumatol* 20:262–266
7. Féry A, Sommelet J (1988) The outcome of operation for the "snapping hip". *Int Orthop* 12:277–282
8. Fox JL (2002) The role of arthroscopic bursectomy in the treatment of trochanteric bursitis. *Arthroscopy* 18:E34
9. Govaert LHM, Vis van der HM, Marti RK, Albers GHR (2003) Trochanteric reduction osteotomy as a treatment for refractory trochanteric bursitis. *J Bone Joint Surg Br* 85:199–203
10. Haaker R, Krämer J (1997) Endoskopische Bursektomie am Trochanter major. *Arthroscopie* 10:323–326
11. Haaker R, Willburger R, Wiese M (2000) Endoscopic bursectomy and fixation of the iliotibial tract at the greater trochanter. *Orthop Traumatol* 8:225–232
12. Ito T, Nakayama Y, Tanaka H, Ishida K, Masuda K (1990) Distraction arthroplasty of the hip by bicentric femoral head prosthesis. *Clin Orthop* 255:186–193
13. Klein W (1996) Endoscopy of the deep infrapatellar bursa. *Arthroscopy* 12:127–131
14. Pässler HH (1996) Bursaendoscopie. *Arthroscopie* 9:22–26
15. Sampson TG, Glick JM (1996) Indication and surgical treatment of hip pathology. In: McGinty JB (ed) *Operative arthroscopy*, 2nd edn. Lippincott-Raven, Philadelphia, p 1078
16. Shbeeb MI, Matterson EL (1996) Trochanteric bursitis (greater trochanter pain syndrom). *Mayo Clin Proc* 71:565–569
17. Shbeeb MI, Duffy JD, Michet CJ Jr, O'Fallon, Matterson EL (1996) Evaluation of glucocorticoid injection for the treatment of trochanteric bursitis. *J Rheumatol* 23:2104–2106
18. Slawski DP, Howard RF (1997) Surgical management of refractory trochanteric bursitis. *Am J Sports Med* 25:86–89
19. Zoltan DJ, Clancy WG, Keen JS (1986) A new operative approach to snapping hip and refractory trochanteric bursitis in athletes. *Am J Sports Med* 14:201–204