

Alterations in human colonic mucin occurring with cellular differentiation and malignant transformation

(colon cancer/fluorescein isothiocyanate-conjugated lectins/peanut agglutinin/transitional mucosa)

C. RICHARD BOLAND*, CAROLYN K. MONTGOMERY†, AND YOUNG S. KIM*

Gastrointestinal Research Unit, Veterans Administration Medical Center, Departments of *Medicine and †Pathology, University of California, San Francisco, California 94121

Communicated by Rudi Schmid, December 9, 1981

ABSTRACT The binding of fluorescein isothiocyanate (FITC)-conjugated lectins to mucin in the human colon was studied by using fluorescence microscopy. In normal mucosa, lectins that preferentially bind to exposed *N*-acetyl-galactosamine residues (*Dolichos biflorus* agglutinin and soybean agglutinin) bound selectively to the goblet cell mucin of well-differentiated cells in the upper colonic crypt. By contrast, lectins that require exposed non-reducing galactose residues for binding (*Ricinus communis* agglutinin₁ and *Bauhinia purpurea* agglutinin) preferentially labeled the mucin of less-differentiated goblet cells located in the lower portion of the colonic crypt. The lectin derived from *Arachis hypogaea* (peanut agglutinin) has a high affinity for a carbohydrate structure not normally exposed in human tissues. This lectin did not label the goblet cell mucin in the normal colon. However, the mucin was labeled in all 21 colon cancer specimens examined. Additionally, the nonmalignant epithelium immediately adjacent to colon cancer (termed "transitional mucosa") also contained goblet cell mucin that was labeled by FITC-peanut agglutinin. Three conclusions may be drawn from the selective binding characteristics of FITC-lectins to colonic mucins. First, an alteration in the exposed, nonreducing carbohydrate residues occurs in human colonic mucin during the process of goblet cell differentiation. Second, an exposed carbohydrate structure that is not normally present in human tissues is expressed in the mucin produced by malignant colonic epithelium. Third, the presence of the cancer-associated carbohydrate structure in the mucin of transitional mucosa suggests that this tissue may be in the process of early malignant transformation.

The process of cell renewal begins with the proliferation of multipotent cells which then mature into functional, differentiated cells no longer capable of division. In colonic epithelium, these processes are compartmentalized in such a way that cells replicate in a proliferative zone at the base of the crypt of Lieberkühn and undergo differentiation as they migrate into the upper portion of the crypt (1).

Alterations in membrane glycoconjugates have long been known to occur with cellular differentiation (2). In the rat intestine, for example, a change in surface membrane glycoconjugates is observed as the undifferentiated crypt cells migrate into the villus region (3). Fluorescence microscopy with fluorescein isothiocyanate (FITC)-conjugated lectins has been used to study the topographical distribution of glycoconjugates in the rat intestine and colon (4-6). Secreted glycoproteins (primarily mucin) are readily labeled and visualized by this technique. By using a series of lectins with various binding specificities, alterations in labeling have been observed between the undifferentiated and differentiated regions in the rat small (4, 6) and large (5) intestine, indicating that a modification of carbohydrate

structures accompanies the process of intestinal goblet cell differentiation. Because differentiation-dependent changes in glycoconjugates have not been investigated in the human colon, we first evaluated FITC-conjugated lectin binding to mucin in normal human colonic mucosa. Based on the findings obtained, we then examined 21 human colon carcinomas to determine the changes in lectin binding to mucinous glycoproteins that occur with malignant transformation.

Mucin is the predominant secreted glycoprotein in the colon and is elaborated by most colon cancers. The mucin extracted from colon cancer is immunologically distinct from that in the normal colon (7, 8) but the exact biochemical nature of this difference has remained elusive. Attention has also been drawn to the goblet cell mucin of the epithelium immediately adjacent to colon cancer in which the histochemical staining characteristics differ from those seen in the normal colon (9, 10). This epithelium contains numerous morphological abnormalities, and undifferentiated stem cells are found in the upper portions of the crypts (11, 12). However, the histological appearance of the tissue falls short of the criteria for malignancy, and therefore it has been termed "transitional mucosa." The FITC-lectin-binding pattern of this region has been examined and compared with that of normal human colon.

MATERIALS AND METHODS

Materials. Five FITC-lectins were used in this study, each possessing specificity for unique carbohydrate structures. The lectins and the respective sugars used to inhibit binding were: *Dolichos biflorus* agglutinin (DBA), GalNAc; soybean agglutinin (SBA), GalNAc; *Ricinus communis* agglutinin (RCA₁), Gal; *Bauhinia purpurea* agglutinin (BPA), Gal; and peanut agglutinin (PNA), Gal^{β1→3}-GalNAc. *Clostridium perfringens* neuraminidase was purchased from Sigma. The lectins were initially prepared in our laboratory by affinity chromatography according to the methods of Lotan *et al.* (13), conjugated to FITC, and purified by passage through Sephadex G-25; additional lots were purchased from two commercial sources (Vector Laboratories, Burlingame, CA, and E-Y Laboratories, San Mateo, CA).

Tissue Samples. Full-thickness specimens of normal colonic epithelium were obtained from 13 patients undergoing surgical resections for colon cancer. The mucosal samples were taken at least 6 cm from the edge of the tumor (6-60 cm; mean, 10 cm), and all were histologically normal. In addition, three specimens of histologically normal colonic epithelium were obtained from surgical resections for ischemic disease (two cases) and an

The publication costs of this article were defrayed in part by page charge payment. This article must therefore be hereby marked "advertisement" in accordance with 18 U. S. C. §1734 solely to indicate this fact.

Abbreviations: FITC, fluorescein isothiocyanate; DBA, *Dolichos biflorus* agglutinin; SBA, soybean agglutinin; RCA, *Ricinus communis* agglutinin; BPA, *Bauhinia purpurea* agglutinin; PNA, peanut agglutinin.

appendiceal carcinoid (one case). Six of the specimens of normal colon were from the ascending or transverse colon, and 10 were from the descending colon, sigmoid colon, or rectum.

Surgical specimens of primary colonic adenocarcinoma were obtained from 21 patients undergoing colonic resection for cancer. The distribution of tumors according to Dukes' system was: class A, 0; class B, 9; class C, 12. Twelve of the tumors were well-differentiated adenocarcinomas of the colon. Six tumors were poorly differentiated colonic adenocarcinomas. Three of the tumors were colloid carcinomas in which the tumor cells were suspended in large amounts of extracellular mucin. In 14 cases of cancer, microscopic examination revealed well-oriented colonic epithelium contiguous with the cancer (transitional mucosa).

Tissue Preparation. All specimens were obtained immediately after surgical removal and were fixed in a modified Bouin's solution (750 ml of aqueous saturated picric acid, 250 ml of 38% formaldehyde, and 10 ml of glacial acetic acid). After fixation, the tissues were dehydrated and embedded in paraffin. Five-micrometer sections were cut from paraffin blocks and mounted on glass slides. Selected tissues were frozen and sectioned prior to fixation to assess the effects of fixation on lectin binding.

Fluorescence Microscopy. The tissue sections were deparaffinized by two 2-min washes in xylene and hydrated by serial 2-min washes in 100%, 95%, and 80% ethanol followed by three 2-min washes in phosphate-buffered saline (pH 7.4). A solution of FITC-lectin was prepared in buffered saline at a concentration of 0.25 mg of protein per ml of solution.

FITC-lectin (50 μ l) was applied to the hydrated tissue sections or freshly prepared frozen sections; after incubation for 20 min, the excess unbound lectin was rinsed off with three 2-min washes in phosphate-buffered saline. The tissue sections were mounted in Gelvitol (Monsanto) at pH 8.0. Selected slides were incubated with 50 μ l of neuraminidase (1 unit/ml) at 37°C and pH 5.1 for 30 min and then rinsed prior to FITC-lectin labeling. The carbohydrate-binding specificity of each lectin was confirmed by incubating it with 50 μ l of the specific inhibitory sugar solution (0.2 M) prior to application to the tissue section. In the case of PNA, 0.2 M Gal completely inhibits the specific binding of lectin to tissue glycoconjugate (6, 14). Sugar specificity was demonstrated by decrease or absence of fluorescence on the section when coincubated with the sugar solution.

The prepared slides were examined with a Zeiss epifluorescence microscope. The fluorescence was graded semiquantitatively; 0, no fluorescence; 1+, trace present; 2+, weak, intermediate; 3+, strong, intermediate; and 4+, intense.

The blood type of each patient was determined by standard hemagglutination with ABO specific antisera.

RESULTS

Normal Colon. DBA and SBA, which bind exposed GalNAc residues, labeled goblet cell mucin weakly in the lower colonic crypt; labeling was progressively stronger in more-differentiated goblet cells of the upper colonic crypt (Fig. 1 A and B). Goblet cell cytoplasm labeled faintly with these lectins. The same pattern of labeling was observed in all normal colon specimens regardless of blood type. RCA₁ and BPA, which bind to exposed Gal residues, showed a pattern of labeling generally opposite to that observed with GalNAc-binding lectins. The goblet cell mucin in the lower colonic crypt labeled 3–4+ and the fluorescence diminished to 1–2+ in the mucin of the more-differentiated cells in the upper colonic crypt (Fig. 1 C and D). On the other hand, PNA did not bind to goblet cell mucin in the upper or lower colonic crypt of normal colon (Fig. 1 E and F). The tissue sections of normal colon treated with neuraminidase prior to incubation with FITC-PNA also showed no la-

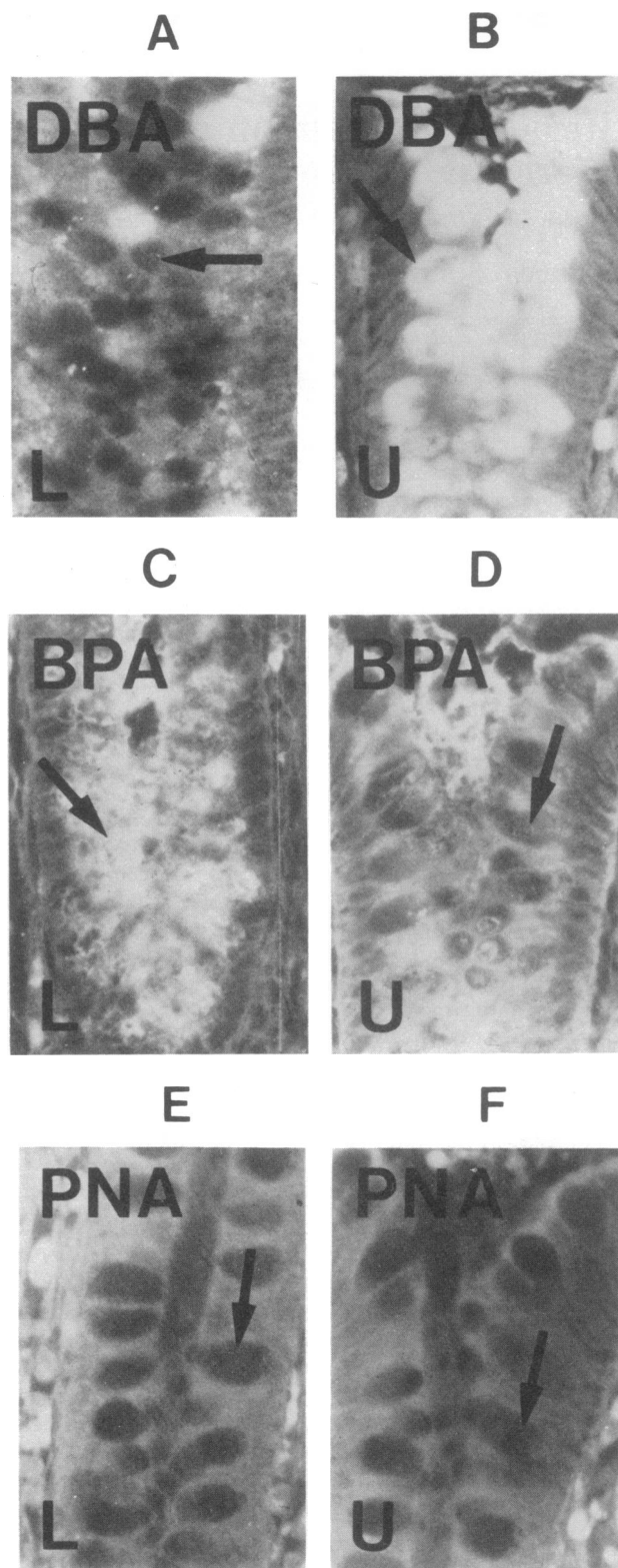


FIG. 1. Fluorescence microscopy of FITC-lectins in sections of normal human colonic mucosa. ($\times 125$.) (A) FITC-DBA labeling of goblet cell mucin in the lower half of the colonic crypt; minimal labeling of mucin in the lower crypt. (B) FITC-DBA labeling of goblet cell mucin in the upper colonic crypt, showing intense fluorescence within the mucin-containing vacuoles. (C) FITC-BPA labeling of goblet cell mucin in the lower colonic crypt. (D) FITC-BPA labeling of goblet cell mucin in the upper colonic crypt, demonstrating less fluorescence compared to the lower crypt in C. (E and F) FITC-PNA labeling of goblet cell mucin in the normal colon, demonstrating the absence of labeling in the lower and upper crypt.

Table 1. Distribution of FITC-lectin labeling of goblet cell glycoconjugates in normal human colon*

Lectin	Major sugar-binding specificity	Fluorescence	
		Lower crypt	Upper crypt
DBA	GalNAc	0-1+	4+
SBA	GalNAc	0-1+	4+
RCA ₁	Gal	3+	2+
BPA	Gal	3-4+	1-2+
PNA	Gal ^{β1→3} -GalNAc	0	0

* *n* = 16.

belonging of the mucin. Therefore, lectins specific for GalNAc residues bound preferentially to the mucin of well-differentiated goblet cells in the upper colonic crypt and lectins specific for Gal bound preferentially to the mucin of the undifferentiated goblet cells in the lower colonic crypt (Table 1).

Colon Cancer and Transitional Mucosa. With differentiation-dependent changes in the labeling of mucin in the normal colon established, the binding of lectins to transitional mucosa and human colon cancer was investigated. With DBA and SBA, transitional mucosa showed a dramatic decrease in, or absence of, labeling. The mucin present in 7 tumors labeled 4+ with DBA whereas that in 14 tumors was not labeled with the same lectin (Fig. 2B). The seven tumors that were labeled by DBA included the six largest tumors (all 8 cm or greater in diameter) and all three colloid carcinomas. SBA showed a variable labeling pattern: 2 tumors showed no labeling of mucin, 9 tumors labeled with heterogeneous (0-4+) intensity within the specimen, and 10 tumors showed uniform 4+ labeling throughout the tumor. Labeling with DBA and SBA was abolished by preincubation with GalNAc. Preincubation with Gal had no effect on either lectin.

With RCA₁ and BPA in transitional mucosa, mucin labeled weakly or not at all, whereas in the mucin secreted by cancer both lectins intensely labeled the mucin in all 21 specimens. Labeling with RCA₁ and BPA was abolished by prior incubation with Gal, whereas prior incubation with GalNAc had no effect on RCA₁ and only partially inhibited labeling with BPA.

PNA showed the most distinctive labeling differences be-

tween normal colon and colon cancer. Whereas PNA labeled none of the goblet cell mucin in the normal colon, all 21 cancers showed strong labeling of the mucin secreted into the glandular lumens (Fig. 2C). Colloid carcinoma, which elaborates large amounts of extracellular mucin, showed intense labeling of secreted mucin. Transitional mucosa also showed 4+ PNA labeling in both the lower and the upper crypt (Fig. 3 A and B). PNA also labeled the apical portion of the cytoplasm of some goblet cells in transitional mucosa. Labeling was abolished in all cases by prior incubation with Gal. Therefore, PNA, which did not bind to mucin in the normal colon, labeled the mucin in colon cancer and in transitional mucosa. The results obtained for the labeling patterns of FITC-lectins in human colon cancer and transitional mucosa are listed in Table 2.

With each of the lectins, normal mucosa from the patients without cancer labeled the same as did normal mucosa from the cancer patients. No difference in goblet cell mucin labeling was detected between the left and right colon or between fixed and frozen sections, nor were differences found between lectins prepared in our laboratory or by commercial suppliers. Mucins secreted into the crypt of Lieberkühn labeled in an identical manner to that seen within the adjacent goblet cells.

DISCUSSION

Three major conclusions can be drawn from our observations. First, the exposed carbohydrate residues in mucin undergo an alteration during the process of goblet cell differentiation, which is similar to prior findings in rat intestine (5, 6). In human tissue, the GalNAc-binding lectins (DBA and SBA) show a progressive increase in labeling in the more-differentiated goblet cells. This indicates the exposure of nonreducing GalNAc residues which had not been exposed in the less-differentiated goblet cells. This change could be accounted for by the appearance of an *N*-acetylgalactosaminyltransferase in differentiated colonic goblet cells. However, the removal of other carbohydrate residues by glycosidases or a conformational change in the mucin could produce a similar result. Further evidence for the addition of GalNAc residues to mucin carbohydrate during differentiation is the progressive decrease in labeling by the Gal-binding lectins (RCA₁ and BPA) in the upper crypt. Terminal GalNAc residues are commonly attached to Gal residues

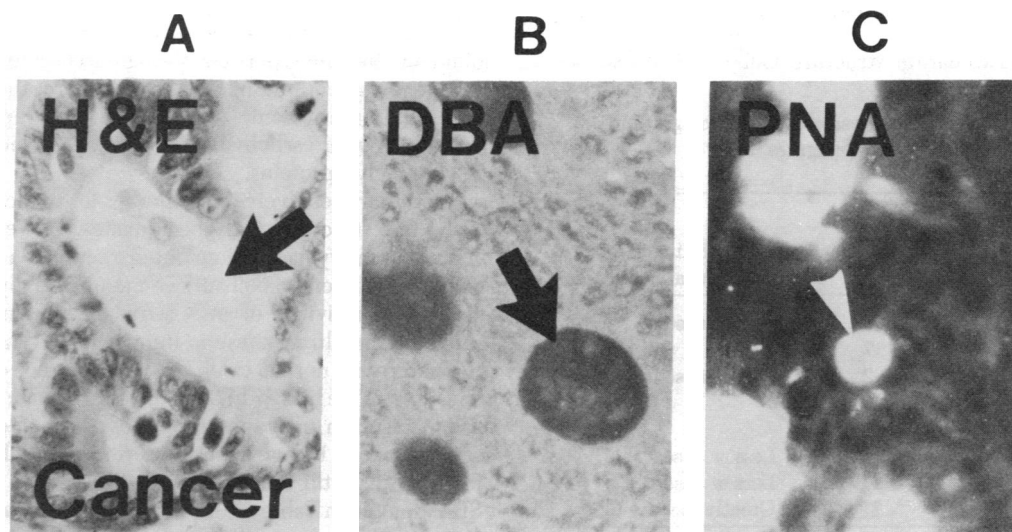


FIG. 2. Fluorescence microscopy of FITC-lectins in sections of colon cancer. ($\times 125$.) (A) Hematoxylin/eosin stain of colon cancer. Arrow, lumen of a malignant gland. (B) FITC-DBA labeling of colon cancer, showing the absence of labeling in the gland lumen. (C) FITC-PNA labeling of colon cancer, demonstrating strong fluorescence of material within the malignant gland lumen.

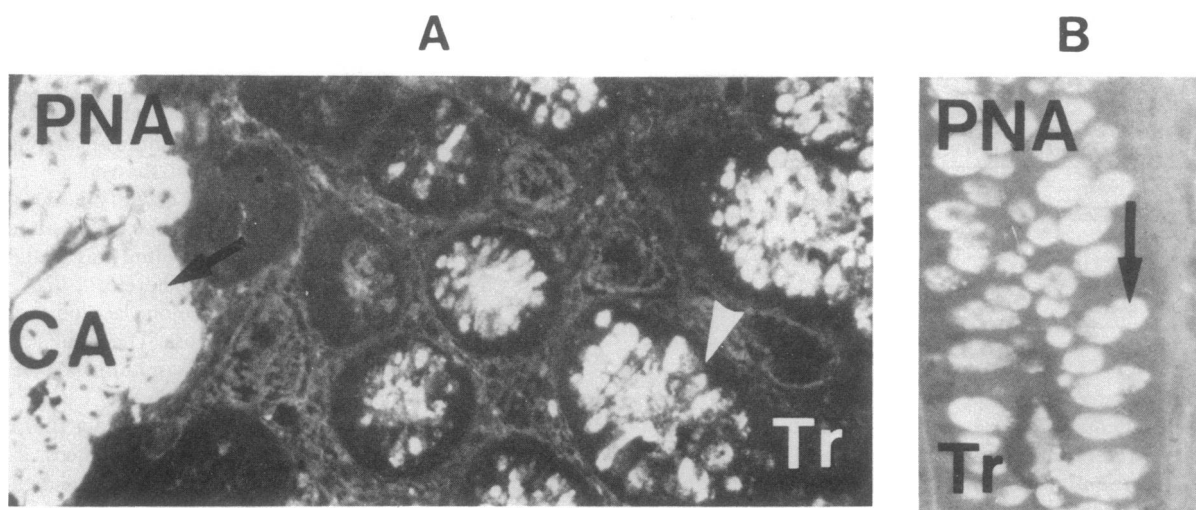


FIG. 3. FITC-PNA on transitional mucosa. (A) Lower-power fluorescence microscopy of FITC-PNA labeling at the junction of carcinoma and adjacent colonic mucosa. Black arrow at left, colloid carcinoma (CA) avidly labeled by FITC-PNA; white arrow at right, goblet cell mucin labeled by FITC-PNA immediately adjacent to the carcinoma in the transitional mucosa (Tr). ($\times 50$.) (B) Higher-power view of FITC-PNA labeling of goblet cell mucin in transitional mucosa. ($\times 125$.)

in mucin carbohydrate chains (15) and our data suggest that GalNAc and Gal are the terminal and penultimate carbohydrates, respectively, in the human colonic mucin side chain. Other laboratories have reported that the addition of terminal sialic acid residues to epithelial cell glycolipids in the rat small intestine is associated with the process of differentiation (16, 17). The addition of terminal GalNAc residues to mucin in differentiating colonic goblet cells would be a similar process. However, the majority of the "normal" colonic tissues were derived from colons bearing synchronous cancers, and it cannot be concluded with certainty that these tissues are entirely normal.

The second major conclusion of this study is that the mucin of normal colonic mucosa differs strikingly from that in colon cancer. The mucin in all 21 tumors showed intense labeling with PNA, whereas goblet cell mucin was not labeled in the normal colon. The binding of PNA to the mucin of colon cancer was inhibited by coinubation with Gal, indicating that a Gal residue in the mucin carbohydrate side chain is involved in the lectin binding. We speculate that the binding of PNA is due to the presence of the disaccharide structure $\text{Gal} \xrightarrow{\beta 1 \rightarrow 3} \text{GalNAc}$ be-

cause the lectin has a 50-fold greater affinity for this sequence than for Gal alone. This disaccharide structure is common to substances having a high affinity for PNA such as Thomsen antigen (isolated from desialylated M or N erythrocyte membranes), desialylated fetuin, and certain other glycoproteins (13). Because PNA reactivity may be inhibited by adjacent sialic acid residues, the absence of PNA binding to mucin in the normal colon could be explained by the presence of sialic acid near the nonreducing terminus (13). The failure of PNA to bind to mucin in the normal colon after neuraminidase treatment makes this explanation unlikely, although sialic acid residues could be present in mucin which are resistant to hydrolysis by the bacterial neuraminidase. Glycoconjugates that are bound by PNA are present on the surface membranes of several types of transformed cells and are absent from their nontransformed counterparts in certain animal models (18) as well as in human breast (14, 19–21), lymphoproliferative (22, 23), and urinary tract malignancies (24). This suggests that the appearance of glycoconjugates bound by PNA may be common in malignant transfor-

mation. The disaccharide structure $\text{Gal} \xrightarrow{\beta 1 \rightarrow 3} \text{GalNAc}$ is often found in the inner portion of oligosaccharide side chains in mucin-type glycoprotein (15, 25). Therefore, the appearance of PNA binding in colonic tumor tissue may represent the unmasking of such carbohydrate structures in incompletely glycosylated glycoproteins.

Lectins are relatively crude probes for detecting differences in the fine structure of glycoconjugates. However, prior work in our laboratory has demonstrated a reduction in the total carbohydrate content of cell surface membrane glycoproteins and diminished activities of an *N*-acetyl-galactosaminyltransferase and a galactosyltransferase in human colon cancer membranes compared with normal colon (26). The absence of glycosyltransferases from the biosynthetic pathway of colonic mucin in cancer would result in incompletely glycosylated side chains, which could produce the observed differences in labeling. The differences in lectin binding among the tumors [with DBA and SBA as noted in Table 1; also with *Ulex europaeus* agglutinin and concanavalin A (unpublished data)] indicate molecular heterogeneity among mucins synthesized by cancer. In spite of this, mucin in every cancer demonstrated binding by PNA. The lack of PNA binding to mucins made by the epithelial cells at the

Table 2. FITC-lectin labeling of secreted glycoconjugates in colon cancer and goblet cell glycoconjugates in transitional mucosa

Lectin	Labeling in colon cancer*		Labeling in transitional mucosa†
	Grade	No.	
DBA	0	14	Less or absent
	4+	7	
SBA	0	2	Less or absent
	0–4+‡	9	
	4+	10	
RCA ₁	4+	21	Less or absent
BPA	4+	21	Less or absent
PNA	4+	21	Greatly increased

* $n = 21$.

† $n = 14$; compared to normal colon.

‡ 0–4+ refers to heterogeneous fluorescence, from absent to intense, within a single tumor.

base of the normal crypt suggests that, with regard to mucin biosynthesis, undifferentiated proliferative colonic cells are not identical to malignant cells.

The third major conclusion is that the goblet cell mucin of transitional mucosa differs from that of both normal and malignant colonic mucosa. Transitional mucosa is found immediately adjacent to colon cancer and is typified by abnormal morphological and growth characteristics, but its histological appearance is not frankly malignant. Goblet cell mucin in transitional mucosa differs from that found in the normal colon in that binding by DBA, SBA, RCA₁, and BPA is diminished and binding by PNA occurs. The observation that the mucin in transitional mucosa is bound by PNA suggests a progression from transitional mucosa to cancer, but further experiments are required to determine whether this alteration in glycoprotein synthesis actually indicates early (but not morphologically evident) malignant transformation of colonic epithelial cells. If so, these observations provide a biochemical marker of the malignant transformation that precedes the histological appearance of malignancy and they may be developed into a powerful probe for the early detection of cancer in the human colon.

The authors thank Drs. Rudi Schmid, James Whitehead, and Laurence McIntyre for critical reviews and suggestions. The authors also gratefully thank Mr. Rick Frautschi for the preparation of this manuscript and Mr. William Frye for the preparation of the photomicrographic prints. This work was supported by National Institutes of Health National Research Service Award AM 06327, Training Grant AM 07007, and U.S. Public Health Service Grant CA 14905 from the National Cancer Institute through the National Large Bowel Cancer Project.

1. Martin, B. F. (1961) *Anat. Rec.* **140**, 1-5.
2. Artzt, K., Dubois, P., Bennett, D., Condamine, H., Babinet, C. & Jacob, F. (1973) *Proc. Natl. Acad. Sci. USA* **70**, 2988-2992.
3. Weiser, M. M. (1973) *J. Biol. Chem.* **248**, 2536-2541.
4. Freeman, H. J., Etzler, M. E., Garrido, A. B. & Kim, Y. S. (1978) *Gastroenterology* **75**, 1066-1072.
5. Freeman, H. J., Lotan, R. & Kim, Y. S. (1980) *Lab. Invest.* **42**, 405-412.
6. Etzler, M. E. & Branstrator, M. L. (1974) *J. Cell Biol.* **62**, 329-343.
7. Nairn, R. C., Fothergill, J. E. & McEntegart, M. G. (1962) *Br. Med. J.* **1**, 1791-1793.
8. Gold, D. & Miller, F. (1975) *Nature (London)* **255**, 85-87.
9. Filipe, M. I. & Branfoot, A. C. (1974) *Cancer* **32**, 282-290.
10. Dawson, P. A. & Filipe, M. I. (1976) *Cancer* **37**, 2388-2398.
11. Riddell, R. H. & Levin, B. (1977) *Cancer* **40**, 2509-2522.
12. Lipkin, M. (1974) *Cancer* **34**, 878-888.
13. Lotan, R., Shutelsky, E., Danon, D. & Sharon, M. (1974) *J. Biol. Chem.* **250**, 8518-8523.
14. Springer, G. F., Desai, P. R. & Bantwala, I. (1975) *J. Natl. Cancer Inst.* **54**, 335-339.
15. Allen, A. (1978) *Br. Med. Bull.* **1**, 28-33.
16. Bouhours, J. F. & Glickman, R. M. (1976) *Biochim. Biophys. Acta* **441**, 123-133.
17. Glickman, R. M. & Bouhours, J. F. (1976) *Biochim. Biophys. Acta* **424**, 17-25.
18. Reisner, Y., Gachelin, G., Dubois, P., Nicolas, J., Sharon, N. & Jacob, F. (1977) *Dev. Biol.* **61**, 20-27.
19. Fischer, K., Poschmann, A. & Stegner, H. E. (1977) *Dtsch. Med. Wochenschr.* **102**, 1227-1228.
20. Newman, R. A., Klein, P. J. & Rudland, P. S. (1979) *J. Natl. Cancer Inst.* **63**, 1339-1346.
21. Howard, D. R. & Batsaki, J. G. (1980) *Science* **210**, 201-203.
22. Levin, S., Russell, E. C., Blanchard, D., McWilliams, N. B., Mauer, H. M. & Mohanankumar, T. (1980) *Blood* **55**, 37-39.
23. Reisner, Y., Sharon, M. & Haran-Ghera, N. (1980) *Proc. Natl. Acad. Sci. USA* **77**, 2244-2246.
24. Limas, D. & Lange, P. (1980) *Cancer* **46**, 1366-1373.
25. Carlson, D. M. (1968) *J. Biol. Chem.* **243**, 616-626.
26. Kim, Y. S., Isaacs, R. & Perdomo, J. M. (1974) *Proc. Natl. Acad. Sci. USA* **71**, 4869-4873.