

Lih-Huei Chen · Po-Liang Lai · Chi-Chien Niu  
Chih-Hwa Chen · Wen-Jer Chen · Tsai-Sheng Fu

## Intracorporal bone grafting for vertebral compression fractures with intraosseous vacuum phenomenon

Accepted: 9 July 2003 / Published online: 30 August 2003  
© Springer-Verlag 2003

**Abstract** From April 1998 to January 2000 we treated 14 patients with vertebral osteoporotic compression fractures and intraosseous vacuum phenomenon with intracorporal bone grafting using a mixture of autogenous bone graft and calcium sulfate and posterior instrumentation. The mixture was packed into the fractured vertebral body through two tunnels created in the pedicles. Eleven patients were followed for a minimum of 24 months. All vertebral bodies healed. There were no perioperative complications. The average vertebral height restoration was 31%. On the visual analogue scale, there was an improvement of average 37 clinical scores.

**Résumé** D'avril 1998 à janvier 2000 nous avons traité 14 malades atteints de fractures vertébrales ostéoporotiques par compression avec phénomène de vide intraosseux avec instrumentation postérieure et greffe intracorporelle utilisant un mélange d'os autogène et de sulfate de calcium. Le mélange a été introduit dans le corps vertébral à travers deux tunnels créés dans les pédicules. Onze malades ont été suivis avec un minimum de 24 mois. Il n'y avait pas de complication peropératoire. Les corps vertébraux ont tous consolidé. La restauration de la hauteur vertébrale moyenne était de 31%. Sur l'échelle analogique visuelle il y avait une amélioration moyenne de 37 dans le score clinique.

No benefits in any form have been received or will be received from a commercial party related directly or indirectly to the subject of this article.

L.-H. Chen (✉) · P.-L. Lai · C.-C. Niu · C.-H. Chen  
W.-J. Chen · T.-S. Fu  
Department of Orthopaedic Surgery,  
Chang Gung Memorial Hospital,  
5 Fu-Hsin Street, 333 Kweishan, Taoyuan, Taiwan,  
Republic of China  
e-mail: lhchen2132@adm.cgmh.org.tw  
Tel.: +886-3-3281200, Fax: +886-3-32 8113

### Introduction

Patients with osteoporotic vertebral compression fractures have a relatively high morbidity and mortality rate. Osteoporotic compression fractures cause chronic pain, sleep loss, reduced mobility, depression, and a loss of independence. Intraosseous vacuum phenomena are potentially consequences of vertebral nonunion. Kyphotic spine deformity is common. Most painful osteoporotic compression fractures are treated conservatively, with bed rest, narcotic analgesia, orthosis, and physical therapy. However, bed rest accelerates bone loss and causes muscle wasting, leading to increased pain. Medications taken for symptomatic relief can cause further drug-related side effects, such as gastrointestinal tract upset.

Patients generally present with kyphosis at the thoracolumbar junction. Combined anterior structure support and posterior long instrumentation has been reported for treating osteoporotic compression fracture with kyphosis [10]. Perioperative morbidity is common among the senile population.

Percutaneous vertebroplasty, using bone cement injection into the vertebral body, provides stabilization and relief of pain [15]. However, the procedure suffers from problems of cement leakage causing deformity, failure of correction and significant complications, such as pulmonary, vascular, and spinal cord injuries, as well as poor bone incorporation in long-term follow-up.

This study describes a treatment option for painful compression fractures with intraosseous vacuum phenomena by intracorporal bone grafting. The method uses a combination of biodegradable calcium sulfate and iliac autogenous bone graft as an alternative to augmentation of the intraosseous vacuum cleft.

### Patients and methods

From April 1998 to January 2000, 14 patients (13 women and one man), aged from 55 to 69 years and diagnosed as having osteoporotic compression fracture with intraosseous vacuum phenomenon

were enrolled in this study. The indications for treatment were intensive focal back pain, progressive kyphosis, and failure of conservative medical treatment. Meanwhile, routine exclusion criteria included history of stroke, senile dementia, and major medical diseases that needed intensive treatment. Patients with neurological compromise or kyphosis greater than 35° received a combined anterior and posterior surgery and were excluded from this study. All enrolled cases underwent intracorporeal bone grafting. Moreover, the anterior body height was measured preoperatively and postoperatively. Additionally, the vertebral body was assessed using AP and lateral views of radiographic images at regular follow-up periods.

Intracorporeal bone grafting was performed under general anesthesia. The patient was positioned prone on a "four-poster frame" that supported the upper chest and pelvis to enable maximum extension of the spinal column. This kind of postural reduction generally restored the body height of fractured vertebrae. The patient then was prepared in a strictly sterile manner. The surgeons used the standard posterior approach to expose the posterior aspect of the spine for spinal stabilization, including the proximal and distal neighboring vertebrae. The spinous process and supraspinatus ligament were preserved intact. Pedicle screws were inserted into the bilateral pedicles of the proximal and distal neighboring vertebrae using a fluoroscopic guide. The same technique for identifying the entry points of pedicle screws was used on the fractured vertebrae. The tunnels through the bilateral pedicles were expanded using a 5.0 mm dilator.

The mixture of bone graft then was prepared by mixing autograft and calcium sulfate. The amount of autogenous iliac crest bone graft harvested was not standardized but typically reflected the amount safely obtainable from a single incision along the right posterior iliac crest. The amount was usually grossly estimated at approximately 10–15 cc. The senile cancellous bone was always very spongy and compressible. The volume of the cancellous bone decreased with slight pressure. The bone graft slurry was mixed with 10 cc of (4.8-mm diameter) calcium sulfate pellets (OSTEOSET, Wright Medical Technology, Arlington, TN, USA). The 10 cc calcium sulfate consisted of 50 pellets.

The mixture was then packed into the fractured vertebrae via the tunnels using a small bone tamp. Posterior instrumentation with transpedicular screws was applied to stabilize and maintain an adequate spinal curve. The wound was closed layer by layer after securing the rods to the screws.

Following surgery, assessment was performed at regular intervals: immediately after surgery, then at 3 months, 6 months, 1 year, and annually thereafter. AP and lateral radiographs were taken at each follow-up. Special attention was paid to the presence of calcium sulfate resorption and vertebral body bone healing.

A visual analog scale (VAS) was used to assess pain severity [4]. Patients were instructed to make a single vertical mark on a horizontally oriented, ungraduated, 100-mm VAS labeled "no pain" at the far left and "most pain possible" at the far right. An initial VAS score was taken on enrollment. Subsequent VAS scores were recorded at each follow-up. Patients were not allowed to review their previous scores.

## Results

Three patients failed to complete the 2-year minimum follow-up. One patient died of lung cancer, one became bed-ridden following a stroke, and one was lost to follow-up. Eleven of the 14 patients were followed-up for at least 2 years (24–30 months). All cases had vacuum cleft confirmed by X-ray, CT, or MRI. All patients were diagnosed with osteoporotic compression fracture with intraosseous osteonecrosis. The compression fracture occurred mostly at the thoracolumbar junction. Affected levels were T11 ( $n=1$ ), T12 ( $n=6$ ), and L1 ( $n=4$ ).

The average hospital stay was five (4–7) days, average operation time was 2.4 (2–3.2) h, and average blood loss was 350 (200–450) cc. No significant perioperative complication occurred. Moreover, there was no evidence of bone graft mixture dislodgement.

The average of 37 clinical improvement scores was calculated. Moreover, the average VAS was 73 preoperative and 36 postoperatively. Additionally, the average anterior height was 43% of the predicted height before treatment and 74% of the predicted height after treatment. The average vertebral height restoration was 31%. Vertebral body bone healing was achieved in all patients at 6-month follow-up, confirmed by increased opacity of the vertebral body (Fig. 1).

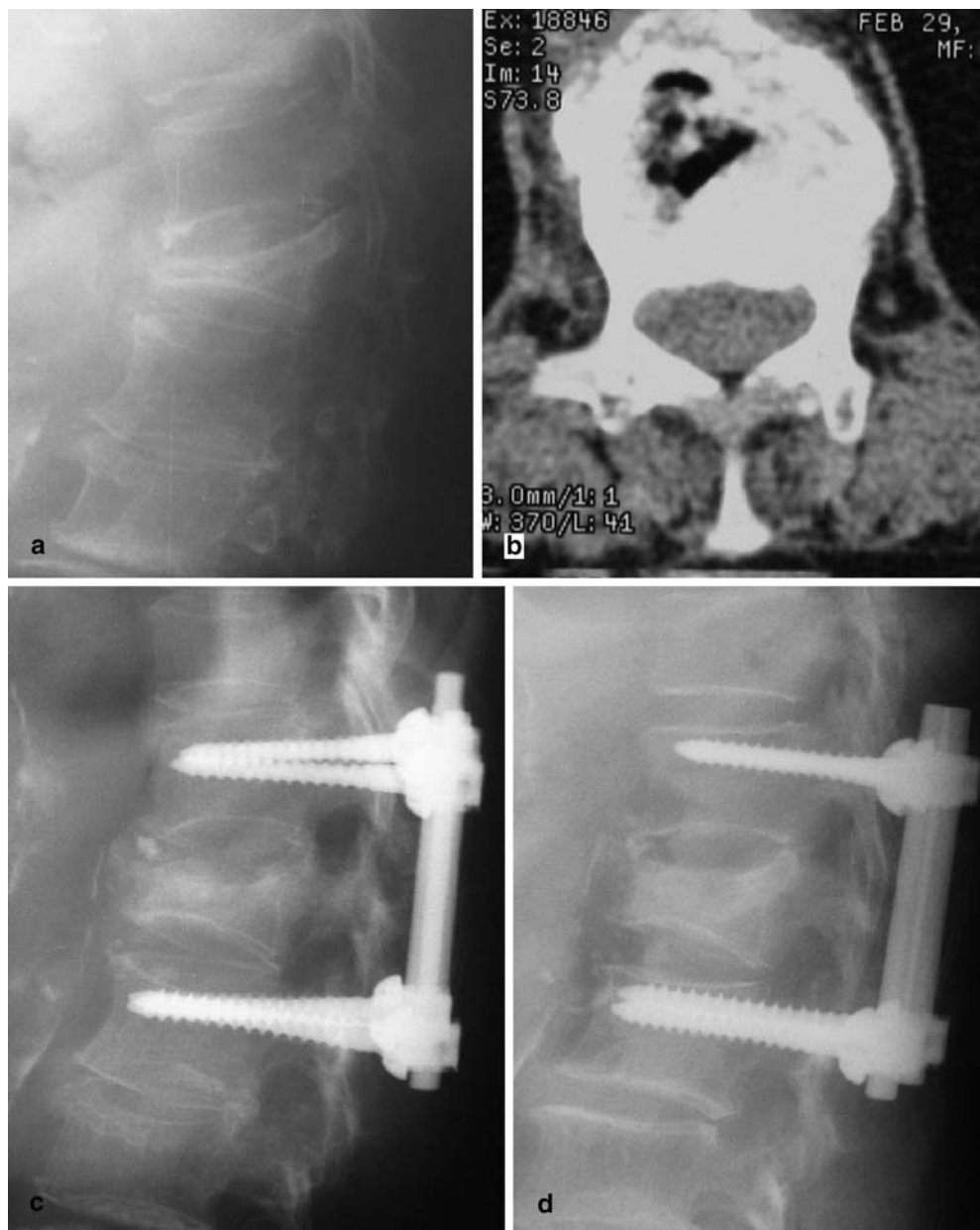
One case developed an adjacent fracture at the neighboring proximal vertebral body 1 year after index surgery. X-ray showed implant loosening. This patient had no history of major trauma postsurgery. Despite implant loosening and adjacent fracture, this patient tolerated the outcome and lived with a thoracolumbar brace.

## Discussion

Osteonecrosis of the vertebral body is a delayed sequel of osteoporotic compression fracture. Kümmell first described this condition 1895 as a traumatic osteitis in which painful kyphosis develops in patients with vertebral fracture [11]. The cause of this entity remains poorly understood. Most investigators agree that the intraosseous vacuum phenomenon is a consequence of a vascular insult causing secondary bone necrosis [2]. Lane et al. suggested that the clefts represent unhealed fractures [12]. Vacuum cleft is not rare in senile patients. The radiographic sign of Kümmell's disease, as described in the literature, is the presence of a bandlike radiolucency in a collapsed vertebral body, known as the intraosseous vacuum cleft. The cleft is hypointensive on a T1-weighted MR image. On T2-weighted images, the cleft may be either hypointensive or hyperintensive, depending on whether gas or fluid occupies the cleft. CT shows a cystic lesion within the vertebral body [2].

Percutaneous vertebroplasty has been reported for treating Kümmell's disease. This technique involves using bone cement (PMMA, polymethylmethacrylate) to reinforce the collapsed vertebral bodies. This technique has been applied successfully to fill defects created by tumors or fractures in vertebra. However, because liquid-form PMMA is forced into the cancellous vertebral bone matrix with high pressures, the potential for leaks is a concern. Cement leakage following vertebroplasty has been reported in between 38% and 72.5% of cases [19]. This phenomenon may cause pulmonary embolism and neurological complications, including myelopathy and radiculopathy [8,13,19]. Kyphoplasty is a new technique involving the insertion of a balloon into a collapsed vertebral body to elevate the end plates of the vertebra and create a cavity for the controlled placement of bone cement [5]. The short-term results of percutaneous ver-

**Fig. 1a–d** A 68-year-old female patient. **a** Lateral view of L1 compression fracture 4 months after a minor trauma. **b** CT showed a vacuum cleft. **c** X-ray at 1 month postoperatively showed a radiolucent body packed with calcium sulfate pellets. **d** Vertebral body bone healing was achieved 6 months postoperatively



tebroplasty and kyphoplasty are encouraging, even though long-term follow-up results are lacking. Besides, PMMA provides a “sealed” instead of healed fused body, and is possibly associated with poor bone incorporation.

Autogenous bone graft improved osseous union by contributing osteoconductive and osteoinductive materials to the fracture site. Unfortunately, a finite amount of bone graft is available from each individual, and donor-site morbidity is common. These limitations have prompted the development and use of synthetic bone-graft materials, including medical-grade calcium sulfate, to minimize or eliminate the need for autogenous bone graft. Bone quality and quantity reduces with the aging process. Cancellous bone of senile patients generally is spongy and compressible and is usually replaced with fatty tissue. In the experience of the authors, bone graft

harvested from the iliac crest was insufficient for packing the entire space of a vertebral body vacuum cleft. Consequently, the bone graft needs to be mixed with calcium ceramic as a graft expander.

Calcium sulfate is osteoconductive, supports the in-growth of blood vessels and osteogenic cells, acts as space filler, and prevents in-growth of soft tissue [3, 6, 7, 14]. Calcium sulfate has long been used to fill bone defects and as a bone graft substitute. In 1978, Peltier and Jones reported the use of calcium sulfate to treat unicameral bone cysts with successful healing of the defect and bone formation in the cyst [16]. A histological study has shown that osteoblasts attach to the surface of the calcium sulfate pellets [17]. The osteoblasts then produce osteoid and the calcium sulfate becomes superfluous and dissolves away. The resorption rate of calcium sulfate

pellets corresponds to the rate of new bone growth with minimal foreign body reaction.

OSTEOSSET is manufactured from a surgical grade calcium sulfate that has a uniform shape and size and a predictable rate of resorption and bone ingrowth into osseous defects [9, 18]. The radiographic rate of resorption closely corresponds to the rate of trabecular new bone growth.

Mixing autogenous cancellous bone with calcium ceramic to expand graft volume is an accepted technique for large defects of long bones [3]. However, clinical use in the spine has been limited. The addition of a ceramic scaffold can also provide improved structural support for the vertebral column. Using a mixture of autogenous bone graft and calcium sulfate pellets is safer than injecting liquid bone cement into the vertebral body. The mixture is solid and is packed into the vertebral vacuum cleft via the bilateral pedicle. The tunnels are dilated to facilitate access to the body. Because the mixture cannot provide immediate stability, as PMMA, posterior instrumentation by placing pedicle screws at the neighboring proximal and distal vertebrae is essential to relieving pain and provide a rigid fixation for bone union.

Adjacent fractures following percutaneous vertebroplasty or kyphoplasty with bone cement are common [1]. Increased stiffness of the cement-augmented vertebrae alters the biomechanics of load transfer to the adjacent vertebrae. The early failure of the adjacent, nonaugmented level may result from a 'stress-riser' effect and a significant disparity in biomechanical properties between the two involved vertebral bodies. Theoretically, a healing vertebral body is less rigid than a cemented vertebral body and therefore has less likelihood of developing adjacent fractures.

The present study contained one patient that developed adjacent fracture at the proximal vertebrae with consequent implant loosening. Despite kyphotic posture, the patient was satisfied with the result. The patient could walk independently under protection of orthosis.

Reviewing the literature, most studies on percutaneous vertebroplasty were published in the recent 3 years. The long-term outcomes of cemented vertebral body and its biomechanical influence on adjacent levels are unclear.

From clinical experience, this study demonstrated that the mixture of iliac cancellous bone graft and calcium sulfate is an efficacious bone graft material. This mixture is easy to handle because the tunnels of the bilateral pedicles were enlarged by a dilator and the mixture was spongy. Moreover, both patients and physicians were satisfied with the results. Autogenous bone graft provides an osteoinductive and osteoconductive material for enhancing bone healing. Calcium sulfate is a readily available bone-graft substitute that acts as a bone-graft expander. Posterior instrumentation with transpedicular screws can provide immediate postoperative stabilization and facilitate bone healing of the vertebral bodies. This

technique is an effective option for treating vertebral compression fractures with intraosseous vacuum phenomenon that cannot be relieved with conservative medical treatment.

## References

- Berlemann U, Ferguson SJ, Nolte LP, et al (2002) Adjacent vertebral failure after vertebroplasty. A biomechanical investigation. *J Bone Joint Surg [Br]* 84:748–752
- Bhalla S, Reinus WR (1998) The linear intravertebral vacuum: a sign of benign vertebral collapse. *Am J Roentgenol* 170: 1563–1569
- Borrelli J Jr, Prickett W, Ricci W (2003) Treatment of non-unions and osseous defects with bone graft and calcium sulfate. *Clin Orthop* 411:245–254
- Bird SB, Dickson EW (2001) Clinically significant changes in pain along the visual analog scale. *Ann Emerg Med* 38:639–43
- Garfin SR, Yuan HA, Reiley MA (2001) New technologies in spine: kyphoplasty and vertebroplasty for the treatment of painful osteoporotic compression fractures. *Spine* 26:1511–1515
- Gitelis S, Piasecki P, Turner T et al (2001) Use of a calcium sulfate-based bone graft substitute for benign bone lesions. *Orthopedics* 24:162–166
- Glancy GL, Brugioni DC, Filert RE et al (1991) Autograft versus allograft for benign lesions in children. *Clin Orthop* 262:28–33
- Jang JS, Lee SH, Jung SK (2002) Pulmonary embolism of polymethylmethacrylate after percutaneous vertebroplasty: a report of three cases. *Spine* 27:E416–418
- Kelly CM, Wilkins RM, Gitelis S et al (2001) The use of a surgical grade calcium sulfate as a bone graft substitute: results of a multicenter trial. *Clin Orthop* 382:42–50
- Kostuik JP, Shapiro MB (2003) Open surgical treatment of osteoporotic fractures and deformity of the spine. *Instr Course Lect* 52:569–78
- Kümmell H (1895) Die rarefizierende Ostitis der Wirbelkörper. *Deutsche Med* 21:180–181
- Lane JJ, Maus TP, Wald JT et al (2002) Intravertebral clefts opacified during vertebroplasty: pathogenesis, technical implications, and prognostic significance. *Am J Neuroradiol* 23: 1642–1646
- Lee BJ, Lee SR, Yoo TY (2002) Paraplegia as a complication of percutaneous vertebroplasty with polymethylmethacrylate: a case report. *Spine* 27:E419–22
- Mirzayan R, Panossian V, Avedian R et al (2001) The use of calcium sulfate in the treatment of benign bone lesions. A preliminary report. *J Bone Joint Surg [Am]* 83:355–358
- Ng PP, Caragine LP Jr, Dowd CF (2002) Percutaneous vertebroplasty: an emerging therapy for vertebral compression fractures. *Semin Neurol* 22:149–156
- Peltier LF, Jones RH (1978) Treatment of unicameral bone cysts by curettage and packing with plaster of Paris pellets. *J Bone Joint Surg [Am]* 60:820–822
- Turner TM, Urban RM, Gitelis S et al (2001) Radiographic and histologic assessment of calcium sulfate in experimental animal models and clinical use as a resorbable bone-graft substitute, a bone-graft expander, and a method for local antibiotic delivery. One institution's experience. *J Bone Joint Surg [Am]* 83 (Suppl) 2:8–18
- Winn SR, Hollinger JO (2000) An osteogenic cell culture system to evaluate the cytocompatibility of Osteoset, a calcium sulfate bone void filler. *Biomaterials* 21:2413–2425
- Yeom JS, Kim WJ, Choy WS et al (2003) Leakage of cement in percutaneous transpedicular vertebroplasty for painful osteoporotic compression fractures. *J Bone Joint Surg [Br]* 85: 83–89