

H. Bächis · L. Perlick · M. Tingart · C. Lüring ·  
C. Perlick · J. Grifka

## Radiological results of image-based and non-image-based computer-assisted total knee arthroplasty

Accepted: 17 November 2003 / Published online: 17 January 2004  
© Springer-Verlag 2004

**Abstract** Restoration of the mechanical limb axis and accurate component orientation are two major factors affecting the long-term results after total knee replacement (TKR). Different navigation systems are available to improve the outcome. Image-based systems require pre-operative CT scans, while non-image-based systems gain all necessary information intra-operatively during a registration process. We studied 130 patients who received a TKR either using the CT-based (Knee 1.1) or the CT-free module (CT-free Knee 1.0) of the BrainLAB Vector-Vision Navigation System. Post-operative leg alignment and component orientation was determined on long-leg coronal and lateral X-rays. Sixty of 65 patients in the CT-based group and 63/65 patients in the CT-free group had a post-operative leg axis between 3° varus/valgus. No significant differences were found for varus/valgus orientation of the femoral and tibial components.

**Résumé** La restauration de l'axe mécanique du membre inférieur et l'orientation exacte des implants sont deux facteurs majeurs qui affectent les résultats à longue échéance après arthroplastie totale du genou total (PTG).

Statement on Conflict of Interest: Although none of the authors has received or will receive benefits for personal or professional use from a commercial party related directly or indirectly to the subject of this article, benefits have been or will be received but will be directed solely to a research fund, foundation, educational institution, or other non-profit organisation with which one or more of the authors are associated.

H. Bächis (✉) · L. Perlick · M. Tingart · C. Lüring · J. Grifka  
Department of Orthopaedic Surgery,  
University of Regensburg,  
PO Box 100662, 93042 Regensburg, Germany  
e-mail: holger.baethis@klinik.uni-regensburg.de  
Tel.: +49-940-5182401  
Fax: +49-940-5182920

C. Perlick  
Department of Orthopaedics, Aarhus Amtssygehus,  
Aarhus University Hospital,  
Tage Hansensgade 2, 8000 Aarhus C, Denmark

Différents systèmes de navigation sont disponibles pour améliorer ces paramètres. Certains systèmes de navigation exigent une tomodensitométrie (TDM) préopératoire, tandis que d'autres acquièrent les informations nécessaires pendant l'intervention. Nous avons étudié 130 malades qui ont reçu un PTG soit avec une TDM préopératoire (Genou 1.1) soit avec le système sans TDM (BrainLAB Vecteur Vision® Navigation System), genou 1.0. L'alignement postopératoire du membre inférieur et l'orientation des composants a été déterminé sur des grands clichés coronaires et latéraux de membre inférieur. 60/65 malades dans le groupe TDM préopératoire et 63/65 malades dans le groupe sans TDM avaient un axe de membre inférieur postopératoire entre 0 et 3° de varus/valgus. Aucune différence notable n'a été trouvée concernant l'orientation des composants en varus/valgus.

### Introduction

Aseptic loosening and knee instability are the most important reasons for revision of total knee arthroplasty (TKA) with an overall 10-year revision rate of 15% [17]. Malalignment of the mechanical limb axis is thought to be an important factor affecting patient outcome and resulting in prosthetic loosening. In previous studies, a post-operative limb axis within a range of  $\pm 3^\circ$  varus/valgus was found to be associated with a lower rate of aseptic prosthetic loosening [1, 3, 4, 8, 14, 16].

Although various mechanical alignment guides have been designed to improve alignment accuracy in TKA, the conventional implantation technique fails in up to 30% of cases in restoring a mechanical limb axis within a range of  $\pm 3^\circ$  of varus or valgus [5, 9, 10, 12]. Potential errors for malalignment are variations in the bony anatomy, visual misjudgement by the surgeon and general technical limitations [2, 7, 11, 15].

Therefore, computer-assisted surgery has been recently introduced in TKA to improve the accuracy of component orientation. Different navigation systems are available: CT-based systems require pre-operative CT scans, while

CT-free systems gain all necessary information intra-operatively during a surface matching process.

The aim of this prospective study was to analyse the accuracy of component orientation and post-operative leg alignment when using either a CT-based or a CT-free navigation system.

## Materials and methods

### Study design and patients

Primary TKA was performed on 130 patients with osteoarthritis of the knee using either the CT-based (Knee 1.1) or the CT-free module (CT-free Knee 1.0) of the Vector-Vision Navigation System (BrainLAB, Munich, Germany). Pre-operatively, no exclusions were defined regarding age, gender, degree of leg axis deviation or previous surgery. The same prosthesis model (PFC Sigma, DePuy Inc., Warsaw, USA) was implanted in all cases, and patients were prospectively followed up. The study was approved by the local ethic committee, and all patients gave their informed consent prior to their inclusion in the study.

Patients in both groups were comparable regarding age, gender and pre-operative leg deformity. In the CT-free group, 42 women and 23 men were included. The mean age was  $69.3 \pm 8.4$  (range: 49–88) years, and the mean pre-operative deviation of leg axis was  $8.1 \pm 4.7^\circ$  (range:  $20^\circ$  varus to  $21^\circ$  valgus). In the CT-based group, 47 women and 18 men were included. The mean age was  $66.5 \pm 9.4$  (range: 30–80) years, and the mean pre-operative deviation of leg axis was  $7.7 \pm 5.0^\circ$  (range:  $18^\circ$  varus to  $22^\circ$  valgus).

### Computer-assisted surgical technique

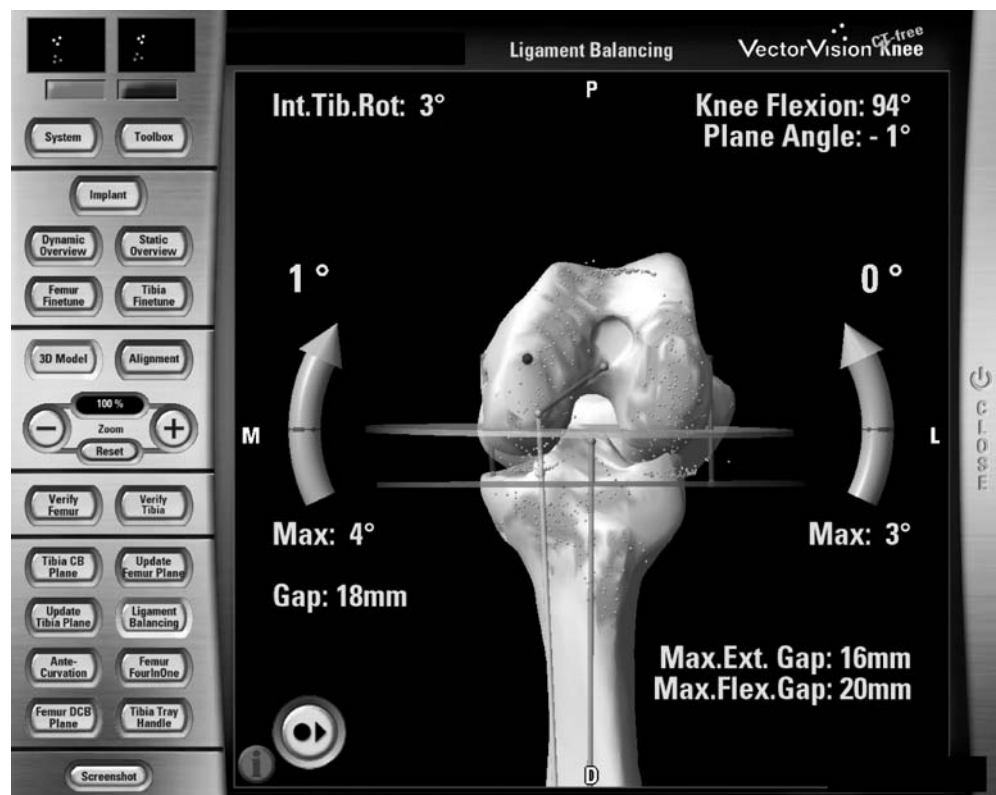
The navigation system used in this study (VectorVision, BrainLAB) has an optical tracking unit, which detects reflecting marker spheres by an infrared camera. For CT-based operations, pre-operative CT scans of the hip, knee and ankle region were performed according to a standard protocol. In a pre-operative planning process, the system generates a three-dimensional reconstruction of the femur and tibia and recommends an optimal component orientation. If necessary, a fine-tuning of resection planes and component orientation can be performed. For axial rotational of the femoral component, the epicondylar axis was used. For the proximal tibial resection plane, the resection level was set to 8 mm from the deepest point of the higher tibia plateau level. Rotational alignment of the tibial tray was orientated to the medial third of the tibial tuberosity. The average time of pre-operative planning and data transfer took  $21 (\pm 7)$  min.

In both techniques, two reference arrays with passive marker spheres were rigidly attached to both the femoral and the tibial bone. For the CT-based module, this was followed by a surface-matching process, where the surgeon has to digitise up to 20 points on the bony surface of both femur and tibia.

For the CT-free module, special landmarks and bone surface information were gained at the beginning of the operation by sliding a pointer over the tibial plateau and the femoral condyles. Based on these data, the system creates an adapted bone model of the specific patient's anatomy and offers a planning proposal for component orientation. Further, in the CT-free module, the surgeon has the opportunity to check and document the leg axis and to examine the ligament laxity throughout the entire range of motion (Fig. 1).

In both techniques, the femoral and tibial cutting blocks were orientated to the bone in real-time visualisation on the navigation system. After resection, all planes were checked by the navigation system's verification tool.

**Fig. 1** Ligament balancing support: ligament tension, leg axis and information on extension and flexion gap can be checked at every step of the operation



## Radiological evaluation and statistics

Axial limb alignment and component orientation were evaluated by two independent observers three times on different days using standardised pre- and post-operative full-length weight-bearing radiographs. The Kolmogorov-Smirnov test was used to evaluate if axial limb alignment followed a normal (Gaussian-shaped) distribution, and no significant departures were identified. Limb alignment between both groups was compared using un-paired *t*-tests. Level of statistical significance was determined for  $p < 0.05$ . The coefficient of variation was calculated to determine intra- and inter-observer variability. The intra-observer variability for limb axis determination was less than 3%, and the inter-observer variation was less than 4%.

## Results

### Leg axis deviation

In the CT-based group, the average deviation from the neutral leg axis was  $1.7 \pm 1.2^\circ$  (range:  $5^\circ$  valgus to  $4^\circ$  varus). In the CT-free group, it was  $1.3 \pm 1.1^\circ$  (range:  $5^\circ$  valgus to  $4^\circ$  varus).

Sixty TKAs in the CT-based group and 63 in the CT-free group had a leg axis within a range of  $\pm 3^\circ$  (varus/valgus). The maximum deviation from the neutral leg axis was  $5^\circ$  in both groups (two cases in the CT-based group and one case in the CT-free group). Between the groups, no statistical difference was found ( $p > 0.05$ ) (Fig. 2).

### Component alignment

The frontal plane alignment of the femoral component (centre of the femoral head to the centre of the component) was found within a range of  $\pm 3^\circ$  in 63 cases in the CT-based group and in 62 cases in the CT-free group ( $p > 0.05$ ). In both groups, all patients except one had a varus/valgus alignment of the tibial component within a range of  $\pm 3^\circ$  ( $p > 0.05$ ).

In the CT-based group, the sagittal alignment of the femoral component was  $5.0 \pm 2.4^\circ$  (range:  $0$ – $13^\circ$ ), while it was  $7.1 \pm 3.5^\circ$  (range:  $0$ – $15^\circ$ ) in the CT-free group. In the CT-based group, the posterior slope of the tibial compo-

nent was  $2.7 \pm 2.1^\circ$  compared with  $2.1 \pm 2.3^\circ$  in the CT-free group.

### Duration of surgical procedure

In both groups, no conversion from computer-assisted procedure to conventional technique was required. The mean time for surgery (skin to skin) was  $81 \pm 15$  min for the CT-based group and  $76 \pm 13$  min for the CT-free group.

## Discussion

The tolerable range of leg axis deviation after TKA is discussed in the literature. Several authors report superior results if deviation in the frontal plane does not exceed  $3^\circ$  varus/valgus [3, 4, 14, 16]. Rand and Coventry [14] found a 10-year survival rate of 90% for patients with less than  $4^\circ$  deviation from the neutral leg axis, while the survival rate decreased to 71–73% when the deviation exceeded  $4^\circ$ . Jeffery et al. [4] analysed the outcome after TKAs in 115 patients. They found a loosening rate of 24% when the mechanical axis exceeded  $\pm 3^\circ$  varus/valgus, whereas it was 3% in cases with a leg axis deviation within a range of  $\pm 3^\circ$ . Hvid and Nielsen [3] studied the overall post-operative limb alignment in 138 consecutive TKAs. They reported superior long-term results with a femorotibial angle of  $5$ – $7^\circ$ . These results were confirmed by Ritter et al. [16] who analysed the femorotibial angle of 421 TKAs. In their study, the highest rate of aseptic loosening was found in patients with a varus malalignment (normal:  $5$ – $8^\circ$ ; varus  $\leq 4^\circ$ , valgus  $\geq 9^\circ$ ).

Mielke et al. [10] analysed the results after computer-assisted TKA (Orthopilot, Aesculap, Tuttlingen, Germany) and made a comparison with the results after a conventional replacement technique. They reported a tendency for a better femoro-tibial leg axis in computer-assisted TKA even if the differences were not significant. In a multicenter study [6] on 555 TKAs, a significantly better post-operative limb axis was found in the navigation-based group (Orthopilot-System) than in conventionally operated patients. In the study, 88% of computer-assisted cases had an alignment of the limb axis of  $\pm 3^\circ$  varus/valgus while only 72% of cases in the conventional group had a similar alignment.

We found that both modules of the VectorVision Navigation System were precise tools for accurate component orientation, even if mechanical leg alignment ( $\pm 3^\circ$ ) was slightly better in the CT-free group (97%) than in the CT-based group (92%). Further, in the CT-free group, less patients exceeded the “secure zone” of  $\pm 3^\circ$ . This might be due to the fact that the CT-free module allows for an intra-operative determination of ligament balancing and leg axis, while the CT-based software does not offer this feature.

Extra-medullary alignment guides or intra-medullary rods are used for component orientation in the conventional technique. Inherited with this technique are poten-

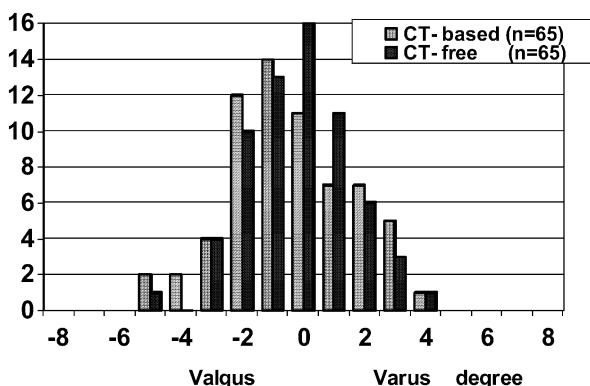


Fig. 2 Post-operative mechanical leg axis

tial errors for component malalignment [2, 7, 11, 15]. However, even when using a navigation system, malalignment of the leg axis might occur due to deviation of the saw blade in dense bone stock [13]. Other factors are variations in cementing the prosthetic components or inaccuracies in determining leg axis on post-operative weight-bearing, long-leg radiographs [18]. On the other side, the CT-free computer-assisted technique offers the advantage of intra-operative verification and correction of some of these errors.

When using navigation systems, additional operating time is needed. However, after an initial learning curve, the additional time needed for the computer-assisted surgical procedure seems to be tolerable. In the future, it might be even further reduced by an improvement of the computer-assisted workflow and the development of specific navigation-adapted instruments.

Computer-assisted TKA allows a significantly better restoration of the mechanical leg alignment and orientation of prosthetic components. The CT-based module offers the possibility of precise pre-operative planning, while the CT-free module allows intra-operative visualisation of leg axis, ligament balancing and joint kinematics. Potential benefits in long-term outcome and functional improvement require further investigation.

## References

1. Bargren JH, Blaha JD, Freeman MA (1983) Alignment in total knee arthroplasty. Correlated biomechanical and clinical observations. *Clin Orthop* 173:178–183
2. Delp SL, Stulberg SD, Davies B, Picard F, Leitner F (1998) Computer assisted knee replacement. *Clin Orthop* 354:49–56
3. Hvid I, Nielsen S (1984) Total condylar knee arthroplasty. Prosthetic component positioning and radiolucent lines. *Acta Orthop Scand* 55:160–165
4. Jeffery RS, Morris RW, Denham RA (1991) Coronal alignment after total knee replacement. *J Bone Joint Surg [Br]* 73:709–714
5. Jenny JY, Boeri C (2001) [Navigated implantation of total knee endoprostheses—a comparative study with conventional instrumentation]. *Z Orthop Ihre Grenzgeb* 139:117–119
6. Jenny JY, Mielke RK, Kohler S, Kiefer H, Konermann K, Boeri C, Clemens U, Ratayski H (2003) Total knee prosthesis implantation with a non-image-based navigation system—a multicentric analysis. *Proceedings 70th Annual Meeting AAOS:96*
7. Laskin RS (2003) Instrumentation pitfalls: You just can't go on autopilot! *J Arthroplasty* 18 [Suppl 1]:18–22
8. Lotke PA, Ecker ML (1977) Influence of positioning of prosthesis in total knee replacement. *J Bone Joint Surg [Am]* 59:77–79
9. Mahaluxmivalla J, Bankes MJ, Nicolai P, Aldam CH, Allen PW (2001) The effect of surgeon experience on component positioning in 673 press fit condylar posterior cruciate-sacrificing total knee arthroplasties. *J Arthroplasty* 16:635–640
10. Mielke RK, Clemens U, Jens JH, Kershally S (2001) [Navigation in knee endoprosthesis implantation—preliminary experiences and prospective comparative study with conventional implantation technique]. *Z Orthop Ihre Grenzgeb* 139:109–116
11. Novotny J, Gonzalez MH, Amirouche FM, Li YC (2001) Geometric analysis of potential error in using femoral intramedullary guides in total knee arthroplasty. *J Arthroplasty* 16:641–647
12. Petersen TL, Engh GA (1988) Radiographic assessment of knee alignment after total knee arthroplasty. *J Arthroplasty* 3:67–72
13. Plaskos C, Hodgson AJ, Inkpen K, McGraw RW (2002) Bone cutting errors in total knee arthroplasty. *J Arthroplasty* 17:698–705
14. Rand JA, Coventry MB (1988) Ten-year evaluation of geometric total knee arthroplasty. *Clin Orthop* 232:168–173
15. Reed SC, Gollish J (1997) The accuracy of femoral intramedullary guides in total knee arthroplasty. *J Arthroplasty* 12:677–682
16. Ritter MA, Faris PM, Keating EM, Meding JB (1994) Postoperative alignment of total knee replacement. Its effect on survival. *Clin Orthop* 299:153–156
17. Robertsson O, Knutson K, Lewold S, Lidgren L (2001) The Swedish Knee Arthroplasty Register 1975–1997: an update with special emphasis on 41,223 knees operated on in 1988–1997. *Acta Orthop Scand* 72:503–513
18. Swanson KE, Stocks GW, Warren PD, Hazel MR, Janssen HF (2000) Does axial limb rotation affect the alignment measurements in deformed limbs? *Clin Orthop* 371:246–252