

## Tissue Localization of Complement Component 3 Receptor-Bearing Cells in Lymphoid Tissue After Injection with Complete Freund Adjuvant

HARUE OKUYAMA,<sup>1\*</sup> SEIICHI KOBAYASHI,<sup>1</sup> MASAKI FUJITA,<sup>2</sup> RYOJI YASUMIZU,<sup>2</sup> AND KAZUO MORIKAWA<sup>2</sup>

*Sections of Cellular Immunology<sup>1</sup> and Pathology,<sup>2</sup> Institute of Immunological Science, Hokkaido University, Sapporo, Japan*

Received 25 March 1982/Accepted 29 June 1982

Localizations of complement component 3 (C3) receptor (C3R)-bearing cells in lymph nodes obtained from normal guinea pigs or from guinea pigs inoculated with complete Freund adjuvant were examined by staining with fluorescein-labeled anti-guinea pig C3 antibody after treatment with aggregated rabbit immunoglobulin M bound with guinea pig complement. In normal lymph nodes, a small number of C3R-positive cells were observed in the cortical and medullary areas. Non-granulomatous lymph nodes from complete Freund adjuvant-inoculated animals showed a number of C3R-positive lymphocytes in a mantle zone of the secondary follicles between the follicles and medullary cords, whereas in the paracortical areas and germinal centers, only a few positive cells were scattered. Long-lasting existence of positive cells was seen in the epithelioid cell granuloma, although the staining patterns were different from those of the lymphocytes. The appearance of a number of C3R-bearing lymphocytes in lymph nodes from complete Freund adjuvant-inoculated animals might be an expression of adjuvant activity.

A number of studies have revealed the presence of a receptor for complement component 3 (C3) on the cell surfaces of B-lymphocytes and macrophages. It has been suggested that C3 receptor (C3R)-bearing lymphocytes contribute to antibody production (4, 14, 20-22). Moreover, C3R on macrophages has been known to play an important role in the phagocytosis of complement-attached antigens (11, 12) and in other functions (27, 32). Complete Freund adjuvant (CFA), the most common adjuvant substance, develops epithelioid granuloma in the regional lymph nodes, accompanied by marked enhancement of antibody formation. It is generally accepted that epithelioid cells are derived from macrophages, but the existence of C3R on epithelioid cells is obscure. It is of interest, therefore, to determine the localization and population of C3R-bearing cells within lymph nodes stimulated with adjuvant substances.

In the present study, receptors for C3 were detected by staining lymph node tissues with fluorescein-labeled anti-guinea pig C3 antibody after combining the tissue with aggregated immunoglobulin M (IgM) and complement complex. Lymph nodes from guinea pigs inoculated with CFA revealed a number of C3R-bearing lymphocytes in the true cortical and medullary

areas, but as the nodes were replaced by the granulomatous lesions, these cells decreased in number. The cells which constituted epithelioid granulomatous lesions also showed the presence of C3R but with different staining patterns.

### MATERIALS AND METHODS

**Animals.** Strain 13 guinea pigs weighing 500 to 800 g each and bred in our animal facility by one generation expansion of breeding pairs purchased from Nisseiken, Tokyo, Japan, were used.

**Preparation of granulomatous tissue.** Guinea pigs were injected with 0.2 ml of a water-in-oil emulsion of CFA (H37Ra; Difco Laboratories, Detroit, Mich.) in the left hind footpad for primary granuloma production. For secondary granuloma production, the same emulsions were reinjected into the right footpad of the animals 4 weeks after the primary injection. After 1 to 5 weeks, the popliteal lymph nodes were excised and cut into two parts. Half of the lymph nodes were fixed with periodate-lysine-paraformaldehyde fixative (18) overnight at 4°C. After washing with 0.1 M cacodylate buffer overnight at 4°C and changing the buffer solution twice, the specimen was dehydrated in a graded solution made up of 70 to 100% ethanol, embedded into JB-4 methacrylate, and cut into 2- $\mu$ m-thick sections with a Sorvall JB-4 microtome. The other half of the lymph nodes were immersed and stirred in phosphate-buffered saline (PBS) for 1 h at 4°C to remove serum components within the tissues. The specimen

TABLE 1. Specificity of staining for C3R detection

Incubation <sup>a</sup>	Fluorescent antibody <sup>b</sup>	Guinea pig lymph node tissue
AggrRIgM-Cfr	FITC- $\alpha$ GPC3 (goat) <sup>c</sup>	+
AggrRIgM-Ci	FITC- $\alpha$ GPC3 (goat)	-
AggrRIgM-Cfr + 0.01 M EDTA	FITC- $\alpha$ GPC3 (goat)	-
AggrRIgM	FITC- $\alpha$ GPC3 (goat)	-
HBSS	FITC- $\alpha$ GPC3 (goat)	-
AggrRIgM	$\alpha$ RIgM (goat) + FITC- $\alpha$ IgG (rabbit) <sup>d</sup>	-

<sup>a</sup> Cfr, Fresh guinea pig complement complex; Ci, heat-inactivated guinea pig complement complex; HBSS, Hanks balanced salt solution.

<sup>b</sup> FITC-labeled antibody.

<sup>c</sup> FITC-labeled goat anti-guinea pig C3.

<sup>d</sup> Goat anti-rabbit IgM antiserum plus FITC-labeled rabbit anti-goat IgG.

was then embedded in Ames OCT compound (Ames Co., Div. Miles Laboratories, Inc., Elkhart, Ind.), frozen with dry ice-acetone solution, and cut into 10- $\mu$ m sections in a cryotome.

**Preparation of immune complex.** Rabbit IgM solution (1%) dissolved in borate-buffered saline solution (pH 8.0) was heated at 63°C for 30 min to obtain aggregates. This solution was fractionated through a Sepharose 4B column into aggregated rabbit IgM (AggrRIgM) and nonaggregated rabbit IgM. AggrRIgM solution at a concentration of 2 mg/ml was mixed with an equal volume of 20% fresh guinea pig serum (final concentrations, 1 mg/ml and 10%, respectively) and incubated at 37°C for 10 min in a water bath to make AggrRIgM-complement complex. For control staining, AggrRIgM was treated with heat-inactivated guinea pig serum.

**Reagents.** Fluorescein isothiocyanate (FITC)-labeled goat anti-guinea pig C3 IgG (FITC- $\alpha$ GPC3) was obtained from Cappel Laboratories, Downingtown, Pa. (lot 15200). This solution was used at a 1:30 dilution for staining of C3 after absorbing with normal rabbit liver powder. Goat anti-rabbit IgM (lot 137392) and FITC-labeled rabbit anti-goat IgG (lot 14438) were also obtained from Cappel Laboratories.

**Histological staining of JB-4 sections.** From JB-4 methacrylate embedding blocks, three serial sections were made. The first section was stained with Carazzi hematoxylin solution for 2 h at room temperature, followed by staining with 0.25% eosin Y water solution for 10 min at room temperature. The second section was stained with Giemsa solution at a 1:50 dilution (pH 7.2) for 90 min at 37°C. The last section was stained for acid phosphatase by the method of Burstone (2). According to this method, the section was immersed in a substrate solution containing Naphthol AS-BI phosphate (Sigma Chemical Co., St. Louis, Mo.) and Fast Garnet GBC salt (Sigma) for 4 h at 37°C, after which the nucleus was stained with hematoxylin.

**Detection of complement receptors on tissue sections.** The cryotome sections of the frozen tissues were rinsed twice for 10 min each with changes of PBS at 4°C to remove the OCT embedding material. The tissues were then covered with AggrRIgM-complement complex solution for 30 min at room temperature in a moisture box. After washing with PBS three times, the tissues were fixed with periodate-lysine-paraformaldehyde fixative for 30 min at 4°C. The

fixatives were then removed sufficiently from the tissues by immersing them twice in 0.1 M cacodylate buffer solution (pH 7.2), at 4°C and then in PBS once, each time for 10 min. The tissue sections were covered with FITC- $\alpha$ GPC3 solution for 30 min at room temperature, followed by washing twice with PBS at 4°C. After sealing in phosphate-buffered glycerine, the sections were examined under a fluorescence microscope.

**Verifying the specificity of staining for complement receptor.** To verify the specificity of staining, several control stainings were made as follows (Table 1). The sections were incubated with AggrRIgM-heat-inactivated guinea pig complement complex, AggrRIgM-complement complex in 0.01 M EDTA solution, AggrRIgM, and Hanks balanced salt solution. After these incubations, the sections were stained with FITC- $\alpha$ GPC3. These stainings showed no positive results. Lastly, after being treated with AggrRIgM followed by goat anti-rabbit IgM, the sections were stained with FITC-labeled anti-goat IgG; however, they showed no positive results. The results indicated that there was neither nonspecific staining with FITC- $\alpha$ GPC3 solution nor binding of AggrRIgM with tissue. It was concluded that a localization of C3 attached to C3R was demonstrated by the staining sites. Almost all of the cells appeared to have been stained on the cell surface, which probably indicated cell membrane staining.

## RESULTS

**Lymph nodes from normal animals.** Mandibular lymph nodes from normal guinea pigs were examined for C3R-bearing cells (Table 2). In some of the lymph nodes, small collections of stained cells were found in the cortical areas and in the medullary cords, but in most of them, only a small number of positive cells were seen scattered in these areas. There were no C3R-bearing cells in the germinal centers or the paracortical areas. Macrophages within the sinuses were stained weakly and showed up as dotted lines along the cytoplasmic rims.

**Non-granulomatous lymph nodes from CFA-inoculated animals.** The mandibular lymph nodes from guinea pigs inoculated with CFA in the

TABLE 2. C3R-bearing cells on granulomatous and non-granulomatous lymph nodes

Lymph nodes	C3R-bearing cells at indicated time (weeks) after following inoculation <sup>a</sup> :							
	Primary				Secondary			None
	1	2	3	5	1	2	5	
Regional granulomatous								
Inside granuloma area	+	++	++	+	++	+	±	
Outside granuloma area	+++	++	+	±	++++	++	+	
Non-granulomatous	++	+±	+±	+	++++	++++	+	
Normal								+ ~ +±

<sup>a</sup> In each experiment, three or more animals were examined. Results are expressed on a scale of - to +++++, according to the number of positive cells and intensity of brightness by immunofluorescent staining with AggrR1gM-fresh guinea pig complement complex and FITC-labeled anti-guinea pig C3 antibody.

footpads were excised and stained for C3R (Table 2). Many brightly stained cells were seen diffusely or in a mass in the mantle zone of the secondary follicles of the cortex (Fig. 1). In the medullary cord and the cortico-medullary junction areas, a number of stained cells were also observed. These positive cells were found in lymph nodes obtained 1 or 2 weeks after reinoculation with CFA. On the other hand, most of the germinal centers contained no positive cells except for a small number which were mainly situated in the periphery of the germinal centers. In the paracortical areas, there were a small number of scattered cells which stained. These brightly stained cells were determined, from their sizes and localization, to be B-lymphocytes.

**Regional lymph nodes from CFA-inoculated animals.** (i) **Primary inoculation.** One week after inoculation, small granulomatous lesions were distributed randomly in the whole parenchyma of the lymph nodes. The paracortical areas were enlarged, and the medullary cords were thickened. Only a few secondary follicles were observed to remain. At 2 to 3 weeks later, the granulomatous lesions occupied one-half to two-thirds of the areas of the markedly enlarged lymph nodes. The follicular and medullary structures disappeared completely, and the lymphocytes between the lesions were observed to decrease in number. Toward 5 weeks, the granulomatous changes entered a recovery stage and were replaced with an increasing number of lymphocytes, although the follicular and medullary cord structures were not reconstructed yet.

At 1 week, the C3R-bearing cells which were stained brilliantly were found in moderate numbers around the germinal centers and in many numbers in the medullary cords (Table 2). These positive cells decreased at 2 and 3 weeks inversely with development of the granulomatous lesions. In these lymph nodes, the C3R-positive cells remained in small clusters between the

granulomatous lesions. The lymph nodes at 5 weeks showed no or only a small number of brightly stained cells, although the number of lymphocytes increased between the lesions. Some sinuses were infiltrated with many macrophages which were stained in a way similar to the dotted line of the cytoplasmic rims observed in normal lymph nodes. However, in most of the lymph nodes which contained many brightly stained cells, the stained macrophages could not be recognized because the lymphocytes were stained so intensely that the weaker staining of macrophages was hidden.

The cells which constituted the granulomatous lesions were stained in a way similar to the dotted line of the cell surface and increased in number at 2 to 3 weeks (Fig. 2). The granulomatous lesions consisted mainly of epithelioid cells.

(ii) **Secondary inoculation.** At 1 week after the secondary CFA inoculation, the granulomatous lesions occupied almost one-half to two-thirds of the areas of the enlarged lymph nodes. Some follicular structures between the lesions and some densely packed lymphocytes were apparent. After 2 weeks, the lesions increased in size and fused with each other to make large granulomatous areas. The follicular and medullary cord structures became obscure, and the number of lymphocytes decreased. At 5 weeks, the peripheral area of the lymph nodes, including the peripheral sinuses, showed granuloma formation, whereas enlarged paracortical and medullary areas were replaced with lymphocytes, although the follicular structures still did not reappear.

C3R-bearing cells at 1 week were observed between the granulomatous lesions and in the medullary areas in great numbers, but there were only a few positive cells in the germinal centers (Fig. 3). These brightly stained cells decreased in number after 2 weeks, although small collections of positive cells still remained around the lesions.

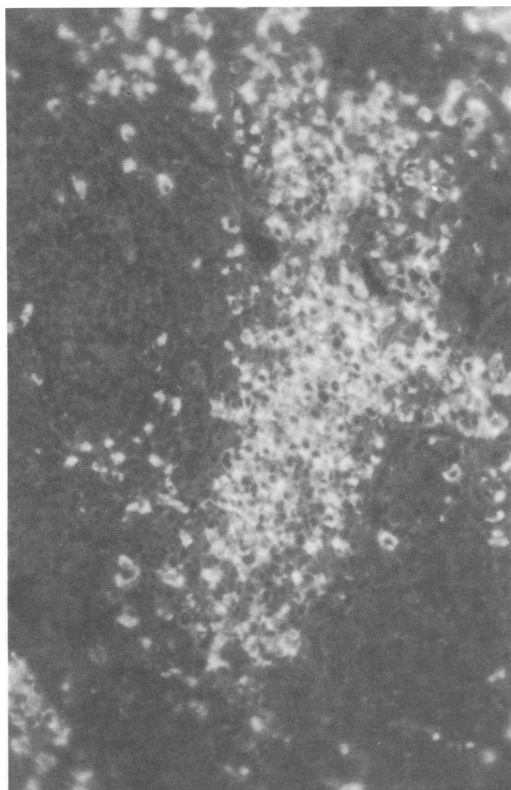


FIG. 1. Non-granulomatous mandibular lymph node from a guinea pig at 2 weeks after CFA secondary inoculation into the footpads. The frozen section was treated with AggrRIgM-guinea pig complement complex and then stained with FITC- $\alpha$ GPC3 IgG. The mantle zone of the secondary follicles shows a number of brightly stained lymphocytes, and individual cells appear to be surrounded by a ring of fluorescence. In the germinal center, there is a small number of fluorescence-positive cells. Paracortical area (right lower corner) shows no positively stained cells. Magnification,  $\times 250$ .

Granulomatous areas at 1 week showed the same dotted staining patterns as those at 2 or 3 weeks in the primary lesions and almost disappeared at 5 weeks (Fig. 4).

#### DISCUSSION

Many workers have reported that C3R on B-cell and macrophage membrane surfaces participates in immune initiation and modulation of immune responses (29). C3R-bearing lymphocytes are small B-cells (20) which also carry surface immunoglobulin (26, 28). It has been suggested that complement receptor-bearing lymphocytes contribute to antibody production (4, 14, 20), cooperation between T- and B-lymphocytes (21), and production of migration inhibition factor when stimulated by lipopoly-

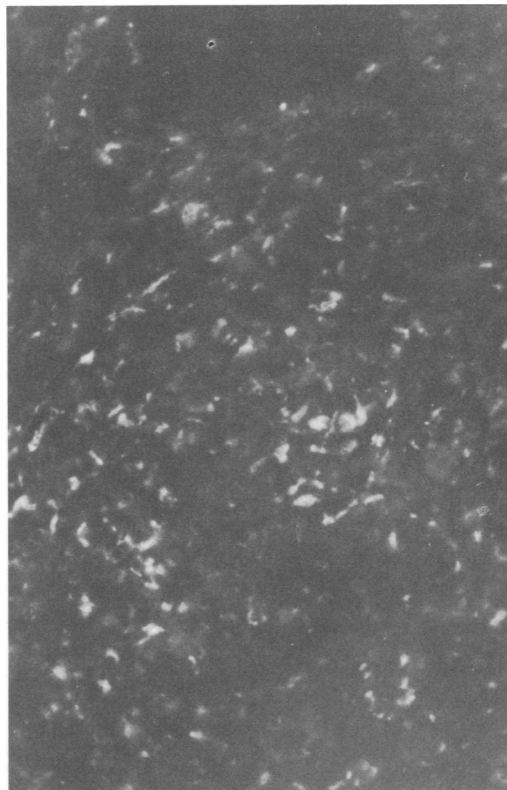


FIG. 2. Granulomatous lymph node from a guinea pig 2 weeks after CFA primary inoculation into the footpads. The staining method was the same as that described in the legend to Fig. 1. Staining figure shows scattered dots or dots arranged in a short line all over the granulomatous tissues. Adjoining section of this granulomatous tissue is stained by hematoxylin-eosin, which shows epithelioid cell granuloma. Magnification,  $\times 250$ .

saccharide or tuberculin (3). In addition, Koopman et al. (13) have showed that C3R bound with the receptor on spleen cells triggers the cells to release macrophage chemotactic factors.

On the other hand, functions of C3R on macrophage plasma membranes have been studied mainly in relation to phagocytic activity (12, 16). Griffin (10) and Ehlenberger and Nussenzweig (5) have reported that C3R is related to C3-coated particle binding to the macrophage surface, whereas phagocytosis is conducted through the mechanism of macrophage Fc receptor becoming bound to the IgG Fc fragment. Bianco et al. (1) have indicated that C3R on nonactivated macrophage membranes causes only the binding of complement-coated particles to the macrophage surface, but when macrophages are activated, C3R thereon mediates both the attachment and ingestion of particles.

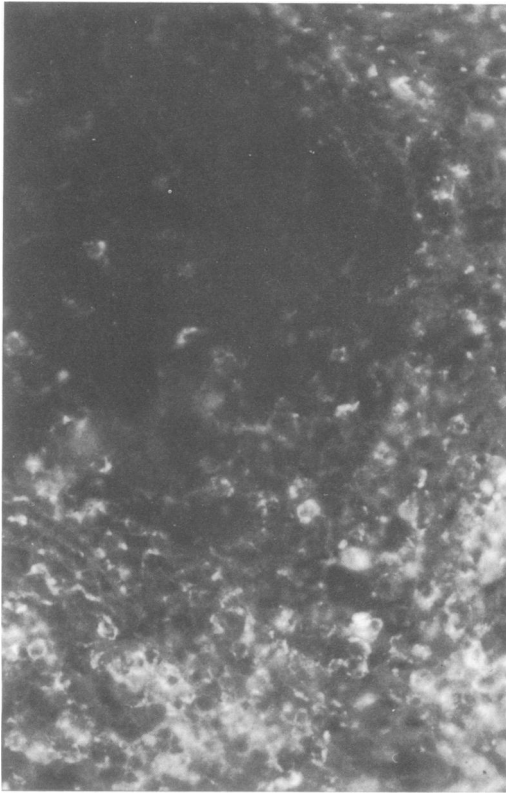


FIG. 3. Granulomatous lymph node from a guinea pig 1 week after CFA secondary inoculation into the footpads. The staining method was the same as that described in the legend to Fig. 1. The secondary follicle (left upper corner) contains only a few stained cells and is surrounded by brightly or weakly stained cells, as seen in the non-granulomatous lymph nodes. Magnification,  $\times 250$ .

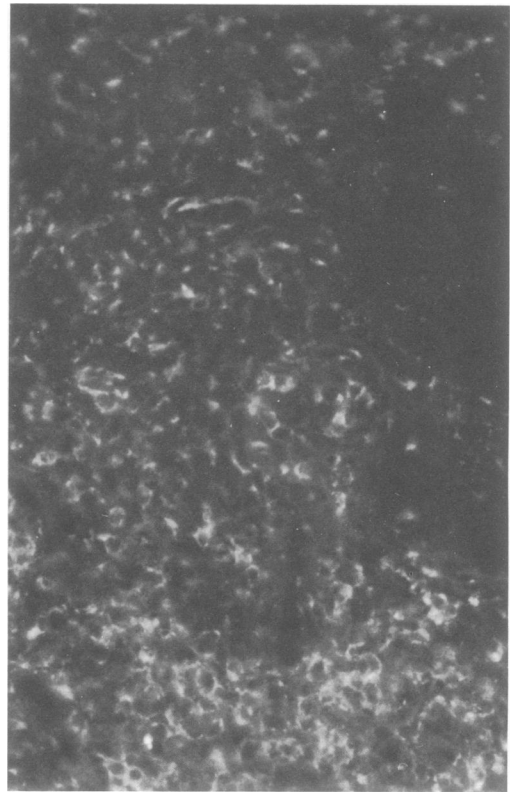


FIG. 4. Granulomatous lymph node from a guinea pig 2 weeks after CFA secondary inoculation. The staining method was the same as that described in the legend to Fig. 1. The granulomatous tissue (upper half) shows the dotted line staining figures and is surrounded by many brightly stained lymphocytes. This area consisted mainly of epithelioid cells. Magnification,  $\times 200$ .

In other studies, Schorlemmer et al. (27) and Riches and Stanworth (23) have showed that guinea pig C3b in the fluid phase triggers the release of lysosomal enzymes from mouse macrophages *in vitro*, and van Furth and Leijh (32) have reported that the Fc fragment of IgG and complement component C3b cause the intracellular killing of bacteria by macrophages via an attachment of Fc and C3b to macrophage membrane receptors.

As the lymph nodes are the major immune response environment for humoral and cell-mediated immunity and C3R-bearing B-cells and macrophages have many relations to immune responses, as mentioned above, it is of interest to determine what kinds of cell species bear C3R, where these cells localize, and how many of their populations appear in the adjuvant-stimulated lymph nodes as compared with normal lymph nodes. Linder et al. (15) have demonstrated the presence of C3 on frozen sections by

the immunofluorescent-antibody method, using anti-human C3 serum after incubation of the tissue sections with normal human sera, and Ross and Polley have (25) demonstrated the presence of complement receptors in B-cells, using soluble complement fragments and the indirect method of immunofluorescence. In the present experiment, we showed also that guinea pig complement combined with cell surface C3R could be detected by FITC-labeled anti-guinea pig C3 antibodies.

In the present experiment, normal guinea pig lymph nodes showed only a small number of positive cells in the true cortex and in the medullary cords. The cells within the sinuses were also stained, but their staining patterns were different from those of the cells in the cortical and medullary cords. The former were stained intensely or faintly as a dotted line on the cell surface, and the latter were small and stained brightly along the whole rim of the cell

membrane. From the shape, size, and localization, we postulated that the cells within the sinuses are macrophages and the cells in the cortical and medullary cords are B-lymphocytes.

By the method of EAC (erythrocyte coated with antibodies and C3) rosette formation, it was shown that complement receptors were present in the germinal centers, mantle zones, primary follicles, and medullary cords (31), but they were not detected in the thymus-dependent areas in human, mouse, rabbit, rat, or guinea pig lymphoid tissues (3, 6, 27, 30, 31). Using anti-Gerdes and Stein (7) have also demonstrated the presence of C3R in the germinal center and follicular mantle zone and a significant number of these cells in the interfollicular zone, but Meijer and Lindeman (19) have found that some germinal centers fail to bind EAC. The mandibular lymph nodes, which are located far from the injected sites of the CFA-inoculated animals used in the present experiment, showed no granulomatous lesions but contained many intensely stained C3R cells in the true cortex, including the mantle zone of secondary lymphoid follicles and the medullary areas, whereas in the germinal center and paracortical area, only a small number of scattered positive cells were seen. Our failure to demonstrate the presence of C3R in the germinal centers is not yet explained.

Positively stained lymphocytes were seen in the lymphoid tissues between epithelioid granulomatous lesions of the regional lymph nodes and in the true cortex and medullary area of the non-granulomatous lymph nodes located far from the injected sites at 1 and 2 weeks after primary and secondary CFA inoculations. This result suggests that a marked increase of C3R-bearing lymphocytes occurred in the lymph nodes by adjuvant inoculation, whether the lymph nodes were located regionally or far from the injected sites. These cells are probably responsible for adjuvant activity of CFA, such as enhancement of antibody formation or memory cell formation, as already reported (4, 14, 15, 20). Furthermore, since C3R-bearing B-lymphocytes are known to release lymphokine when stimulated by tuberculin (20) or C3 (13), the local accumulation of macrophages is considered to be due in part to the lymphokine released from these lymphocytes. Consequently, granuloma formation might be accelerated.

Stained macrophages in the sinuses were detected only occasionally in lymph nodes in which the lymphocytes were relatively faintly stained, because in the majority of the examined lymph nodes the faint staining of macrophages seemed to be hidden by the intense staining of the lymphocytes in the medullary cord. At 3

weeks after the primary inoculation and 5 weeks after the secondary inoculation, granulomatous lesions disappeared gradually and were replaced by an increasing number of lymphocytes. However, of the lymphocytes which appeared during this period, only a small number of C3R-bearing cells were observed. This decrease of C3R-bearing cells might be due to the disappearance of immunogenic or stimulatory substances of adjuvant from the lymph nodes.

Mariano et al. (17) have reported that epithelioid cells developing on cover slips which were inserted into subcutaneous tissue lost Fc receptors but continue to bind EAC. Using EA or EAC, Ridley et al. (24) reported that the skin lesions of tuberculoid leprosy bound EAC but lost the capacity to bind EA, in contrast to their activity in lepromatous leprosy, in which they bind only EA. In the present experiment, the granulomatous lesions consisting mainly of epithelioid cells showed elongated cells positively stained as scattered dots or a dotted line along the cell membranes. This staining pattern resembles that of the macrophages in the sinuses. However, C3R-bearing cells in primary granuloma at 5 weeks and secondary granuloma at 2 weeks or more decreased or lost their C3R staining ability. Griffin (9) has showed that mouse peritoneal macrophages treated with lymphokines enhance the ability to phagocytize complement-coated particles through their C3 receptors. At a later stage of CFA inoculation, lymphokine production in granulomatous lesions was considered to diminish as antigenic stimulus disappeared. Thus, lymphokine depletion and the disappearance of FcR on epithelioid cells, as Grecchi et al. (8) have reported, might lead to a loss in phagocytic activity of epithelioid cells. However, in the present study, C3R was maintained on the epithelioid cells for some time, indicating that C3R might have some function in relation to epithelioid cells, the precise relation of which remains to be elucidated.

#### ACKNOWLEDGMENT

This work was supported in part by grants-in-aid for immunological research from the Ministry of Education, Science and Culture, Japan.

#### LITERATURE CITED

1. Bianco, C., F. M. Griffin, Jr., and S. C. Silverstein. 1975. Studies of the macrophage complement receptor. Alteration of receptor function upon macrophage activation. *J. Exp. Med.* 141:1278-1290.
2. Dannenberg, A. M., Jr., M. S. Burstone, P. C. Walter, and J. W. Kinsley. 1963. A histochemical study of phagocytic and enzymatic functions of rabbit mononuclear and polymorphonuclear exudate cells and alveolar macrophages. I. Survey and quantitation of enzymes, and states of cellular activation. *J. Cell. Biol.* 17:465-486.
3. Dukor, P., C. Bianco, and V. Nussenzweig. 1970. Tissue localization of lymphocytes bearing a membrane receptor

- for antigen-antibody-complement complexes. Proc. Natl. Acad. Sci. U.S.A. 67:991-997.
4. Dukor, P., G. Schuman, R. H. Gisler, M. Dierich, W. König, U. Hadding, and D. Bitter-Suerman. 1974. Complement-dependent B-cell activation by cobra venom factor and other mitogens? J. Exp. Med. 139:337-354.
  5. Ehlenberger, A. G., and V. Nussenzweig. 1977. The role of membrane receptors for C3b and C3d in phagocytosis. J. Exp. Med. 145:357-371.
  6. Gajl-Peczalska, K. J., A. J. Fish, H. J. Meuwissen, D. Frommel, and R. A. Good. 1969. Localization of immunological complexes fixing  $\beta$ lc(C3) in germinal centers of lymph nodes. J. Exp. Med. 130:1367-1393.
  7. Gerdes, J., and H. Stein. 1981. Human membrane-bound C3 receptors. II. Physicochemical properties of the C3b and C3d receptors isolated from tonsil cells by immunoprecipitation. Scand. J. Immunol. 13:77-86.
  8. Grecchi, R., A. M. Saliba, and M. Mariano. 1980. Morphological changes, surface receptors and phagocytic potential of fowl mononuclear phagocytes and thrombocytes in vivo and in vitro. J. Pathol. 130:23-31.
  9. Griffin, F. M., Jr. 1980. Effects of soluble immune complexes on Fc receptor- and C3b receptor-mediated phagocytosis by macrophages. J. Exp. Med. 152:905-919.
  10. Griffin, F. M., Jr. 1981. Roles of macrophage Fc and C3b receptors in phagocytosis of immunologically coated *Cryptococcus neoformans*. Proc. Natl. Acad. Sci. U.S.A. 78:3853-3857.
  11. Harrington-Fowler, L., P. M. Henson, and M. S. Wilder. 1981. Fate of *Listeria monocytogenes* in resident and activated macrophages. Infect. Immun. 33:11-16.
  12. Huber, H., M. J. Polley, W. D. Linscott, H. H. Fudenberg, and H. J. Müller-Eberhard. 1968. Human monocytes: distinct receptor sites for the third component of complement and for immunoglobulin G. Science 162:1281-1283.
  13. Koopman, W. J., A. L. Sandberg, S. M. Wahl, and S. E. Mergenhagen. 1976. Interaction of soluble C3 fragments with guinea pig lymphocytes. Comparison of effects of C3a, C3b, C3c and C3d on lymphokine production and lymphocyte proliferation. J. Immunol. 117:331-336.
  14. Levy, N. L., D. W. Scott, and R. Snyderman. 1972. Bone marrow-derived lymphoid cells (B cells): functional depletion with cobra factor and fresh serum. Science 178:866-867.
  15. Linder, E., M. Rhen, and S. Meri. 1981. An immunofluorescence assay for complement activation by the classical pathway. J. Immunol. Methods 47:49-59.
  16. Mantovani, B. 1981. Phagocytosis of immune complexes mediated by IgM and C3 receptors by macrophages from mice treated with glycogen. J. Immunol. 126:127-130.
  17. Mariano, M., T. Nikitin, and B. E. Malucelli. 1976. Immunological and non-immunological phagocytosis by inflammatory macrophages, epithelioid cells and macrophage polykaryons from foreign body granuloma. J. Pathol. 120:151-159.
  18. McLean, I. W., and P. K. Nakane. 1974. Periodate-lysine-paraformaldehyde fixative. A new fixative for immunoelectron microscopy. J. Histochem. Cytochem. 22:1077-1083.
  19. Meijer, S. J. L. M., and J. Lindeman. 1975. A modified method for tissue localization of cells bearing a complement receptor. J. Immunol. Methods 9:59-65.
  20. Nussenzweig, V. 1974. Receptors for immune complexes on lymphocytes. Adv. Immunol. 19:217-258.
  21. Pepys, M. B. 1976. Role of complement in the induction of immunological responses. Transplant. Rev. 32:93-120.
  22. Pryjma, J., and J. H. Humphrey. 1975. Prolonged C3 depletion by cobra venom factor in thymus-deprived mice and its implication for the role of C3 as an essential second signal for B-cell triggering. Immunology 28:569-576.
  23. Riches, D. W. H., and D. R. Stanworth. 1981. Studies on the possible involvement of complement component C3 in the initiation of acid hydrolase secretion by macrophages. I. Correlation between enzyme-releasing and complement-activating capacities of several secretagogues. Immunology 44:29-39.
  24. Ridley, M. J., D. S. Ridley, and J. L. Turk. 1978. Surface markers on lymphocytes and cells of the mononuclear phagocyte series in skin sections in leprosy. J. Pathol. 125:91-98.
  25. Ross, G. D., and M. J. Polley. 1975. Specificity of human lymphocyte complement receptors. J. Exp. Med. 141:1163-1180.
  26. Rutishauser, U., and G. M. Edelman. 1972. Binding of thymus- and bone marrow-derived lymphoid cells to antigen-derivatized fibers. Proc. Natl. Acad. Sci. U.S.A. 69:3774-3778.
  27. Schorlemmer, H. U., P. Davies, and A. C. Allison. 1976. Ability of activated complement components to induce lysosomal enzyme release from macrophages. Nature (London) 267:48-49.
  28. Shevach, E. M., L. Ellman, J. M. Davie, and I. Green. 1972. L2C guinea pig lymphatic leukemia: a "B" cell leukemia. Blood 39:1-12.
  29. Shevach, E. M., E. S. Jaffe, and I. Green. 1973. Receptors for complement and immunoglobulin on human and animal lymphoid cells. Transplant. Rev. 16:3-28.
  30. Silveira, N. P. A., N. F. Mendes, and M. E. A. Tolnai. 1972. Tissue localization of two populations of human lymphocytes distinguished by membrane receptors. J. Immunol. 108:1456-1460.
  31. Stein, H., U. Siemssen, and K. Lennert. 1978. Complement receptor subtypes C3b and C3d in lymphatic tissue and follicular lymphoma. Br. J. Cancer 37:520-529.
  32. van Furth, H., and P. C. J. Leijh. 1980. Regulation of intracellular killing by extracellular stimulation of the monocyte membrane, p. 441-454. In E. R. Unanue and A. S. Rosenthal (ed.), Macrophage regulation of immunity. Academic Press, Inc., New York.