



CASE REPORT

Open Access

The utility of hyperthermia for local recurrence of breast cancer

Daigo Yamamoto^{1,3*}, Toshio Inui², Yu Tsubota¹, Noriko Sueoka¹, Chizuko Yamamoto³, Kayoko Kuwana¹ and Mitsuo Yamamoto³

Abstract

Background: Hyperthermia has long been used in combination with chemotherapy or radiation therapy for the treatment of superficial malignancies, in part due to its sensitizing capabilities. Patients who suffer from superficial recurrences of breast cancer have poor clinical outcomes. Skin metastases may particularly impair the quality of life due to the physical appearance, odor and bleeding.

Case presentation: A 66-year-old woman underwent mastectomy and axillary lymph node dissection for breast cancer. Nine years post-operatively, local metastases developed in the left axillary area (measuring 5 cm in diameter). Initially the tumor did not respond to radiation therapy and chemotherapy. Therefore, we added hyperthermia combined with them. Eight weeks later, the tumor became nearly flat and the patient noted improved activity in her daily life.

Conclusion: Hyperthermia may accelerate the antitumor effects of radiation therapy and chemotherapy. This treatment provides an alternative for unresectable breast cancer skin metastases.

Keywords: Breast cancer, Skin metastasis, Hyperthermia

Background

Hyperthermia has been combined with radiotherapy in an effort to improve local control, which is essential in unresectable locally advanced breast cancer (LABC). Hyperthermia's ability to affect cells in S phase, inhibit sub-lethal damage repair, and improve oxygenation make it an attractive therapy to combine with radiation and/or chemotherapy in the hopes of synergy [1-5]. The ultimate goal of the addition of hyperthermia to treatment for LABC is improved tumor kill, which most often is assessed with the rate of clinical complete response/partial response (cCR/pPR), and if the patient undergoes surgery, pCR. In addition to the inherent biology of an individual tumor, achieving a CR with thermoradiotherapy depends on the size of the tumor, dose of radiotherapy used, and ability to adequately heat the tumor, which can be especially challenging with large burdens of unresectable disease [6].

Case presentation

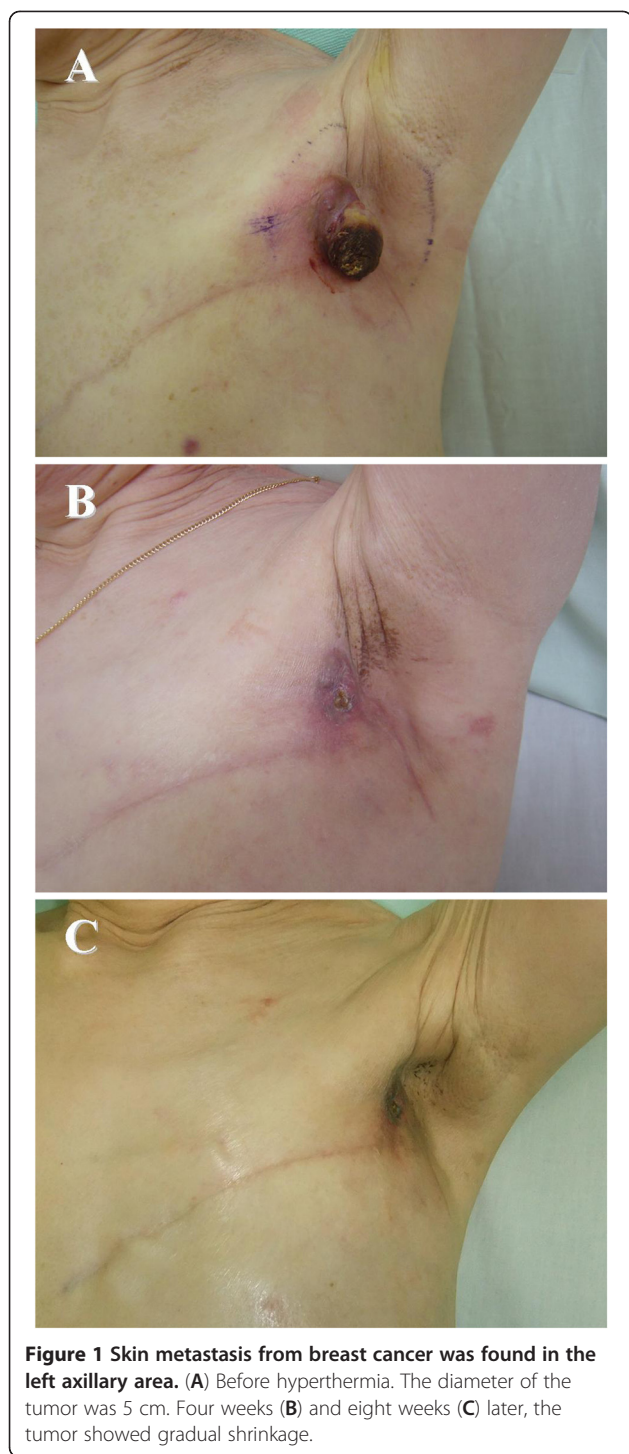
A 66-year-old woman underwent mastectomy and axillary lymph node dissection for breast cancer. The histopathological findings were papillo-tubular carcinoma with metastases in two axillary lymph nodes. IHC staining showed that estrogen receptor (ER) and progesterin receptor (PR) were positive, and Human Epidermal Growth Factor Receptor 2 (HER-2) oncoprotein was negative. As adjuvant therapy, doxorubicin (60 mg/m²) and cyclophosphamide (600 mg/m²) were administered four times and aromatase inhibitor was prescribed for five years. There was no post-mastectomy radiotherapy (PMRT). Nine years post-operatively, local metastases developed in the left axillary area. Chemotherapy (weekly paclitaxel: 80 mg/m²) and radiotherapy (total 30 Gy) were attempted, but the lesions continued to enlarge. On examination, a tumor measuring 5 cm in diameter was found in the left axillary area (Figure 1A). Therefore, we added hyperthermia combined with radiotherapy and chemotherapy. Hyperthermia was performed using a Thermotron RF-8 capacitive heating device (Yamamoto VINITA Co., Ltd., Osaka, Japan at a surface temperature of 38°C to 41°C, once a week for 50 minutes [6]. The output power ranged

* Correspondence: yamamotd@hirakata.ac.jp

¹Department of Surgery, Kansai Medical University, Hirakata, Japan

³Department of Internal Medicine, Seiko Hospital, Neyagawa, Osaka, Japan

Full list of author information is available at the end of the article



from 1,300 to 1,400 W. After four weeks, the surface of the tumor began to dissolve, then became gradually necrotic (Figure 1B). Along with a reduction of the tumor size, the foul odor disappeared. Eight weeks later, the tumor became nearly flat and the response was evaluated as a complete response (CR), according to the Response Evaluation Criteria in Solid Tumors Group criteria, and

the patient noted improved activity in her daily life (Figure 1C).

Discussion

Breast cancer is the most common neoplasm to metastasize to the skin. Skin metastases impair activities of daily life due to the physical appearance, odor and bleeding. In the present study, chemotherapy (weekly paclitaxel: 80 mg/m²) and radiotherapy (total 30 Gy) were attempted, but the lesions continued to enlarge. On examination, a tumor measuring 5 cm in diameter was found in the left axillary area (Figure 1A). Therefore, we added hyperthermia combined with the other therapies. In general, the first-line therapy for lymphadenopathy is radiotherapy in which the area was irradiated (total 30 Gy). Thus, we selected hyperthermia, as the radiotherapy (total 30 Gy) was already applied to the area of axillary lymphadenopathy. As a result, we succeeded in controlling these symptoms through the combined application of chemo-radiation therapy and hyperthermia, which resulted in a greatly improved quality of life.

Hyperthermia has been investigated in several randomized and non-randomized clinical trials for cancer therapy [7-11]. Hyperthermia can increase the therapeutic ratio by enhancing the permeability of tumor blood vessels to liposomes. In pre-clinical studies it has been demonstrated that the rate of liposomal extravasation is enhanced four- to eight-fold for temperatures in the target range of this trial [12]. In cats with soft tissue sarcomas, hyperthermia enhanced radio-labeled liposomal uptake by 4- to 16-fold compared to normothermia [13]. Hyperthermia also increases oxygen levels within the tumor, which is critical to the effectiveness of radiation and chemotherapy [14-17]. In a clinical setting, some recent studies [18,19] showed that neoadjuvant chemotherapy combined with hyperthermia is a feasible and well-tolerated treatment strategy in breast cancer patients. In this study [18], 19 of 44 patients were deemed inoperable at the initial assessment. Fourteen of these patients had inflammatory disease. Only five patients were candidates for breast-conserving surgery (BCS). Eight patients elected to have BCS, although 16 were eligible after reassessment following neoadjuvant treatment. At surgery, 32 patients (73%) were found to have axillary lymph node involvement. No patients progressed during neoadjuvant therapy. A complete pathological response was seen in four patients (9%). The combined pathological response was 60% (CR: 9%, and PR: 51%). Therefore, there is a possibility that the addition of HT to preoperative chemotherapy increases cCR and pCR rates more so than chemotherapy alone. In our previous studies, patients with pCR to chemotherapy had a favorable prognosis [20,21]. Thus, the goal of adding hyperthermia to radiotherapy and/or

chemotherapy is to increase response rates, and hopefully local control and disease-free survival.

Conclusions

In conclusion, multidisciplinary therapy, such as hyperthermia, radiotherapy and chemotherapy, may be a useful and effective method for the treatment of progressive breast cancer.

Consent

Written consent was obtained from the patient for publication of this study and the related photos.

Abbreviations

BCS: Breast-conserving surgery; cCR: Clinical complete response; CR: Complete response.

Competing interests

The authors declare that they have no competing interests.

Authors' contributions

DY, YT, NS, and KK performed chemotherapy as a team. TI and CY treated the patient using hyperthermia. DY drafted the manuscript. MY carried the data acquisition. All authors read and approved the final manuscript.

Acknowledgements

We would like to thank staff in Inui Clinic for assisting in the preparation of this manuscript.

Author details

¹Department of Surgery, Kansai Medical University, Hirakata, Japan. ²Inui Clinic, Moriguchi, Japan. ³Department of Internal Medicine, Seiko Hospital, Neyagawa, Osaka, Japan.

Received: 10 July 2012 Accepted: 21 September 2012

Published: 27 September 2012

References

1. Westra A, Dewey WC: Variation in sensitivity to heat shock during the cell-cycle of Chinese hamster cells *in vitro*. *Int J Radiat Biol Relat Stud Phys Chem Med* 1971, **19**:467-477.
2. Kampinga HH, Dikomey E: Hyperthermic radiosensitization: mode of action and clinical relevance. *Int J Radiat Biol* 2001, **77**:399-408.
3. Raaphorst GP, Ng CE, Yang DP: Thermal radiosensitization and repair inhibition in human melanoma cells: a comparison of survival and DNA double strand breaks. *Int J Hyperthermia* 1999, **15**:17-27.
4. Dewhirst MW: Concepts of oxygen transport at the microcirculatory level. *Semin Radiat Oncol* 1998, **8**:143-150.
5. Zagar TM, Oleson JR, Vujaskovic Z, Dewhirst MW, Craciunescu OI, Blackwell KL, Prosnitz LR, Jones EL: Hyperthermia for locally advanced breast cancer. *Int J Hyperthermia* 2010, **26**:618-624.
6. Uto Y, Hori H, Kubo K, Ichihashi M, Sakamoto N, Mette M, Inui T: GcMAF: our next generation immunotherapy. *Nature* 2012, **485**:S67-S70.
7. Jones EL, Oleson JR, Prosnitz LR, Samulski TV, Vujaskovic Z, Yu D, Sanders LL, Dewhirst MW: Randomized trial of hyperthermia and radiation for superficial tumors. *J Clin Oncol* 2005, **23**:3079-3085.
8. Vernon CC, Hand JW, Field SB, Machin D, Whaley JB, van der Zee J, van Putten WLJ, van Rhoon GC, van Dijk JDP, Gonzalez Gonzalez D: Radiotherapy with or without hyperthermia in the treatment of superficial localized breast cancer: Results from five randomized controlled trials. *Int J Radiat Oncol Biol Phys* 1996, **35**:731-744.
9. Lee HK, Antell AG, Perez CA, Straube WL, Ramachandran G, Myerson RJ, Emami B, Molmenti EP, Buckner A, Lockett MA: Superficial hyperthermia and irradiation for recurrent breast carcinoma of the chest wall: Prognostic factors in 196 tumors. *Int J Radiat Oncol Biol Phys* 1998, **40**:365-375.
10. Hehr T, Lamprecht U, Glocker S, Classen J, Paulsen F, Budach W, Bamberg M: Thermoradiotherapy for locally recurrent breast cancer with skin involvement. *Int J Hyperthermia* 2001, **17**:291-301.
11. Barnes JA, Dix DJ, Collins BW, Luft C, Allen JW: Expression of inducible Hsp70 enhances the proliferation of MCF-7 breast cancer cells and protects against the cytotoxic effects of hyperthermia. *Cell Stress Chaperones* 2001, **6**:316-325.
12. Kong G, Braun RD, Dewhirst MW: Hyperthermia enables tumor-specific nanoparticle delivery. Effect of particle size. *Cancer Res* 2000, **60**:4440-4445.
13. Matteucci ML, Anyarambhatla G, Rosner G, Azuma C, Fisher PE, Dewhirst MW, Needham D, Thrall DE: Hyperthermia increases accumulation of technetium-99 m-labeled liposomes in feline sarcomas. *Clin Cancer Res* 2000, **6**:3748-3755.
14. Griffin RJ, Okajima K, Barrios B, Song CW: Mild temperature hyperthermia combined with carbogen breathing increases tumor partial pressure of oxygen (pO₂) and radio-sensitivity. *Cancer Res* 1996, **56**:5590-5593.
15. Song CW, Shakil A, Osborn JL, Iwata K: Tumour oxygenation is increased by hyperthermia at mild temperatures. *Int J Hyperthermia* 1996, **12**:367-373.
16. Vujaskovic Z, Poulson JM, Gaskin AA, Thrall DE, Page RL, Charles HC, MacFall JR, Brizel DM, Meyer RE, Prescott DM: Temperature-dependent changes in physiologic parameters of spontaneous canine soft tissue sarcomas after combined radiotherapy and hyperthermia treatment. *Int J Radiat Oncol Biol Phys* 2000, **46**:179-185.
17. Thrall DE, Larue SM, Pruitt AF, Case B, Dewhirst MW: Changes in tumour oxygenation during fractionated hyperthermia and radiation therapy in spontaneous canine sarcomas. *Int J Hyperthermia* 2006, **22**:365-373.
18. Vujaskovic Z, Kim DW, Jones E, Lan L, McCall L, Dewhirst MW, Craciunescu O, Stauffer P, Liotcheva V, Betof A, Blackwell K: A phase I/II study of neoadjuvant liposomal doxorubicin, paclitaxel, and hyperthermia in locally advanced breast cancer. *Int J Hyperthermia* 2010, **26**:514-521.
19. Craciunescu OI, Thrall DE, Vujaskovic Z, Dewhirst MW: Magnetic resonance imaging: a potential tool in assessing the addition of hyperthermia to neoadjuvant therapy in patients with locally advanced breast cancer. *Int J Hyperthermia* 2010, **26**:625-637.
20. Iwase S, Yamamoto D, Kuroda Y, Kawaguchi T, Kitamura K, Odagiri H, Teramoto S, Akazawa K, Nagumo Y: Phase II trial of preoperative chemotherapy for breast cancer: Japan Breast Cancer Research Network (JBCRN)-02 trial. *Anticancer Res* 2011, **31**:1483-1487.
21. Yamamoto D, Iwase S, Yoshida H, Kuroda Y, Yamamoto C, Kitamura K, Odagiri H, Nagumo Y: Efficacy of meloxicam in combination with preoperative chemotherapy for breast cancer - Japan Breast Cancer Research Network (JBCRN) 02-1 trial. *Anticancer Res* 2011, **31**:3567-3571.

doi:10.1186/1477-7819-10-201

Cite this article as: Yamamoto et al.: The utility of hyperthermia for local recurrence of breast cancer. *World Journal of Surgical Oncology* 2012 **10**:201.

Submit your next manuscript to BioMed Central and take full advantage of:

- Convenient online submission
- Thorough peer review
- No space constraints or color figure charges
- Immediate publication on acceptance
- Inclusion in PubMed, CAS, Scopus and Google Scholar
- Research which is freely available for redistribution

Submit your manuscript at
www.biomedcentral.com/submit

