

Penile lengthening procedure with V-Y advancement flap and an interposing silicone sheath: A novel methodology

Srinivas B.V., Vasan S.S., Sajid Mohammed¹

Departments of Andrology and ¹Radiodiagnosis, Ankur Health Care Private Limited, Bengaluru, India

ABSTRACT

Surgery to augment penile length has become increasingly common. Lack of standardization of this controversial procedure has led to a wide variety of poorly documented surgical techniques, with unconvincing results. The most commonly used technique involves release of the suspensory ligament, with an advancement of an infrapubic skin flap onto the penis via a V-Y plasty. This technique has a major drawback of the possibility of reattachment of the penis to the pubis. We describe a new technique of interposing a silicone sheath along with V-Y advancement flap that overrides this drawback and minimizes the loss of the gained length.

Key words: Penile length, silicone sheath, suspensory ligament, symphysis pubis, V-Y plasty

INTRODUCTION

Penile lengthening is performed for various reasons, some cosmetic and some medical.^[1] In the United States, an estimated 10,000 men have undergone penile surgery for cosmetic reasons in the last decade.^[2] Various surgical approaches have been described to augment both the length and the girth. The technique most commonly used for penile lengthening is the release of the suspensory ligament in combination with an inverted V-Y skin plasty. However, the drawback of this procedure is the possibility of reattachment of the penis to the pubis.^[3] In this work, we describe refinements to this technique by interposing a silicone sheath between the released suspensory ligament and the pubis.

For correspondence: Dr. Srinivas B. V.,
Department of Andrology, Ankur Health Care Private Limited,
No. 55, 20th Main, 1st Block, Rajajinagar,
Bengaluru - 560 010, India.
E-mail: drsrinivasbv@hotmail.com

Access this article online

Quick Response Code:



Website:

www.indianjurol.com

DOI:

10.4103/0970-1591.102722

CASE REPORT

We report the case of a 30-year-old male who presented with short penile length. On physical examination, he had normal secondary sex characters, clinically normal testes, and a flaccid outstretched penile length of 3 cm, from the bony pelvis to the tip of the glans [Figure 1a]. Erection was induced by intracorporeal injection of prostaglandin E1 and the erect length was 4.5 cm. The angle between the penis and the trunk upon erection was around 100 degrees. A written consent was signed by the patient for undergoing the procedure after explaining the consequences. The procedure was carried out as per the standard technique of V-Y Advancement Flap combined with severing of the suspensory ligament described by Osama Shaer^[4] [Figure 1b]. After the deep layer of the suspensory ligament was resected, the resulting gap between the base of the penis and the symphysis pubis was interposed with a silicone sheath [Figure 1c]. The silicone sheath was a torn-out sleeve from Shah penile prosthesis [Figure 2]. The Shah penile prosthesis is a solid silicone, semi-rigid, flexible implant with the unique features of two removable sleeves to adjust the diameter. This silicone sleeve was used to interpose between symphysis pubis and the released suspensory ligament. This maneuver filled up the gap and the deeper part of the corpora cavernosa was sutured to the cranial part of the flap with braided polyglactin (Vicryl) 3-0, thus elevating the corpora, adding to the length gain as well and closing the gap with braided polyglactin (Vicryl) 3-0. A Penrose drain was left in the remaining tight space. The caudal lip of the penopubic incision was sutured to itself in the midline with braided

polyglactin (Vicryl) 3-0 along the vertical axis of the penis. This incision was then closed in a T-shaped manner with monofilament polyamide (Ethilon) 3-0. The cranial lip of the incision was sutured to the vertically closed caudal lip. The remaining V flap (skin flap) was pushed caudally and the incision was closed. The limbs of the V were closed as a Y. A urinary catheter was inserted. The drain was removed after 48 h, and the urinary catheter was removed after five days. The final length was measured after six months which showed a length of 7 cm [Figure 1d], the same as measured intraoperatively. Main outcome measures were the maintenance of the intraoperative length gain by the

sixth month after surgery, as well as the angle between the penis and the trunk upon erection which was about 100 degrees.

DISCUSSION

The technique of release of the suspensory ligament in combination with an inverted V-Y skin plasty is the most commonly used procedure for augmentation of penile length.^[3-5] However, the length attained from this procedure is variable and controversial. The main drawback remains that the penis reverts to its original

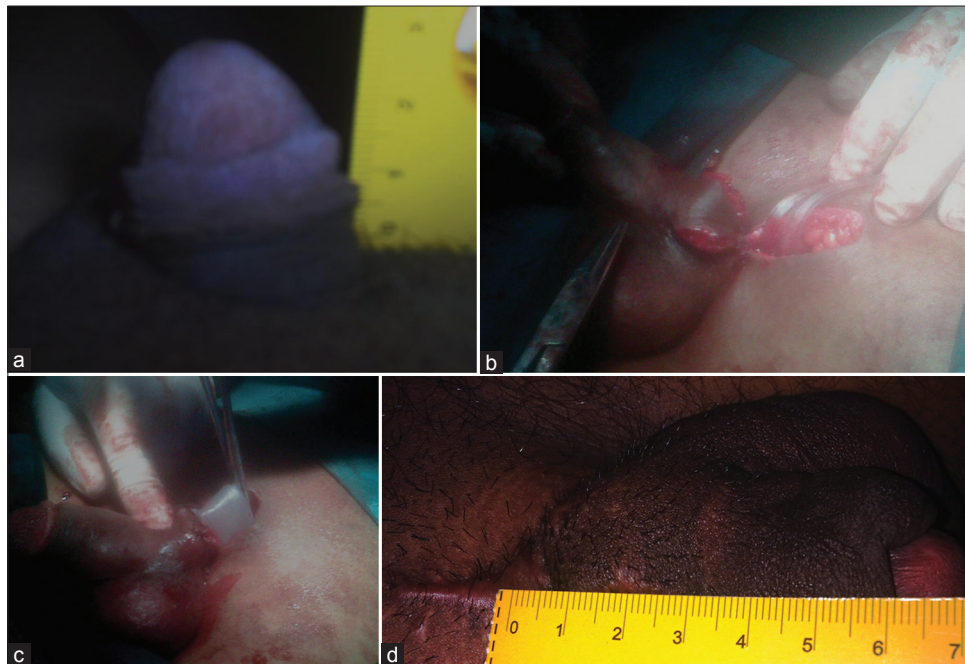


Figure 1: (a) Preoperative demonstration of short penis with length of 3 cm (b) Intraoperative demonstration of flap dissection and mobilization after release of suspensory ligament (c) Intraoperative demonstration of interposition of silicone sheath between the released suspensory ligament and the pubis (d) Postoperative demonstration of increased penile length to 7 cm

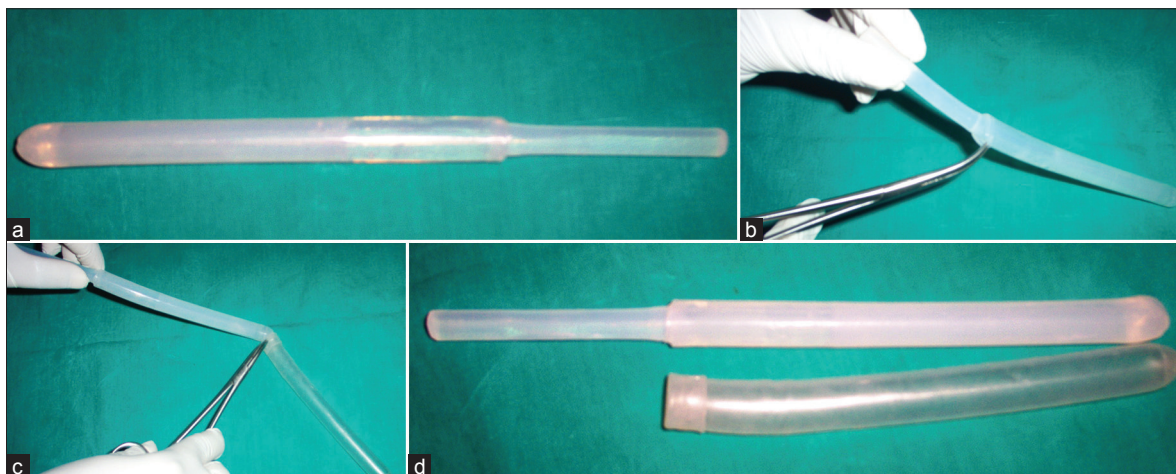


Figure 2: Demonstrating removal of the silicone sleeve from Shah penile prosthesis (a) Shah penile prosthesis without hinge (WH11) (b) Use of curved artery forceps to remove sleeve from penile prosthesis (c) Complete separation of the silicone sleeve from the prosthesis (d) Shah penile prosthesis along with the silicone sheath—sleeve removed from the prosthesis

length due to reattachment of the suspensory ligament to the pubis.^[5]

We modified this procedure to minimize the above mentioned drawback and to prevent the loss of the gained length, by interposing a silicone sheath between the pubic symphysis and the suspensory ligament. The descent of the corpora off the pubic bone creates a dead space that should be filled because the ligament can reattach and possibly reduce length gain, or can even cause penile shortening. Dermal fat grafts are occasionally used to fill the space but they have the drawback of resorption due to unreliable blood supply, and morbidity to the donor site too makes them unacceptable. Harvesting fat from remote sites through other incisions is also met with the same results. We used a silicone sheath to fill this gap without any risk of infection. The silicone sheath utilized was from a torn-out sleeve from Shah penile prosthesis which was removed during a penile prosthesis procedure. The silicone sheath was autoclaved and then used in this procedure. This maneuver not only prevents reattachment of the suspensory ligament to the pubis but also prevents the consequent loss of length gain, because the ligament is liable to contracture and, if it attaches to a raw surface, may pull the penis inwards. Another downside of severing the suspensory ligament is that it may result in a pendulous “low-hanging” penis,^[5] where the angle of erection is different from the preoperative state. In our procedure, this was avoided by suturing the deeper parts of the corpora cavernosa to the cranial part of the fat flap. We did not apply penile stretching postoperatively because the corpora are already pushed forward. The hump that occurs at

the penopubic junction upon advancement of the V-Y flap^[5] can be avoided. This hump is mostly due to advancement of a bulk of fat along with the skin. This is not the case with our technique as the fat plunges into the dead space to fill it up. There was also no evidence of infection during the entire follow-up period of six months.

To sum up, the length gain achieved is effectively maintained with this novel technique of V-Y advancement flap and interposing silicone sheath. Further modifications based on this technique may add to the durability of the length gain.

REFERENCES

1. Kabalin JN, Rosen J, Perkas I. Penile advancement and lengthening in spinal cord injury patients with retracted phallus who have failed penile prosthesis placement alone. *J Urol* 1990;144:316-8.
2. Wessells H, Lue TF, McAninch JW. Penile length in the flaccid and erect states: Guidelines for penile augmentation. *J Urol* 1996;156:995-7.
3. Johnston JH. Lengthening of the congenital or acquired small penis. *Br J Urol* 1974;46:685-7.
4. Shaeer O, Shaeer K, el-Sebaie A. Minimizing the Losses in Penile Lengthening: “V-Y Half-Skin Half-Fat Advancement Flap” and “T-Closure” Combined with Severing the Suspensory Ligament. *J Sex Med* 2006;3:155-60.
5. Gary JA. Aesthetic genital surgery. Aesthetic surgery of the male genitalia. In: Richard ME, Gary JA, editors. *Reconstructive and plastic surgery of the external genitalia. Adult and pediatric.* Philadelphia, London, Toronto, Sydney: W.B. Saunders Company; 1999. p. 460-70.

How to cite this article: Srinivas BV, Vasan SS, Mohammed S. Penile lengthening procedure with V-Y advancement flap and an interposing silicone sheath: A novel methodology. *Indian J Urol* 2012;28:340-2.

Source of Support: Nil, **Conflict of Interest:** None declared.