

NOTES

Uncoupled Relationship Between Demyelination and Primary Infection of Myelinating Cells in Theiler's Virus Encephalomyelitis

MAURO C. DAL CANTO

Department of Pathology/Neuropathology, Northwestern University Medical School, Chicago, Illinois 60611

Received 8 June 1981/Accepted 28 October 1981

Theiler's virus infection in mice produces a chronic demyelinating disease which appears to be based on an immune pathogenesis rather than on direct viral destruction of myelin-supporting cells. The purpose of the present study is to ascertain whether viral antigen is present in the cytoplasm of such cells in areas of demyelination. Because of the difficulty of identifying oligodendrocytes in tissues rich in infiltrating mononuclear cells and fixed for immunohistochemistry, I turned to a recently described form of Theiler's virus encephalomyelitis which follows inoculation with the attenuated ww strain and is characterized by extensive spinal cord remyelination by invading Schwann cells and by recurrent demyelination of Schwann cell-remyelinated axons. The unlabeled antibody peroxidase-antiperoxidase technique was employed to study whether such spinal cord Schwann cells were primarily infected by virus at the time when recurrent demyelination was occurring. Whereas other types of cells, including neurons, astrocytes, and macrophages, contained abundant viral antigen, no positive immune reaction was observed in Schwann cells. These results correlate with our previous studies which had suggested that demyelination in this viral model is not dependent on primary viral attack on myelinating cells but is probably dependent on the host immune response.

Theiler's virus (TV) encephalomyelitis is a murine model for virus-induced demyelination and viral persistence (3, 8).

Demyelinating lesions in anterior and lateral columns of spinal cord are in a strict anatomical and temporal relationship with meningeal and perivenular infiltrates of mononuclear inflammatory cells (2). This pattern is practically identical to that in experimental allergic encephalomyelitis, the prototypic model of autoimmune demyelination (1, 6). Immunosuppression of mice infected with TV significantly decreases or totally prevents demyelination, thus supporting a major role by the host immune response in the pathogenesis of myelin destruction in this model (9).

Infection by TV is, therefore, at variance with JHM virus encephalomyelitis, another important murine model of virus-induced demyelination in which oligodendrocytes are primary targets for the virus (7) and immunosuppressive therapy fails to prevent white matter lesions (12). Demyelination in the JHM virus model appears, therefore, to be dependent upon direct

viral cytopathic effect rather than on the host immune response.

It would be important to know whether primary viral infection of myelin-producing cells precedes and plays a role in the demyelinating pathology of the Theiler's model as well.

Ultrastructural identification of TV has only been reported in *in vitro* and *in vivo* systems in which virus replicated to high titers and formed cytoplasmic paracrystalline inclusions in a variety of cells, including oligodendroglia (11, 13, 14). *In vivo* visualization of TV, for example, is possible in suckling mice (11, 13). These permit, in fact, unrestricted replication of most viruses because of alterations in virus-host interactions when compared with older animals (5).

In the chronic demyelinating model, on the other hand, the small size of TV and the low central nervous system viral titers during the entire course of the infection consistently hampered efforts to identify viral inclusions in any central nervous system structure by routine transmission electron microscopy (2).

Recently, we were able to identify TV in both

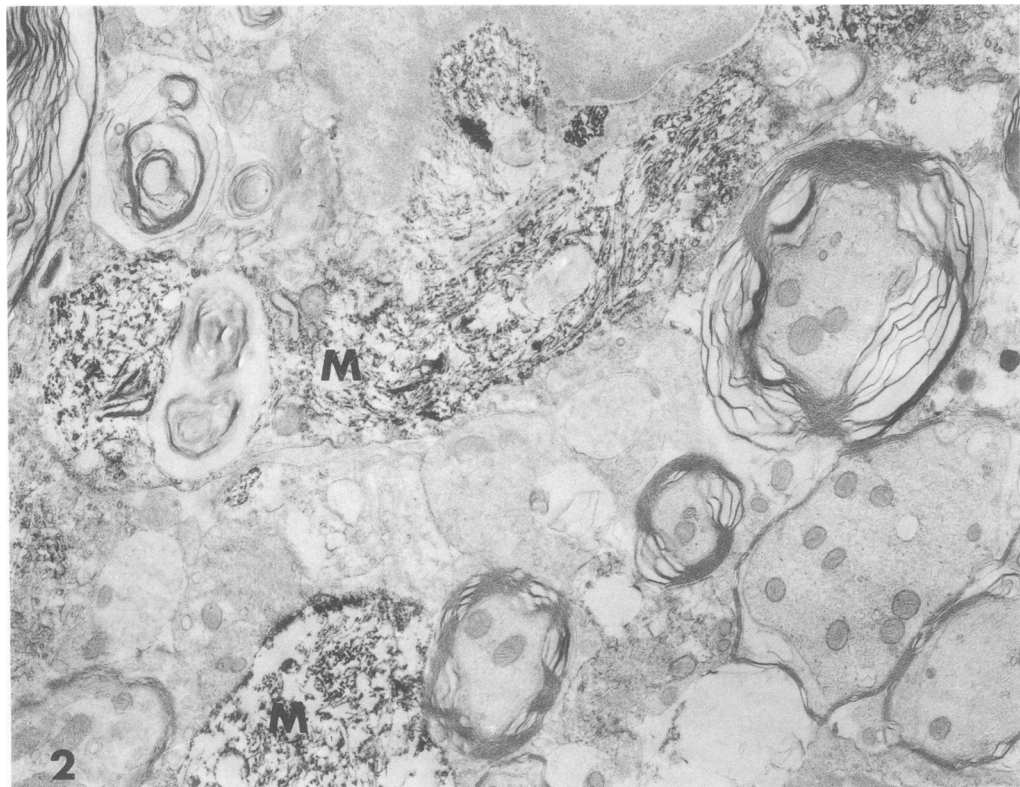
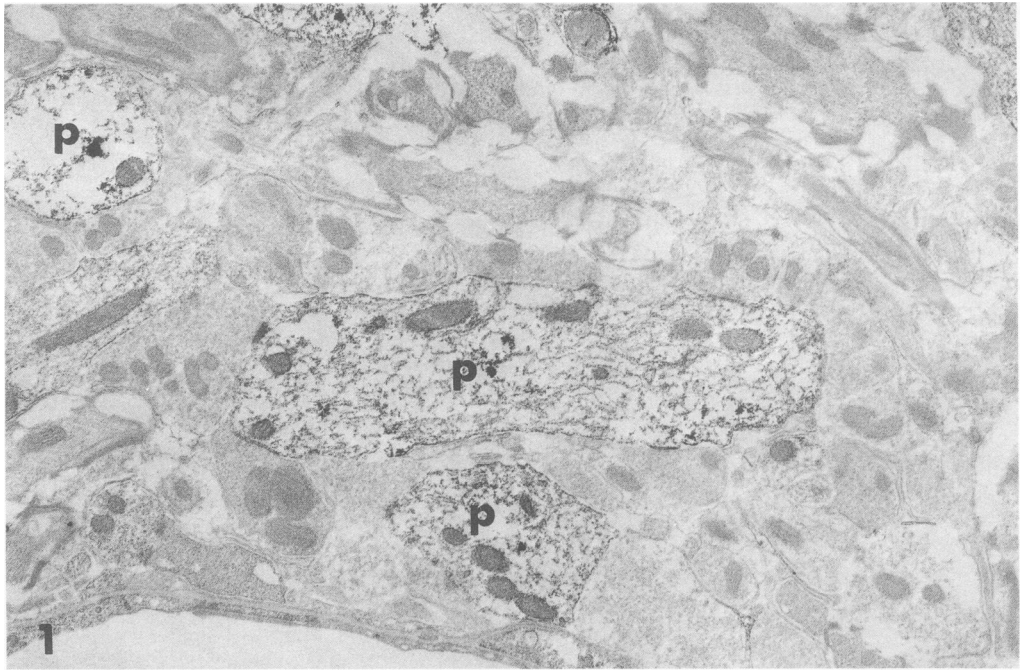


FIG. 1 and 2. Spinal cord sections of mice infected with ww virus. Sections were treated by the unlabeled antibody peroxidase-antiperoxidase method. Purified anti-TV IgG was used. Sections are without counterstains.

FIG. 1. Section from spinal cord gray matter 80 days postinfection showing specific immune staining in several neuronal processes (p). $\times 10,800$.

FIG. 2. Section from spinal cord white matter 80 days postinfection showing portions of cytoplasm of two macrophages (M) at the margins of an area of demyelination. Intense positive immune staining is observed in these macrophages. $\times 10,800$.

acute and chronic phases of the demyelinating model by immunofluorescence and by ultrastructural immunoperoxidase techniques (4a; H. L. Lipton, P. Sethi, and M. C. Dal Canto, submitted for publication). We were not able, however, to always recognize oligodendrocytes with certainty, in part because of their similarity to the numerous infiltrating mononuclear cells and in part because of suboptimal conditions of tissue fixation, necessitated by the immunohistochemical protocol. Although the few oligodendrocytes which could be identified because of their relations to surrounding axons appeared to be free of virus (4a), the question regarding the role of primary viral injury in the pathogenesis of TV-induced demyelination remained largely unresolved.

To circumvent this problem we turned to a recently described form of TV-induced demyelination which results from infection with the attenuated cell-adapted ww strain of TV (4). As previously reported, most areas of demyelination in spinal cords of ww-inoculated mice

show complete remyelination which is accomplished by invading Schwann cells rather than by oligodendrocytes (4). In addition, recurrent demyelination is observed in such animals, as evidenced by the simultaneous presence of acute and chronic plaques and especially by the occurrence of demyelination in those areas which had been previously remyelinated by Schwann cells (4). Since these cells are easily identifiable in tissues fixed for immunocytochemical studies, an ultrastructural immunoperoxidase technique was used for a search for viral antigen in Schwann cells in spinal cord areas where demyelination of Schwann cell-remyelinated axons was observed. These studies may help elucidate whether a direct viral attack on myelin-supporting cells is necessary for demyelination to occur in this viral infection.

Outbred Swiss male mice (CD-1) were obtained from Charles River Breeding Laboratories, Inc. (Portage, Mich.), and were housed 5 to 10 in polycarbonate cages. Animals were given water and food ad libitum. Four- to six-

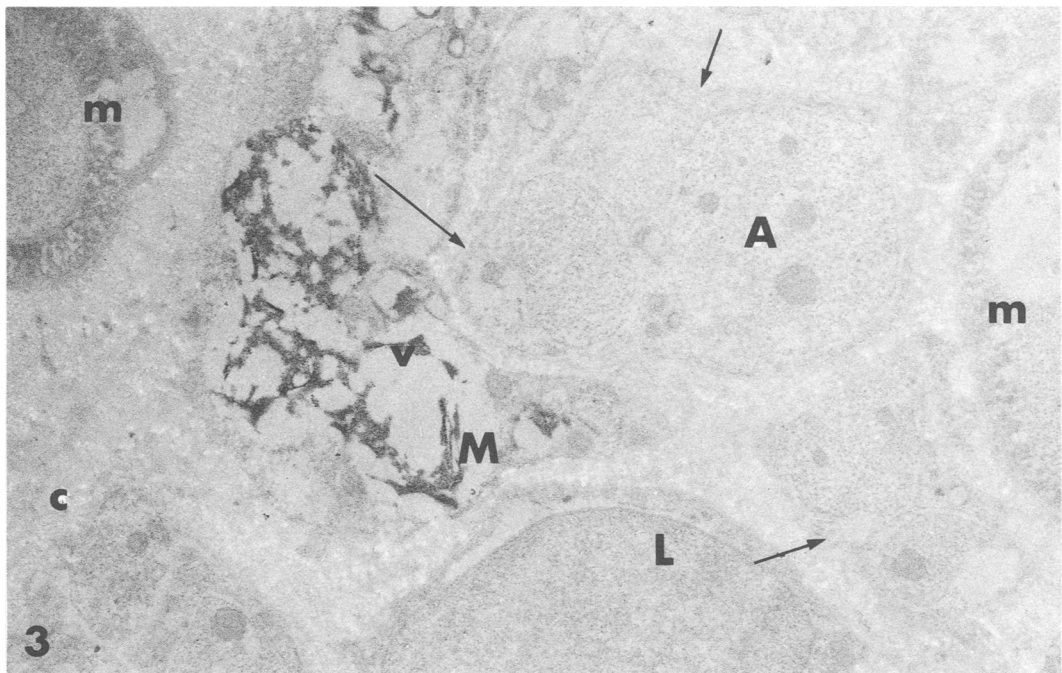


FIG. 3-5. Spinal cord sections of mice infected with ww virus. Sections were treated by the unlabeled antibody peroxidase-antiperoxidase method. Purified anti-TV IgG was used. Sections are without counterstains.

FIG. 3. Section from spinal cord white matter 80 days postinfection showing complete Schwann cell takeover after initial demyelination. Axons "m" have still intact Schwann cell-formed myelin. Axons like "A" are still enveloped by Schwann cell processes and basement membrane but have lost their myelin sheaths. An adjacent lymphoid cell (L) and macrophage (M) are expressions of renewed inflammatory demyelinating activity, and a positive antiviral immunostaining reaction (v) is present in M cytoplasm. The extracellular space is rich in collagen fibers. Schwann cell cytoplasm (arrows) are free of any staining. $\times 17,000$.

week-old animals were injected intracerebrally with 10^3 to 10^4 PFU of ww virus. ww virus was adapted to grow and produce a cytopathic effect in tissue culture, and a virus stock was prepared on the fourth passage in primary baby mouse kidney cells (10). Two mice were sacrificed at biweekly intervals from 1 to 8 weeks and every 4 weeks until 7 months after infection. Anesthetized animals were perfused through the heart with a freshly prepared chilled mixture of 0.4% paraformaldehyde and 0.02% glutaraldehyde. Spinal cords were then cut into 20- to 30- μ m-thick sections on a Vibratome and processed as follows: (i) incubation in 3% normal sheep serum in 0.5 M Tris (pH 7.6) for 30 min at room temperature; (ii) incubation in purified rabbit anti-TV immunoglobulin G (IgG) diluted 1:20 in

the same Tris overnight at 4°C; (iii) incubation in goat anti-rabbit IgG diluted 1:40 in the same Tris for 30 min at room temperature; (iv) incubation in rabbit peroxidase-antiperoxidase diluted 1:50 in Tris buffer with 1% normal sheep serum for 3 h at room temperature; (v) fixation in 3% glutaraldehyde for 15 min; (vi) reaction with 3,3'-diaminobenzidine in the presence of H_2O_2 for 30 min at room temperature. All sections were treated with 1% osmium tetroxide for 5 min at room temperature and then dehydrated and embedded in Epon by the usual protocol. Epon blocks were examined directly under light microscopy, and selected fields were trimmed for thin sectioning. Grids were examined without counterstain in a Philips 200 electron microscope. As controls for staining specificity, paral-

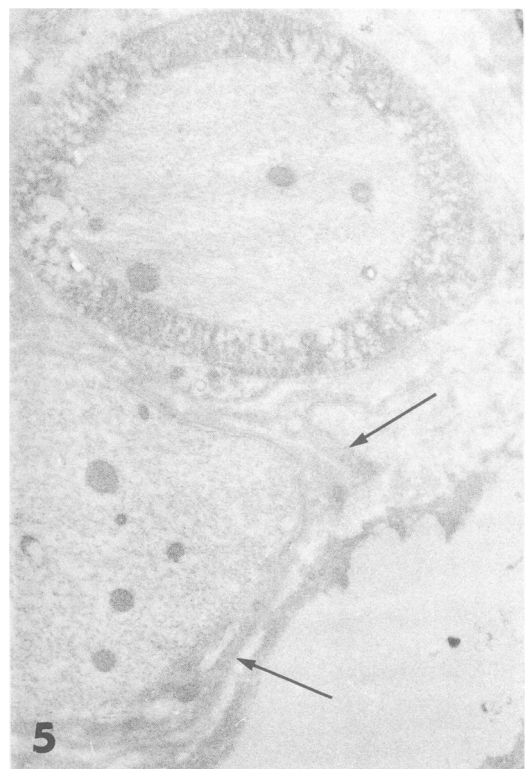
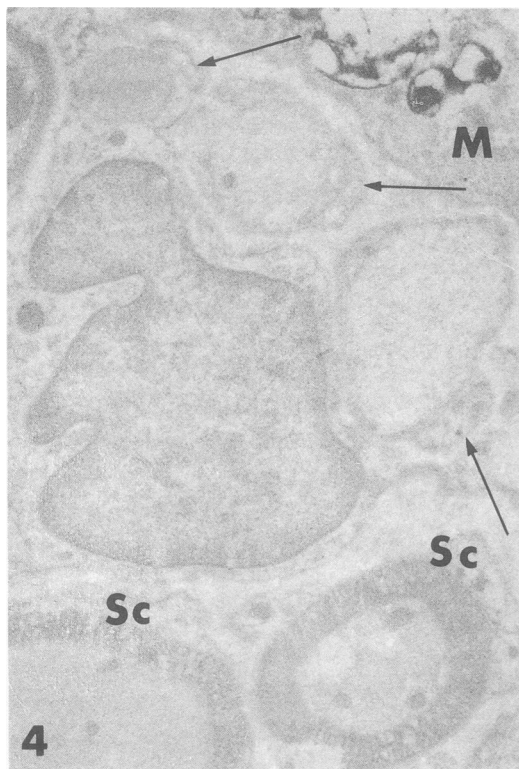


FIG. 4. Section from spinal cord white matter 64 days postinfection showing that all axons had been contacted by Schwann cells after initial demyelination. Whereas the two axons on the bottom show intact Schwann cell (Sc)-formed myelin, three axons have lost their sheaths although they are still in contact with the respective Schwann cells (arrows). An infiltrating mononuclear cell occupies the center of the photograph in close proximity to the demyelinated axons. A portion of a macrophage (M) in the upper right-hand corner shows positive immune reaction. All Schwann cells are free of staining. $\times 11,200$.

FIG. 5. Section showing two axons. The axon at the top shows an intact Schwann cell-formed myelin sheath. The upper left-hand corner is occupied by Schwann cell cytoplasm which is free of reaction. The axon at the bottom has lost its myelin but is still surrounded by Schwann cell processes (arrows) which rest on a basement membrane. These processes have the characteristic duplicated and convoluted appearance which results from demyelination. Such processes are free of immune staining. Eighty days postinfection. $\times 14,000$.

lel sections for each spinal cord were incubated in normal rabbit serum rather than in rabbit anti-TV IgG, and other sections were incubated in anti-glial fibrillary acidic protein antibody rather than in rabbit anti-TV IgG. Sections were treated identically in all other steps.

Examination of both gray and white matter generally confirmed previous results from mice inoculated with the brain-derived DA strain of TV (4a). Briefly, neurons showed cytoplasmic staining for the first few weeks of infection, whereas axonal terminals, dendrites, and post-synaptic terminals displayed viral antigen for the entire period of observation (Fig. 1). In addition, astrocytes, mononuclear inflammatory cells, and macrophages were seen to contain virus from about 10 to 15 days postinfection to the end of the study (Fig. 2). As in DA virus-infected animals, macrophages were the most numerous and most heavily infected cells in both anterior and lateral columns of the spinal cord.

The possible significance of the presence of viral antigen in neuronal processes, astrocytes, mononuclear cells, and especially macrophages during the chronic phase of TV infection has been discussed elsewhere (4a). Briefly, different cell types appear to be involved in the development of persistent infection, but macrophages in white matter are probably the most important in this regard. In addition, because of their strict relationship to demyelinating lesions and the known capacity of activated macrophages to denature myelin basic protein, persistently infected macrophages may also have a primary role in the production of myelin injury.

In contrast to DA virus-infected animals and in agreement with previous studies, the chronic phase of infection by ww virus was, in addition, characterized by areas of recurrent inflammatory mononuclear cell activity accompanied by numerous macrophages. Most of these areas contained axons which had previously been remyelinated by Schwann cells and were now undergoing a second wave of demyelination. Such areas contrasted with quiescent Schwann cell-remyelinated areas where no inflammatory activity and only rare scattered macrophages remained (4).

Schwann cells in white matter were easily recognizable because of their one-to-one relation with axonal internodes and the presence of a basement membrane resting on a collagen-rich extracellular space. In sharp contrast with nearby astrocytes, inflammatory cells, and macrophages. Schwann cells in either quiescent or demyelinating lesions never showed any evidence of viral antigen in their cytoplasm (Fig. 3 to 5). Since this immunohistochemical technique is very sensitive and capable of revealing the presence of small amounts of antigen down to

terminal neuronal processes, total lack of antigen in the cytoplasm of Schwann cells strongly suggests that these cells were actually free of primary infection.

Lack of viral antigen in Schwann cells despite widespread demyelination of Schwann cell-remyelinated axons correlates well with previous investigations in animals with the DA strain of TV. Ultrastructural studies of such animals had, in fact, shown that oligodendroglial outer tongues, still in contact with the plasma membranes of demyelinated axons, appeared to be free of pathological alterations (2). The absence of cytopathic effect of oligodendrocytes suggested that direct viral injury was not a primary factor in the pathogenesis of myelin degeneration. This conclusion was supported by subsequent immunosuppression experiments whose results suggested the host immune response rather than direct viral cytolysis as the most probable pathogenetic factor in this demyelinating model (9). The present immunocytochemical investigation adds further support to those studies by showing that demyelination of Schwann cell-remyelinated axons in spinal cord white matter is not dependent on the presence of virus in the myelinating cells. Such an uncoupled relationship between demyelination and direct viral infection of the myelin-supporting cell is consistent with and indirectly supports the immune pathogenetic hypothesis of demyelination that was previously suggested for this viral model (2, 9).

This work was supported by Public Health Service grant NS 13011 from the National Institutes of Health. H. L. Lipton kindly provided ww virus and anti-virus IgG. The excellent technical assistance of Jannie Tong is gratefully acknowledged.

LITERATURE CITED

1. Alvord, E. C., Jr. 1970. Acute disseminated encephalomyelitis and allergic neuroencephalopathies, p. 500-571. In P. J. Vinken and G. W. Bruyn (ed.), *Handbook of clinical neurology*, vol. 9. North-Holland Publishing Co., Amsterdam.
2. Dal Canto, M. C., and H. L. Lipton. 1975. Primary demyelination in Theiler's virus infection: an ultrastructural study. *Lab. Invest.* 33:626-637.
3. Dal Canto, M. C., and H. L. Lipton. 1977. Animal model: Theiler's virus infection in mice. *Am. J. Pathol.* 88:497-500.
4. Dal Canto, M. C., and H. L. Lipton. 1980. Schwann cell remyelination and recurrent demyelination in the central nervous system of mice infected with attenuated Theiler's virus. *Am. J. Pathol.* 98:101-122.
- 4a. Dal Canto, M. C., and H. L. Lipton. 1982. Ultrastructural immunohistochemical demonstration of Theiler's virus in acute and chronic Theiler's demyelinating encephalomyelitis. *Am. J. Pathol.* 106:20-29.
5. Johnson, R. T. 1964. The pathogenesis of Herpes virus encephalitis. II. A cellular basis for the development of resistance with age. *J. Exp. Med.* 120:359-374.
6. Lampert, P. W. 1965. Demyelination and remyelination in

- experimental allergic encephalomyelitis: further electron microscopic observations. *J. Neuropathol. Exp. Neurol.* **24**:371-385.
7. **Lampert, P. W., J. K. Sims, and A. J. Kniazeff.** 1973. Mechanism of demyelination of JHM virus encephalomyelitis. Electron microscopic studies. *Acta Neuropathol.* **24**:76-85.
 8. **Lipton, H. L.** 1975. Theiler's virus infection in mice: an unusual biphasic disease process leading to demyelination. *Infect. Immun.* **11**:1147-1155.
 9. **Lipton, H. L., and M. C. Dal Canto.** 1976. Theiler's virus-induced demyelination: prevention by immunosuppression. *Science* **192**:62-64.
 10. **Lipton, H. L., and M. C. Dal Canto.** 1979. The TO strains of Theiler's viruses cause "slow virus-like" infection in mice. *Ann. Neurol.* **6**:25-28.
 11. **Penny, J. B., and J. S. Wolinski.** 1979. Neuronal and oligodendroglial infection. *Lab. Invest.* **40**:324-330.
 12. **Weiner, L. P.** 1973. Pathogenesis of demyelination induced by a mouse hepatitis virus (JHM virus). *Arch. Neurol.* **28**:298-303.
 13. **Wroblewska, Z., D. H. Gilden, M. Wellish, L. B. Rorke, K. G. Warren, and J. S. Wolinski.** 1977. Virus specific intracytoplasmic inclusions in mouse brain produced by a newly isolated strain of Theiler's virus. I. Virologic and morphologic studies. *Lab. Invest.* **37**:595-602.
 14. **Wroblewska, Z., S. U. Kim, W. D. Sheffield, and D. H. Gilden.** 1979. Growth of the ww strain of Theiler's virus in mouse central nervous system organotypic culture. *Acta Neuropathol.* **47**:13-19.