

---

# Acute Aortic Stenosis of a Porcine Valve Heterograft Apparently Caused by Graft Rejection: Case Report with Discussion of Immune Mediated Host Response

---

Wilmier M. Talbert, Jr., M.D., and Philip Wright, M.D.

*This report describes a patient with a glutaraldehyde preserved porcine xenograft in which acute prosthetic aortic valve stenosis developed during the postoperative period. Thrombotic occlusion was ruled out by direct visualization at reoperation, when a fibrin fusion of two leaflets was released to relieve the stenosis. After a fatal arrhythmia (79 days following insertion of the prosthesis), histological evaluation of the xenograft revealed a reaction on the leaflets, interpreted as predominantly transformed or blast lymphocytes. Microscopically, a thin layer of fibrin was visible over these cells. This fibrin layer could have stitched the commissure closed, producing the aortic stenosis. Such a sequence of events is unique in our past experience with 68 porcine xenograft valves. We believe that this case is an example of an immune mediated host response caused by rapid early fibrin fusion of prosthetic aortic leaflet margins, which resulted in prosthetic stenosis.*

THE PORCINE valve heterograft has proven to be the valve of choice for many situations. One of our patients developed early and rather sudden stenosis of an aortic porcine heterograft due to stiffening of the valve leaflet and formation of a fibrous adhesion between the margins of two adjacent leaflets. Fusion of the leaflets obliterated a commissure, permitted movement of only one leaflet, and produced significant stenosis and heart failure. Recatheterization suggested the presence of thrombus despite adequate anticoagulation with sodium warfarin. At reoperation, fusion of the leaflets was observed but no thrombus was present. Although separation of the fused leaflets relieved the aortic stenosis, the patient died of ventricular arrhythmia 79 days after valve insertion. At ne-

croscopy, the valve revealed changes consistent with an immune reaction.

## Case Report

The patient, a 35-year-old man, had been well until 6 months prior to admission when a routine physical examination revealed mild hypertension. During a follow-up visit, a murmur indicating aortic insufficiency was discovered. The patient was afebrile, but he reported increasing fatigability, shortness of breath, and an episode of paroxysmal nocturnal dyspnea. Three months prior to the present admission, he was hospitalized elsewhere and was treated for congestive heart failure. Blood cultures were negative. Penicillin and streptomycin were given for possible occult subacute bacterial endocarditis.

---

*From the Departments of Pathology and Surgery, Memorial Hospital Medical Center, Long Beach, California 90801.*

---

*Address for reprints: Wilmier M. Talbert, Jr., M.D., Associate Pathologist, Memorial Hospital Medical Center, P.O. Box 1428, Long Beach, California 90801.*

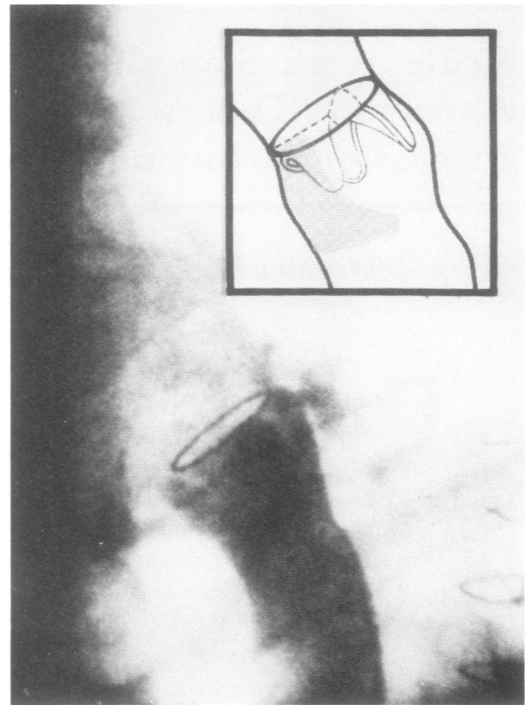
---

Cardiac catheterization confirmed aortic insufficiency, but during the procedure, the patient developed ventricular arrhythmia and pulmonary edema. He was transferred to this hospital for aortic valve replacement.

The patient was a well-developed and well-appearing young man with evidence of aortic insufficiency. Additional blood cultures failed to grow organisms. Antibiotic coverage was continued, and throughout a week of vigorous diuretic therapy and rest, the patient lost 5½ pounds. Eight days after admission, a #23 Hancock porcine xenograft was inserted.

At operation, there was a flail right aortic cusp, multiple sinus of Valsalva aneurysms, a sinus of Valsalva fistula to the right atrium, and a small secundum atrial septal defect. The sinus fistula and septal defect were closed. The aortic root was small, as though the insufficiency of the valve was acute, and minimal dilatation had occurred, as if the condition had been chronic. Cultures of the valve failed to grow organisms. The histological findings on the valve were consistent with the residua of acute bacterial endocarditis superimposed upon a normal valve, although no organisms were found in sections of the valve. Intravenous Keflin (cephalothin sodium) was given for 5 days, and oral Keflex (cephalexin) was given for an additional 4 days. Sodium warfarin was begun on the fourth postoperative day.

On the third postoperative day, a short early systolic murmur was heard. This murmur increased, becoming harsh with a Grade 2/3 intensity on a scale of 1 to 6, until it occupied the first half of systole by the ninth postoperative day. On the twelfth day, the murmur radiated to the base of the neck. The cardiac status of the patient was one of persistent tachycardia and borderline cardiac compensation. Cardiac catheterization, performed 22 days after insertion of the porcine prosthesis, revealed aortic stenosis, with no movement of two of the three prosthetic cusps (Fig. 1). A 70 mm Hg resting systolic LV-Ao gradient was measured across the valve. No significant change occurred, and because of cardiac failure, the patient was reexplored on the 55th day following insertion of the porcine valve.



**Fig. 1** Frame from the postoperative aortogram. On the right, the jet of nonopacified blood is seen being ejected through the patent sector of the tricuspid porcine prosthesis. A persistence of contrast remains in the sinuses to the left, where the common free margins of two leaflets are adherent to each other, producing prosthetic stenosis.

At reoperation, the noncoronary and right cusps of the porcine prosthesis were adherent along their entire common margin from *corpora Arantii* at their midpoints to the commissure of the heterograft. The left cusp was stiff but mobile. No thrombus was present on the prosthesis, beneath the valves, or on the aortic wall. The *corpora Arantii* were gently separated by blunt dissection; the valve edges appeared to have created the adhesion between the two cusps. In the absence of thrombus or infection, the valve was not replaced.

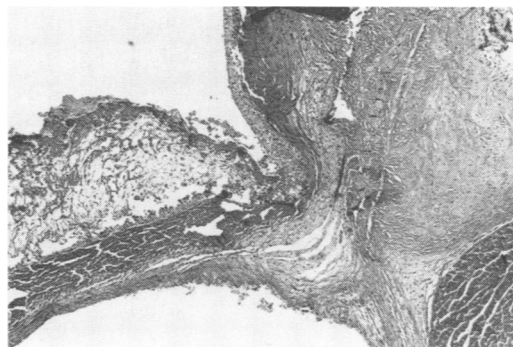Six days postoperatively, when the pericardial tube was still in place, an echocardiogram revealed evidence of pericardial effusion. On the eighth postoperative day, anticoagulation with sodium warfarin was resumed after removal of the last chest tube. On the eleventh postoperative day, a superficial fluid collection in the sternotomy site was

drained. On the twelfth day, we suspected imminent pericardial tamponade, and a serosanguinous effusion was drained via the subxiphoid approach. The epicardial and chest wall tissues oozed excessively. Subsequently, *E. coli* sensitive to Gentamicin was cultured from superficial sternotomy drainage. The patient was treated with Gentamicin and remained afebrile and stable until he developed a ventricular arrhythmia; cardiac arrest occurred 79 days after the initial valve implantation (23 days after his second operation).

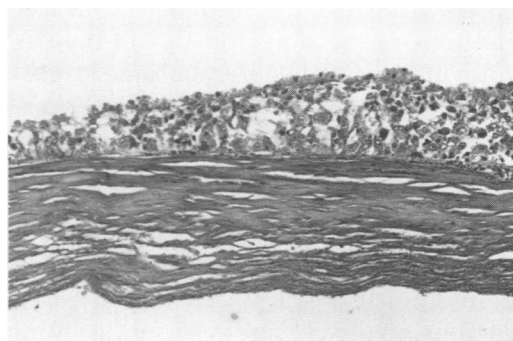
### Histologic Analysis

Autopsy revealed the liver to weigh 2250 gm, with central necrosis and cholestasis. The kidneys weighed 240 and 280 gm and had focal hematogenous abscesses. The porcine valve heterograft leaflets were not adherent to each other. The sinus of Valsalva fistula tracts that were closed during the initial operation were still closed and were healing. No abscesses or bacterial colonies were found in or about the prosthesis. The finding of greatest interest and the reason for this report was the cellular reaction on the inner, or aortic, aspect of the heterograft cusps.

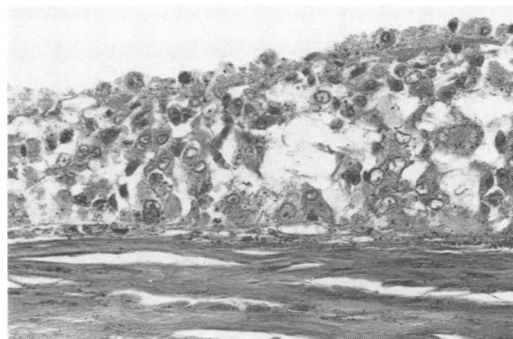
The Hancock porcine valve used in this case included the pig aortic valve plus a small portion of pig ventricular myocardium and pig aorta. Figure 2 shows the heterograft near the valve's origin from the porcine aorta. The porcine myocardium exhibited cross striations and nuclei (not visible at this magnification), and the edges of the graft (not shown here) were the site of a normal foreign body giant cell response which we have seen in other cases. The endocardium of the valve on the aortic side of the leaflet had a fibrin layer which was adherent to a cellular reaction on the surface of the valve. In Figure 3, which is a higher-powered magnification, the quality of the cellular reaction on the sinus or aortic surface is emphasized. Figure 4 shows the detail of the cells themselves. These cells are interpreted by us as activated lymphocytes most characteristic of the large cells of lymphoid origin seen in renal graft reac-



**Fig. 2** Heterograft valve with porcine ventricular myocardium in the right lower corner and the aortic aspect of valve with fibrinous and cellular reaction. (Magnification  $\times 12.5$ )



**Fig. 3** Heterograft valve with cellular reaction on aortic side of graft. Note near absence of nuclei in the collagenous substance of the valve. (Magnification  $\times 125$ )



**Fig. 4** Heterograft valve showing detail of area in Figure 2. The small black grains are formalin pigment caused by fixation of the valve, with loosely adherent postmortem blood clot that has been peeled off. These are the cells of reaction to the valve. Unlike phagocytic cells, which are frequently motile, they show no tendency to invade the substance of the valve. (Magnification  $\times 312$ )

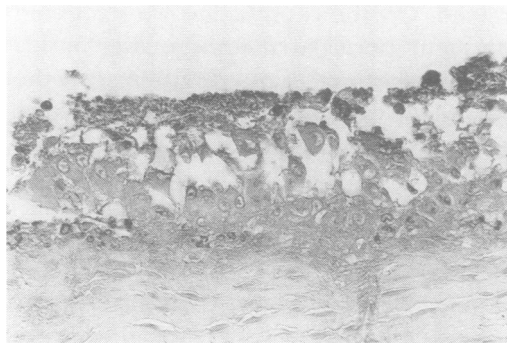tions.<sup>1</sup> Immunoperoxidase staining of the paraffin embedded tissues failed to reveal stainable immunoglobulins (IgG, IgA, IgM, Kappa and Lambda) in the cytoplasm of these cells (Fig. 5). Review of these sections by a transplantation and immunologic pathology associate reported that histologically the picture was most consistent with graft rejection.<sup>2</sup>

### Other Observations

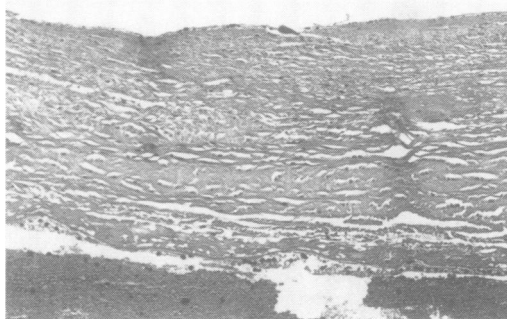
Gluteraldehyde-preserved porcine heterografts in our hospital have been very successful, and only three specimens with survival time of more than 10 days have become available for histologic study. A representative section from one of these is shown in Figure 6, taken at the same magnification as Figure 3. The aortic side is uppermost in the picture, and there is good nuclear preservation in the valve itself. This tissue is from a #31 Hancock porcine prosthesis placed in the mitral position of a 35-year-old woman. A Bjork-Shiley #23 prosthesis had been placed in the aortic position and the porcine valve in the mitral position 2½ months prior to death. The patient had stopped her anticoagulants and died when her Bjork-Shiley valve thrombosed. In spite of this complication in the aortic position, the porcine valve in the mitral position was unaffected. A single layer of host, small mononuclear cells was barely visible on the aortic surface of this valve. The valve did not display the cellular reaction observed in the case we have just reported.

### Discussion

Early work on heterograft rejection tended to emphasize the humoral aspects of graft rejection.<sup>3,4</sup> Inflammatory responses were described as neutrophils or macrophages by Aparicio et al.<sup>5</sup> That group dealt with cellular reactions of preserved homografts and heterografts where gluteraldehyde was not one of the methods of preservation studied. The sequence of cel-



**Fig. 5** Immunoperoxidase staining for IgG. No staining of the cell cytoplasm is seen. (Magnification x312)



**Fig. 6** Heterograft valve in Case 2 has minimal cellular reaction on either ventricular (inferior in this photograph) or aortic (superior in this photograph) surfaces. Note preservation of nuclei. (Magnification x125)

lular reactions of gluteraldehyde-treated skin grafts and xenografts suggested that gluteraldehyde-treated skin grafts were rejected as foreign bodies and that a cellular immune response was not involved.<sup>6</sup>

Several studies of the histology of gluteraldehyde-treated xenografts describe tissue reactions quite similar to those seen in the present case.<sup>7-9</sup> However, no reference is made to valve cusp fusion without thrombosis. In the largest series of gluteraldehyde-preserved valves reported to date, the greatest inflammatory reaction was found in a valve inserted in a patient who was having a second set of xenografts after the initial xenograft had been in place for 56 months. Although the suggestion was made that host sensitization was responsible for the inflammatory response, it

was not characterized as an immune response.<sup>8</sup>

Clearly, there are at least two separate phenomena involving fibrin deposition on or about a xenograft. In one, the valve is covered by bland fibrin devoid of cellular evidence of host reaction, and the clinical story provides other hemodynamic reasons for the development of thrombosis on or near the prosthesis. On the other hand, evidence of sensitization may exist: cellular evidence of host reaction is present and fibrin is found deposited on the cells involved with the rejection process of the valve. That the material on and possibly in the valve is fibrin is shown not only by routine histology, but also by X-ray diffraction studies.<sup>12</sup> The participation of the coagulation system in the immune response of graft rejection is well recognized.<sup>13</sup> Most discussions of anticoagulation therapy for artificial heart valves do not consider the possibility of an immune reaction initiating the coagulation. Perhaps this is due to the long history of virtually nonimmune objects such as artificial valves. With porcine xenografts, however, thrombosis may occur, which, in some cases, is related to rejection of the graft. In these cases it seems most logical to consider therapy directed against the rejection phenomena. Radiation therapy of the prosthetic valve would appear to be the easiest way to accomplish this.

### Acknowledgments

We should like to express our appreciation to Dr. Robert Nakamura, who reviewed the slides of the graft, and to Dr. Hun Kim, who performed the immunoperoxidase studies.

### References

1. Nabarra B, Descamps B. Ultrastructure of cells infiltrating human kidney allografts. *Clin Exp Immunol* 1976; 24:300.
2. Nakamura RA. Personal communication. Scripps Clinic, La Jolla, California (1980).
3. Tector AJ, Boyd WC, Korn ME. Aortic valve allograft rejection. *J Thorac Cardiovasc Surg* 1971; 62:592.
4. Mattila SP, Fogarty TJ. Antigenicity of vascular heterografts. *J Surg Res* 1973; 15:81.
5. Aparicio SR, Donnelly RJ, Dexter F, Watson DA. Light and electron microscopy studies on homograft and heterograft heart valves. *J Path* 1975; 115:147.
6. Schechter I. Prolonged retention of glutaraldehyde-treated skin allografts and xenografts: Immunologic and histological studies. *Ann Surg* 1975; 182:699.
7. Albert HM, Bryant L, Schechter FG. Seven year experience with mounted porcine valves. *Ann Surg* 1977; 185:717.
8. Spray TL, Roberts WC. Structural changes in porcine xenografts used as substitute cardiac valves. *Am J Cardiol* 1977; 40:319.
9. Fishbein MC, Gissen SA, Collins JJ Jr, Barsamian EM, Cohn LH. Pathologic findings after cardiac valve replacement with glutaraldehyde-fixed porcine valves. *Am J Cardiol* 1977; 40:331.
10. Mair DD, Fulton RE, Danielson GK. Thrombotic occlusion of Hancock conduit due to severe dehydration after Fontan operation. *Mayo Clin Proc* 1978; 53:397.
11. Fontan E, Baudet E. Surgical repair of tricuspid atresia. *Thorax* 1971; 26:240.
12. Huc A, Planche CL, Weiss M, Manschott PH, Chapin F, Chabrand D. Study of pig valve heterografts by X-ray diffraction. *J Biomed Mater Res* 1975; 9:79.
13. Starzel TE, Bolhmig HL, Amemiya H, Wilson CB, Dixon EJ, Giles GR, Simpson KM, Halgrimson CG. Clotting changes, including disseminated intravascular coagulation, during rapid renal-homograft rejection. *N Engl J Med* 1970; 283:383.
14. McComb RD, Stahmann FD, O'Connor WN, Todd EP. Structure-related thrombosis involving a porcine xenograft valve. *Ann Thorac Surg* 1979; 27:191.