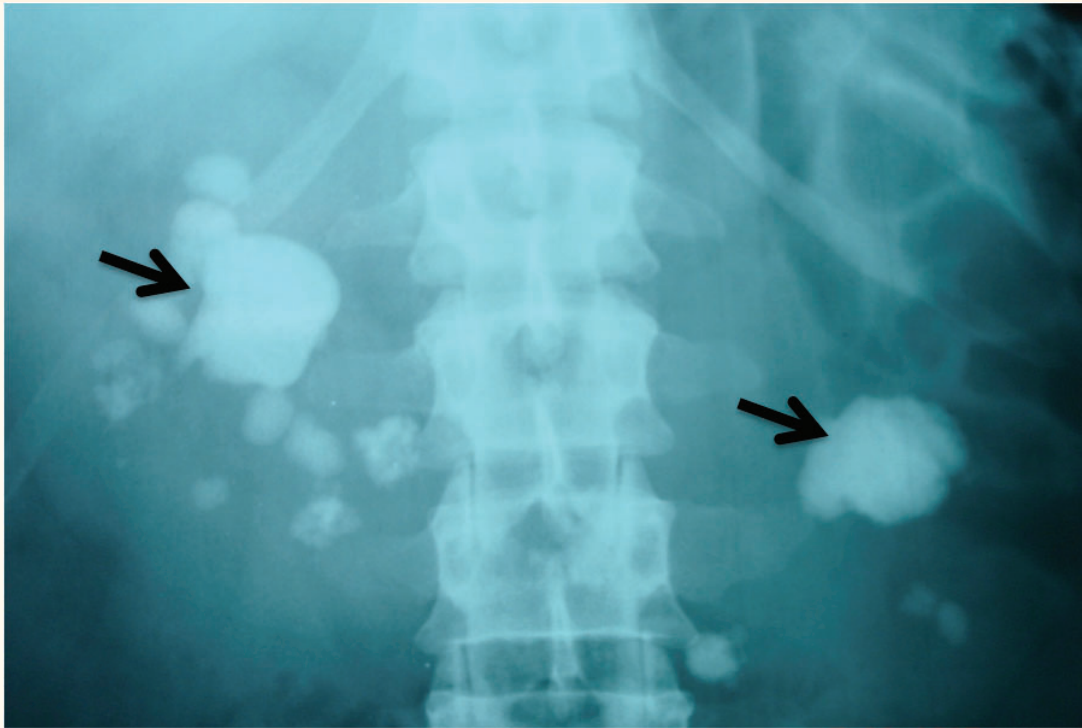


## Staghorn Calculus in a Horseshoe Kidney

Mohammed S. Al-Marhoon

### حصاة مرجانية في كلية حدوة الحصان

محمد المرهون

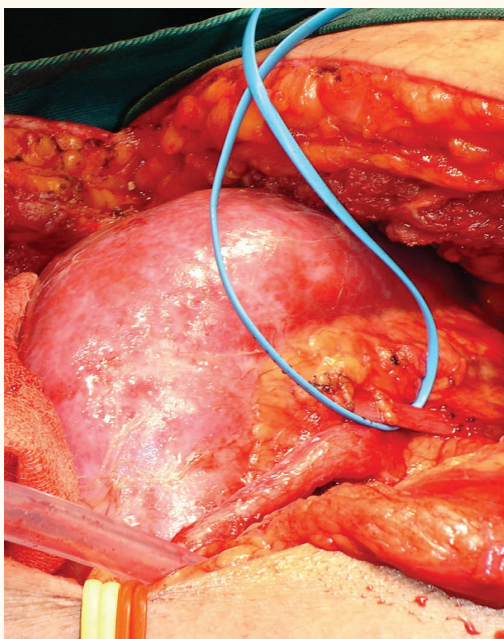


**Figure 1:** Plain X-ray showing staghorn calculus in a horseshoe kidney (black arrows).

**A** 52-YEAR-OLD MALE PATIENT PRESENTED with bilateral loin pain of four months' duration. Twenty years before, he had had surgery for kidney stone disease. An abdominal examination revealed a scar from the previous surgery on his left side. Investigations showed microscopic haematuria with no growth on urine culture. His serum creatinine and haemoglobin were normal. A plain abdominal X-ray of the kidneys, ureter, and bladder (KUB) [Figure 1] showed bilateral renal stones. The detailed renal anatomy and the extent of renal stones were delineated by computed

tomography (CT). The patient underwent an open pyelonephrolithotomy [Figure 2] and a staghorn stone was extracted [Figure 3]. The post-operative course was smooth and the residual stones were managed by extracorporeal shock wave lithotripsy (ESWL).

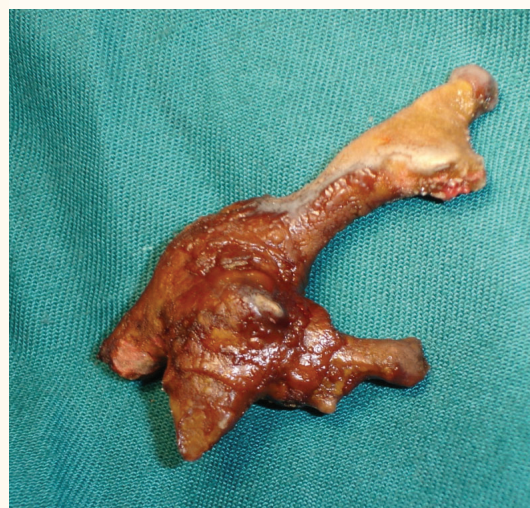The horseshoe kidney is the most common of all renal fusion anomalies. It occurs in 0.25% of the population (1 in 400 persons). The horseshoe kidney, even though it produces no symptoms, is frequently found in association with other congenital anomalies including genital anomalies: hypospadias - 4%,



**Figure 2:** Intra-operative view of the horseshoe kidney (vessel loop around renal artery).

undescended testes - 4%, bicornuate uterus - 7% and septate vagina - 7%; urinary collecting system anomalies: ureteral duplication - 10%, ureteropelvic junction obstruction - 20%, vesicoureteral reflux - 50%; renal parenchymal abnormalities: multicystic dysplasia - 1%, autosomal recessive polycystic kidney - 1%, and metabolic derangements in patients with stones in 50%: hypercalciuria, hyperoxaluria, hypocitraturia, hypouricuria.<sup>1</sup>

The association of horseshoe kidneys with staghorn calculus formation is rare. The reported cases in the literature of a staghorn calculi in a horseshoe kidneys were 19,<sup>2</sup> 3,<sup>3</sup> 8,<sup>4</sup> and 35 cases. Percutaneous extraction of stones from horseshoe kidneys has been done safely and is considered the standard of care. Prado *et al.* treated 8 patients with staghorn calculi in a horseshoe kidney by percutaneous nephrolithotomy (PCNL).<sup>4</sup> Complete stone clearance was achieved in all the patients. Only one patient suffered a long-term urinary tract infection of three months' duration, and temporary deterioration in renal function. It was concluded that PCNL, performed after an imaging study and careful assessment of the renal anatomy and related structures, can be a safe and effective monotherapy for patients with staghorn calculi in horseshoes kidney. Liatsikos *et al.*, in a study of 15 patients with 17 staghorn calculi in horseshoe kidneys who were treated by PCNL, reported an overall



**Figure 3:** The staghorn calculus extracted from the horseshoe kidney.

stone-free rate of 82%, with a major and minor complication rate of 20 and 46.6%, respectively.<sup>6</sup> Raj *et al.* used PCNL for the treatment of 37 patients with renal calculi in a horseshoe kidney (3 staghorn) and concluded that PCNL is an effective means of kidney stone management in this complex patient population.<sup>3</sup> However, PCNL is technically challenging, usually requiring upper pole access and flexible nephroscopy due to the altered anatomical relationships of the fused renal units.

The present case was managed by open surgery rather than PCNL due to the surgeon's preference. In addition, it has been shown that staghorn calculi are associated with a lower stone-free rate after percutaneous nephrolithotomy.<sup>2</sup> A patient with staghorn calculi in a horseshoe kidney was 45 times more likely to have a lower stone-free rate after percutaneous nephrolithotomy than a patient without staghorn calculi in the horseshoe kidney. Therefore, open surgery still has a role in the treatment of horseshoe kidneys with staghorn calculus when indicated.

## References

1. Boatman DL, Kolln CP, Flocks RH. Congenital anomalies associated with horseshoe kidney. *J Urol* 1972; 107:205–7.
2. Skolarikos A, Binbay M, Bisas A, Sari E, Bourdoumis A, Tefekli A, et al. Percutaneous nephrolithotomy in horseshoe kidneys: Factors affecting stone-free rate. *J Urol* 2011; 186:1894–8.
3. Raj GV, Auge BK, Weizer AZ, Denstedt JD, Watterson

- JD, Beiko DT, et al. Percutaneous management of calculi within horseshoe kidneys. *J Urol* 2003; 170:48–51.
4. Prado N, Ide E, Batista AJ. Management of staghorn calculi in horseshoe kidney. *Br J Urol* 1997; 80:332.
  5. Shokeir AA, El-Nahas AR, Shoma AM, Eraky I, El-Kenawy M, Mokhtar A, et al. Percutaneous nephrolithotomy in treatment of large stones with horseshoe kidneys. *Urology* 2004; 64:426–9.
  6. Liatsikos EN, Kallidonis P, Stolzenburg JU, Ost M, Keeley F, Traxer O, et al. Percutaneous management of staghorn calculi in horseshoe kidneys: A multi-institutional experience. *J Endourol* 2010; 24:531–6.