

Comparison of conventional lateral cephalograms with corresponding CBCT radiographs

Chang-Seo Park, Jae-Kyu Park, Huijun Kim, Sang-Sun Han, Ho-Gul Jeong, Hyok Park

Department of Oral and Maxillofacial Radiology, College of Dentistry, Yonsei University, Seoul, Korea

ABSTRACT

Purpose: This study was performed to assess the compatibility of cone beam computed tomography (CBCT) synthesized cephalograms with conventional cephalograms, and to find a method for obtaining normative values for three-dimensional (3D) assessments.

Materials and Methods: The sample group consisted of 10 adults with normal occlusion and well-balanced faces. They were imaged using conventional and CBCT cephalograms. The CBCT cephalograms were synthesized from the CBCT data using OnDemand 3D software. Twenty-one angular and 12 linear measurements from each imaging modality were compared and analyzed using paired-*t* test.

Results: The linear measurements between the two imaging modalities were not statistically different ($p > 0.05$) except for the U1 to facial plane distance. The angular measurements between the two imaging modalities were not statistically different ($p > 0.05$) with the exception of the gonial angle, ANB difference, and facial convexity.

Conclusion: Two-dimensional cephalometric norms could be readily used for 3D quantitative assessment, if corrected for lateral cephalogram distortion. (*Imaging Sci Dent* 2012; 42 : 201-5)

KEY WORDS: Cone-Beam Computed Tomography; Cephalometry

Introduction

Radiographic cephalometry is an essential clinical and research tool for diagnosing skeletal imbalance and for assessing skeletal growth and development. Lateral and frontal cephalograms have been well established and have resulted in several large databases of clinically normal and treated patient populations. Conventional cephalometric examination has, however, intrinsic limitations since it is a two-dimensional (2D) shadow of a three-dimensional (3D) structure, produced by a nonparallel beam that results in a distorted and enlarged image.¹

The 3D imaging technique has provided a new possibility for orthodontic diagnosis and treatment evaluation.^{2,3} The application of cone beam computed tomography (CBCT)

to the craniofacial region provides an alternative to traditional computed tomography (CT) systems with the advantages of less radiation and lower billing costs.

Because standard population norms have not been available for 3D CBCT volumes, patients from whom CBCT data are acquired may be subjected to further radiation exposure to acquire traditional lateral cephalograms and panoramic radiographs.⁴

The purpose of this study was to determine whether CBCT synthesized cephalograms could provide the same measurement of patients as conventional cephalograms and to find a method for obtaining normative values for 3D assessments.

Materials and Methods

The sample group consisted of 10 adults (6 males and 4 females, 32.3 ± 6.63 years old) with normal occlusions and well-balanced faces. The patients were imaged using conventional and CBCT synthesized cephalometric radiographs. Conventional cephalometric radiographs were

*This study was supported by a faculty research grant of Yonsei University College of Dentistry for 2008-0060.

Received December 22, 2011; Revised March 7, 2012; Accepted April 26, 2012

Correspondence to : Prof. Chang-Seo Park

Department of Oral and Maxillofacial Radiology, College of Dentistry, Yonsei University, 50 Yonsei-ro, Seodaemun-gu, Seoul, Korea

Tel) 82-2-2228-8843, Fax) 82-2-363-5232, E-mail) csp@yuhs.ac

Table 1. Measurements used in the study

Linear measurements
1. Anterior cranial base (S-N)
2. Posterior cranial base (S-Ar)
3. Ramus height (ArGo)
4. Body length (GoMe)
5. Body to anterior cranial base ratio (GoMe/SN)
6. Facial depth (NGo)
7. Facial length or Y axis (SGn)
8. Posterior facial height (SGo)
9. Anterior facial height (NMe)
10. Facial height ratio (SGo/NMe)
11. U1 to facial plane (Upper incisor to NPo)
12. L1 to facial plane (Lower incisor to Npo)
Angular measurements
1. Saddle angle (N-S-Ar)
2. Articular angle (S-Ar-Go)
3. Gonial angle (Ar-Go-Me)
4. SUM (1+2+3)
5. Gonial angle (upper) (Ar-Go-N)
6. Gonial angle (lower) (N-Go-Me)
7. SNA
8. SNB
9. ANB difference
10. SN to GoMe
11. Y-axis to SN (SGn to SN)
12. Facial plane angle (SN to NPog)
13. Facial convexity (NA to APog)
14. FMA (FH plane to Mandibular plane)
15. FMIA (FH plane to L1)
16. IMPA (L1 to Mandibular plane)
17. Occlusal plane to GoMe
18. Interincisal angle (U1 to L1)
19. L1 to Mandibular plane
20. U1 to FH
21. U1 to SN

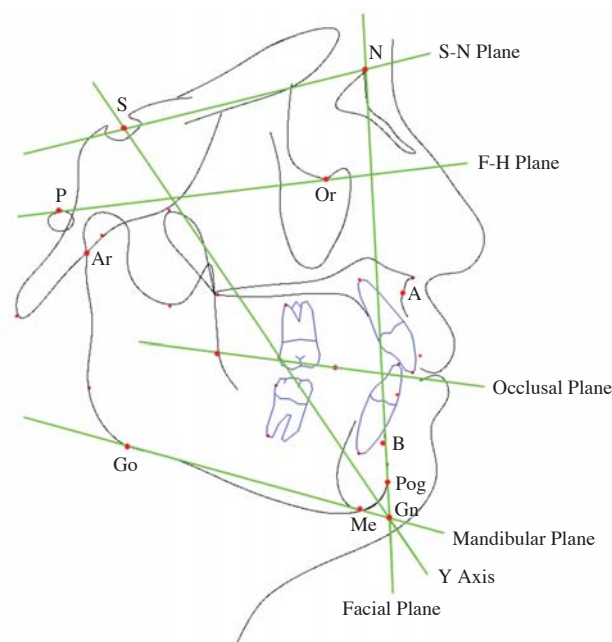


Fig. 1. Anatomic landmarks and planes used in the cephalometric analysis.

(V-ceph, CyberMed Co., Seoul, Korea) (Fig. 1). The measurements from the conventional cephalometric radiographs were corrected, taking a 10% magnification rate into account. The measurements between the imaging modalities were compared and analyzed using a paired-*t* test using IBM SPSS Statistics 20.0 (IBM Corp., Armonk, NY, USA). The results were considered statistically significant at $p < 0.05$.

Results

Table 2 shows that the differences between the linear measurements (mm) of the imaging modalities were not statistically different ($p > 0.05$) except for the U1 to facial plane distance. Table 3 shows that differences between angular measurements from the two imaging modalities were not statistically different ($p > 0.05$) with the exception of the gonial angle, ANB difference, and facial convexity.

Discussion

Several large databases of lateral and frontal cephalograms of clinically normal and treated patient populations have been compiled. Since the time of Broadbent,⁵ researchers have proposed procedures for combining lateral, frontal, and submentoververtex radiographs to obtain a 3D assessment of a patient.⁶ Although direct measurements

taken using an X-ray equipment (Cranex 3+[®], Sordex Orion Corp., Helsinki, Finland) set at 73 kVp, 10 mA, and 1.0 second and a cassette with an image plate (Fujifilm Holdings Corp., Tokyo, Japan). The image plates were scanned using a computed radiography system (FCR XG5000, Fujifilm Holdings Corp., Tokyo, Japan) and the conventional cephalometric images were then acquired. For CBCT cephalometry, CBCT data were obtained using CBCT equipment (Rayscan Symphony, Ray Co., Seoul, Korea). The scanning parameters were 90 kVp, 10 mA, 20 seconds of exposure time, a 0.38 mm slice thickness, and an 18 cm × 15 cm field of view (FOV). The synthesized CBCT cephalometric radiographs were acquired using the CBCT data using 3D imaging software (OnDemand 3D, Cybermed Co., Seoul, Korea). Twenty-one angular and 12 linear measurements (Table 1) were performed based on the skeletal and dental analysis using imaging software

Table 2. Linear measurements from the two imaging modalities (mm)

Measurement items	Conventional	CBCT	Difference	<i>p</i> -value
Anterior cranial base	72.47 ± 4.09	71.95 ± 5.61	-0.52 ± 1.72	0.368
Posterior cranial base	41.63 ± 4.17	40.96 ± 5.26	-0.67 ± 5.20	0.693
Ramus height	51.88 ± 4.40	51.42 ± 4.20	-0.46 ± 4.47	0.753
Body length	82.89 ± 4.44	81.00 ± 8.03	-1.89 ± 5.01	0.264
Body to anterior cranial base ratio	1.15 ± 0.04	1.13 ± 0.06	-0.02 ± 0.06	0.313
Facial depth	132.84 ± 6.75	134.07 ± 9.87	1.23 ± 8.45	0.656
Facial length on Y-axis	138.25 ± 6.65	134.91 ± 9.12	-3.34 ± 8.62	0.253
Posterior facial height	90.37 ± 6.80	90.11 ± 6.51	-0.26 ± 8.48	0.926
Anterior facial height	136.90 ± 5.38	136.09 ± 9.78	-0.81 ± 8.76	0.778
Facial height ratio	66.03 ± 4.45	66.36 ± 4.35	0.33 ± 5.14	0.844
U1 to facial plane*	9.58 ± 3.47	11.85 ± 2.62	2.27 ± 2.68	0.025
L1 to facial plane	5.80 ± 2.97	6.80 ± 2.45	1.00 ± 1.69	0.094

*the statistically significant difference between the two imaging modalities at $p < 0.05$.

Table 3. Angular measurements from the two imaging modalities (degrees)

Measurement items	Conventional	CBCT	Difference	<i>p</i> -value
Saddle angle	125.34 ± 4.92	125.70 ± 3.82	0.36 ± 5.87	0.85
Articular angle	150.57 ± 5.21	154.05 ± 4.66	3.48 ± 5.36	0.07
Gonial angle*	118.99 ± 4.62	115.60 ± 5.93	-3.39 ± 4.16	0.03
SUM	394.90 ± 5.87	395.35 ± 6.45	0.45 ± 6.44	0.83
Gonial angle (upper)	44.02 ± 2.93	41.73 ± 3.67	-2.29 ± 3.19	0.05
Gonial angle (Lower)	74.66 ± 3.85	73.77 ± 5.75	-0.89 ± 3.96	0.50
SNA	81.47 ± 3.89	81.42 ± 3.63	-0.05 ± 4.37	0.97
SNB	77.31 ± 4.41	75.60 ± 4.09	-1.71 ± 4.63	0.27
ANB difference*	4.16 ± 2.10	5.81 ± 2.01	1.65 ± 1.92	0.02
SN-GoMe	34.90 ± 5.87	35.35 ± 6.45	0.45 ± 6.44	0.83
Y axis to SN	72.18 ± 4.47	73.99 ± 4.67	1.81 ± 4.65	0.25
Facial plane angle	78.47 ± 4.62	76.42 ± 4.18	-2.05 ± 4.85	0.21
Facial convexity*	6.56 ± 5.43	11.12 ± 4.77	4.56 ± 5.00	0.02
FMA	28.59 ± 4.72	26.26 ± 7.07	-2.33 ± 5.38	0.20
FMIA	54.53 ± 7.78	55.00 ± 9.28	0.47 ± 3.18	0.65
IMPA	96.89 ± 5.38	98.75 ± 5.29	1.86 ± 3.83	0.16
Occlusal plane to GoMe	18.99 ± 3.35	17.48 ± 2.07	-1.51 ± 2.47	0.09
Interincisal angle	123.01 ± 10.63	123.01 ± 12.11	0.00 ± 7.20	1.00
L1 to mandibular plane	46.09 ± 2.23	46.22 ± 3.05	0.13 ± 2.92	0.89
U1 to FH	111.52 ± 6.42	111.98 ± 6.36	0.46 ± 7.49	0.85
U1 to SN	105.23 ± 7.78	102.92 ± 6.57	-2.31 ± 9.67	0.47

*the statistically significant difference between the two imaging modalities at $p < 0.05$.

on 3D images have marked advantages over other methods and measurements on the synthesized 2D images using 3D scans were similar with those of conventional radiographs proposed recently in the literatures,^{7,8} cephalometric analysis using 3D images still have the characteristics and limitations of a traditional cephalometric examination. Taking 3D measurements directly from 3D images such as CBCT or even 3D photographs allows an examiner to accurately quantify the right and left sides of the patient's jaw and face, separately. A diagnosis can then be reached by comparing the deviation of those measurements from the "normal values." Unfortunately, the exact nature of

such "normal values" for 3D measurements remains undefined.⁹

Due to the high economic cost, high dose of exposure, and ethical issues, obtaining 3D normative values from a large number of people with normal occlusion is unlikely to occur in the near future.⁹ Thus three-dimensional measurements can be compared only to their contralateral side to evaluate asymmetries¹⁰ or to measurements taken at different times to monitor treatment effects.¹¹ Normative values are essential to reach an appropriate diagnosis and to evaluate the net effects of the treatment. While a great deal of work is requested to demonstrate the added value of

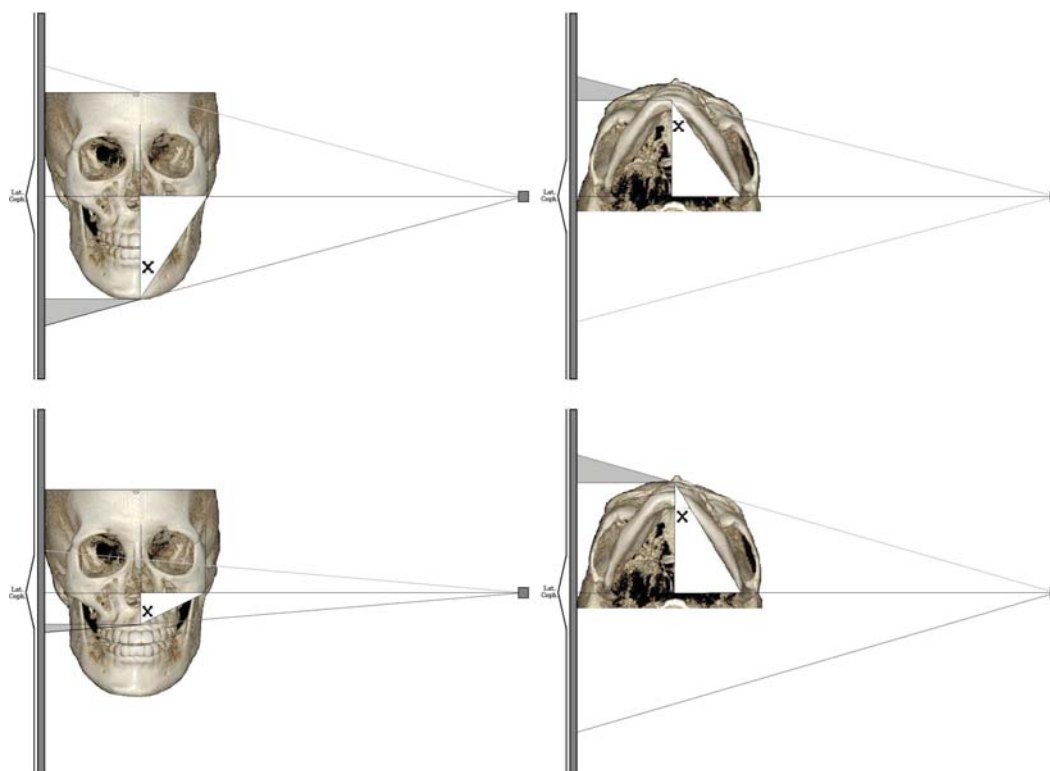


Fig. 2. Lateral cephalogram image construction diagram. $3D \text{ measurement} = [(cephalometric \text{ measurement}) - (cephalometric \text{ magnification})] / [\cosine (X)]$.

CBCT in standard orthodontic cases, it is not known whether data obtained from synthesized CBCT views can be compared with the current population norms and the existing databases obtained from conventional cephalograms.⁹

This study was performed to determine whether cephalometry could be synthesized from CBCT volumes and whether traditional cephalometry could be performed on these synthesized images with similar results. The results of this study showed that the linear measurements between the two imaging modalities were not statistically different except for U1 to facial plane distance; this distance difference was 2.27 mm, which was statistically and clinically significant (Table 2). The angular measurements between the two imaging modalities were not statistically significant except for the gonial angle, ANB difference, and facial convexity angle. These angular differences were -3.39 , 1.65 , and 4.56 degrees, respectively (Table 3). The differences of the gonial angle and facial convexity angle were not only statistically significant but also clinically significant. These results, although not definite, might have originated from the small sample size and the proficiency of the observer.

Gribel et al⁹ evaluated the accuracy of a simple algorithm

that corrected 2D cephalometric measurements from landmarks both on and off the midsagittal plane into a 3D CBCT measurements with accuracy. By applying this algorithm to other existing cephalometric longitudinal growth studies, it was possible to derive normative values for 3D measurements without exposing new untreated subjects to radiation (Fig. 2).

In conclusion, there were significant differences in one linear and three angular measurements between the conventional lateral and CBCT synthesized cephalometric radiographs. These differences among the measurements might originate from the projection difference of the two imaging modalities. Two-dimensional cephalometric norms could be readily used for 3D quantitative assessment with corrections for lateral cephalogram distortion.

References

1. Baumrind S, Frantz RC. The reliability of head film measurements. 1. Landmark identification. *Am J Orthod* 1971; 60 : 111-27.
2. Zamora N, Llamas JM, Cibrián R, Gandía JL, Paredes V. Cephalometric measurements from 3D reconstructed images compared with conventional 2D images. *Angle Orthod* 2011;

- 81 : 856-64.
3. Oz U, Orhan K, Abe N. Comparison of linear and angular measurements using two-dimensional conventional methods and three-dimensional cone beam CT images reconstructed from a volumetric rendering program in vivo. *Dentomaxillofac Radiol* 2011; 40 : 492-500.
 4. Kumar V, Ludlow J, Soares Cevidanes LH, Mol A. In vivo comparison of conventional and cone beam CT synthesized cephalograms. *Angle Orthod* 2008; 78 : 873-9.
 5. Broadbent BH. A new x-ray technique and its application to orthodontia. *Angle Orthod* 1931; 1 : 45-66.
 6. Rousset MM, Simonek F, Dubus JP. A method for correction of radiographic errors in serial three-dimensional cephalometry. *Dentomaxillofac Radiol* 2003; 32 : 50-9.
 7. Farman AG, Scarfe WC. Development of imaging selection criteria and procedures should precede cephalometric assessment with cone-beam computed tomography. *Am J Orthod Dentofacial Orthop* 2006; 130 : 257-65.
 8. Cattaneo PM, Bloch CB, Calmar D, Hjortshøj M, Melsen B. Comparison between conventional and cone-beam computed tomography-generated cephalograms. *Am J Orthod Dentofacial Orthop* 2008; 134 : 798-802.
 9. Gribel BF, Gribel MN, Manzi FR, Brooks SL, McNamara JA Jr. From 2D to 3D: an algorithm to derive normal values for 3-dimensional computerized assessment. *Angle Orthod* 2011; 81 : 3-10.
 10. Kwon TG, Park HS, Ryoo HM, Lee SH. A comparison of craniofacial morphology in patients with and without facial asymmetry - a three-dimensional analysis with computed tomography. *Int J Oral Maxillofac Surg* 2006; 35 : 43-8.
 11. Cevidanes LH, Bailey LJ, Tucker SF, Styner MA, Mol A, Phillips CL, et al. Three-dimensional cone-beam computed tomography for assessment of mandibular changes after orthognathic surgery. *Am J Orthod Dentofacial Orthop* 2007; 131 : 44-50.