



Contents lists available at SciVerse ScienceDirect

International Journal of Surgery Case Reports

journal homepage: www.elsevier.com/locate/ijscr

Metastatic hepatocellular carcinoma to the parotid gland: Case report and review of the literature

Young-Dong Yu^a, Dong-Sik Kim^{a,*}, Sung-Won Jung^a, Jeong-Hyeon Lee^b, Yang-Seok Chae^b, Sung-Ock Suh^a^a Department of Surgery, Division of HBP Surgery and Liver Transplantation, Korea University Medical Center, Korea University College of Medicine, Seoul, Republic of Korea^b Department of Pathology, Korea University Medical Center, Korea University Medical College, Seoul, Republic of Korea

ARTICLE INFO

Article history:

Received 8 June 2012

Received in revised form 31 July 2012

Accepted 9 August 2012

Available online 17 October 2012

Keywords:

Metastatic hepatocellular carcinoma

Parotid gland

Fine-needle aspiration

ABSTRACT

INTRODUCTION: Hepatocellular carcinoma, the most frequent primary hepatic tumor, metastasizes in more than 50% of cases. However, parotid gland metastatic HCCs are very uncommon. We report a patient in whom the finding of a left parotid mass revealed metastatic HCC.

PRESENTATION OF CASE: A thirty-six-year-old male presented with a round palpable left neck mass that persisted for 3 months. He had received right hemihepatectomy for hepatocellular carcinoma (HCC). Preoperative evaluation revealed a benign tumor of the parotid gland. We performed superficial parotidectomy. Metastatic hepatocellular carcinoma of the parotid gland was diagnosed.

DISCUSSION: Although HCC metastases to the oral cavity have been reported, to date, only 4 cases HCC metastasis to the parotid gland have been reported. Although clinicians and cytopathologists alike both agree that salivary gland fine needle aspiration biopsies (FNABs) are highly useful and safe diagnostic alternatives to biopsies and resections, we believe that in specific clinical situations, awareness of potential diagnostic pitfalls in salivary gland FNAB is a necessary part of the microscopic interpretations of these lesions.

CONCLUSION: Although rare, since HCC can metastasize to the parotid gland, high suspicion should be maintained in a patient presenting with a parotid mass with a history of HCC. In addition, since potential diagnostic pitfalls in salivary gland fine-needle aspiration (FNA) biopsies exist, incisional or excisional biopsy may be necessary for definite diagnosis of metastatic HCC to the parotid gland.

© 2012 Surgical Associates Ltd. Published by Elsevier Ltd. All rights reserved.

1. Introduction

Hepatocellular carcinoma (HCC) spreads via the hematogenous route, the lymphatic route, or by direct invasion into adjacent organs.¹ The common extrahepatic metastatic sites of HCC are the lungs, peritoneum, adrenal glands, and bone, although there are rare reports of metastases to the heart, nasal cavity, orbital cavity, skin, external auditory canals, and pharynx.^{2–8} Metastatic involvement of the parotid glands is uncommon, comprising 8% of all parotid gland malignancies.⁹ These metastases usually arise from a primary mucosal or cutaneous cancer, generally melanomas and squamous cell carcinomas, located in the ipsilateral head and neck region.^{10,11} Metastases arising from a primary cancer outside the head and neck region are also possible.¹² Hepatocellular carcinoma (HCC), the most frequent primary hepatic tumor, metastasizes in more than 50% of cases. However, parotid gland metastatic HCCs are very uncommon with 4 cases reported in the English literature.^{12–15}

We report a patient in whom the finding of a left parotid mass revealed metastatic HCC.

2. Presentation of case

A thirty-six-year-old Korean male presented to our otolaryngology clinic with a round 2 cm × 2 cm sized palpable, firm and painless left neck mass that persisted for 3 months. Past medical history revealed that he had received right hemihepatectomy for hepatocellular carcinoma (HCC) 8 months before presenting to the clinic. The initial pathology of the liver showed multiple lesions in the right lobe and the largest one was 9.3 cm × 7.5 cm (pathologic stage T3a, moderately differentiated HCC). There was no microvascular invasion and the preoperative positron emission tomography (PET) scan prior to liver resection showed no extrahepatic abnormal hypermetabolic lesions. Postoperatively, there was no evidence of recurrence and the serum alpha-fetoprotein (AFP) level was normal. A fine-needle aspiration (FNA) of the parotid gland performed prior to presenting to our clinic suggested the possibility of pleomorphic adenoma. A neck computed tomography (CT) scan revealed a 1.6 cm sized round and well defined enhancing nodular lesion in superficial lobe of the left parotid gland with no other remarkable lymph node enlargement and a

Abbreviations: HCC, hepatocellular carcinoma; FNA, fine-needle aspiration.

* Corresponding author. Tel.: +82 2 920 6620; fax: +82 2 921 6620.

E-mail addresses: kimds1@korea.ac.kr, hust1351@gmail.com (D.-S. Kim).

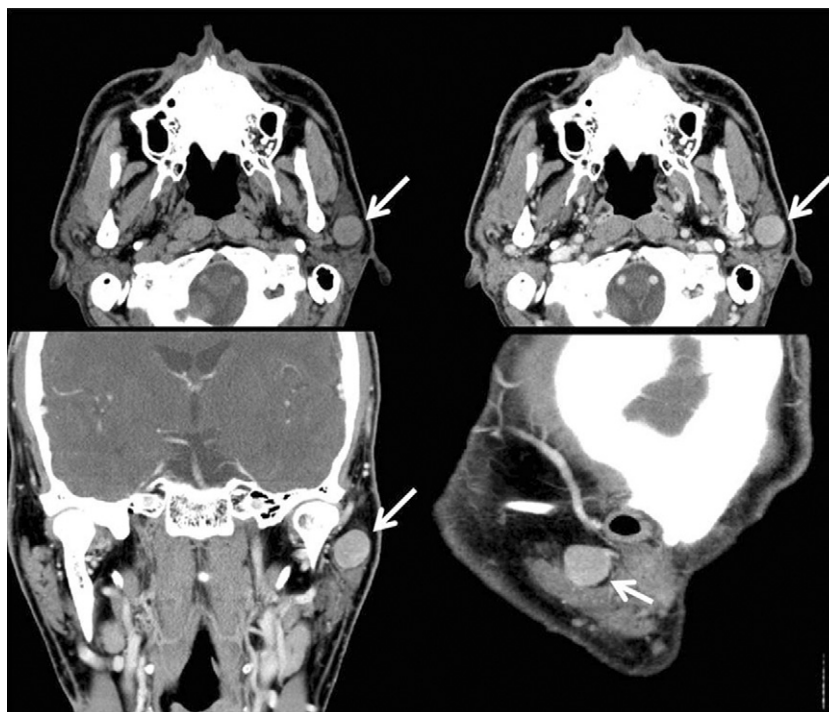


Fig. 1. Preoperative neck computed tomography (CT) scan a 1.6 cm sized round and well defined enhancing nodular lesion in superficial lobe of the left parotid gland (white arrow).

Pleomorphic adenoma or Warthin's tumor of the parotid gland was considered (Fig. 1). The preoperative liver function and AFP level was normal. We performed superficial parotidectomy of the left parotid gland while preserving the facial nerve and great auricular nerve. There were no immediate complications after the operation and the patient was discharged 3 days after surgery. Grossly, there was a well circumscribed yellowish ovoid mass within the parotid gland measuring 2.6 cm × 2.1 cm. The cut surface of the mass showed multiple hemorrhagic and microcystic foci in the diffuse granular background (Fig. 2). On microscopic examination, a totally encapsulated multilobulating tumor with a pushing margin showed a peripheral residual lymphoid cortex.

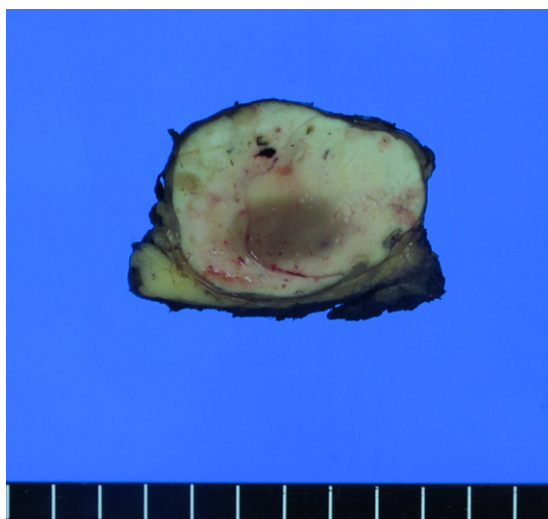


Fig. 2. Gross findings of the parotid gland revealed a well circumscribed yellowish ovoid mass within the parotid gland measuring 2.6 cm × 2.1 cm. The cut surface of the mass showed multiple hemorrhagic and microcystic foci in the diffuse granular background.

The tumor cells were polygonal cells with centrally located round nuclei containing large amount of eosinophilic cytoplasm. They were arranged in predominantly trabecular and focal pseudoglandular patterns. Occasional intracytoplasmic and canalicular bile pigmentation was also seen. The morphology of the tumor cells was identical to that of hepatocellular carcinoma and revealed moderate differentiation. In addition, immunohistochemical staining for antihepatocyte antibody showed diffuse strong positive reaction in the cytoplasm (Fig. 3). Metastatic hepatocellular carcinoma arising in the intraparotid lymph node was diagnosed. Re-examination of the FNA cytology slide obtained prior to the operation revealed high cellularity composed of many syncytial fragments of uniformly polygonal tumor cells with low nuclear–cytoplasmic ratio. Although the differential diagnoses included primary pleomorphic adenoma and oncocytoma, some endothelial cells were wrapped with tumor cells peripherally, and myxoid material, which is usually seen in pleomorphic adenoma, was not identified (Fig. 4). After diagnosis, a PET scan was performed for evaluation of other potential sites of recurrence. There was no evidence of tumor recurrence or metastasis. The patient is free of tumor recurrence for 6 months and is currently being observed at our outpatient clinic.

3. Discussion

Metastatic involvement of the salivary glands is uncommon, comprising 10–16% of all salivary gland malignancies, excluding lymphomas.¹⁴ These metastases usually originate from head and neck malignancies. Only 20% originate from infraclavicular sites, usually lung, kidney, or breast, or, more rarely, from gastrointestinal or genitourinary primary sites.¹⁴ Although HCC metastases to the oral cavity have been reported, to date, only 4 cases HCC metastasis to the parotid gland have been reported.⁸ To the best of our knowledge, the present case is the fifth case of metastatic HCC to the parotid gland reported in the English literature (Table 1).

Establishing a diagnosis of metastatic HCC in the maxillofacial area may be difficult.¹² The previous four cases of parotid

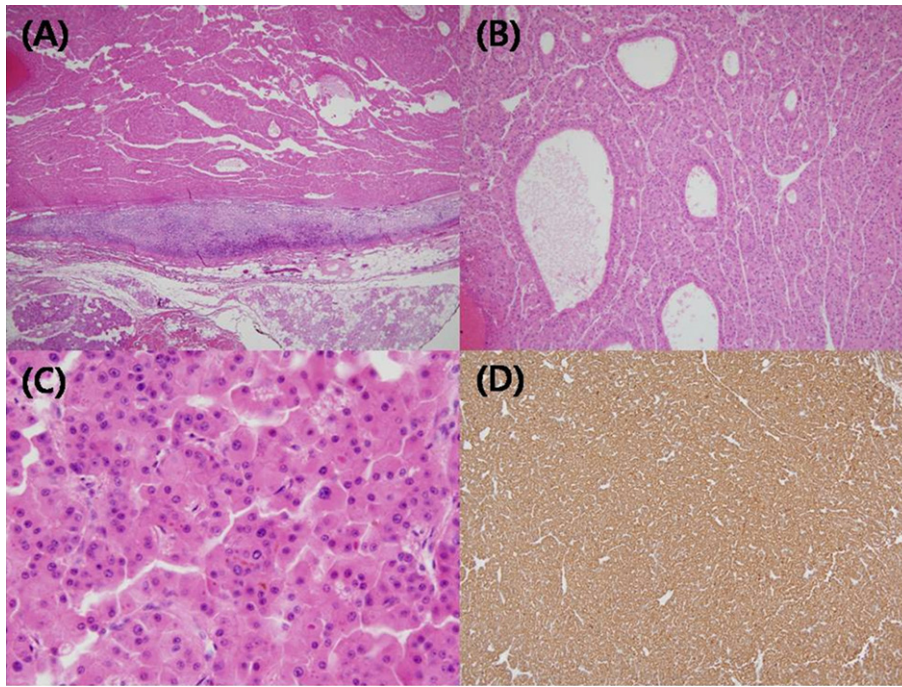


Fig. 3. Microscopic findings of the parotid gland. (A) Totally encapsulated multilobulating tumor with a pushing margin showed peripheral residual lymphoid cortex. (B) The tumor cells were polygonal cells with centrally located round nuclei containing large amount of eosinophilic cytoplasm. They were arranged in predominantly trabecular and focal pseudoglandular patterns. (C) Occasional intracytoplasmic and canalicular bile pigmentation was also seen. (D) Immunohistochemical staining for antihepatocyte antibody showed diffuse strong positive reaction in the cytoplasm.

metastasis from HCC and the present case were initially investigated by FNA. Despite its accuracy, specificity and sensitivity, discrepancies between the cytomorphological and histopathological examinations can occur.¹² FNA of the salivary gland lesions presents one of the most challenging of diagnoses in cytopathology.¹⁵ Difficulties that arise in salivary gland FNAs not only include distinguishing benign from malignant but also the specific classification of lesions.¹⁵ Occasionally, difficulties in salivary gland FNA interpretation may also include distinguishing primary from metastatic tumors.¹⁵ In the present case, the initial FNA finding was benign. Moreover, re-evaluation of the FNA slide after parotid surgery did not show specific cytological features that allowed a diagnosis of metastatic HCC and histological and immunohistochemical examination of the surgical specimen was necessary for accurate diagnosis. Although clinicians and cytopathologists alike both agree that salivary gland FNAs are highly useful and safe diagnostic alternatives to biopsies and resections, we believe that in specific clinical situations, awareness of potential diagnostic pitfalls in salivary gland FNA is a necessary part of the microscopic interpretations of these lesions.¹⁵

HCC, primary or metastatic, often presents cytological and histopathological features sufficiently characteristic to suggest its diagnosis, as in the present case.¹² A number of other metastatic tumors, notably from the breast, kidney and adrenal glands, may mimic the trabecular, liver-like pattern of HCC. Immunohistochemical analysis, including markers such as cytoplasmic alpha-fetoprotein, 'hepatic' cytokeratins 8 and 18, carcinoembryonic antigen, epithelial membrane antigen, CD10, CD15, K1-67 and the recently developed monoclonal antibody HepPar 1, are often required to aid in distinguishing metastatic HCC from other parotid metastatic tumors.¹²

The current patient, like that reported by Romanas et al., was exceptional in that he presented with metastatic disease in his left parotid gland.¹⁴ Typically, metastases from the liver to the maxillofacial area reach the lungs first, via the hepatic artery and the portal vein, and later reach the maxillofacial area.¹² To explain the parotid localization without lung involvement, it has been suggested that HCC could disseminate into Batson's plexus (a connection between the azygos and hemiazygos veins and the vertebral venous plexus) bypassing filtration through the lungs.¹²

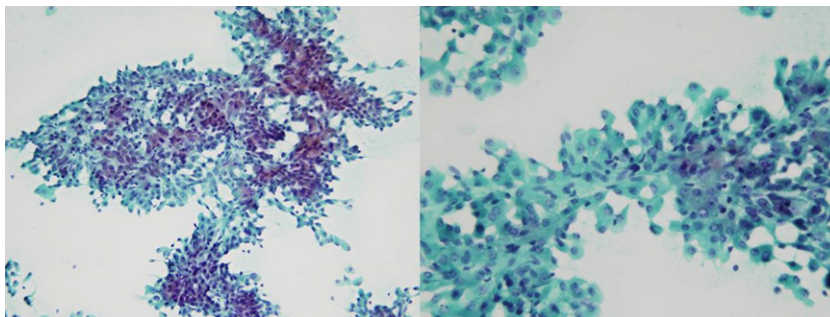


Fig. 4. Parotid fine-needle aspiration (FNA) revealed high cellularity composed of many syncytial fragments of uniformly polygonal tumor cells with low nuclear-cytoplasmic ratio.

Table 1
Summary of four cases of metastatic hepatocellular carcinoma to the parotid gland previously reported and the present case.

Case no.	Age	Sex	Metastatic site	Clinical features	Size	AFP (ng/mL)	Serology	Method of diagnosis	Initial findings of cytology	Time to recurrence	Previous treatment for HCC	Treatment	Other metastatic lesions	Disease progression	Year reported/ reference/ no.
1	62	Male	Left parotid gland	Fever, painful swelling of left mandible	NR	3520	HCV	FNAB	Typical for HCC	Liver lesion detected after parotid lesion	None	Local irradiation and tamoxifen	Bone	NR	1998 ¹³
2	47	Male	Right parotid gland	Tender swollen right lower jaw and preauricular area	4.5 cm on CT	Normal	HCV	FNAB	Typical for HCC	Liver lesion detected after parotid lesion	None	Palliative radiation and chemotherapy	None	Died after 4 months	2004 ¹⁴
3	82	Male	Right parotid gland	Painless, palpable firm mass	3.8 cm on US	NR	NR	Incisional biopsy	Not typical for HCC	Liver lesion detected after parotid lesion	None	No active treatment	None	Died after 6 months	2009 ¹²
4	75	Male	Right parotid gland	Palpable mass	NR	NR	NR	Repeat FNAB	Not typical for HCC	Liver lesion detected after parotid lesion	None	Chemotherapy	Bone	Stable for 2 years	2010 ¹⁵
5	36	Male	Left parotid gland	Painless, palpable firm mass	1.6 cm on CT	Normal	HBV	Excisional biopsy	Not typical for HCC	6 months	RL	Superficial parotidectomy	None	Stable for 1 year	Present case

AFP, alpha-feto protein; NR, not reported; FNAB, fine-needle aspiration biopsy; RL, right lobectomy.

However, the solitary parotid metastasis in this case might have occurred via the lymphatic route, although the exact route is not clear, since the metastatic HCC was found in the lymph node within the parotid gland.

The recurrence of HCC can be detected by an elevated serum AFP or imaging findings.¹⁶ AFP is also known as an independent prognostic factor for HCC and a markedly elevated serum AFP level may reflect advanced HCC in terms of its large size or metastasis.¹⁶ However, on reviewing the four reported cases and the current case of metastatic HCC to the parotid gland (Table 1), the AFP level was not elevated prior to parotidectomy in 2 cases including the present case and the AFP level was not checked in 2 cases. Moreover, the lesion in the liver was detected after parotid metastasis occurred in the previous four cases. Therefore, we believe that without a high suspicion for metastasis, neither the serum AFP nor imaging findings can be a useful indicator of recurrent HCC in the parotid gland.

4. Conclusion

Although rare, since HCC can metastasize to the parotid gland, high suspicion should be maintained in a patient presenting with a parotid mass with a history of HCC. In addition, since potential diagnostic pitfalls in salivary gland FNABs exist, incisional or excisional biopsy may be necessary for definite diagnosis of metastatic HCC to the parotid gland.

Conflict of interest statement

None to declare.

Funding

None.

Ethical approval

Written informed consent was obtained from the patient for publication of this case report and accompanying images. A copy of the written consent is available for review by the Editor-in-Chief of this journal on request.

Author contributions

Dong-Sik Kim, Jeong-Hyeon Lee, and Yang-Seok Chae have made the data collection. Sung-Won Jung and Sung-Ock have performed data analysis. SuhYoung-Dong Yu and Dong-Sik Kim have designed the study and written the manuscript.

References

- Hong SS, Kim TK, Sung KB, Kim PN, Ha HK, Kim AY, et al. Extrahepatic spread of hepatocellular carcinoma: a pictorial review. *European Radiology* 2003;**13**(4):874–82.
- Kim TH, Cheung DY, Chung WB, Son DK, Jo DH, Chung JS, et al. A case of metastatic hepatocellular carcinoma of the ovary. *Korean Journal of Gastroenterology* 2004;**43**(3):215–8.
- Masci G, Magagnoli M, Grimaldi A, Covini G, Carnaghi C, Rimassa L, et al. Metastasis of hepatocellular carcinoma to the heart: a case report and review of the literature. *Tumori* 2004;**90**(3):345–7.
- Frigy AF. Metastatic hepatocellular carcinoma of the nasal cavity. *Archives of Otolaryngology* 1984;**110**(9):624–7.
- Font RL, Maturi RK, Small RG, Garcia-Rojas M. Hepatocellular carcinoma metastatic to the orbit. *Archives of Ophthalmology* 1998;**116**(7):942–5.
- Yamanishi K, Kishimoto S, Hosokawa Y, Yamada K, Yasuno H. Cutaneous metastasis from hepatocellular carcinoma resembling granuloma teleangiectaticum. *Journal of Dermatology* 1989;**16**(6):500–4.
- Yasumatsu R, Okura K, Sakiyama Y, Nakamuta M, Matsumura T, Uehara S, et al. Metastatic hepatocellular carcinoma of the external auditory canal. *World Journal of Gastroenterology* 2007;**13**(47):6436–8.

8. Oida Y, Ishii M, Dowaki S, Tobita K, Ohtani Y, Imaizumi T, et al. Hepatocellular carcinoma with metastasis to the pharynx: report of a case. *Tokai Journal of Experimental and Clinical Medicine* 2005;**30**(1):31–4.
9. Markowski J, Gierek T, Zielinska-Pajak E, Witkowska M, Wodolazski A, Pajak J, et al. Distant metastases to the parotid gland—review of the literature and report of own two cases. *Otolaryngologia Polska – The Polish Otolaryngology* 2005;**59**(4):547–52.
10. Borg MF. Parotid gland as an initial site of metastasis. *Australasian Radiology* 2004;**48**(1):88–92.
11. Nuyens M, Schupbach J, Stauffer E, Zbaren P. Metastatic disease to the parotid gland. *Otolaryngology – Head and Neck Surgery* 2006;**135**(6):844–8.
12. Vitale AR, Compilato D, Coletti G, Calvisi G, Ciuffitelli V, Barbera D, et al. Metastatic hepatocellular carcinoma of the parotid region without lung metastasis: a case report. *International Journal of Oral and Maxillofacial Surgery* 2009;**38**(6):696–8.
13. Dargent JL, Deplace J, Schneider E, Morales J, Kentos A, Willemart S, et al. Hepatocellular carcinoma metastatic to the parotid gland: initial diagnosis by fine needle aspiration biopsy. *Acta Cytologica* 1998;**42**(3):824–6.
14. Romanas MM, Cherian R, McGregor DH, Wu Y, May CL, Baranda JC. Hepatocellular carcinoma diagnosed by fine-needle aspiration of the parotid gland. *Diagnostic Cytopathology* 2004;**30**(6):401–5.
15. Moore FR, Bergman S, Geisinger KR. Metastatic hepatocellular carcinoma mimicking acinic cell carcinoma of the parotid gland: a case report. *Acta Cytologica* 2010;**54**(5 Suppl.):889–92.
16. Lee JM, Park KM, Lee SY, Choi J, Hwang DW, Lee YJ. Metastasis of hepatocellular carcinoma to the ovary: a case report and review of the literature. *Gut Liver* 2011;**5**(4):543–7.

Open Access

This article is published Open Access at scimedirect.com. It is distributed under the [IJSCR Supplemental terms and conditions](#), which permits unrestricted non commercial use, distribution, and reproduction in any medium, provided the original authors and source are credited.