

# Photobiomodulation by helium neon and diode lasers in an excisional wound model: A single blinded trial

Snehil Dixit, Arun Maiya, Laxmi Rao<sup>1</sup>, M. Arjun Rao<sup>2</sup>, Barkur Ananthakrishna Shastry<sup>3</sup>, L. Ramachandra<sup>4</sup>

Department of Physiotherapy, Manipal College Of Allied Health Sciences, <sup>1</sup>Department of Pathology, Kasturba Medical College, <sup>2</sup>Department of Pharmacology, <sup>3</sup>Department of Medicine Kasturba Medical College, <sup>4</sup>Department of Surgery, Manipal University, Manipal, Karnataka, India

## Abstract

**Background:** Application of different kinds of lasers in clinical and experimental studies causes photobiomodulation that works at localized cellular and humoral level on various biological systems. Increased numbers of fibroblasts, myofibroblast, and degranulation of mast cells have been the observed benefits post-irradiation.

**Objective:** Was to find out the effect of irradiation with energy densities of 3.38 J/cm<sup>2</sup>, 8 J/cm<sup>2</sup>, and 18 J/cm<sup>2</sup> on animal tissue (albino wistar rats) in an excisional wound model and to assess changes in biochemical (hydroxyproline) and histopathological levels in excisional wound model.

**Materials and Methods:** The animals were divided into 4 groups, which were labeled as L1, diode laser (18 J/cm<sup>2</sup>), L2 Helium-neon (He-Ne, 8 J/cm<sup>2</sup>), L3 diode laser (3.38 J/cm<sup>2</sup>), and sham treatment for control was depicted by C, respectively. Histological and hydroxyproline analysis was performed on 7, 14, 21 days of post-wounding. One-way analysis of variance, ANOVA and Bonferroni's multiple comparison tests were done for tissue hydroxyproline levels.

**Results:** There was no significant increase in the hydroxyproline content ( $P < 0.005$ ) when observed in study group and compared to controls. Whereas significant epithelizations was seen in group treated with He-Ne laser of intensity of 8 J/cm<sup>2</sup>.

**Conclusion:** The experimental observations suggest that low intensity helium-neon laser of 8 J/cm<sup>2</sup> intensity facilitated photo stimulation by tissue repair, but failed to show significant tissue hydroxyproline levels in excisional wound model.

**Key Words:** Diode lasers, helium-neon laser, wound healing, acute and chronic inflammation

### Address for correspondence:

Dr. Snehil Dixit, MPT, Manipal College of Allied Health Sciences, Department of Physiotherapy, 2<sup>nd</sup> floor, Manipal University, Manipal 576104, Karnataka, India. E-mail: snehildixit83@gmail.com or Snehil.dixit@manipal.edu

Received: 03.12.2011, Accepted: 15.05.2012

Access this article online	
Quick Response Code:	Website: www.advbiores.net
	DOI: 10.4103/2277-9175.100132

## INTRODUCTION

Wound healing requires an integrated series of cellular and biochemical events that restore the structural and functional integrity and regain strength of an injured tissue.<sup>[1]</sup> The pattern of wound healing may be affected by cytokines, endocrines, or by manipulation of wound environment. The circumstance, in which the wound

Copyright: © 2012 Dixit. This is an open-access article distributed under the terms of the Creative Commons Attribution License, which permits unrestricted use, distribution, and reproduction in any medium, provided the original author and source are credited.

**How to cite this article:** Dixit S, Maiya A, Rao L, Rao MA, Shastry BA, Ramachandra L. Photobiomodulation by helium neon and diode lasers in an excisional wound model: A single blinded trial. Adv Biomed Res 2012;1:38.

is sustained, clearly influences what bacteria's are carried or enters as foreign bodies.

Inflammation is a potential response intended to eliminate the initial cause of cell injury as well as necrotic cells and tissue resulting from original insult.

Inflammation can be acute or chronic. Acute inflammation is designed to deliver leukocytes and plasma protein to site of injury. Compromises of vascular changes i.e. alteration in vessel calibration resulting in an increase in blood flow (vasodilatation) and cellular events usually seen as migration of leucocytes from microcirculation and accumulation at the foci of injury.<sup>[2]</sup>

Tissue healing is one of the main claimed effect of laser and focus of varied body of research. Lasers are electromagnetic wave amplifiers, which can produce pencil-like beams of electromagnetic waves with special properties. Helium neon lasers and diode lasers are the commonly used laser in a clinical or experimental scenario. He-Ne lasers are produced in red visible region at 632.8 nm.<sup>[3]</sup> Diode lasers are commonly made of semi-conductive materials, and electrons can flow more readily in one direction. Sometimes, various laser diodes of assorted wavelength are mounted together and used as cluster probes.<sup>[3]</sup> Beneficial effects of laser are now understood, and merits of accelerated healing are cornerstone of laser therapy. However, still there is a dearth in literature regarding the role played by lasers in wound healing.

Hence, in this study, different dosages of laser were used to observe photobiomodulation by laser. The objectives of the present study were to irradiate the animal tissue (albino wistar rats) with different energy densities 3.38 J/cm<sup>2</sup>, 8 J/cm<sup>2</sup>, 18 J/cm<sup>2</sup> and to assess the biochemical (hydroxyproline) and histopathological (capillarity proliferation/neovascularization, fibroblastic proliferation, granulation tissue vascularity and epithelialization) properties in open excisional wound using wistar rat model.

## MATERIALS AND METHODS

An ethical clearance for the study was obtained before the commencement of the experiment by manipal ethical committee. Materials used in the present study were helium-neon laser class 3B with 632.8 nm wave length (150 mW output), class 1 diode laser 660 nm + 950 nm wavelength (235 mW output), class 4 diode laser 660 nm + 950 nm wavelength (865 mW output), and continuous mode with hand held probes [Table 1].

Drugs and surgical materials (alloxan, gloves, solvent ether, ketamine, syringes, and saline from hospital pharmacy), reagents for biochemical investigations (Lobachem chemicals, Germany).

### Animal selection and care

In-house bred albino wistar strain male rats were used in the study. The range of weight of animals is between 170 to 250 gm. All the animals were maintained at less than 12 hours day light environment. In each cage, only one animal was housed. For housing, the animals' sterile propylene cages were used with husk bedding at 22 celsius and humidity 55 ± 5%. The animals were kept in hygienic environment, and the cages were changed every day. All the animals were provided with water and food, standard rat pellet by Mohur Lipton India Ltd. was provided. Breeding and maintenance of animals were done in accordance with the guidelines laid by government of India for use of laboratory animals.

### Grouping

Animals were randomized into experimental and control group had  $n = 6$  animals in each groups i.e. total of 24 animals in 4 groups (3 experimental and 1 control).

### Excisional wound procedures

Animals were assigned into study and control group with 3 animals in each group, comparable in weight and age. The animals were anesthetized with intravenous ketamine of 2 mg/kg weight. The dorsal furs of animals were shaved with blade. Animals were anesthetized prior to and during creation of the wounds. The rats were inflicted with excision wounds as described by Morton and Malone.<sup>[4]</sup> After the dorsal fur of the animals was shaved with a stainless steel blade, the anticipated area of the wound to be created was outlined on the back of the animals with methylene blue using a circular stainless steel stencil. A wound of circular area 5 cm by 5 cm was created with full thickness, 4 cm<sup>2</sup> excisional wound was created using toothed forceps, no. 15 surgical blade, and pointed scissor. Then wound markings were marked on transparency sheets.

The entire wound was left open, and wistar rats were made to stabilize after the surgical procedure was over for at least 2 days.

### Laser therapy protocol

All the equipments were calibrated prior to the study to make sure they deliver an accurate dose during the study protocol. The tissues were irradiated for varying length of time to have a desired influence on the animal's tissue. The dose was calculated according to the formula:  $D = P \times T/A$  ( $D =$  dose in J/cm<sup>2</sup>;  $P =$  laser output in watts;  $T =$  irradiation time in sec;  $A =$  area of wound measured in cm<sup>2</sup>). The low energy He-Ne

laser provides continuous mode of irradiation. Low-level laser therapy was provided through a fiber optic delivery system over the wound for 5 days a week until complete healing.

### Study design

Experimental design: Male albino wistar rats were randomized into 4 groups; L1 (laser group), L2 (laser group), L3 (laser group) and control, each group comprised of 6 albino rats and ( $n = 24$ ) twenty-four in total.

Tissue histology analysis: Group C- Control, group L1-3 optimum laser dose was given after creating an excisional wound model in wistar rats. Animals were sacrificed at 7<sup>th</sup> day, 14<sup>th</sup> day, and 21<sup>st</sup> day after creation of wound.

Biochemical analysis: Group C- Control, group L1-3 optimum laser dose was given after creating an excisional wound model. Animals were sacrificed on 7<sup>th</sup>, 14<sup>th</sup>, and 21<sup>st</sup> day of post-wounding.

## RESULTS

### Tissue histology

Histological samples were analyzed by a pathologist, and blinding was done for the samples to avoid bias for

the results. For histological studies, the animals were euthanized and granulation tissues were collected on 7<sup>th</sup>, 14<sup>th</sup>, 21<sup>st</sup> day post-wounding. Wound specimen together with underlying muscle layers were excised and immediately fixed in bouin's fixative. Tissues were subjected to dehydration with different grades of alcohol, cleared in xylene, and embedded in paraffin wax. Thin sections of 5  $\mu$ m each tissue were stained with haematoxylin-eosin and qualitatively assessed under the light microscope and observed for different parameters related to inflammation and repair. The list of assessing parameters is given in Table 2. Each parameter was graded further as described by McMinn.<sup>[5]</sup>

### Estimation of hydroxyproline

The tissues were collected for estimation on 7<sup>th</sup>, 14<sup>th</sup>, 21<sup>st</sup> day of post-wounding. The tissue was dried in an oven at 60°C, and the dry weight was noted. The acid hydrolysate of the dry tissue was used for the determination of hydroxyproline. To 0.1 mL acid hydrolysate added 0.4 mL of deionised water, 1.0 mL of 2.5 N NaOH, 1.0 mL 0.01 M CuSO<sub>4</sub>, and 1.0 mL 6% hydrogen peroxide. Tubes were covered with marbles and boiled for 15 min at 80°C. Then, 2.0 mL para-methylaminobenzaldehyde (Ehrlicks reagent) and 4.0 mL of 3 N H<sub>2</sub>SO<sub>4</sub> was added.

**Table 1: Illustrating the groups and types of laser being used**

Laser therapy group	Output in J/cm <sup>2</sup>	Number of Albino rats irradiated	Number of exposure	Laser specifications	Wave -emission	Distance from wound spot	Duration of exposure
L 1	18	6	M1, M1'- 6, M2, M2'- 13 M3, M3'- 20	Class 4 diode laser 660 nm + 950 nm wavelength (865 mW power output)	Continuous	1 - 2 mm	9 min
L 2	8	6	M4, M4'- 6 M5, M5'- 13 M6, M6'- 20	Helium Neon laser class 3B with 632.8 nm wave length (150 mW power output)	Continuous	1 - 2 mm	9 min
L 3	3.38	6	M7, M7'- 6 M8, M8'- 13 M9, M9'- 20	Class 1 diode laser 660 nm + 950 nm wavelength (235 mW power output)	Continuous	1 - 2 mm	9 min

\*\* (Note: four groups were there, M1-M12, coding of albino wistar rats in four groups. Groups were labeled as C-control; laser group L1- with 18 J/cm<sup>2</sup>, laser group L2- with 8J/cm<sup>2</sup> and laser group L3- with 3.38 J/cm<sup>2</sup>, nm- nanometer, mW- milliwatts)

**Table 2: Scoring of histological section by McMinn method**

	Laser group-L1	Laser group-L2	Laser group-L3	Control-C
Energy density	18 J/cm <sup>2</sup>	8 J/cm <sup>2</sup>	3.38 J/ cm <sup>2</sup>	No laser
Score	33	29	26	29
Histological impression	Re-epithelialization observed, surface crest formation with mast cells present on 7 <sup>th</sup> day of experiment. Re-epithelialization absent with granuloma formation on 14 <sup>th</sup> and 21 <sup>st</sup> day of the study.	Significant re-epithelialization with healthy granulation tissue on 7 <sup>th</sup> , 14 <sup>th</sup> , and 21 <sup>st</sup> day, crest formation and mast cells observed in all the tissue samples	Re-epithelialization not observed in tissue sections until 14 <sup>th</sup> day, re-epithelialization and mast cells present with scarring on 21 <sup>st</sup> day of experiment.	Presence of surface bacteria on 7 <sup>th</sup> , 14 <sup>th</sup> , and 21 <sup>st</sup> day. Surface neutrophils, and surface re-epithelialization seen on 7 <sup>th</sup> , 14 <sup>th</sup> , and 21 <sup>st</sup> day of the experiment.

\*\* (L1 was irradiated with 18J/cm<sup>2</sup>, L2 with 8J/cm<sup>2</sup>; L3 with 3.38 J/cm<sup>2</sup>; control-C, sham or no treatment was given; scoring done was done according to McMinn method.)

**Table 3: Weight of the sample tissue and collagen content in Laser group and control group**

Serial no	Weight of each sample tissue in mg	Collagen content ( $\mu\text{g}/\text{mg}$ of each tissue)
L1- M1, M1'	50	25.724
M2, M2'	44.6	24.560
M3, M3'	50	13.727
L2- M4, M4'	50	13.871
M5, M5'	26.2	15.853
M6, M6'	40.6	9.158
L3-M7, M7'	50	10.997
M8, M8'	38.2	18.210
M9, M9'	28.3	13.124
Control- M10, M10'	50	6.284
M11, M11'	29.6	14.589
M12, M12'	18.7	11.543

\*\* (mg- milligram,  $\mu\text{g}/\text{mg}$ - microgram per milligram of tissue, laser group L1 was irradiated with  $18\text{ J}/\text{cm}^2$ , laser group L2 with  $8\text{ J}/\text{cm}^2$ ; laser group L3 with  $3.38\text{ J}/\text{cm}^2$ ; control-sham treatment was given. M1-M12 – coding for albino wistar rats)

**Table 4: A comparison within group using one way ANOVA**

Are means significantly different ( $P < 0.05$ )	No		
Number of groups	4		
F	2.864		
Bonferroni's multiple comparison test	Mean difference	P value	95% Confidence interval of difference
C vs. L1	-10.53	$P > 0.05$	-23.81 to 2.742
C vs. L2	-2.155	$P > 0.05$	-15.43 to 11.12
C vs. L3	-3.305	$P > 0.05$	-16.58 to 9.969
L1 vs. L2	8.377	$P > 0.05$	-4.897 to 21.65
L1 vs. L3	7.227	$P > 0.05$	-6.047 to 20.50
L2 vs. L3	-1.15	$P > 0.05$	-14.42 to 12.12

\*\* (No. of groups = 4, groups were labeled as C-control; laser group L1- with irradiation of  $18\text{ J}/\text{cm}^2$ , laser group L2 with irradiation of  $8\text{ J}/\text{cm}^2$  and laser group L3 with irradiation of  $3.38\text{ J}/\text{cm}^2$ )

Incubated at  $80^\circ\text{C}$  for 15 min and the absorbance was read at 540 nm using spectrophotometer.<sup>[6]</sup>

There were 4 groups with 24 wistar rats in total. Results were analyzed using one way ANOVA because there were 4 groups and between the groups, differences were to be known. It showed no difference within groups or on comparison with control [Tables 3 and 4].

## DISCUSSION

### Wound healing is a dynamic process involving series of phases

Inflammatory, proliferative, and maturation phase and is usually dependent on the extent of the tissue damage, host response to the wound, and health of the wound area. Irradiation of wound surface with laser

depends on biological molecules, such as hemoglobin and melanin are particularly strong absorber of visible and infrared radiations.<sup>[7]</sup> Therefore, superficial absorption of laser remains unquestionable. What remains questionable is the effect of laser at depth produces any beneficial effects or not. This further depends on whether the biological process stimulated is sensitive enough to the spectrum of wavelength being used to finally produce any positive effect.

A study done by Jhangiri *et al.* on combination of 670 nm and 810 nm diode lasers for wound healing acceleration in diabetic rats showed no difference in wound parameters in laser or control groups.<sup>[8]</sup> Reddy *et al.* in an experimental study stated that the results from the biochemical analysis indicated that the Gallium-Arsenide (Ga-As) laser used in this study significantly increased wound tensile strain and toughness compared to the control wounds. Marginal increases in wound tensile strength (9%) and stress (7%) were observed in the Ga-As laser-treated wounds compared to the controls. Analysis of wound collagen revealed significant increases in total collagen (14%), salt soluble collagen (31%), acid soluble (14%), and insoluble collagen (50%) with simultaneous decrease in pepsin soluble collagen (19%) in the gallium-arsenide (Ga-As) laser-treated wounds compared to controls. Comparisons of these results with He-Ne lasers revealed its superiority over Ga-As lasers, at the parameters of treatment tested, in promoting the wound healing in diabetic rats.<sup>[9]</sup>

Table 2 shows results of histological section of tissue in experimental and control group, which reveals a distinction in observation and comparison of scores. In control, there was presence of bacterial infection with mild re-epitheliazation post 7<sup>th</sup>, 14<sup>th</sup>, and 21<sup>st</sup> day post-wounding. Whereas there was a clear re-epitheliazation seen in the entire laser-treated group.

Mendez *et al.*, (2004) carried out a study with higher dosage of  $50\text{ J}/\text{cm}^2$  in an experimentally-created wounds in rats that produced more advanced healing from day 3 to day 7.<sup>[10]</sup> Accelerated re-epitheliazation was seen in group L1 with dosage of  $18\text{ J}/\text{cm}^2$ , but there were shortcomings with a higher dosage, which might have caused photo inhibition after a week of irradiation [Table 2].

Mester *et al.* (1985) suggested that any dosage from  $1-4\text{ J}/\text{cm}^2$  is an appropriate dosage for wound healing, but a range of  $1-48\text{ J}/\text{cm}^2$  is used clinically.<sup>[11,12]</sup> Hence, in L3 laser-treated group, a low dosage of  $3.38\text{ J}/\text{cm}^2$  was used to know the effect on wound healing. Re-epitheliazation in this group was absent

till 14<sup>th</sup> day post-wounding and was only seen on 21<sup>st</sup> day. However, the state of inflammation was lower in this group as seen by absence of edema and lower scores for leukocytes. This dosage of laser had a slower effect on re-epithelialization, and scarring was seen on 21<sup>st</sup> day only. A study done by Vijyendra *et al.* in 2011 concluded that a dosage of 2 J/cm<sup>2</sup> was an appropriate optimal dose for tissue histology and hydroxyproline levels.<sup>[13]</sup> Nevertheless, in our study, we didn't have findings supporting the merits of low dosage.

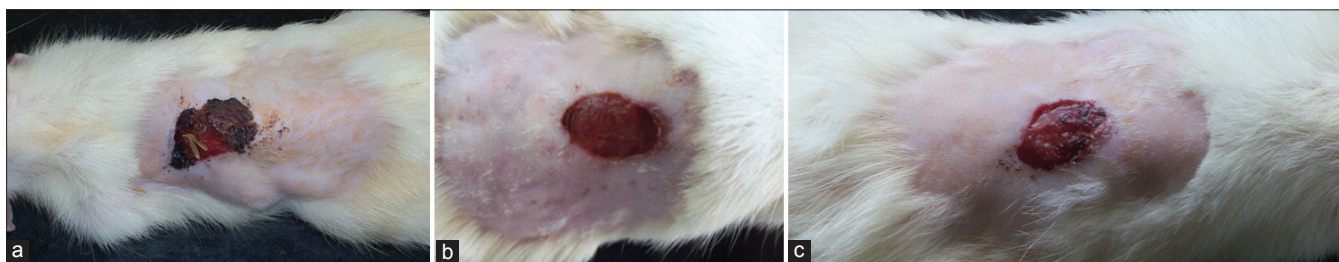
Researchers have postulated in past that at higher dosages of laser, calcium ion imbalance is an important indicator of cell damage and dysfunction. Therefore, the effect of higher spectrum of wavelength in laser with greater power output still needs to be demonstrated. A Cochrane review on effect of low level lasers on venous leg ulcers in human by Flemming and Cullum was inconclusive about the evidence and benefits of low level laser therapy (2001).<sup>[14]</sup> Another review done by Lucas *et al.* in 2002 on wound healing in animals showed that out of 49 outcomes of the studies included, 30 were positive for granulation tissue. However, after excluding methodologically poor studies, 13 out of 21 were negative for evidence of healing.<sup>[15]</sup> Further evidence supporting laser for wound healing is complicated by difference in skin between humans and animals.

In laser group irradiated with 8 J/cm<sup>2</sup> showed a

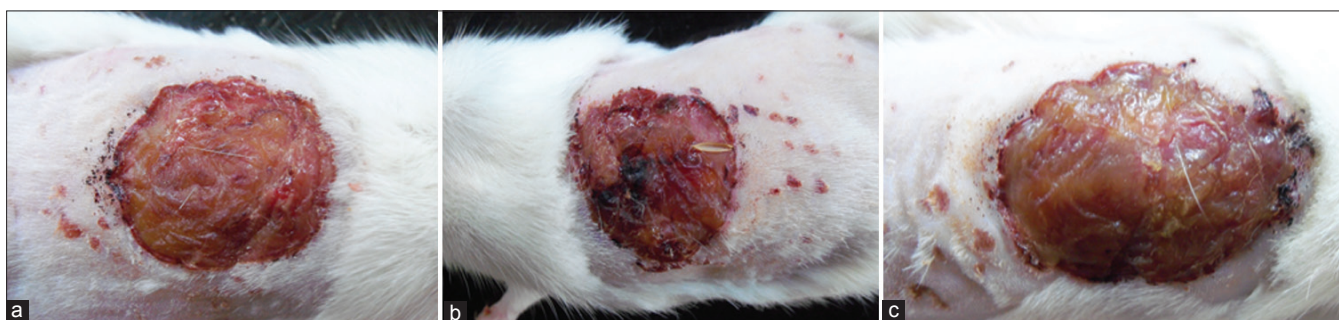lesser inflammation, re-epithelialization post 7 day of irradiation i.e. lower scores for edema and leucocytes, re-epithelialization was marked by 14<sup>th</sup>, and closure of wound site was seen by 21<sup>st</sup> day [Figures 1 and 2]. It has also been claimed that there is a window for an effective photobiostimulation, above threshold, beneficial effect are produced, but if the intensity is too high, the beneficial effects do not occur. The windows are hypothesized to be narrow. Though this concept had been challenged in past by simple statistics, still arndt-schultz law is used to explain the hypothetical narrow 'windows', the effect would be appreciable and positive above some dosage but negative at increasingly higher dosages.<sup>[16]</sup>

In laser group treated with 18 J/cm<sup>2</sup>, re-epithelialization was significant after one week of irradiation but with subsequent sessions of irradiation, the re-epithelialization became negative by 21<sup>st</sup> day. Another shortcoming in this group was development of granuloma on 14<sup>th</sup> day with this dosage. Granuloma is defined as circumscribed, tiny lesions may be due to localized inflammatory mass.<sup>[2]</sup> Usually, formation of granuloma is hypothesized to be a protective defense reaction by host, but eventually causes tissue destruction because of persistent poorly-digested antigen. Another study done with too low dosages resulted in insignificant changes in horses following treatment with 2 J/cm<sup>2</sup> (Peterson *et al.* 1999).<sup>[17]</sup>

Nayak *et al.* in 2007 reported proliferative action



**Figure 1:** Irradiation with energy density 8 J/cm<sup>2</sup>. (a) Figure depicts wound healing on 7th day of irradiation by He-Ne laser with an energy density of 8 J/cm<sup>2</sup>, (b) Figure depicts wound healing on 14th day of irradiation by He-Ne laser with an energy density of 8 J/cm<sup>2</sup>, (c) Figure depicts 21st day of irradiation by He-Ne laser with an energy density of 8 J/cm<sup>2</sup>



**Figure 2:** Control group with no laser irradiation (a) Figure depicts wound healing of control group on 7th day of study, (b) Figure depicts wound healing of control group on 14th day of the study, (c): Figure depicts wound healing of control group on 21st day of study

of He-Ne laser at the dosage of 2.1 J/cm<sup>2</sup>, which demonstrated an increase in hydroxyproline levels that is a reflection of collagen content in the tissue.<sup>[4]</sup> Similar findings were reported by Vijendra *et al.* in 2011; their samples were taken on 5<sup>th</sup>, 10<sup>th</sup>, and 15<sup>th</sup> day of post-wounding with single exposure of He-Ne laser with same dosage.<sup>[13]</sup> Findings of the previous studies did not correlate with the results in our study, we didn't find significant changes in the tissue hydroxyproline levels in either laser treated, or in sham-treated group.

## CONCLUSION

In present study, we investigated the dose response of He-Ne and diode lasers on animal tissue to observe the resultant cell response. The experimental observation suggests that low intensity He-Ne laser of 8 J/cm<sup>2</sup> intensity facilitated photo stimulation by tissue repair, but failed to show any tissue hydroxyproline changes in an excisional wound model. The results indicate that He-Ne laser resulted in more stimulatory effect than diode lasers. From the histopathological examination, we can conclude that 8 J/cm<sup>2</sup> of He-Ne lasers appear to be the threshold dosage for an enhanced regeneration of tissue and reduced inflammation.

## Future recommendation

However, 8 J/cm<sup>2</sup> appears to have a better response to granulation tissue post-wounding for histological section. A 3-day irradiation frequency with 18 J/cm<sup>2</sup> may be incorporated for histopathological and biochemical analysis in a diabetic excisional model for wound healing, which might be useful to augment rate of healing in acute and chronic wounds.

## ACKNOWLEDGMENTS

The present study is being carried out under the project, no. entitled, "5/3/8/41/2007 RHN". This study is a part of ongoing project funded by Indian Council of Medical Research (ICMR), under government of India. The authors are grateful to Mr. Sridhar, Animal house facility, KMC, Manipal University for his help during the study. The authors also thank Dr. Padmanabha Udupa, Professor,

Department of Biochemistry for his support and encouragement during the study.

## REFERENCES

1. Henry M, Thompson J. Wound healing and management. Clinical Surgery. 2nd edn. London: Elsevier Saunders Limited; 2002. p. 105-13.
2. Kumar V, Abul AK, Nelson F, Richard M. Acute and chronic inflammation. Robbins Basic Pathology, 8th edition. New Delhi: Reed Elsevier India private limited; 2007. p. 31-58.
3. Robertson V, Ward A, Low J, Reed A. Infrared and visible radiations. Electrotherapy explained principles and practice. 4th ed. Noida: Reed Elsevier India Private limited; 2009. p. 459-98.
4. Morton JJ, Malone MH. Evaluation of vulnerary activity by an open wound procedure in rats. Arch Int Pharmacodyn Ther 1972;196:117-26.
5. McMinn RH, Pritchard JJ. Tissue repair. New York and London: Academic Press; 1969:1-40.
6. Nayak BS, Maiya A, Kumar P. Influence of helium-neon laser photostimulation on excision wound healing in wistar rats. Online J Biol Sci 2007;7:89-92.
7. Sullivan S, Schmitz T. Vascular, lymphatic and integumentary disorders. Physical rehabilitation, 5th ed. Philadelphia: FA Davies Company; 2001. p. 643.
8. Jahangiri Noudeh Y, Shabani M, Vatankhah N, Hashemian SJ, Akbari K. A combination of 670 nm and 810 nm diode lasers for wound healing acceleration in diabetic rats. Photomed Laser Surg 2010;28:621-7.
9. Reddy GK. Comparison of the photostimulatory effects of visible He-Ne and infrared Ga-As lasers on healing impaired diabetic rat wounds. Lasers Surg Med 2003;33:344-51.
10. Mendez TM, Pinheiro AL, Pacheco MT, Nascimento PM, Ramalho LM. Dose and wavelength of laser light have influence on the repair of cutaneous wounds. J Clin Laser Med Surg 2004;22:19-25.
11. Mester E, Mester AF, Mester A. The biomedical effects of laser application. Lasers Surg Med 1985;5:31-9.
12. Mester E, Spiry T, Szende B, Tota JG. Effect of laser rays on wound healing. Am J Surg 1971;122:532-5.
13. Vijendra P, Rao SBS, Kumar P, Rao L, Mahato KK. Photobiomodulatory effects of He-Ne laser on excision wounds. Proc of SPIE 2011;7887.
14. Flemming K, Cullum NA. Laser therapy for venous leg ulcers. Cochrane Database Syst Rev 1999.
15. Lucas C, Poublon C, Cockrell C, Haan RJ. Wound healing in cell studies and animal experimental mode by Low level Laser therapy were clinically justified? A systematic review. Lasers Med Sci 2002; 17:100-34.
16. Sommer AP, Pinheiro AL, Mester AR, Franke RP, Whelan HT. Biostimulatory windows in low-intensity laser activation: Lasers, scanners, and NASA's light-emitting diode array system. J Clin Laser Med Surg 2001;19:29-33.
17. Petersen SL, Botes C, Olivier A, Guthrie AJ. The effect of low level laser therapy (LLLT) on wound Healing in Horses. Equine Vet J 1999;31:228-31.

**Source of Support:** Indian Council of Medical Research, **Conflict of Interest:** None declared.