

Sir,
Ranibizumab for the management of Sorsby fundus dystrophy

Sorsby fundus dystrophy is a rare retinal dystrophy of autosomal-dominant inheritance characterized by central vision loss before the fifth decade of life, secondary to

choroidal neovascularization (CNV) and/or pigment epithelium atrophy. The natural history of the condition involves early development of lesion fibrosis.¹ The genetic background of the disease resides in a mutation in the tissue inhibitor of metalloproteinase 3 (TIMP3) gene.² We report here a case of Sorsby fundus dystrophy successfully treated with repeated injections of ranibizumab.

Case report

The 41-year-old patient presented in January 2007 with sudden onset distortion of vision in his left eye. Visual acuity was 6/5 OD and 6/18 OS on Snellen chart. Fluorescein angiography revealed OS occult CNV. No treatment was administered, and in October 2007, an extensive macular hemorrhage developed with vision dropping to 6/60. Despite a single session of verteporphin photodynamic treatment in November 2007, the lesion relentlessly progressed to a disciform scar. In April 2009, the patient developed distortion in his right eye with 6/36 vision. A classic subfoveal CNV was identified. DNA analysis revealed the presence of mutation c.610A>T (p.Ser204Cys) in exon 5 of the TIMP3 gene and confirmed the diagnosis of Sorsby fundus dystrophy. After his first intravitreal injection of ranibizumab to the right eye in May 2009 (Figure 1a), vision improved to 6/15. He received 14 injections of ranibizumab for persistent intraretinal fluid identified on optical coherence tomography until February 2011, at which point disease quiescence was established (Figures 1b and 2). Visual acuity stabilized at 6/15 without disease reactivation 6 months thereafter (Figure 1c).

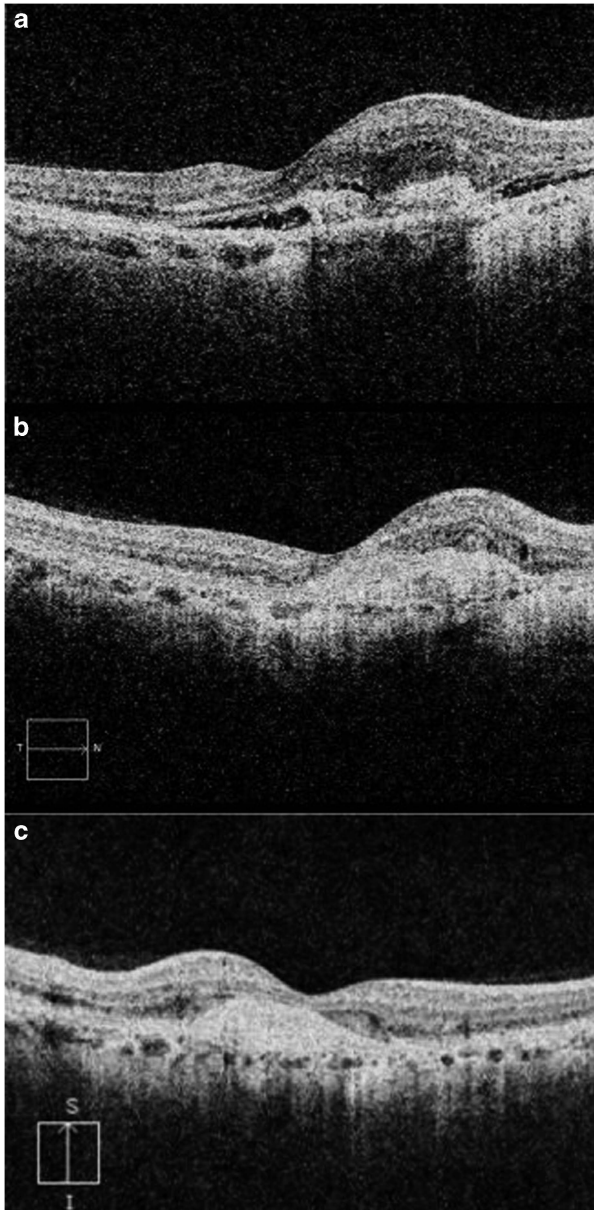


Figure 1 OCT frames OD, pretreatment, posttreatment, and 6 months after the last injection. (a) OCT frame OD, May 2009 (time of the first injection), showing active CNV with subretinal fluid. (b) OCT frame OD, February 2011 (time of last injection), showing subretinal fibrosis without subretinal fluid. There is a minimal residual intraretinal cyst. (c) OCT frame OD, August 2011 (6 months after last injection), confirming continuous disease quiescence.

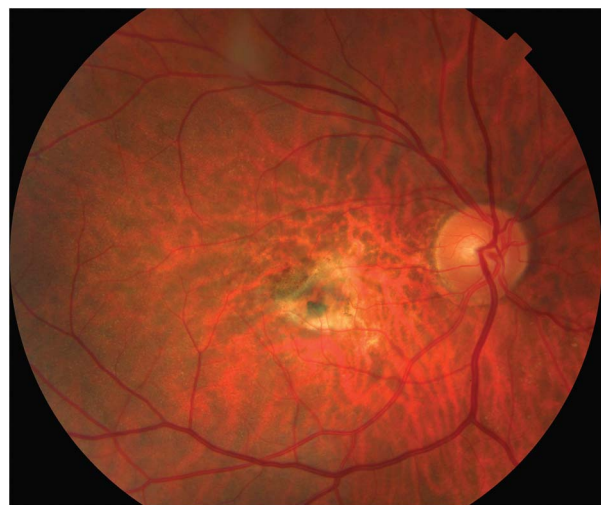

Figure 2 Color Fundus Image OD, February 2011 (time of last injection), revealing fibrosed CNV adjacent to spared functional retina that includes the foveal region justifying preserved visual acuity.

Comment

Therapeutic management of CNV in Sorsby fundus dystrophy remains challenging. Treatment options reported on a limited number of case series include argon laser photocoagulation, PDT alone or in combination with intravitreal triamcinolone and intravitreal bevacizumab.¹ Aggressive recurrence has been reported for extrafoveal CNV treated with argon laser,³ while PDT treatment for subfoveal CNV was ineffective.⁴ Few reports of the use of intravitreal¹ or systemic⁵ bevacizumab have claimed moderate benefit. To our knowledge, this is the first report of the use of ranibizumab in Sorsby fundus dystrophy, with excellent response and long-standing favorable visual outcome. We also would like to draw attention to the extra benefit of effective treatment for CNV in Sorsby fundus dystrophy, in terms of more time spent in active employment, as this condition predominantly affects patients in the productive age range.

Conflict of interest

The authors declare no conflict of interest.

Acknowledgements

This work was supported by the NIHR Manchester Biomedical Research Centre.

References

- 1 Sivaprasad S, Webster A, Egan C, Bird A, Tufail A. Clinical course and treatment outcomes of Sorsby fundus dystrophy. *Am J Ophthalmol* 2008; **146**: 228–234.
- 2 Weber BH, Vogt G, Pruett RC, Stohr H, Felbor U. Mutations in the tissue inhibitor of metalloproteinases-3 (TIMP3) in patients with Sorsby's fundus dystrophy. *Nat Genet* 1994; **8**: 352–356.
- 3 Holz FG, Haimovici R, Wagner DG, Bird AC. Recurrent choroidal neovascularization after laser photocoagulation in Sorsby's fundus dystrophy. *Retina* 1994; **14**: 329–334.
- 4 Peiretti E, Klancknik JM Jr, Spaide RF, Yannuzzi L. Choroidal neovascularization in Sorsby fundus dystrophy treated with photodynamic therapy and intravitreal triamcinolone acetonide. *Retina* 2005; **25**: 377–379.
- 5 Prager F, Michels S, Geitzenauer W, Schmidt-Erfurth U. Choroidal neovascularization secondary to Sorsby fundus dystrophy treated with systemic bevacizumab (Avastin). *Acta Ophthalmol Scand* 2007; **85**(8): 904–906.

K Balaskas, M Hovan, S Mahmood and P Bishop

Central Manchester University Hospitals NHS Foundation Trust, Manchester Academic Health Science Centre, Manchester, UK
E-mail: konstantinos.balaskas@gmail.com

Eye (2013) **27**, 101–102; doi:10.1038/eye.2012.221;
published online 26 October 2012

Sir, Topical dorzolamide therapy for taxane-related macular oedema

The taxane class of drugs (eg, paclitaxel (Taxol), paclitaxel nanoparticle albumin bound (NAB) (Abraxane), docetaxel (Taxotere)) are microtubule-stabilizing agents that are used to treat numerous malignancies. Cystoid macular oedema (CME) without increased permeability is a rare side effect of these medications.^{1–3} In the following report, non-leaking CME secondary to paclitaxel–NAB was successfully treated with off-label use of topical 2% dorzolamide (Trusopt) in conjunction with cessation of the chemotherapy agent. A monocular treatment trial suggested more rapid resolution with dorzolamide compared with drug cessation alone.

Case report

A 59-year-old female with metastatic breast cancer presented with decreased vision following paclitaxel–NAB infusion. The visual acuity was 20/50 in both eyes. Fundus examination and diagnostic testing revealed bilateral non-leaking CME (Figures 1, 2a and b). A monocular trial of dorzolamide three times daily was initiated in the right eye. Paclitaxel–NAB was also stopped. Two weeks later, OCT showed marked reduction of CME ($-114\ \mu\text{m}$) in the treated eye compared with the fellow eye ($+28\ \mu\text{m}$) (Figures 2c and d). Given the improvement, bilateral dorzolamide was initiated. One month later, near-complete resolution of CME was noted in both eyes with visual acuity improvement to 20/20. (Figures 2e and f).

Comment

This report suggests a possible therapeutic efficacy for topical carbonic anhydrase inhibitors in the treatment of taxane-induced CME. Although the paclitaxel–NAB was stopped, topical dorzolamide resulted in a rapid decrease in oedema in the treated eye compared with the untreated eye. Once bilateral therapy was initiated, rapid resolution of oedema occurred. Though this report suggests a monocular response to dorzolamide therapy, asymmetric spontaneous resolution cannot be ruled out. Topical dorzolamide has been reported to decrease oedema for non-leaking CME from other conditions (eg, retinitis pigmentosa, X-linked retinoschisis).^{4,5}

As in this case, all previous reports of taxane-related CME have included cessation of the drug. In some cases, drug cessation may not be appropriate. Although systemic acetazolamide has also been reported for treating taxane-related CME, the topical use of dorzolamide may be a useful treatment alternative given its limited systemic side effects.² Further research is needed to better understand the role for topical dorzolamide therapy in this condition. This report highlights the importance of ophthalmic