

## OTOLOGY

# Ossicular chain lesions in cholesteatoma

## *Danni della catena ossiculare nell'otite cronica colesteatomatosa*

R. ALBERA, A. CANALE, E. PIUMETTO, M. LACILLA, F. DAGNA  
ENT Department, San Giovanni Battista Hospital, Turin, Italy

## SUMMARY

The aim of the study was to describe ossicle resorption in chronic otitis with cholesteatoma and correlate it with clinical parameters such as age, contralateral ear condition, tympanic membrane aspect, cholesteatoma pathogenesis and extension, associated lesions and hearing threshold. Preoperative clinical data were collected for 140 patients with chronic otitis with cholesteatoma, whose ossicles were evaluated during surgery. 82% of patients showed ossicle resorption, with incus damage in 78% of cases. Multiple involvement was found in 45% of cases and the incus-stapes association was the most frequent. In 13 patients (11%) with ossicle damage, the ossicular chain was in continuity with a hearing threshold similar to patients without ossicular resorption. Ossicles were always damaged in congenital cholesteatoma and in case of associated lesions. Cholesteatoma extension was related to the incidence of ossicle resorption ( $p < 0.0001$ ). Air and bone conduction worsened as the number of involved ossicles increased, while the air-bone gap remained stable. In conclusion, the origin and location of cholesteatoma are related to the site of ossicular damage, which is subsequent to the contact between bone and cholesteatoma. Pure-tone audiometry and air-bone gap do not reflect actual ossicular chain status. None of the other preoperative clinical parameters considered were reliable predictors of the condition of the ossicular chain.

KEY WORDS: Cholesteatoma • Chronic otitis • Ossicular chain

## RIASSUNTO

*Lo scopo dello studio è stato descrivere i danni della catena ossiculare nelle otiti croniche colesteatomatose correlandoli a parametri clinici quali età, condizione dell'orecchio controlaterale, reperto otoscopico, patogenesi ed estensione del colesteatoma, presenza di lesioni associate, soglia uditiva. Sono state raccolte le suddette informazioni per 140 pazienti con otite cronica colesteatomatosa la cui catena ossiculare è stata valutata durante l'intervento chirurgico. L'82% mostrava danni agli ossicini, con un coinvolgimento dell'incudine nel 78% dei casi. Un coinvolgimento multiplo era evidente nel 45% dei casi, interessante l'incudine e la staffa nella maggior parte dei casi. La catena ossiculare di 13 pazienti (11%), benché danneggiata, risultava funzionalmente integra garantendo una soglia uditiva pari a quella dei pazienti con ossicini normali. La catena ossiculare era sempre danneggiata nei colesteatomi congeniti e quando presenti lesioni associate. L'estensione del colesteatoma era correlata all'incidenza di rimaneggiamento degli ossicini ( $p < 0,0001$ ). Il peggioramento della via area ed ossea era proporzionale al numero di ossicini coinvolti, ma il gap aereo-osseo risultava sostanzialmente stabile. conclusione sulla base dei nostri dati è stato possibile stabilire una correlazione fra l'origine e la localizzazione del colesteatoma e il sito di danneggiamento della catena ossiculare legato al contatto tra tessuto patologico e osso. Inoltre l'audiometria tonale e il gap aereo-osseo non riflettevano il reale stato della catena ossiculare. Infine nessuno dei parametri preoperatori considerati è risultato predittivo della reale condizione della catena ossiculare.*

PAROLE CHIAVE: Colesteatoma • Otite cronica • Catena ossiculare

Acta Otorhinolaryngol 2012;32:309-313

## Introduction

Cholesteatoma may be defined as skin in the wrong place<sup>1</sup>, which causes middle ear chronic inflammation, leading to ossicles and bone erosion. Chronic otitis with cholesteatoma is divided into congenital and acquired forms. The former is more frequent in young patients and is caused by skin growth behind the eardrum since birth. The latter is more frequent in adults and originates from tympanic retraction pockets or from migration of skin through perforations of the tympanic membrane into the middle ear<sup>4,6</sup>. The incidence of cholesteatoma ranges from 3/100,000 in children to 9/100,000 in adults<sup>3</sup>.

It is well acknowledged that skin in cholesteatoma differs histologically from normal skin, showing a matrix of squamous keratin stratified epithelium with a connective envelope (peri-matrix), separated by an inflammatory layer rich in lymphocytes and mast cells which are thought to play a major role in both symptoms and complications<sup>11</sup>. Some recent studies tried to explain the molecular characteristics in cholesteatoma. High levels of caspase-14 mRNA may explain its aberrant terminal differentiation<sup>7</sup>; the expression of p63, a p53 homologue, and survivin, an inhibitor of apoptosis, suggests a common origin with tumours<sup>8,9</sup>; chromosome copy number alterations relate to a more or less aggressive behaviour<sup>10</sup>. Although cholest-

eatoma has been studied from multiple points of view, its aetiology and pathogenesis remain unclear.

At clinical examination, chronic otitis with cholesteatoma usually presents with recurrent otorrhea and hearing impairment, often conductive, due to erosion of the middle ear ossicles. This happens for two main reasons: chronic inflammation, which leads to cytokine release and osteoclast activation, and pressure necrosis, caused by cholesteatoma expansion <sup>11</sup>.

The air-bone gap (ABG) in patients affected by chronic otitis media has been related to ossicular chain condition by some authors: in particular, narrow ABG would suggest ossicle integrity, whereas wide ABG would predict ossicular erosion <sup>2</sup>. However, it is widely known that pathological tissue can transmit sounds replacing the damaged ossicles <sup>12</sup>; therefore, pure-tone audiometry (PTA) does not always show the real state of the ear transmission system. Moreover, these patients can also show signs of inner ear damage with sensorineural hearing loss (SNHL) <sup>13</sup>.

Although knowing the functional status of the affected ear would be crucial to plan surgery, in association with HRCT scan, they are not reliable clinical parameters which reflect the actual ear condition evaluated during surgery. If the main goal of surgery is to completely remove the pathological tissue, trying to minimize the risk of recurrence, it is indisputably true that treating cholesteatoma complications and preserving or even improving preoperative hearing level is of great importance.

The aim of this study was to describe the ossicular chain defects in chronic otitis with cholesteatoma and to correlate them with hearing function and clinical parameters such as cholesteatoma extension and its pathogenesis, age, PTA threshold, contralateral ear condition, eardrum aspect and presence of other complications.

## Materials and methods

The study group was composed of 140 patients affected by middle ear chronic otitis with cholesteatoma and submitted to surgery between 2004 and 2009. Subjects who had already been operated on the same ear were excluded from the study.

Age ranged from 3 to 78 years (mean age 37); 91 (65%) were males and 49 (35%) females. There were 66 right ears (47%) and 74 left ears (53%) evaluated.

Assessment of data was carried out during tympanoplasty and recorded after surgery filling a standard form for each patient; in order to gain a uniform evaluation of data, we included only subjects operated on by the same surgeon (first author).

The day before surgery each subject underwent otologic evaluation based on otoscopy, micro-otoscopy and pure-tone audiometry (PTA) carried out in a soundproof chamber at the frequency range 0.25 - 8 kHz. In each case, CT scan was requested at diagnosis.

In each patient, we carefully evaluated the condition of the ossicular chain in order to determine the presence and site of lesion of each ossicle. In case of integrity of the ossicular chain, we manually checked its mobility.

We evaluated the following parameters for each patient:

- age;
- condition of the contralateral ear: normal or affected by chronic otitis;
- pathogenesis of cholesteatoma: congenital, retraction or migration cholesteatoma;
- tympanic membrane aspect: considered on the basis of the site of retraction (posterior pars tensa, atelectasis, anterior epitympanic retraction, posterior epitympanic retraction, total epitympanic retraction) or of the site of perforation in migration cholesteatoma;
- extension of cholesteatoma: we considered the extension of cholesteatoma on the basis of its presence in the atrium, atticus and antrum; results were evaluated even on the basis on the number of sites interested by pathology;
- presence of associated lesions such as labyrinthine fistula or tympanic facial dehiscence with epidermization;
- PTA threshold.

Distribution of clinical parameters are shown in Table I.

Air conduction (AC) and bone conduction (BC) thresholds and ABG refer to mean values at 0.5-1-2-4 kHz.

Statistical evaluation of data was carried out with SPSS software, and a p level of 0.05 was considered to be statistically significant. All patients gave their informed consent prior to inclusion in the study.

## Results

Ossicular chain defects were observed in 115 of 140 patients (82%). The malleus was involved in 28 cases (20%), incus in 109 (78%) and stapes in 41 (29%). In 52 cases (45%), more than one ossicle was involved. In these cases,

**Table I.** Clinical data.

<b>Contralateral ear</b>			
Normal	79 (56%)		
Chronic otitis	61 (44%)		
<b>Tympanic membrane</b>			
Normal	12 (8%)	Posterior attical retraction	9 (7%)
Atelectasis	13 (9%)	Anterior attical retraction	10 (8%)
Posterior perforation	12 (8%)	Total attical retraction	10 (8%)
Subtotal perforation	7 (5%)	Posterior pars tensa retraction	67 (47%)
<b>Pathogenesis</b>		<b>Cholesteatoma extension</b>	
Congenital	12 (9%)	Atrium	59 (42%)
Migration	16 (11%)	Atrium- atticus	53 (38%)
Retraction	112 (80%)	Atrium-atticus-antrum	28 (20%)
<b>Other lesions</b>			
None	117 (83%)	Cochlea	1 (1%)
HSC	4 (3%)	Facial nerve	8 (6%)
SSC	1 (1%)	HSC-Facial nerve	9 (6%)

the association of incus and stapes was the most frequently. The pattern of ossicular lesions is reported in Figure 1.

In 13 of the 115 patients affected by ossicular chain lesions (11%), despite the presence of partial bone erosion, the ossicular chain was functionally in continuity. In these patients, the ossicular lesions were located at the head of malleus in 1 case (8%), at the body of the incus in 8 cases (61%), at the anterior crus of the stapes in 1 case (8%) and together at the head of the malleus and body of the incus in 3 cases (23%) (Fig. 2).

Among the 25 patients (18%) with no ossicular lesions, we found a stiffness of incus and/or malleus in 5 cases (20%) and stapes footplate fixation in 1 (3%). A footplate fixation was also observed in 7 patients affected by ossicular chain lesions (6%). Bone defects, classified on the basis of the part interested by resorption in each element of the ossicular chain, are summarized in Table II.

The second aim of this study was to determine the relations between ossicular chain defects and the clinical parameters considered. There was no significant difference in age ( $p > 0.05$  at chi-square test) since subjects with ossicular lesions had a mean age of 38 years (SD 20) versus a mean age of 33 years (SD 20) in the group without lesions.

The distribution of the ossicular chain lesions did not differ significantly, with a chi-square test, independently of the condition of the other ear, origin of cholesteatoma, aspect of the tympanic membrane, presence of otorrhea and other lesions (i.e. epithelization of the facial nerve, otic capsule fistula etc.) (Table III). Only a wider extension of cholesteatoma, expressed as the number of sites involved, was significantly associated with a higher incidence of ossicular chain lesions ( $p < 0.0001$ , chi-square test).

Beyond the results of statistical analysis, conditioned by the relatively low number of cases without lesions, it is interesting to observe that the chain was always damaged in congenital cholesteatoma, in those cases in which the cholesteatoma involved all three sites considered (atrium, atticus and antrum) and in the presence of other associated lesions, such as horizontal canal fistula or facial nerve involvement. All cases presenting normal eardrum presented an ossicular lesion since they concealed congenital cholesteatomas.

Total resorption of the malleus was more frequently found in presence of tympanic atelectasis, which was seen in 40% of these cases, while resorption of the head was more frequently found in attic retractions (70% of these cases) and handle resorption in pars tensa retractions (75% of these cases). Total resorption and long apophysis resorption of the incus were more frequently found in the pres-

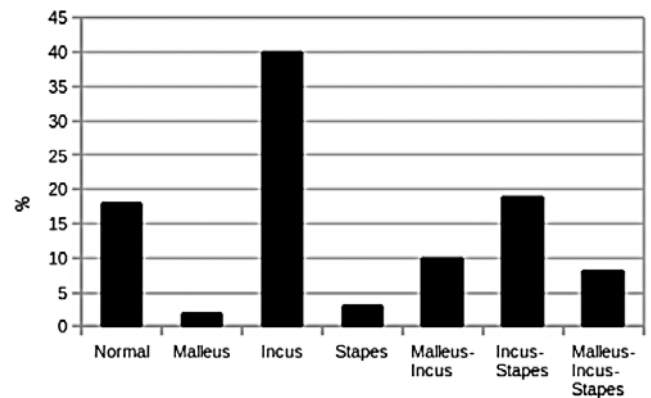


Fig. 1. Distribution of ossicular lesions.

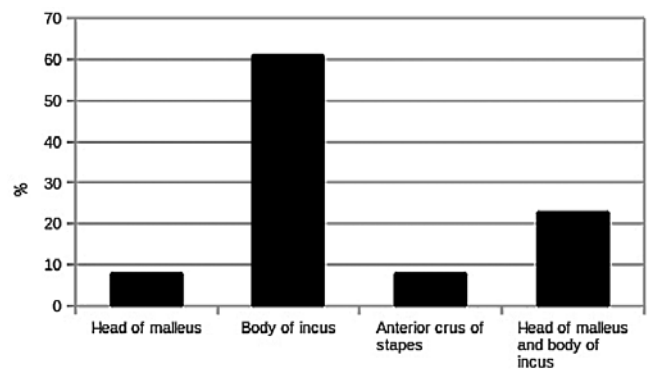


Fig. 2. Distribution of ossicle lesions in patients with normal ossicular chain function.

ence of pars tensa retractions (respectively, 55% and 60% of these cases), while body resorption was found only in attic retractions. Stapes resorption was more frequently observed in pars tensa retractions (40% of these cases). Subjects affected by ossicular chain defects had a significantly worse air conduction threshold, bone conduction threshold and air-bone gap by the Student's *t* test (Table IV). The 13 patients with ossicular lesions but without chain discontinuity had hearing thresholds similar to those who had a normal ossicular chain.

In Table V, PTA values in relation to the kind of ossicular lesions are reported. AC and BC thresholds were more impaired in the case of stapes erosion and, above all, if all three ossicles were damaged, whereas ABG differences were less related to the extension of ossicular chain erosion. This pattern is clearly shown in Figure 3 in which mean PTA thresholds are divided according to the number of damaged ossicles. In case of three damaged ossicles, air and bone conduction were more impaired while the air-bone gap remained relatively stable.

## Discussion

The aim of this study was, firstly, to describe ossicle defects in

Table II. Distribution of lesions in each ossicle.

Malleus	n (%)	Incus	n (%)	Stapes	n (%)
No lesion	112 (80%)	Normal	31 (22%)	Normal	99 (71%)
Head	14 (10%)	Body	5 (4%)	Crura	41 (29%)
Handle	4 (3%)	Long process	61 (45%)		
Absence	10 (7%)	Absence	43 (31%)		

**Table III.** Relationship between clinical parameters and condition of the ossicular chain.

Other ear	Normal ossicular chain	Eroded ossicular chain
Normal	11 (18%)	68 (82%)
Chronic otitis	14 (23%)	47 (77%)
		p > 0.05
Pathogenesis of cholesteatoma		
Congenital	0 (0%)	12 (100%)
Migration	3 (19%)	13 (81%)
Retraction	22 (20%)	90 (80%)
		p > 0.05
Aspect of the tympanic membrane		
Normal	0 (0%)	12 (100%)
Posterior perforation	2 (17%)	10 (83%)
Subtotal perforation	1 (14%)	6 (86%)
Anterior attic retraction	4 (40%)	6 (60%)
Posterior attic retraction	2 (22%)	7 (78%)
Total attic retraction	0 (0%)	10 (100%)
Posterior pars tensa retraction	15 (22%)	52 (78%)
		p > 0.05
Number of sites involved		
1	20 (34%)	39 (66%)
2	5 (9%)	48 (91%)
3	0 (0%)	28 (100%)
		p < 0.0001*
Otorrhea		
No	16 (23%)	52 (77%)
Yes	9 (12%)	63 (88%)
		p > 0.05
Other lesions		
No	25 (21%)	92 (79%)
Yes	0 (0%)	23 (100%)
		p > 0.05

cholesteatoma and, secondly, to correlate these with clinical parameters. Chronic otitis with cholesteatoma is a subtle disease whose main symptoms are otorrhea and hearing loss related to ossicle erosion. This is one of the main issues when managing patients affected by cholesteatoma since, as some previous studies have pointed out<sup>14-17</sup>, more than two-thirds show ossicular defects. In our sample, 115 of 140 enrolled patients (82%) showed some type of ossicular chain damage, and the incus was the most frequently involved ossicle (78%). In 45% of patients, we observed more than one lesion; in this case, the involvement of the incus and stapes was most frequently present. As expected, disease extension was significantly related to ossicular chain defects. The chances to have a normal chain were 34%, 9% and 0%, respectively, when 1, 2 or 3 middle ear sites were involved.

Concerning the site of lesion of ossicles, we found a close correlation between the origin of cholesteatoma and the part of the ossicle damaged. Therefore, the head of the malleus and the body of the incus were involved mostly

**Table IV.** Relationship between hearing level and condition of the ossicular chain.

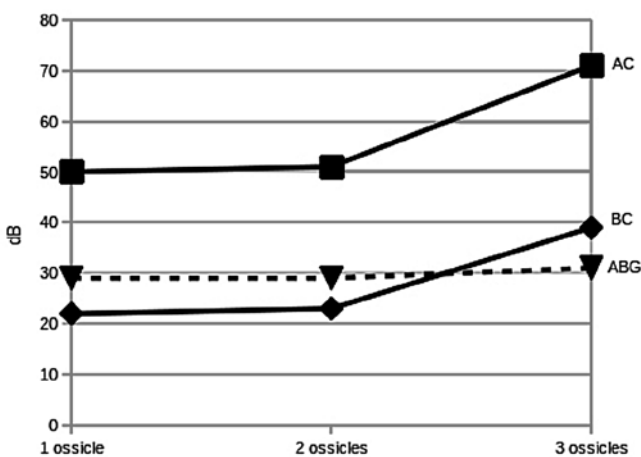
Ossicular chain condition (n)	AC (SD)	BC (SD)	ABG (SD)
Normal (35)	36 (20)	18 (13)	19 (12)
Pathological with integrity (13)	34 (13)	16 (5)	17 (10)
Pathological without integrity (102)	54 (18)	26 (17)	28 (12)
p	<0.0001*	<0.05*	<0.0001*

AC = air conduction; BC = bone conduction; ABG = air-bone gap. Values, expressed in dB, represent the average threshold at 0.5-1-2-4 kHz at pure-tone audiometry; standard deviation (SD) values in brackets. Differences are significant by chi-square test ( ).

**Table V.** Relationship between hearing level and type of ossicular chain defect in the 102 patients who showed ossicular chain lesions.

Ossicular chain condition (n)	AC (SD)	BC (SD)	ABG (SD)
Malleus (3)	48 (18)	18 (5)	30 (15)
Incus (48)	48 (18)	23 (14)	25 (10)
Stapes (3)	58 (6)	29 (8)	29 (8)
Malleus-incus (11)	49 (22)	24 (12)	25 (13)
Incus-Stapes (26)	53 (16)	24 (17)	30 (15)
Malleus-Incus-Stapes (11)	71 (18)	39 (30)	32 (16)
p	<0.0001*	<0.05*	<0.05*

AC = air conduction; BC = bone conduction; ABG = air-bone gap. Values, expressed in dB, represent the average thresholds at 0.5-1-2-4 kHz at pure-tone audiometry; standard deviation (SD) in brackets. Differences are significant by chi-square test ( ).



**Fig. 3.** Hearing thresholds in relation to the number of involved ossicles.

in attic retractions, while atelectasis and pars tensa retractions largely determined the resorption of the long process of the incus and the resorption of the malleus.

We observed that ossicular chain suffering was not always associated with chain discontinuity. In fact, 11% of our patients presented normal hearing yet had chain lesions located far from the articulations between ossicles involving the head of the malleus, the body of the incus and one crus of the stapes. In contrast, we found stiffness of the chain due to sclerotic reactions to chronic otitis in some cases without ossicular lesions.

The presence of ossicular lesions was not related to age, condition of the other ear, origin of cholesteatoma or the

presence of otorrhea. The only parameter that correlated with ossicular defects was the extension of cholesteatoma since in case of mastoid antrum involvement an ossicular defect was always found. We have no information about disease duration, but greater cholesteatoma extension certainly expresses a longer disease or a more aggressive pathology, such as in younger patients or in congenital cholesteatoma, which more often determines ossicular lesions<sup>3</sup>. The origin of cholesteatoma and its location affect the site of ossicular lesions since atrial suffering correlates with resorption of handle of malleus, long process of the incus and crura of the stapes; on the other hand, attic cholesteatoma leads to suffering of the head of the malleus and the body of the incus. Therefore, this suggests that ossicle resorption is subsequent to the contact with cholesteatoma and not to other phenomena typical in case of chronic otitis (otorrhea, dysventilation, etc.). Although some papers<sup>12</sup> reported that persistent ear discharge might be a parameter to predict chain discontinuity, being an indicator of severe inflammation that could lead to bone resorption, in our study no such role was evident.

An ossicular lesion determines poorer hearing than in the case of chain integrity. Worse threshold values in case of damaged ossicles were measured in AC, BC and ABG. On the other hand, the functional integrity of the ossicular chain, even in the presence of bone erosion, allows a hearing function similar to that found in case of cholesteatoma without chain involvement<sup>12</sup>.

Among the groups with single and multiple chain defects, patients presenting only stapes and complete chain involvement, respectively, showed the worst AC and BC thresholds, while ABG seemed to be less influenced by chain condition. Moreover, air and bone conduction impairment was related to the number of damaged ossicles, while the air-bone gap remained relatively stable (Fig. 3). This pattern is explained by more significant inner ear suffering in case of wider disease extension and is related to the grade of chain involvement. This contrasts with previous studies concluding that larger air-bone gap suggests chain discontinuity<sup>2</sup> and shows that neither PTA nor ABG are reliable parameters on which to base the diagnostic process and predict ossicular condition. ABG is not related to ossicular chain status in case of damaged ossicles; this could be explained by the fact that, from a functional point of view, chain discontinuity leads to hearing impairment regardless of the type or number of involved ossicles.

## Conclusions

Although ossicle defects in chronic otitis with cholesteatoma are frequent, and dealing with them is crucial to inform

patients, plan and perform surgery, none of the preoperative clinical parameters considered seem to have a reliable role as predictors of the ossicular chain condition, underlying the importance of imaging and the otologist's experience.

## References

- 1 Gray JH. *The treatment of cholesteatoma in children*. Proc R Soc Med 1964;57:769.
- 2 Carrillo RJ, Yang NW, Abes GT. *Probabilities of ossicular discontinuity in chronic suppurative otitis media using pure-tone audiometry*. Otol Neurotol 2007;28:1034-7.
- 3 Dornelles C, da Costa SS, Meurer L, et al. *Some considerations about acquired adult and pediatric cholesteatomas*. Braz J Otorhinolaryngol 2005;71:536-45.
- 4 Olszewska E, Wagner M, Bernal-Sprekelsen M, et al. *Etiopathogenesis of cholesteatoma*. Eur Arch Otorhinolaryngol 2004; 261:6-24.
- 5 Saleh HA, Mills RP. *Classification and staging of cholesteatoma*. Clin Otolaryngol 1999;24:355-9.
- 6 Zini C. *Classification of cholesteatoma*. In: *Proceedings of the International Course on Microsurgery of cholesteatoma of the middle ear*. Libreria Scientifica già Ghedini: Parma 1980.
- 7 Jung MH, Lee JH, Cho JG, et al. *Expressions of caspase-14 in human middle ear cholesteatoma*. Laryngoscope. 2008;118:1047-50.
- 8 Park HR, Min SK, Min K, et al. *Increased expression of p63 and survivin in cholesteatomas*. Acta Otolaryngol 2009;129:268-72.
- 9 Shinoda H, Huang CC. *Expressions of c-jun and p53 proteins in human middle ear cholesteatoma: relationship to keratinocyte proliferation differentiation and programmed cell death*. Laryngoscope 1995;105:1232-7.
- 10 Ecsedi S, Rákósy Z, Vízkeleti L, et al. *Chromosomal imbalances are associated with increased proliferation and might contribute to bone destruction in cholesteatoma*. Otolaryngol Head Neck Surg 2008;139:635-40.
- 11 Dornelles C, Petersen Schmidt Rosito L, Meurer L, et al. *Histology findings' correlation between the ossicular chain in the transoperative and cholesteatomas*. Braz J Otorhinolaryngol 2007;73:738-43..
- 12 Jeng FC, Tsai MH, Brown CJ. *Relationship of preoperative findings and ossicular discontinuity in chronic otitis media*. Otol Neurotol 2003;24:29-32.
- 13 Da Costa SS, Rosito LP, Dornelles C. *Sensorineural hearing loss in patients with chronic otitis media*. Eur Arch Otorhinolaryngol 2009;266:221-4.
- 14 Tos M. *Pathology of the ossicular chain in various chronic middle ear diseases*. J Laryngol Otol 1979;93:769-80.
- 15 De Corso E, Marchese MR, Sergi B, et al. *Role of ossiculoplasty in canal wall down tympanoplasty for middle-ear cholesteatoma: hearing results*. J Laryngol Otol 2007;121:324-8.
- 16 De Corso E, Marchese MR, Scarano E, et al. *Aural acquired cholesteatoma in children: surgical findings, recurrence and functional results*. Int J Pediatr Otorhinolaryngol 2006;70:1269-73.
- 17 Artuso A, di Nardo W, De Corso E, et al. *Canal wall down tympanoplasty surgery with or without ossiculoplasty in cholesteatoma: hearing results*. Acta Otorhinolaryngol Ital 2004;24:2-7.

Received: January 4, 2012 - Accepted: June 6, 2012

Address for correspondence: Federico Dagna, via Cassini 75/8, 10129 Turin, Italy. E-mail: federico.dagna@gmail.com