



Published in final edited form as:

Clin Cancer Res. 2013 January 15; 19(2): 462–468. doi:10.1158/1078-0432.CCR-12-2625.

Durable Cancer Regression Off-treatment and Effective Re-induction Therapy with an Anti-PD-1 Antibody

Evan J. Lipson^{1,7}, William H. Sharfman^{1,4}, Charles G. Drake^{1,2}, Ira Wollner³, Janis M. Taube^{4,5}, Robert A. Anders⁵, Haiying Xu⁴, Sheng Yao^{1,4}, Alice Pons¹, Lieping Chen^{1,4}, Drew M. Pardoll¹, Julie R. Brahmer¹, and Suzanne L. Topalian^{6,7}

¹Department of Oncology, Johns Hopkins University School of Medicine and Sidney Kimmel Comprehensive Cancer Center, Baltimore, MD 21287

²Department of Urology, Johns Hopkins University School of Medicine and Sidney Kimmel Comprehensive Cancer Center, Baltimore, MD 21287

³Department of Internal Medicine, Wayne State University School of Medicine and Henry Ford Hospital, Detroit, MI 48202

⁴Department of Dermatology, Johns Hopkins University School of Medicine and Sidney Kimmel Comprehensive Cancer Center, Baltimore, MD 21287

⁵Department of Pathology, Johns Hopkins University School of Medicine and Sidney Kimmel Comprehensive Cancer Center, Baltimore, MD 21287

⁶Department of Surgery, Johns Hopkins University School of Medicine and Sidney Kimmel Comprehensive Cancer Center, Baltimore, MD 21287

Abstract

Purpose—Results from the first-in-human phase I trial of the anti-programmed death-1 (PD-1) antibody BMS-936558 in patients with treatment-refractory solid tumors, including safety, tolerability, pharmacodynamics, and immunologic correlates, have been previously reported. Here, we provide long-term follow-up on three patients from that trial who sustained objective tumor regressions off therapy, and test the hypothesis that re-induction therapy for late tumor recurrence can be effective.

⁷To whom correspondence should be addressed at 1550 Orleans Street, David H. Koch Cancer Research Building, Baltimore, MD 21287. Tel: 410-502-8200; Fax: 410-502-1958; evanlipson@jhmi.edu; stopali1@jhmi.edu.
Current affiliation for Sheng Yao and Lieping Chen: Department of Immunobiology, Yale University, New Haven, CT 06519

Conflict of Interest Disclosures:

EJL: none

WHS: compensated consultant for Genentech and Merck; honoraria from Prometheus

CGD: compensated consultant for Bristol-Myers Squibb, Dendreon, Janssen, and ImmuneXcite; stock or other ownership interest in Amplimmune; honoraria from Bristol-Myers Squibb, Dendreon, Janssen; other remuneration (patent licensing) from Amplimmune and Bristol-Myers Squibb

IW: none

JMT: research funding from Bristol-Myers Squibb; travel reimbursement from Bristol-Myers Squibb

RAA: compensated consultant, contract for service, research funding and other remuneration from Bristol-Myers Squibb

HX: none

SY: employment (compensated, research scientist) and stock holdings or other ownership at Amplimmune

AP: none

LC: none

DMP: uncompensated consultant for Bristol-Myers Squibb, compensated consultant for Amplimmune and ImmuneXcite

JRB: uncompensated consultant for Bristol-Myers Squibb, compensated consultant for Genentech and Eli Lilly

SLT: uncompensated consultant for Bristol-Myers Squibb, compensated consultant for Amplimmune; research funding from Bristol-Myers Squibb; travel reimbursement from Bristol-Myers Squibb

Patients and methods—Three patients with colorectal cancer, renal cell cancer, and melanoma achieved objective responses on an intermittent dosing regimen of BMS-936558. Following cessation of therapy, patients were followed for over 3 years. A patient with melanoma who experienced a prolonged partial regression followed by tumor recurrence received re-induction therapy.

Results—A patient with colorectal cancer experienced a complete response which is ongoing after 3 years. A patient with renal cell cancer experienced a partial response lasting 3 years off therapy, which converted to a complete response which is ongoing at 12 months. A patient with melanoma achieved a partial response that was stable for 16 months off therapy; recurrent disease was successfully treated with re-induction anti-PD-1 therapy.

Conclusion—These data represent the most prolonged observation to date of patients with solid tumors responding to anti-PD-1 immunotherapy and the first report of successful re-induction therapy following delayed tumor progression. They underscore the potential for immune checkpoint blockade with anti-PD-1 to reset the equilibrium between tumor and the host immune system.

Keywords

anti-PD-1; immunotherapy; immune checkpoint blockade; re-induction

INTRODUCTION

The specific or selective expression of antigens by cancer cells creates an opportunity for endogenous cell-mediated and serologic immune attack, and for immunotherapeutic interventions. The development of effective cancer immunotherapies depends on reversing inhibitory and tolerogenic signals in the tumor microenvironment, thereby enhancing the visibility of tumor cells to the immune system. In the last decade, it has become clear that the immune regulatory pathway comprised of programmed death-1 (PD-1, CD279), a receptor expressed on activated T and B cells, and its ligands PD-L1 (B7-H1, CD274) and PD-L2 (B7-DC, CD273), plays an integral role in the down-modulation of antitumor immunity. Inhibition of this pathway using blocking monoclonal antibodies (mAbs) against PD-1 or PD-L1 is emerging as an effective method for reversing cancer immunosuppression and thereby causing tumor regression in patients with advanced disease(1). Although such therapies are still in development, they have shown promising clinical results not only for tumors classically considered to be immunogenic such as melanoma and renal cell carcinoma (RCC), but also for common epithelial malignancies such as non-small cell lung cancer (NSCLC), historically resistant to immunotherapy.

BMS-936558 (MDX-1106/ONO-4538) is a blocking mAb specific for human PD-1. The first-in-human single-dose, dose-escalation trial of this agent reported by Brahmer and colleagues (2) enrolled 39 patients with treatment-refractory metastatic solid tumors including melanoma, RCC, colorectal cancer (CRC), NSCLC, and castration resistant prostate cancer (CRPC). A favorable safety profile and preliminary evidence of clinical activity in all histologies except CRPC led to the design of a multi-dose trial of BMS-936558 in 296 patients that was recently reported (3), confirming antitumor efficacy in melanoma, RCC and NSCLC.

The adaptive immune system has a vast capacity for specific antigen recognition and holds the potential to adjust to ongoing tumor evolution, including genetic and epigenetic changes that typically cause resistance to small molecule inhibitors. This adaptability, coupled with an immune memory component, implies that immunotherapy can “re-orient” endogenous antitumor immunity with durable effects even after the cessation of therapy. Here, we

provide long-term follow-up on patients from the first-in-human trial of BMS-936558 who achieved objective tumor regressions, including a patient with CRC who maintained a complete response (CR) off therapy; a patient with RCC who sustained a partial response (PR) that converted to a CR off therapy; and a patient with melanoma who experienced a prolonged PR off therapy followed by tumor progression and then response to re-induction therapy with the same anti-PD-1 antibody. These data represent the most prolonged observation of patients with solid tumors responding to anti-PD-1 therapy and the first evidence that re-induction therapy with this agent after late tumor progression may be effective. The observed durability of responses underscores the potential for immune checkpoint blockade with anti-PD-1 to reset the equilibrium between tumor and host, and provide durable tumor control after cessation of therapy.

MATERIALS AND METHODS

Treatments administered and response evaluation

BMS-936558, a fully human immunoglobulin G4 (IgG4) blocking mAb against PD-1, was administered in a multi-institutional, first-in-human, phase I dose-escalation study (2). The protocol was approved by local institutional review boards and all participating subjects signed informed consent. The antibody was given as a single intravenous (IV) infusion at 0.3 – 10 mg/kg per dose, followed by radiologic restaging at 8 and 12 weeks. Responses were evaluated using Response Evaluation Criteria in Solid Tumors (RECIST) 1.0. Patients who tolerated the drug well (no adverse events grade 3 and no development of human antihuman antibodies) and demonstrated stable disease or any evidence of tumor regression were eligible for retreatment at weeks 12 and 16. Patients who achieved an objective response (PR or CR) discontinued dosing and were observed with periodic radiologic restaging.

A patient with melanoma who experienced a prolonged PR followed by tumor progression received re-induction therapy with BMS-936558 10 mg/kg on days 1, 29 and 86, repeated every 120 days, on a single patient use clinical trial following IRB approval and informed consent. In contrast to the original dosing schema, treatment on this trial may continue until the patient develops a confirmed CR, confirmed progressive disease or unacceptable toxicity.

Tumor biopsies and immunohistochemistry

Histologic slides were reviewed to confirm the cancer diagnosis, and one representative formalin fixed, paraffin embedded (FFPE) block of tumor was chosen for immunohistochemical (IHC) analysis to characterize the tumor and its microenvironment. PD-L1 immunostaining was performed with the mAb 5H1 as previously described (4). The method for PD-1 immunostaining parallels that reported for PD-L1 with minor modifications. The murine anti-human PD-1 mAb, clone M3, was used at a concentration of 1.0 ug/mL. Citrate buffer pH 6.0 was used for antigen retrieval, and a CSA System (DAKO; Glostrup, Denmark) was used for signal amplification, followed by development with diaminobenzidine chromagen which results in brown staining. In the heavily pigmented melanoma, a Giemsa counterstain was used for the PD-1 antibody. This results in green coloration of the melanin pigment and facilitates interpretation of the brown signal (5). CD3, CD4, CD8, CD68, and T-cell intracytoplasmic antigen-1 (TIA-1) immunostains were performed according to routine automated methods.

RESULTS

Among 39 patients with treatment-refractory solid tumors receiving BMS-936558 on an intermittent dosing regimen (2), three objective tumor regressions were observed. Following are the clinical and immunologic assessments of these patients during prolonged observation.

Durable complete response in colorectal cancer

A 71-year-old male with CRC underwent a right hemicolectomy in October 2003, revealing a moderately differentiated adenocarcinoma with metastases to 4 of 16 pericolic lymph nodes and vascular and perineural invasion [G2, pT3N2; microsatellite instability (MSI)-high genotype]. He received adjuvant 5-FU and leucovorin, however, a CT scan the following year revealed metastatic disease. Over the subsequent 3 years, the patient received multiple chemotherapeutic regimens with temporary response but then progression at multiple lymph node sites (gastrohepatic, portacaval, peripancreatic); therapies included FOLFOX, irinotecan, bevacizumab, and cetuximab. Chemotherapy was last administered in April 2007. The patient began therapy with anti-PD-1 at 3 mg/kg per dose in July 2007 after documentation of disease progression, and received 5 doses over the next 9 months. CT scans performed 8 and 12 weeks after a single dose of anti-PD-1 demonstrated a partial response (Figure 1A). A CR was achieved in January 2008, and periodic CT and PET scans have revealed no evidence of recurrence since then. The patient was most recently evaluated in April 2011, at which time he had not received any anti-neoplastic therapy for 3 years and had no evidence of disease recurrence.

Immunohistochemical studies of the primary colon tumor, performed on FFPE tissues archived 4 years before the initiation of anti-PD-1 therapy, revealed cell surface (“membranous”) expression of PD-L1 by infiltrating macrophages and lymphocytes and by rare tumor cells, associated with infiltrating PD-1+, CD3+ T cells (Figure 1B). We have previously reported preliminary evidence for a correlation between tumor cell membranous PD-L1 expression and the likelihood of response to anti-PD-1 therapy (2). Potential relationships between PD-L1 expression on non-tumor cells and clinical outcomes require further study (4).

Evolution of complete tumor regression off therapy in renal cell carcinoma

A 76-year-old male underwent a right nephrectomy and vena caval thrombectomy in 2001, demonstrating clear cell renal carcinoma. He developed bilateral pulmonary metastases in 2003 and received systemic therapies including the histone deacetylase inhibitor mocetinostat, sorafenib and sunitinib, experiencing disease progression with new metastatic sites in mediastinal lymph nodes, bone and paraspinal musculature. In January 2008, he began treatment with anti-PD-1 at 10 mg/kg per dose. CT scans performed in March 2008, 8 weeks after a single dose of anti-PD-1, showed a mixed response: pulmonary, lymph node and intramuscular metastases were regressing, but lesions were enlarging in the pancreas and bone. The patient also developed hypothyroidism which was assessed as possibly treatment-related. He received two more doses of anti-PD-1 in April and May 2008; a CT scan in July 2008 showed a PR compared to baseline tumor measurements, including disappearance of the pancreatic lesion (Figure 2A); the bone metastasis slowly resolved (2). PR status was maintained off therapy until February 2009, when a re-staging brain CT and subsequent brain MRI showed a new enhancing 1.4-cm lesion in the inferior right frontal lobe, with intralesional hemorrhage and surrounding edema, consistent with metastasis (Figure 2B). Resection of this asymptomatic mass revealed fibrovascular tissue with macrophages and chronic inflammation but no evidence of tumor; this was consistent with a resolving lesion of undetermined origin. No further anti-neoplastic therapy was administered

and metastatic lesions continued to regress off therapy (Figure 2C). A CR was documented with CT and PET scans in August 2011. This patient remains in remission as of radiologic evaluation in August 2012, more than 4 years after discontinuation of anti-PD-1 therapy.

Re-induction therapy for recurrent melanoma

A 55-year-old female was diagnosed with metastatic melanoma following biopsy of a left axillary mass in 2006; the primary site of origin was undetermined. Further workup revealed liver metastases. Disease progression occurred despite therapy with high-dose interleukin-2 and temozolomide. Eight weeks after receiving one dose of anti-PD-1 at 10mg/kg in October 2007, CT scans revealed a mixed picture: lesions in the liver and left axilla were stable or regressing, while a left subpectoral lymph node had enlarged (Figure 3A). Two more doses of anti-PD-1 were administered in January and February 2008. CT scans performed in April and May 2008 again demonstrated a mixed response with interval development of central necrosis in some lesions. The patient continued to receive anti-PD-1 therapy through June 2009, and a PR compared to baseline measurements was documented in August 2009. Per protocol, treatment was discontinued. A stable PR persisted until December 2010, when a restaging PET/CT scan revealed newly enlarged, FDG-avid precarinal and subcarinal lymph nodes. A transbronchial biopsy of the subcarinal lesion confirmed a diagnosis of melanoma (Figure 3B). Similar to prior IHC studies of an axillary lymph node metastasis in this patient (2), there was intense membranous tumor cell expression of PD-L1 and infiltration by CD8+, PD-1+ T cells. A patient-specific protocol providing for re-induction therapy with BMS-936558 was approved by the Johns Hopkins IRB, and treatment was re-initiated in May 2011. After the patient received two doses of anti-PD-1, a PET/CT scan in November 2011 showed near complete resolution of the abnormal metabolic activity in the subcarinal lymph node and no new lesions (Figure 3C). CT scan demonstrated a 40% tumor regression of the new mediastinal adenopathy compared to re-induction baseline measurements (Figure 3D). The patient continues on anti-PD-1 at the time of this report, with a sustained PR documented 16 months following initiation of re-induction therapy.

DISCUSSION

The successful application of PD-1/PD-L1 pathway blockade in treating a diversity of solid tumors underscores the power of immunotherapy in combating not only cancers traditionally considered to be immunogenic, such as melanoma and RCC, but also epithelial malignancies such as NSCLC and CRC which are commonly viewed as refractory to immunotherapy. The activity of agents blocking this pathway is currently being explored in multiple new indications in oncology, including ovarian, breast, gastric, and pancreatic cancer. Preclinical evidence suggests that continuous antigen exposure of cytolytic T cells may induce a tolerant or “exhausted” state in which T cell effector functions and transition to memory T cells are impaired. PD-1 pathway blockade may restore the functions of exhausted T cells with long-term clinical benefit, generating powerful memory T cells that may provide an ongoing antitumor dynamic and keep tumors in check for months to years, even in the absence of continued therapy (6). This hypothesis is consistent with the results of the current study and is highlighted by the RCC case, in which partially responsive metastatic deposits continued to regress off therapy and eventuated in a durable CR. The new brain lesion resected from this patient in the interim, while not independently diagnostic, was consistent with a healing lesion such as might occur at a site of tumor regression. Similar pathologic features, including tumor necrosis in the presence of complex immune cell infiltrates, have been described in post-treatment tumor biopsies from patients receiving anti-CTLA-4 immunotherapy (7). These findings suggest the potential of PD-1 pathway blockade to reset the immune equilibrium between tumor and host (8). It follows

that tumor recurrence after a response may reflect a disturbance in this equilibrium, as illustrated by the melanoma patient described herein. Repeat application of PD-1 blockade in this patient, whose recurrent tumor strongly expressed PD-L1 and contained PD-1+ infiltrating lymphocytes, re-induced a rapid partial tumor regression. Unlike tumors exposed to tyrosine kinase inhibitors that may rapidly acquire resistance and exhibit progression during continued drug exposure, due to the emergence of new genetic or epigenetic alterations (9), tumor progression in this patient occurred only after therapy was discontinued. These findings suggest a potential role for continued administration of anti-PD-1 on an intermittent “maintenance” schedule after achieving an objective tumor regression, in order to preserve an immune equilibrium and protect the host from tumor re-growth.

The findings described herein also demonstrate the importance of establishing new immune-related RECIST (iRECIST) criteria to evaluate patients undergoing therapy with agents blocking immune checkpoints such as anti-PD-1. These agents are not directly tumoricidal, but work indirectly by activating antitumor immunity and thus may be associated with delayed response kinetics (10). As exemplified by the melanoma and RCC patients reported here, metastatic lesions may appear anew or enlarge before showing evidence of regression (11). “Mixed” responses characterized by the simultaneous growth of some lesions and regression of others have also been observed. These unconventional response patterns may provide survival benefits, which remains to be determined in future randomized trials of PD-1 blockade. Indeed, these principles are illustrated by randomized trials of immune checkpoint blockade with ipilimumab (anti-CTLA-4) in patients with advanced melanoma, where overall survival rates exceeded objective response rates (CR+PR)(12, 13), suggesting the possibility of a new paradigm for evaluating clinical benefit that does not rely solely on traditional RECIST response criteria. Development of iRECIST criteria in combination with biomarkers that reliably predict clinical response will be vital as an increasing number of immunotherapies become commercially available (14).

Since the publication of the first-in-human phase I trial of BMS-936558 using an intermittent dosing regimen(2), this drug has been tested in a follow-up phase I trial with cohort expansion, using bi-weekly administration to patients with various treatment-refractory solid malignancies(3). Objective responses (PR or CR) were observed in 18% of patients with NSCLC, 28% with melanoma, and 27% with RCC. Grade 3–4 treatment-related adverse events occurred in 14% of patients, and there were three deaths from pulmonary toxicity. Similar to observations from the first-in-human trial, responses were durable: among 31 responding patients with 1 year of follow-up, 20 responses lasted 1 year. Data from this and trials of other agents blocking the PD-1 pathway (15–17) should inform future studies involving combinatorial immune-based approaches, which have shown pre-clinical evidence of synergistic anti-tumor activity (18, 19).

The co-localization of tumor-infiltrating T cells and PD-L1+ tumor and stromal cells seen in biopsies from the CRC and melanoma patients reported here represents a more general phenomenon, and is consistent with observations suggesting that interferon-gamma secretion by intratumoral lymphohistiocytic infiltrates fosters an immunosuppressive microenvironment by promoting PD-L1 expression [“adaptive immune resistance”;(4)]. PD-1 pathway blockade may be particularly effective in these cases, as illustrated by the recent report from Topalian and colleagues showing preliminary evidence for a correlation between tumor cell surface expression of PD-L1 in pretreatment tumor specimens and objective response to anti-PD-1 therapy (3). PD-L1 expression as a predictive tumor marker of response to re-induction therapy with PD-1 pathway blockade, as demonstrated in the melanoma patient described in this report, remains to be explored in larger studies.

Acknowledgments

We thank Marina Laiko for clinical research coordination and data management, and Dr. Peter Burger for helpful discussions (both Johns Hopkins University School of Medicine). We thank Bristol-Myers Squibb for providing BMS-936558 for re-induction therapy.

GRANT SUPPORT

This work was supported by the National Institutes of Health (R01 CA142779; JMT, LC, DMP, SLT), the Melanoma Research Alliance (JMT, LC, DMP, SLT), the Laverna Hahn Charitable Trust (EJL, WHS, JMT, SLT), the Barney Family Foundation (EJL, WHS, JMT, SLT), the Commonwealth Foundation (DP), and the Seraph Foundation (DP).

REFERENCES

1. Topalian SL, Drake CG, Pardoll DM. Targeting the PD-1/B7-H1(PD-L1) pathway to activate anti-tumor immunity. *Curr Opin Immunol*. 2012
2. Brahmer JR, Drake CG, Wollner I, Powderly JD, Picus J, Sharfman WH, et al. Phase I study of single-agent anti-programmed death-1 (MDX-1106) in refractory solid tumors: Safety, clinical activity, pharmacodynamics, and immunologic correlates. *J Clin Oncol*. 2010; 28(19):3167–3175. [PubMed: 20516446]
3. Topalian SL, Hodi FS, Brahmer JR, Gettinger SN, Smith DC, McDermott DF, et al. Safety, activity, and immune correlates of anti-PD-1 antibody in cancer. *N Engl J Med*. 2012; 366(26):2443–2454. [PubMed: 22658127]
4. Taube JM, Anders RA, Young GD, Xu H, Sharma R, McMiller TL, et al. Co-localization of inflammatory response with B7-H1 expression in human melanocytic lesions supports an adaptive resistance mechanism of immune escape. *Sci Transl Med*. 2012; 4(127) 127ra37.
5. Kamino H, Tam ST. Immunoperoxidase technique modified by counterstain with azure B as a diagnostic aid in evaluating heavily pigmented melanocytic neoplasms. *J Cutan Pathol*. 1991; 18(6): 436–439. [PubMed: 1723081]
6. Kim PS, Ahmed R. Features of responding T cells in cancer and chronic infection. *Curr Opin Immunol*. 2010; 22(2):223–230. [PubMed: 20207527]
7. Hodi FS, Mihm MC, Soiffer RJ, Haluska FG, Butler M, Seiden MV, et al. Biologic activity of cytotoxic T lymphocyte-associated antigen 4 antibody blockade in previously vaccinated metastatic melanoma and ovarian carcinoma patients. *Proc Natl Acad Sci U S A*. 2003; 100(8):4712–4717. [PubMed: 12682289]
8. Dunn GP, Old LJ, Schreiber RD. The three E's of cancer immunoediting. *Annu Rev Immunol*. 2004; 22:329–360. [PubMed: 15032581]
9. Sequist LV, Waltman BA, Dias-Santagata D, Digumarthy S, Turke AB, Fidias P, et al. Genotypic and histological evolution of lung cancers acquiring resistance to EGFR inhibitors. *Sci Transl Med*. 2011; 3(75) 75ra26.
10. Weber J. Review: Anti-CTLA-4 antibody ipilimumab: Case studies of clinical response and immune-related adverse events. *Oncologist*. 2007; 12(7):864–872. [PubMed: 17673617]
11. Wolchok JD, Hoos A, O'Day S, Weber JS, Hamid O, Lebbe C, et al. Guidelines for the evaluation of immune therapy activity in solid tumors: Immune-related response criteria. *Clin Cancer Res*. 2009; 15(23):7412–7420. [PubMed: 19934295]
12. Hodi FS, O'Day SJ, McDermott DF, Weber RW, Sosman JA, Haanen JB, et al. Improved survival with ipilimumab in patients with metastatic melanoma. *N Engl J Med*. 2010; 363(8):711–723. [PubMed: 20525992]
13. Robert C, Thomas L, Bondarenko I, O'Day S, M DJW, Garbe C, et al. Ipilimumab plus dacarbazine for previously untreated metastatic melanoma. *N Engl J Med*. 2011; 364(26):2517–2526. [PubMed: 21639810]
14. Sharma P, Wagner K, Wolchok JD, Allison JP. Novel cancer immunotherapy agents with survival benefit: Recent successes and next steps. *Nat Rev Cancer*. 2011; 11(11):805–812. [PubMed: 22020206]

15. Brahmer JR, Tykodi SS, Chow LQ, Hwu WJ, Topalian SL, Hwu P, et al. Safety and activity of anti-PD-L1 antibody in patients with advanced cancer. *N Engl J Med*. 2012; 366(26):2455–2465. [PubMed: 22658128]
16. Patnaik A, Kang SP, Tolcher AW, Rasco DW, Papadopoulos KP, Beeram M, et al. Phase I study of MK-3475 (anti-PD-1 monoclonal antibody) in patients with advanced solid tumors [abstract]. *J Clin Oncol*. 2012; 30(suppl) abstr 2512;30.
17. Berger R, Rotem-Yehudar R, Slama G, Landes S, Kneller A, Leiba M, et al. Phase I safety and pharmacokinetic study of CT-011, a humanized antibody interacting with PD-1, in patients with advanced hematologic malignancies. *Clin Cancer Res*. 2008; 14(10):3044–3051. [PubMed: 18483370]
18. Matsuzaki J, Gnjatic S, Mhawech-Fauceglia P, Beck A, Miller A, Tsuji T, et al. Tumor-infiltrating NY-ESO-1-specific CD8+ T cells are negatively regulated by LAG-3 and PD-1 in human ovarian cancer. *Proc Natl Acad Sci U S A*. 2010; 107(17):7875–7880. [PubMed: 20385810]
19. Zhou Q, Munger ME, Veenstra RG, Weigel BJ, Hirashima M, Munn DH, et al. Coexpression of tim-3 and PD-1 identifies a CD8+ T-cell exhaustion phenotype in mice with disseminated acute myelogenous leukemia. *Blood*. 2011; 117(17):4501–4510. [PubMed: 21385853]

Statement of Translational Relevance

This report provides long-term follow-up on patients from the first-in-human trial of the anti-PD-1 antibody BMS-936558 (MDX-1106) who achieved objective tumor regressions. They include patients with metastatic melanoma, colorectal and renal cancer. Remarkably, durable responses including continued tumor regression off therapy were observed. Furthermore, a patient with melanoma, who experienced tumor recurrence following a prolonged partial response, responded to re-induction with anti-PD-1 therapy. These findings of durable treatment effect underscore the potential for immune-based therapies such as antibodies blocking the immunosuppressive PD-1/PD-L1 pathway to reset the equilibrium between tumor and the host immune system, distinguishing them from conventional chemotherapies as well as small molecule inhibitors of oncogenic driver pathways. They represent the most prolonged observation of patients with solid tumors responding to anti-PD-1 immunotherapy to date, and the first evidence that re-induction therapy with this agent after late tumor recurrence may be effective.

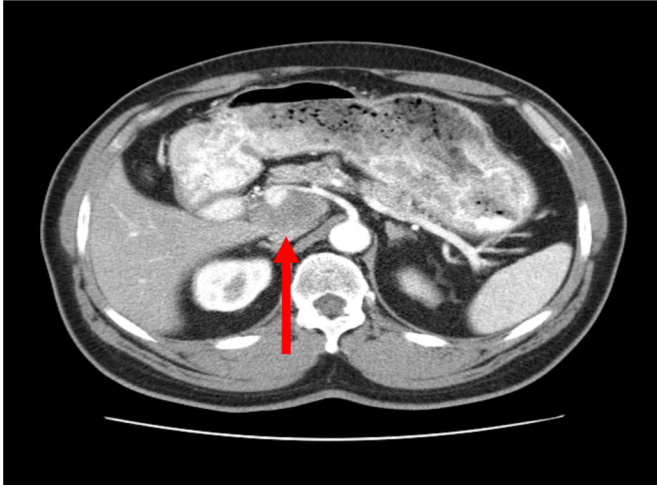
\$watermark-text

\$watermark-text

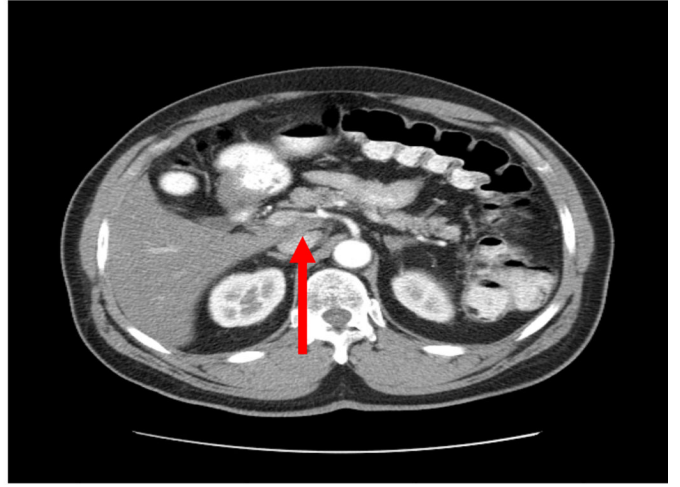
\$watermark-text

A

Pretreatment



Day 85



\$watermark-text

\$watermark-text

\$watermark-text

B

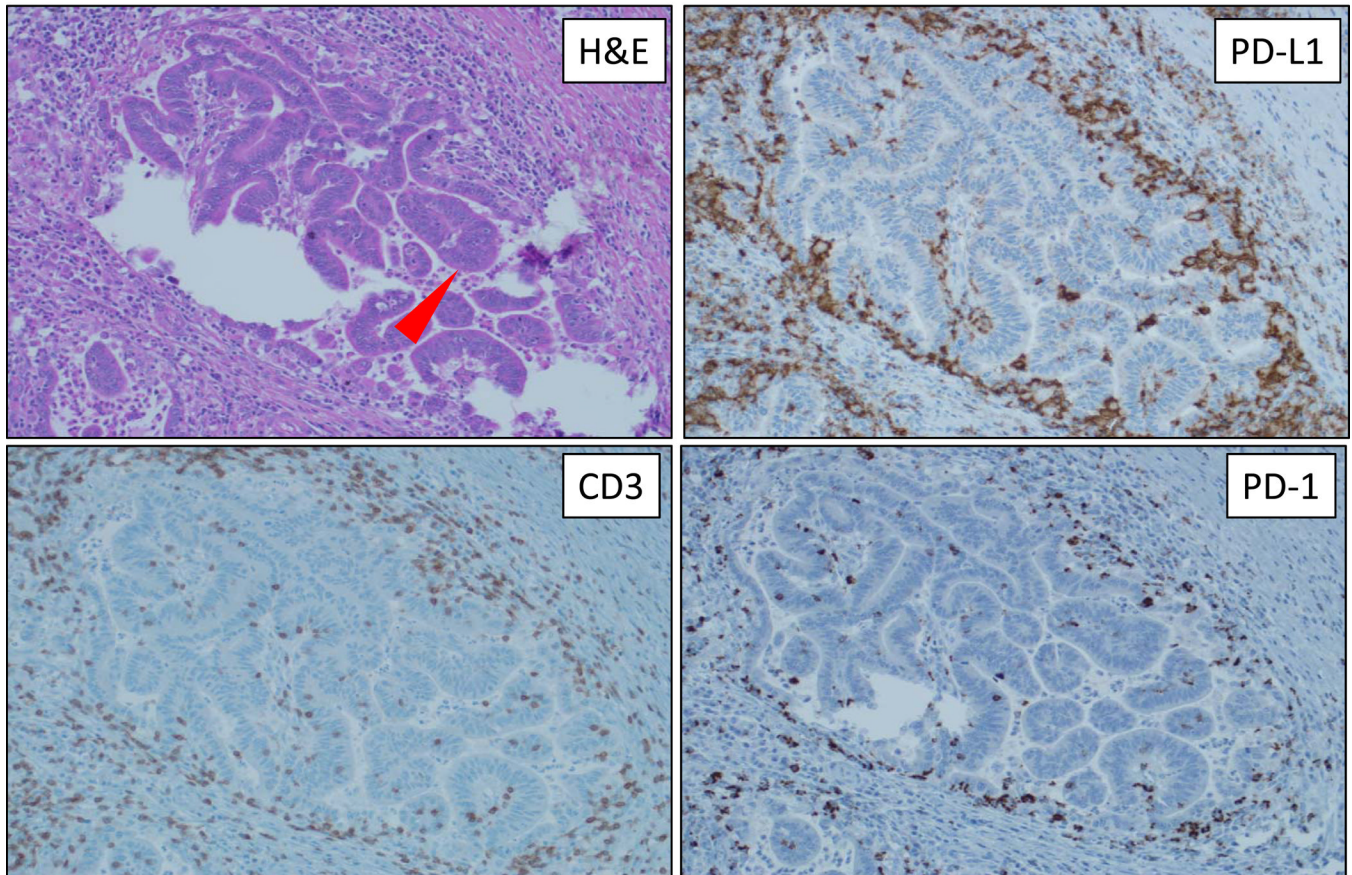
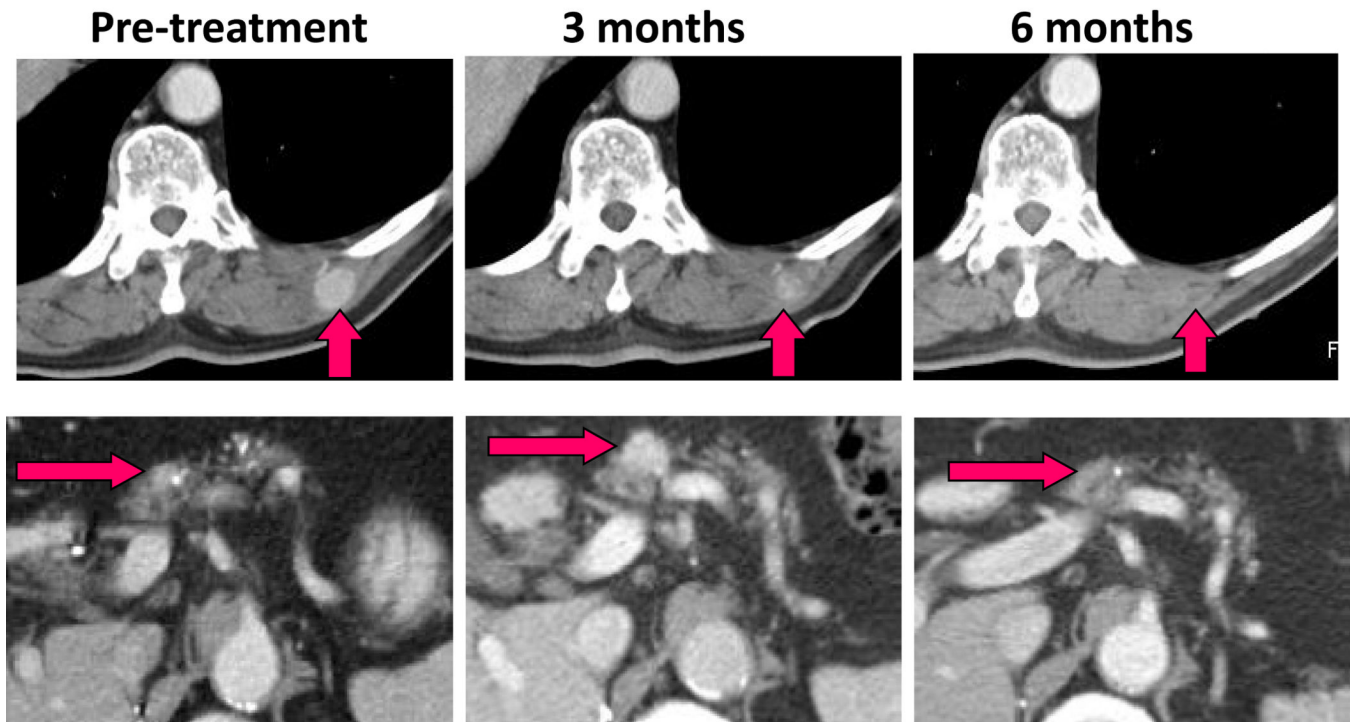
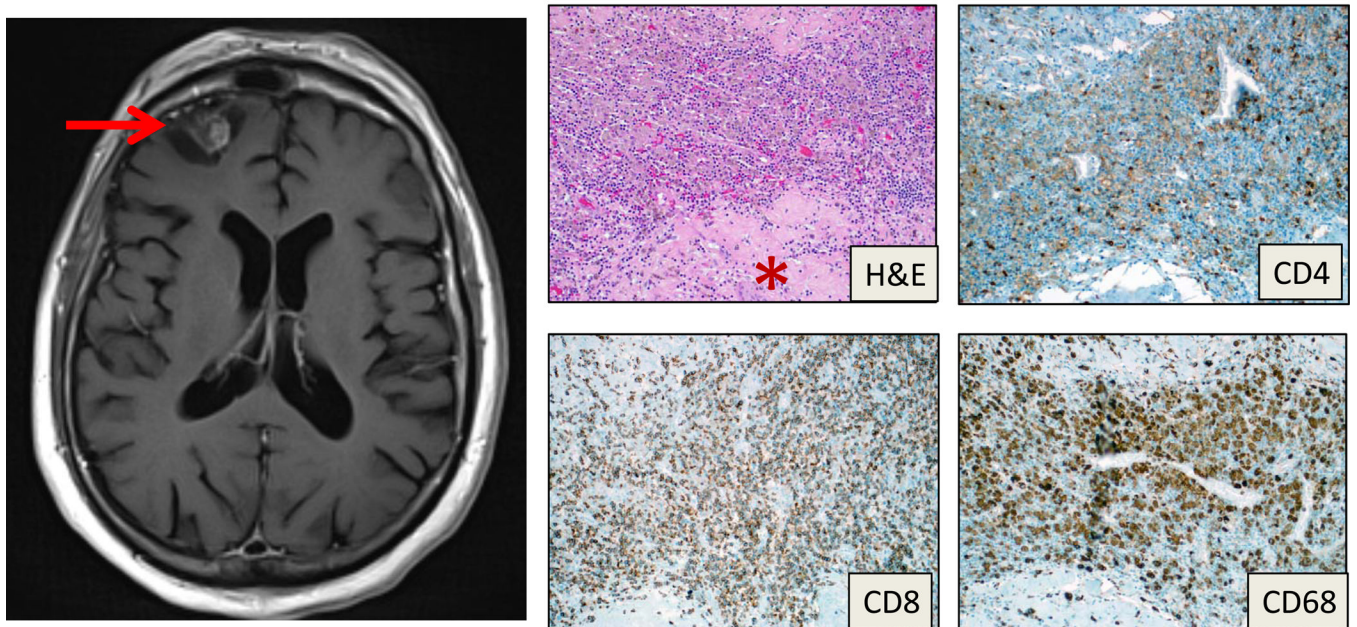


Figure 1. Response of metastatic colorectal cancer to anti-PD-1 therapy. (A) Computed tomographic scan showing partial regression of a representative lymph node metastasis in a patient with CRC, after receiving a single dose of anti-PD-1. (B) H&E staining and IHC analysis of primary colon tumor from this patient, showing PD-L1+ lymphohistiocytic infiltrates surrounding tumor cells, and rare PD-L1+ tumor cells, interposed with CD3+, PD-1+ infiltrating T cells. Arrow denotes tumor cells. 200x original magnification.

A



B



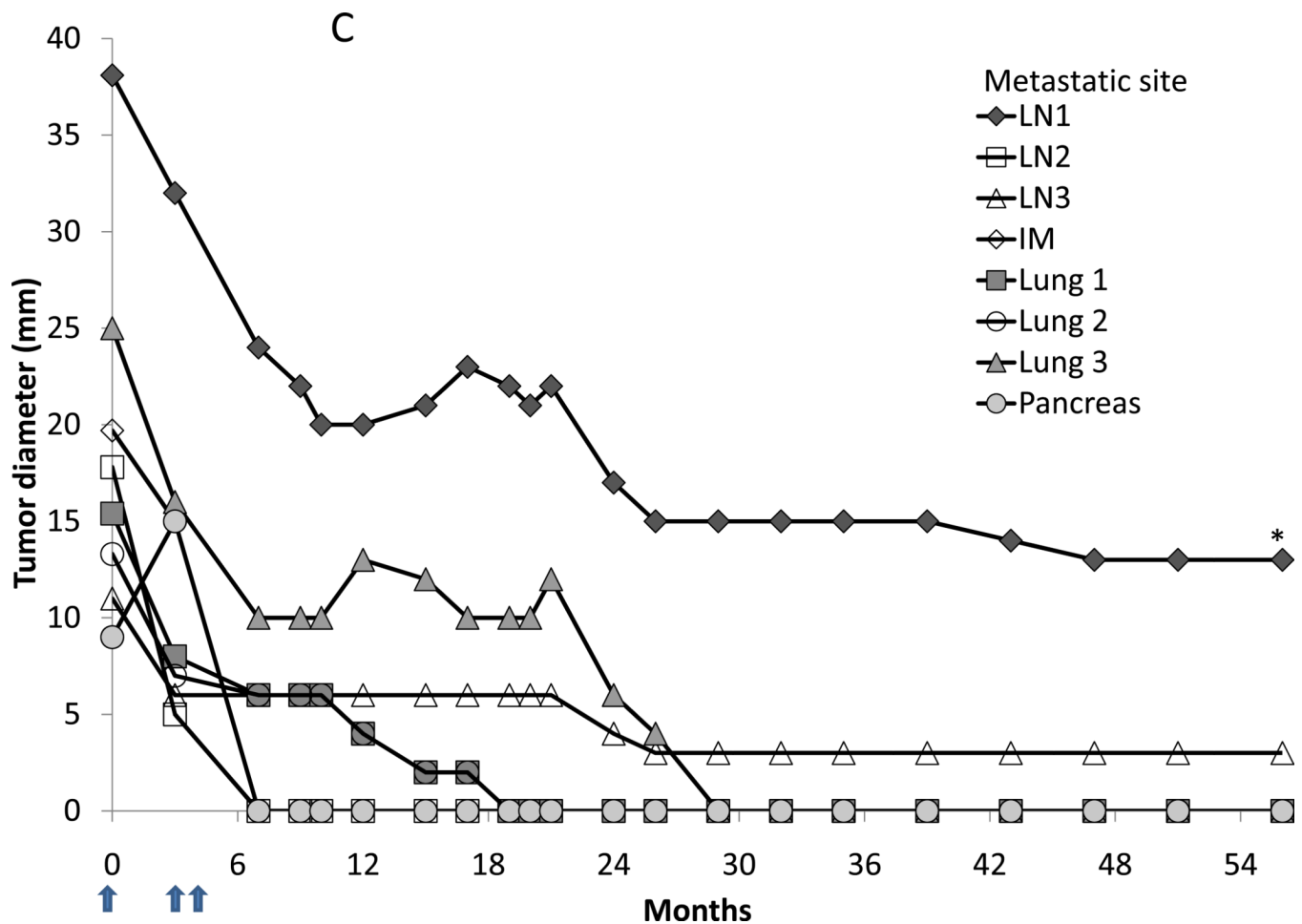
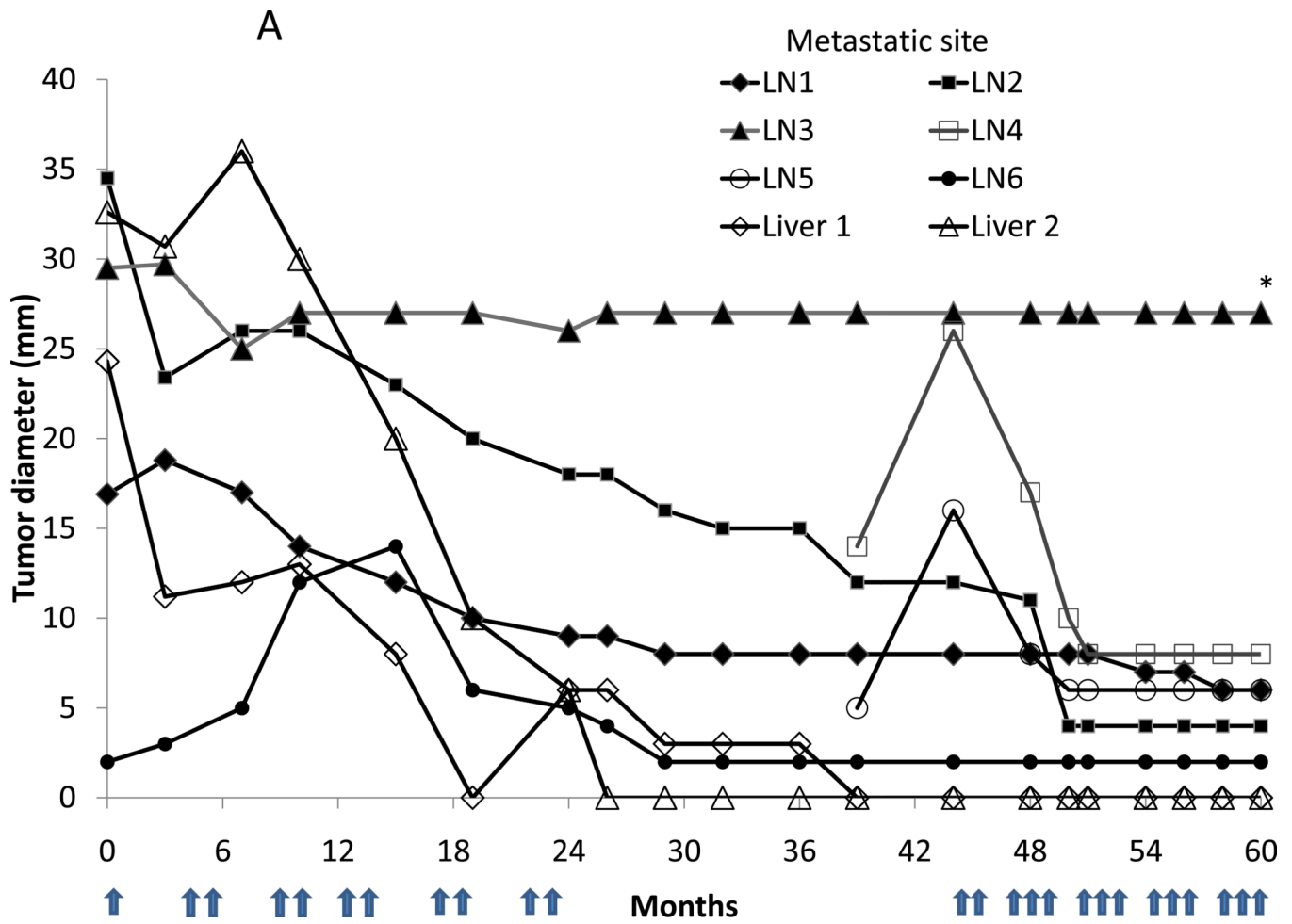
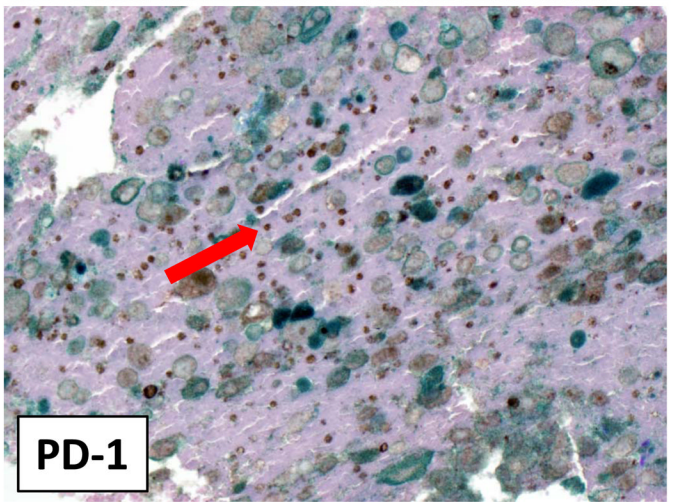
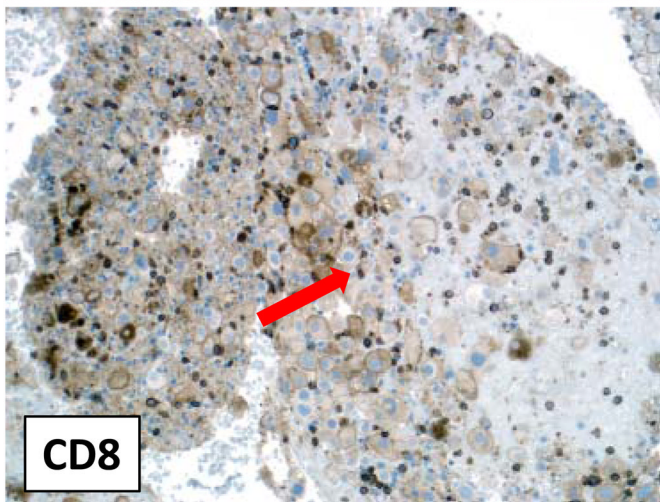
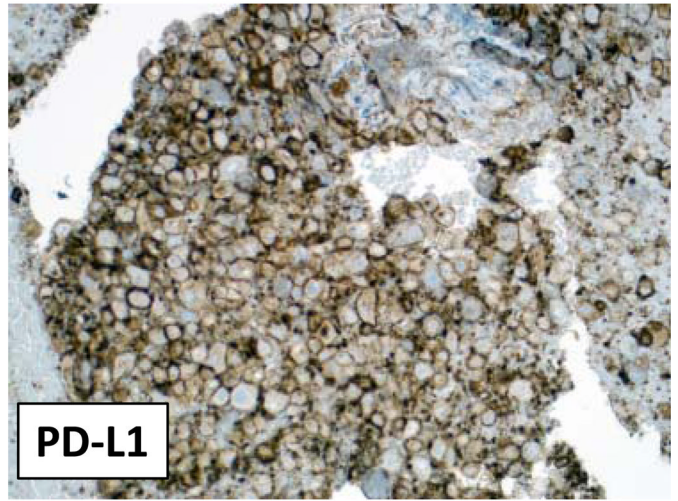
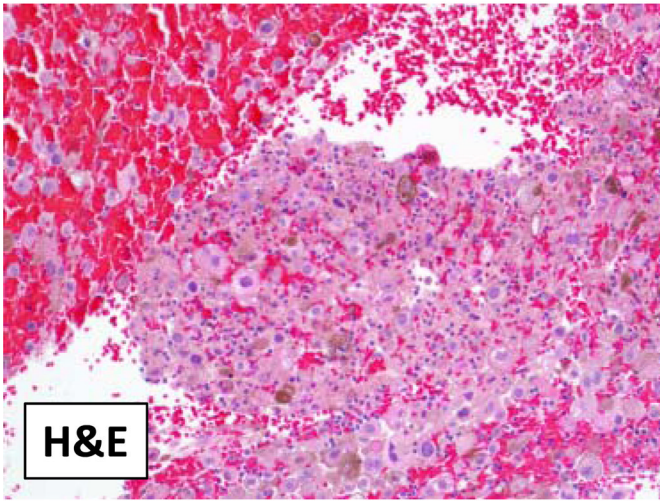


Figure 2. Regression of metastatic RCC following anti-PD-1 therapy, with “immune related” response characteristics. (A) Contrast-enhanced CT scans showing regression of a biopsy-proven paraspinous intramuscular metastasis (top row, arrows) and concomitant progression followed by regression of a pancreatic lesion (bottom row, arrows) in a patient who received 3 doses of anti-PD-1. (B) Newly appearing lesion radiologically compatible with brain metastasis, demonstrated on T1-weighted contrast enhanced magnetic resonance imaging, with intralesional hemorrhage and surrounding edema (left panel). Pathologic evaluation of the resected lesion on H&E staining revealed fibrosis (asterisk), a chronic inflammatory cell infiltrate, and old hemorrhage, consistent with a resolving process. There was no morphologic or immunohistochemical evidence of RCC (no expression of PAX-8, EMA, or AE1/AE3; data not shown). Immunostaining to characterize the inflammatory infiltrate demonstrated a lymphocytic infiltrate with CD8 predominance when compared to CD4. The CD8 cells were also TIA-1 positive, supporting a cytotoxic phenotype (not shown). Staining for CD68 highlighted numerous hemosiderin-laden macrophages in the inflammatory infiltrate. 200x original magnification. (C) Continued regression of multiple metastatic sites over time, following cessation of anti-PD-1 therapy. Drug administration indicated by arrows. The lesion marked with an asterisk became calcified on CT scan and showed no FDG activity on PET scan. LN, lymph node; IM, intramuscular.



B



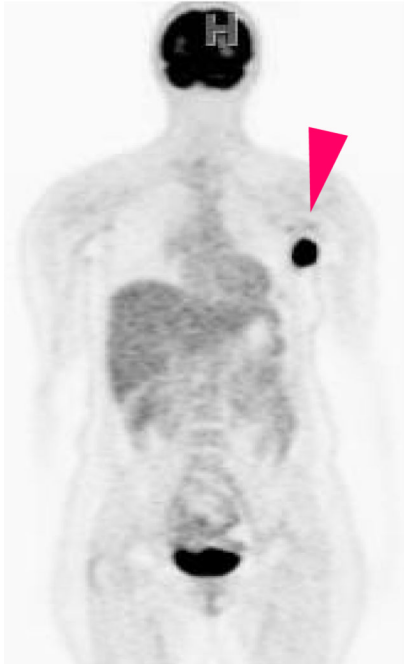\$watermark-text

\$watermark-text

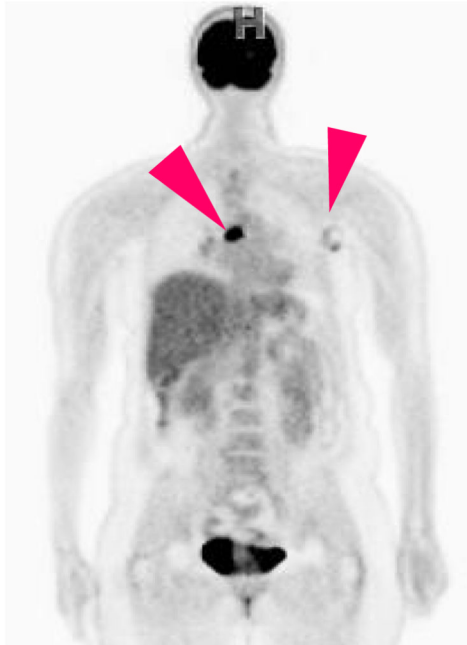\$watermark-text

C

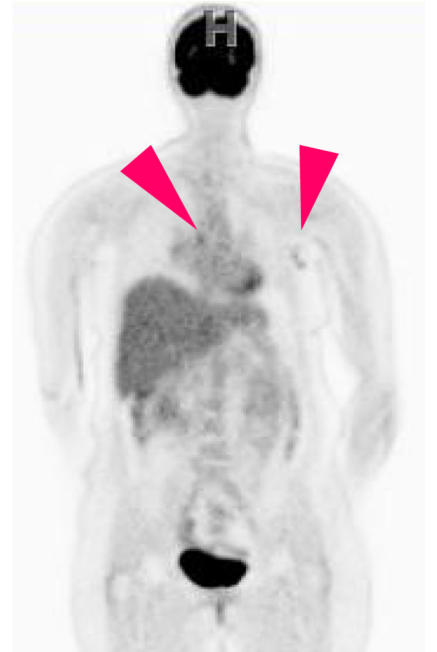August 2007



December 2010



November 2011



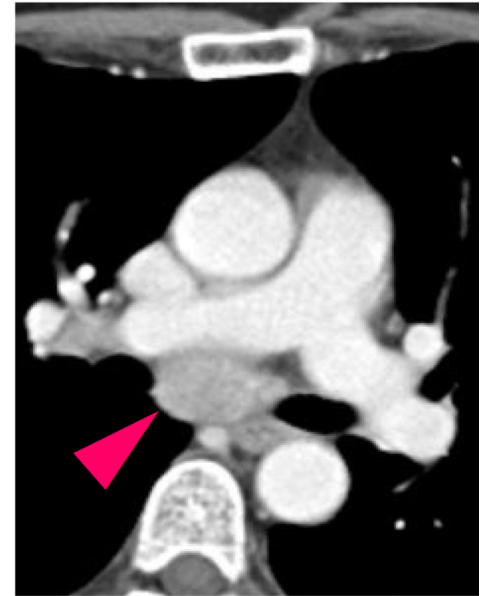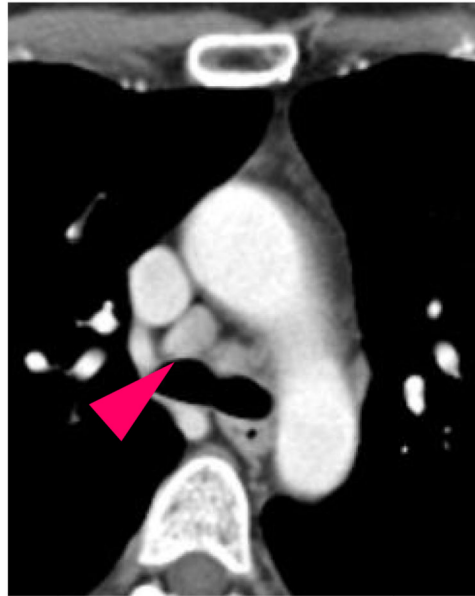
\$watermark-text

\$watermark-text

\$watermark-text

D

**Melanoma
recurrence**



**4 months
after starting
re-induction
therapy**

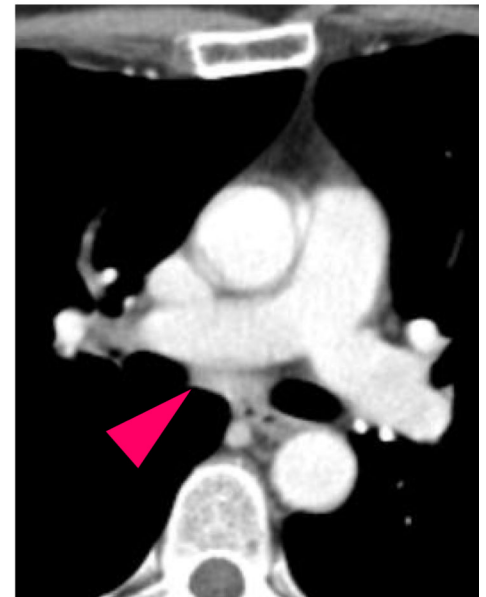
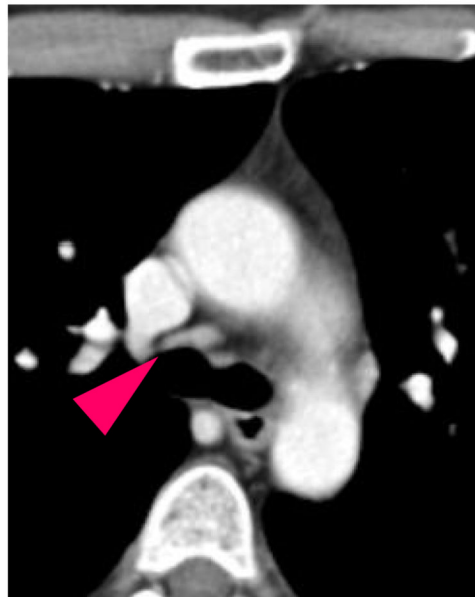


Figure 3.

Response of metastatic melanoma to re-induction anti-PD-1 therapy. (A) Initial partial regression of liver and lymph node (LN) metastases in a melanoma patient treated with anti-PD-1. Drug administration indicated by arrows. Recurrent disease in mediastinal lymph nodes while off therapy was successfully treated with re-induction therapy. The lesion marked with an asterisk developed peripheral calcification and demonstrated minimal PET activity. (B) Membranous (cell surface) PD-L1 expression by metastatic melanoma cells in a transbronchial biopsy of a subcarinal lymph node mass, prior to re-induction therapy. Tumor infiltration by CD8+, PD-1+ T cells is evident (arrows). 200x original magnification. (C) PET scans prior to first treatment with anti-PD-1 (August 2007), prior to re-induction therapy (December 2010), and following re-induction (November 2011). Resolution of a left

axillary lymph node metastasis that was present prior to anti-PD-1 therapy, and response of a new subcarinal lymph node metastasis to re-induction therapy, are shown (arrows). (D) Regression of new mediastinal lymph node metastasis following re-induction therapy with anti-PD-1, demonstrated in contrast-enhanced CT scans.

\$watermark-text

\$watermark-text

\$watermark-text