

Impacted maxillary incisors: diagnosis and predictive measurements

Chiara Pavoni
Manuela Mucedero
Giuseppina Laganà
Valeria Paoloni
Paola Cozza

Department of Orthodontics, University of Rome Tor Vergata, Italy

Corresponding author:

Giuseppina Laganà
Department of Orthodontics, University of Rome Tor Vergata, Rome, Italy
Via G. Baglivi, 5/E
00161 Roma, Italy
Phone: +39 06 44232321
E-mail: giuseppinalagana@libero.it

Summary

Background. When the incisors do not erupt at the expected time, it is crucial for the clinician to determine the etiology and formulate an appropriate treatment plan. **Aim.** The aim of this report is to provide useful information for immediate diagnosis and management of impacted maxillary incisors using the interceptive treatment: removal of obstacles and rapid maxillary expansion (RME).

Design. An accurate diagnosis may be obtained with clinical and radiographic exam such as panoramic radiograph, computerized tomography (CT) and cone beam computerized tomography (CBCT). It's important to know the predictive measurements of eruption evaluated on panoramic radiograph: distance from the occlusal plane, maturity, angulation and vertical position of the unerupted incisors. Early diagnosis is important and interceptive orthodontic treatment, such as removal of obstacles and orthopedic rapid maxillary expansion (RME), may correct disturbances during the eruption through recovering space for the incisors and improving the intraosseus position of delayed teeth.

Results. RME treatment following the surgical removal of the obstacle to the eruption of maxillary incisors leads to an improvement of the intraosseus position of the tooth.

Conclusions. The angulation and the vertical position of the delayed tooth appear to be important in trying to predict eruption. The improvement of the intraosseus position of the unerupted incisor, obtained by removal of the odontoma and rapid maxillary expansion, permits a conservative surgery and the achievement of an excellent esthetics and periodontal result.

Key words: eruption disturbances, odontoma, maxillary expansion, orthodontic traction, close eruption technique.

Introduction

Impaction of the maxillary incisor poses a problem at an earlier age (1); this pathologic condition is reported less frequently than that of third molars or canines. Impaction of maxillary permanent incisors occurs in 0,2-1% of the population (2), early referral of patients in the mixed dentition is common due to concern of parents and general dentists regarding delayed eruption of the permanent maxillary central incisors (3,4).

As missing upper incisors are regarded as unattractive this may have an effect on self-esteem and general social interaction, and it is important to detect and manage the problem as early as possible (5).

The maxillary incisors are the most prominent teeth in an individual's smile, they are also the teeth that are on maximum display during speech in most individuals and the normal eruption, position and morphology of these teeth are crucial to facial esthetics and phonetics (6).

Early diagnosis is very important and interceptive orthodontic treatment could not only improve skeletal malrelationship and eliminate functional interferences, but also may correct disturbances during the eruption (7).

Etiology

Literature reveals several causes of failure or delayed eruption of maxillary incisors.

Eruption failure may occur if pathological obstructions, such as supernumerary teeth, odontomas, cysts, develop in the eruptive path of the incisor (6,8).

Supernumerary teeth and odontomas are the most common cause: 56-60% of supernumerary teeth cause impaction of permanent incisors due to a direct obstruction for the eruption (9).

Eruption failure can also be caused by tooth malformation or dilacerations. Dilacerations occur after trauma to a primary tooth, where the developing permanent tooth bud is damaged due to close proximity to the primary tooth. The degree of damage of the permanent tooth depends on the developmental stage of the tooth in question, as well as the type and direction of the trauma inflicted (6,10).

Other possible causes of lack of eruption of maxillary incisors are: ectopic position of the tooth bud (11), non-vital or ankylosed primary teeth (12), early extraction (or loss) of deciduous teeth, mucosal barriers in the path of

eruption that acts as a physical barrier to eruption, endocrine abnormalities, bone disease (5).

Diagnostic procedures

When the incisors do not erupt at the expected time, it is crucial for the clinician to determine the etiology and formulate an appropriate treatment plan. An accurate diagnosis may be obtained after thorough clinical and radiographic exams. It is also imperative to review a patient's medical history to rule out local or systemic conditions (6). Patients and parents should be questioned regarding any history of dental trauma even in early childhood (13). Diagnosis of the delayed tooth is usually made on the basis of clinical and radiographic findings (14). Clinical inspection and palpation of the alveolar process is recommended (15).

Clinical examination

An intra-oral examination should be undertaken to identify retained deciduous teeth, buccal-palatal swelling and availability of suitable space for the incisor (9mm for a central and 7 mm for lateral incisors) (5).

Important clinical signs are over-retention of the corresponding primary teeth while the contralateral permanent tooth has already erupted; substantial reduction in the available space for permanent tooth eruption or space closure; rotation and inclination of the adjacent teeth; elevation of the soft tissue of the palatal or labial mucosa depending on the tooth location; absence of a bulge in the buccal sulcus at 1-1.5 years before the expected time of tooth eruption (11, 14, 15).

The pathognomic sign which indicates impaction of a central incisor is the presence on the arch of the homolateral lateral incisor, as this points to an anomaly in the central incisor eruption process (8).

Deviation from normal sequence of eruption, e.g. lateral incisors erupt prior to the central incisor, or eruption of adjacent teeth occurred 6 months previously (with both incisors unerupted-lower incisors erupted one year previously), are other signs of delayed eruption of maxillary incisors (5,16).

The position of the adjacent teeth in the arch should be noted as well as whether they are upright or tilted toward the missing tooth. This may be helpful in determining the location of the unerupted tooth: once it is close to its normal eruption path the neighboring teeth may tilt, but when the unerupted tooth is far from its normal eruption path the adjacent teeth may close the space in a more bodily kind of movement (10).

Palpation of the alveolar region

Palpation is a valuable adjunct in final location of the unerupted tooth, it may also help in the radiographic evaluation (10).

On palpation of the area, the clinician is likely to encounter a palatal or labial bulge that will help determine the position of the unerupted tooth (6). In order to locate the crown of the impacted tooth, we locate a painless, incompressible, palatal or vestibular fibromucosal protruberance. An edentulous ridge with particularly small

mesiodistal and vestibulopalatal dimensions at its summit signifies that the tooth is impacted deeper (8).

Radiographic assessment

Diagnosis of impacted tooth is verified and its location determined through radiographic evaluation (13).

Panoramic radiograph is considered the standard radiographic first-step examination for treatment planning of impacted teeth because it imparts a low dose while giving the best radiographic survey (11,17). This film is useful because it is unique in that it will show the entire dentition as a whole (6), it may reveal the existence of an impacted tooth, the degree of root resorption for the corresponding primary tooth (15), and the depth of impaction (8).

Lateral cephalometric is another film that is particularly useful if there is a supernumerary tooth or dilacerations present because it allows visualization in several dimensions (6).

To be in a position to recommend the best line of treatment and to plan an appropriate strategy, the orthodontists requires the following information: the exact positions of the crown and root apex of the impacted tooth and the 3-dimensional orientation of its long axis; the proximity of the impacted tooth to the roots of the adjacent teeth; the presence of pathology such as supernumerary teeth, odontomes, apical granulomas or cysts, and their spatial relationship with the impacted tooth; the presence of adverse conditions affecting the adjacent teeth, including root resorption; the 3 dimensional anatomy of the crown and root of the impacted tooth (17).

CT has proved to be superior to other radiographic method in visualizing bone tissue: 3D CT images clearly show the intraosseus location, inclination and morphology of impacted teeth as well as the distance from adjacent structures (18,19).

Due to the highly detailed three-dimension information obtained, computerized tomography is the method of choice for accurately defining the position of an unerupted tooth and identifying any root resorption of adjacent teeth not detectable by other methods (6). The highly detailed information and the excellent tissue contrast without blurring and overlapping of adjacent structures outweighs the high radiation dose, limited availability, and high cost (18,20).

Three-dimensional imagery enables analysis of the precise location and orientation of impacted teeth, their situation relative to obstacles to eruption, their external and internal anatomy, the labial and palatal bone thickness; any resorption of the adjacent teeth or pathological bone loss; the presence or absence of a continuous radiolucent line between the root and the bone (possible ankylosis) (8).

Recently cone-beam CT (CBCT) has been introduced as a technique dedicated to the imaging of dental and maxillofacial structures. It has one-sixth of the radiation of computed tomography, is more time efficient, more cost effective, is still able to provide three dimensional images, excellent bone differentiation and an unlimited number of views (6,17). Its disadvantages include spatial resolution of subtle structures that is slightly inferior to that of CT and limited representation of soft tissues (due to the lower radiation dose) (17).

Predictive measurements of eruption evaluated on panoramic radiograph

Mitchell and Bennet in 1992 classified the distance of the unerupted permanent tooth from the occlusal plane as: *near*, vertical displacement within coronal 1/3 root of adjacent teeth, horizontal displacement < 1/2 tooth width; *mid*, vertical displacement within middle 1/3 root of adjacent tooth, horizontal displacement > 1/2 tooth width but < 1 tooth width; *far*, greater displacement (21) (Fig. 1). The maturity of the unerupted incisors is assessed by Cvek's classification. The teeth with wide, divergent root ends and a root estimated to be less than half the final length were allocated to group 1. Those teeth with roots between one-half and two-thirds the final root length were allocated to group 2, and those with roots two-thirds of their final length to group 3. The teeth with open apical foramina and nearly full root length were placed in group 4 and those with completed roots in group 5 (22) (Fig. 2).

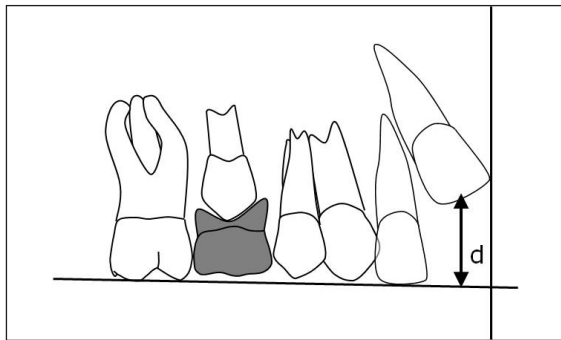


Figure 1. Mitchell and Bennet measurement.

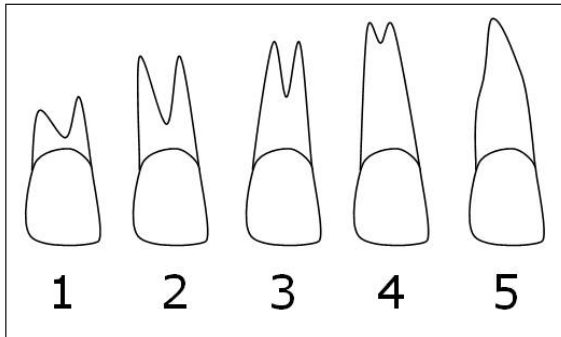


Figure 2. Cvek's classification.

Bryan et al. estimated the angle of the long axis of the unerupted permanent tooth to the mid-sagittal plane (23) (Fig. 3).

The vertical position of impacted permanent incisors in relation to the contralaterally erupted central incisor was analyzed by Smailiene et al.. To determine initial vertical position of impacted tooth, the thirds of the root length of the erupted contralateral central incisor were used. Three possible vertical positions of impacted incisor have been defined: v1- sector at the level of gingival third of the root; v2- sector at the level of middle third of the root; v3 – sector at the level of apical third of the root (9) (Fig. 4).

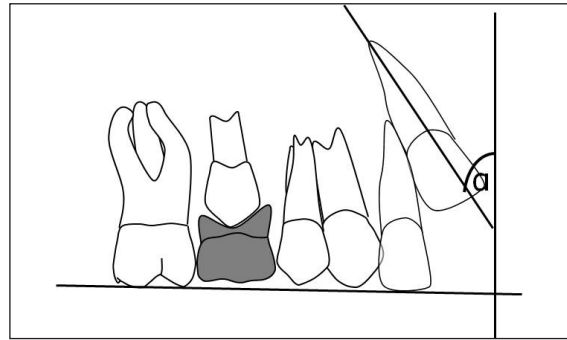


Figure 3. Brian et al. measurement.

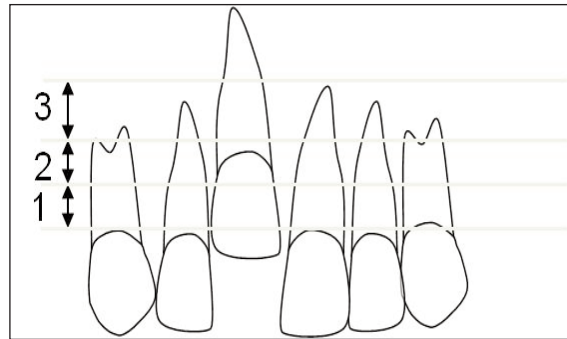


Figure 4. Smailiene et al. measurement.

Case report

Aim of this report was to show the interceptive management of a case with an impacted central maxillary incisor caused by odontoma in a young patient.

History and initial examination

A 9-year-old Caucasian girl was referred by his general dentist to the Department of Orthodontics of the University of Rome "Tor Vergata" for evaluation. The chief complaint was concern about an eruption disturbance, which had resulted in an unaesthetic appearance.

Diagnosis

The patient had balanced facial pattern with a convex profile, and an asymmetric ugly smile. Intraoral clinical examination showed a mixed dentition, an altered sequence of eruption and the absence of the maxillary right central incisor (Figs. 5, 6).

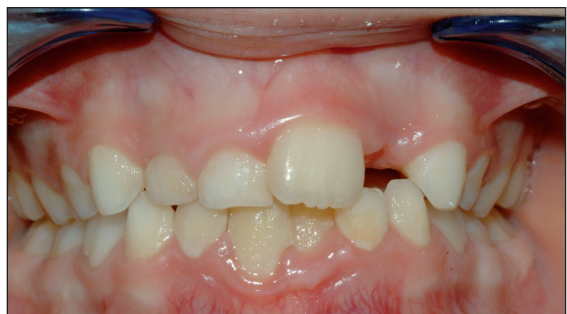

Figure 5. Pretreatment intraoral photograph, frontal view.

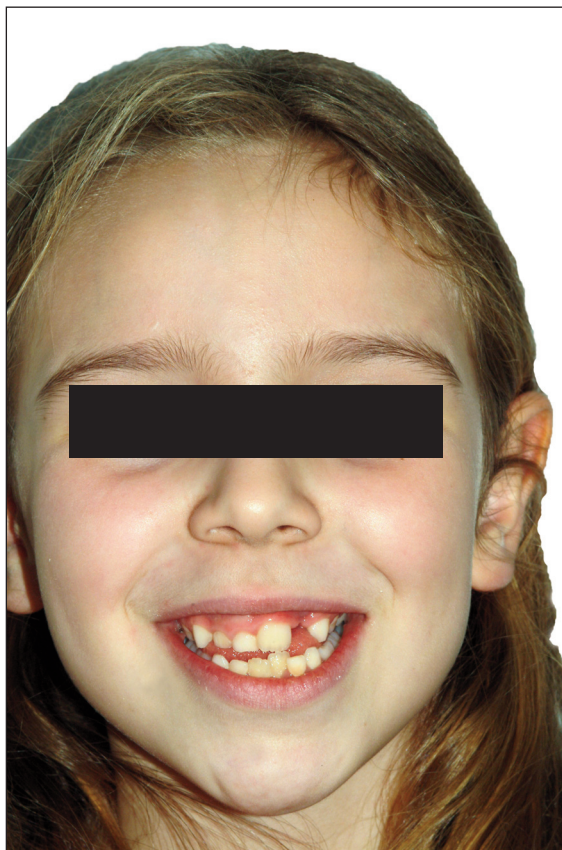

Figure 6. Pretreatment extraoral photograph, smile view.

Occlusal analysis revealed a molar Class I relationship. There was significant dental crowding in the upper and lower arches. The maxillary right central incisor was absent and the maxillary right lateral incisor was erupting with lack of space for the central incisor in the line of the arch. Overjet and overbite were 3 mm.

Radiological examinations are performed to complete clinical evaluation. The panoramic radiograph showed an odontoma located in the eruption path of permanent maxillary right incisor. It was not possible to exactly define the place of impacted incisor.

TC-Dentascan evaluation confirmed the presence of a composite odontoma in the body of the premaxilla, near the crown of impacted incisor.

Cephalometric analysis revealed a skeletal Class I malocclusion (ANB T1: 3°) and a dolichofacial pattern (FMA T1: 31°). Lower incisor showed good inclination on mandibular plane (IMPA T1: 92°).

The vertical position of the delayed permanent incisor in relation to the contralaterally erupted central incisor was $\nu 2$, while its angulation to the mid-sagittal plane was 20° (Fig. 7).

Treatment objectives

The following treatment objectives were established: 1) surgical removal of obstacle, 2) orthopedic maxillary expansion to recover space for the eruption of the incisor and to improve the intra osseous position of delayed maxillary incisor, 3) recovery of impacted tooth.

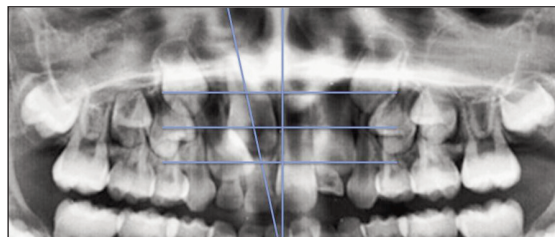


Figure 7. Measurements at T1.

Treatment plan

The odontoma was removed (2), and a Palatal Expander was bonded in the maxillary arch. The expansion of upper arch permitted to obtain good correction of the inter-arch relationship to favour teeth alignment, dental intercuspation and functional movements, and to improve intra osseous incisor position (24) (Fig. 8).

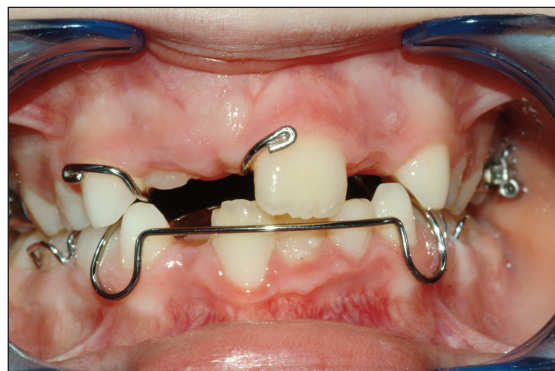


Figure 8. Intraoral frontal view during maxillary expansion.

The patient underwent a modify Rapid Maxillary Expander (25) designed with two Crozat wire Chromium Cobalt 0.028 arms soldered on the metal arms placed in a forward position; these arms are situated mesial to the right deciduous canine and to the left central incisor in order to create and maintain space for the absent tooth (Fig. 9). Activation of the screw was continued until the palatal cusps of the maxillary posterior teeth were in contact with the buccal cusps of the mandibular posterior teeth. After expansion, the patient was retained with the expander in place for 6 months. Following the retention period the expander was removed and the patient

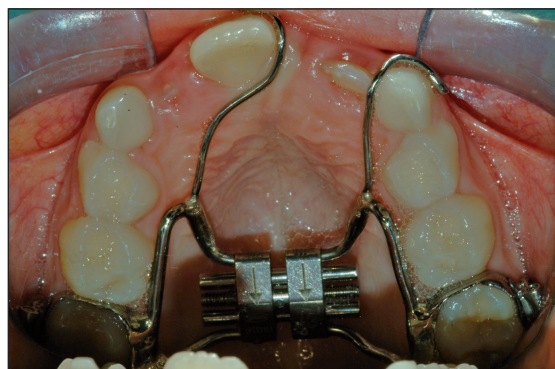


Figure 9. Intraoral occlusal view during maxillary expansion.

was made available for clinical examination and radiographs to monitor the intra osseous position of the delayed incisor.

On the panoramic radiographs the right central incisor showed an improvement of the initial vertical position (sector v1) and angulation (12°) (Fig. 10).

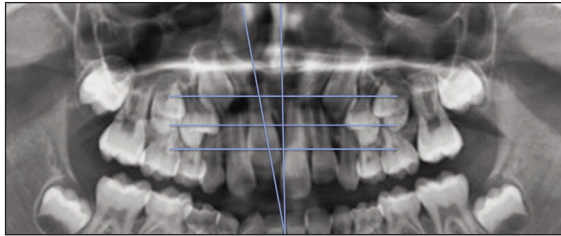


Figure 10. Measurements at T2.

8 months after odontoma removal a surgical exposure and traction of the impacted right central incisor were planned. Surgical exposure has been performed using a closed eruption technique (4), in which the raised flap that incorporates attached gingiva is fully replaced to its former position. In fact the gingival flap was sutured back in such a way that the bracketed crown was not exposed into the oral cavity. Special care was given to preserve the bone, mucoperiosteum and gingival tissues around the crown. The patient returned two weeks later, after soft tissue healing, and the elastomeric chain (60-90 g) was tied with tension to the open coil (8). The patient was seen every three weeks (Fig. 11).

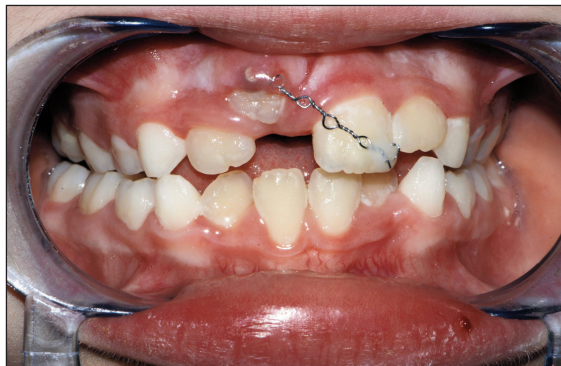

Figure 11. Intraoral frontal view of the orthodontic traction stages.

Once the impacted tooth had erupted, brackets were placed on the upper arch and it was tied to an archwire (0.016 x 0.022-in multibraid stainless steel) (Fig. 12). Interim radiographs were requested to verify the root positioning.

Active treatment took 14 months to recovery delayed incisor in dental arch. She is currently on routine patient recall. At the end of dentition the patient will be reevaluated for a second phase of treatment with fixed appliance.

Treatment results

The patient showed a good smile arch and balanced profile (Figs. 13, 14).

The impacted maxillary right central incisor was brought

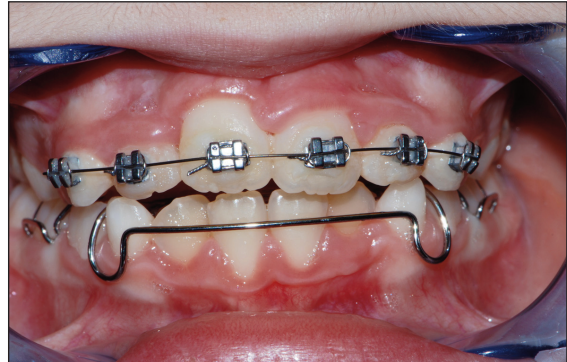


Figure 12. Intraoral frontal view at the end of orthodontic traction.

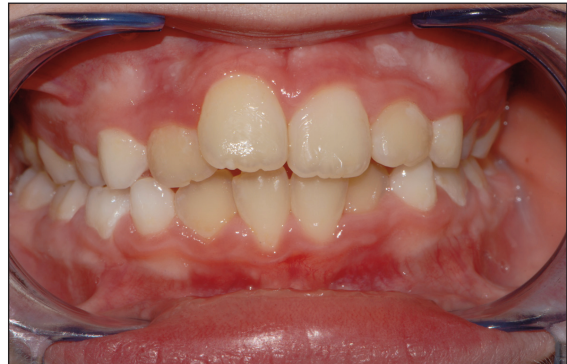

Figure 13. Post treatment intraoral photograph, frontal view.

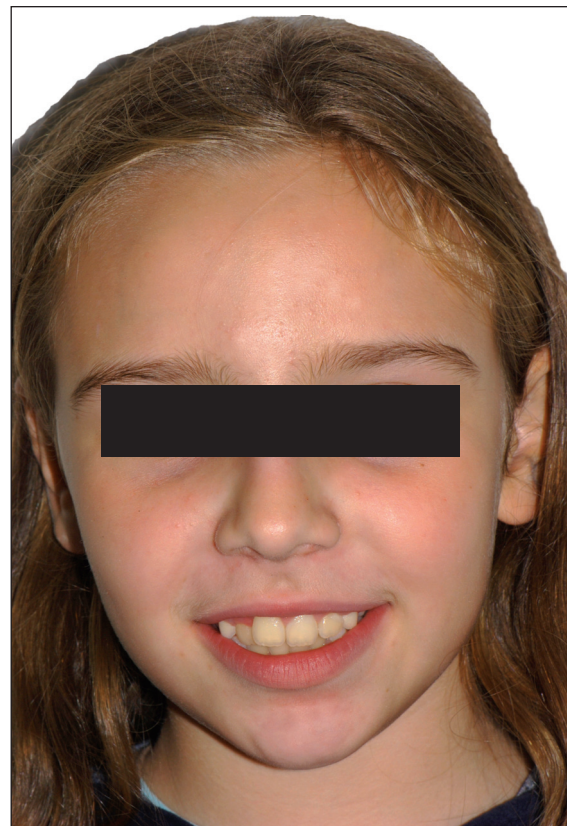

Figure 14. Post treatment extraoral photograph, smile view.

into proper position. The final appearance of the tooth was esthetically pleasing, with gingival margins at the same level with similar clinical crowns sizes. The tooth responded well to vitality and did not show abnormalities in crown shape. From a periodontal point of view a band of labial keratinized gingival measuring 4 mm was present, and pocket depth ranged from 1 to 2 mm.

The final radiographs indicated intact roots, proper root alignment, and no root disease.

A skeletal class I (ANB T1:3°, T2:3°) was maintained. An ideal overbite (T1: 3mm, T2: 2mm) and overjet (T1: 2mm, T2: 2mm) were established and a Class I molar and canine relationship was presented. Upper and lower incisors showed good inclination (IMPA T1: 92°, T2: 91°; U1^AFH T1: 108°, T2: 113°).

Conclusions

When the incisors do not erupt at the expected time, it is crucial for the clinician to determine the exact etiology and formulate an appropriate treatment plan.

Early diagnosis of delayed eruption is important and it is made on the basis of clinical and radiographic findings. The use of TC-dentascan or CBCT should be considered a routine diagnostic aid in cases where the treatment of impacted teeth is being considered, because it gives highly detailed three-dimension information.

The interceptive treatment consists of surgical removal of obstacles followed by the orthopaedic rapid maxillary expansion and creation of space for the delayed tooth through Modify Rapid Maxillary Expander, which permits to improve intraosseous incisor position.

In the described case, thanks to the interceptive approach, satisfactory functional and aesthetic results were obtained, gingival attachment was maintained and integrity of the dental arch was restored.

References

1. Pinho T, Neves M, Alves C. Impacted maxillary central incisor: surgical exposure and orthodontic treatment. *Am J Orthod Dentofacial Orthop* 2011 Aug; 140(2): 256-265.
2. Kuroi J. Early treatment of tooth eruption disturbances. *Am J Orthod Dentofacial Orthop* 2002; 121: 588-591.
3. Kolokitha OE, Papadopoulou AK. Impaction and apical root angulation of the maxillary central incisors due to supernumerary teeth: combined surgical and orthodontic treatment. case report. *Am J Orthod Dentofacial Orthop* 2008 Jul; 134(1): 153-160.
4. Becker A, Brin I, Ben-Bassat Y, Zilberman Y, Chaushu S. Closed-eruption surgical technique for impacted maxillary incisors: a postorthodontic periodontal evaluation. *AJODO* 2002; 122: 9-14.
5. Jones J. W. A Medico-legal Review of Some Current UK Guidelines in Orthodontics: A personal View. *J. Orthod* 1999; 26: 307-324.
6. Huber KL, Suri L, Taneja P. Eruption disturbances of the maxillary incisors: a literature review 1: *J Clin Pediatr Dent* 2008; 32(3): 221-230.
7. Cozza P, Marino A, Laganà G. Interceptive management of eruption disturbances: case report. *J Clin Pediatr Dent* 2004; 29(1): 1-4.
8. Chokron A, Reveret S, Salmon B, Vermelin L. Strategies for treating an impacted maxillary central incisor. *Int Orthod* 2010 Jun; 8(2): 152-176.
9. Smailiene D, Sidlauskas A, Bucinskiene J. Impaction of the central maxillary incisor associated with supernumerary teeth: initial position and spontaneous eruption timing. *Stomatologija* 2006; 8(4): 103-107.
10. Brin I, Zilberman Y, Azaz B. The unerupted maxillary central incisor: review of its etiology and treatment. *ASDC J Dent Child* 1982 Sep-Oct; 49(5): 352-356.
11. Becker A. The orthodontic treatment of impacted teeth. 1998.
12. Betts A, Camilleri GE. A review of 47 cases of unerupted maxillary incisors. *International Journal of Paediatric Dentistry* 1999; 9: 285-292.
13. Douglas DE. Management of impacted anterior teeth utilizing basic orthodontic principles. *ASDC J Dent Child* 1989; 56(5): 353-357.
14. Duncan WK, Ashrafi MH, Meister F Jr, Pruhs RJ. Management of the unerupted maxillary anterior tooth. *J Am Dent Assoc* 1983; 106(5): 640-644.
15. Kavadia-Tsatala S. Orthodontic and periodontal considerations in managing teeth exhibiting significant delay in eruption. *World Journal of Orthodontics* 2004; vol.5 N 3.
16. Roberts-Harry D, Sandy J. Orthodontics. Part 10: Impacted teeth. *Br Dent J* 2004; 196(6): 319-327.
17. Chaushu S, Chaushu G, Becker A. The role of digital volume tomography in the imaging of impacted teeth. *World J Orthod* 2004; 5(2): 120-132.
18. Sawamura T, Minowa K, Nakamura M. Impacted teeth in the maxilla: usefulness of 3D dental-CT for preoperative evaluation. *Eur J radiol* 2003; 47: 221-226.
19. Chen Y, Duan P, Meng Y, Chen Y. Three-dimensional spiral computed tomographic imaging: a new approach to the diagnosis and treatment planning of impacted teeth. *Am J Orthod Dentofacial Orthop* 2006 Jul; 130(1): 112-116.
20. Walker L, Enciso R, Mah J. Three-dimensional localization of maxillary canines with cone-beam computed tomography. *Am J Orthod Dentofacial Orthop* 2005 Oct; 128(4): 418-423.
21. Mitchell L, Bennet TG. Supernumerary teeth causing delayed eruption. A retrospective study. *Br J Orthod* 1992; 19(1): 41-48.
22. Cvek M. Prognosis of luxated non-vital maxillary incisors treated with calcium hydroxide and filled with gutta percha. A retrospective clinical study. *Endod Dent Traumatol* 1992; 8: 45-55.
23. Bryan RA, Cole BO, Welbury RR. Retrospective analysis of factors influencing the eruption of delayed permanent incisors after supernumerary tooth removal. *Eur J Paediatr Dent* 2005; 6(2): 84-89.
24. Baccetti T, Mucedero M, Leonardi M, Cozza P. Interceptive treatment of palatal impaction of maxillary canines with rapid maxillary expansion: A randomized clinical trial. *Am J Orthod Dentofacial Orthop* 2009; 136: 657-661.
25. Cozza P, Giancotti A, Petrosino A. Rapid Palatal Expansion in Mixed Dentition using a Modified Expander: a cephalometric investigation. *J Orthod* 2001; 28: 129-134.