

The Application of a New Cyanoacrylate Glue in Pediatric Surgery for Fistula Closure

Seyed Mohammad Vahid Hosseini¹,
Ali Bahador¹, Hamid Reza Foroutan²,
Babak Sabet³, Bita Geramizadeh⁴,
Mohammad Zarenezhad⁵

Abstract

Surgical glues have been used in pediatric surgery because of the fragility of tissue, and to prevent major surgeries. The present report describes our experience with using a new cyanoacrylate Glubran 2 (Viareggio, Italy) in the treatment of five cases of tracheoesophageal atresia with fistula (one fistula protection, three recurrent fistula, and one unstable patients), two cases of hypospadias, one case of vesicutanouse fistula after bladder extrophy, and one case of cloacal extrophy from January–December 2008. Three cases of recurrent tracheoesophageal atresia with fistula were treated by bronchoscopic glue injection. The other two cases benefited from glue through its ability to plug the fistula and to act as a protecting layer on anastomosis. In two cases with hypospadias excessive use of the glue caused skin necrosis, which was repaired. The wounds of cloacal extrophy were protected from nearby colostomy contamination and infection, and the vesicocutanouse fistula was closed by deepithelialization and sealing with glue. Based on the outcomes of the cases, it may be possible to suggest that Glubran 2 may be used safely in Pediatric Surgery as a sealant for the prevention and treatment of fistulas.

Iran J Med Sci 2011; 36(1): 54-56.

Keywords • Glubran 2 • surgical glues • tracheoesophageal atresia with fistula • hypospadias • fistula

Introduction

A number of glues have been used in pediatric surgery because of tissue fragility, and to protect reconstructive repair of injured organs. They have also been used to prevent in a small child a major surgery, which is usually associated with a high risk of mortality or morbidity. Glues, such as fibrin glue, have been shown to lack durability and impermeability to bacteria or fluid.^{1,2} However, a new cyanoacrylate glue (GLUBRAN 2, GEM, Viareggio, Italy), which is FDA approved, has opened a new horizon in reconstructive and minimally invasive surgeries. It may be used either internal or externally, and has an easy application, high adhesive properties, antiseptic barrier, and total impermeability to liquid.³

The present study describes our experience with using cyanoacrylate glue in the treatment and prevention of fistulas in pediatric surgery.

Materials and Methods

The study was performed at Nemazee Hospital, a teaching hospital associated with Shiraz University of Medical Sciences, from January through December 2008.

¹Departments of General surgery,
²Pediatric Surgery, ⁴Pathology,
Medical School,
Shiraz University of Medical Sciences,
Shiraz, Iran.
³Department of surgery,
Medical School,
Semnan University of Medical Sciences,
Semnan, Iran.
⁵Member of Iranian National Legal
Medicine Research Center,
Shiraz, Iran.

Correspondence:

Seyed Mohammad Vahid Hosseini MD,
Department of Surgery,
Faghihi Hospital,
Shiraz, Iran.

Fax: +98 711 6239105

Tel: +98 711 2331006

Email: psrg.sums@yahoo.com

Received: 1 December 2009

Revised: 8 July 2010

Accepted: 18 July 2010

The new polymerized cyanoacrylate glue was used during operation for the reinforcement or prevention of reoperation in fistula closure in pediatric surgery. The objectives of the study and likely risks involved were described to patients' parents, and written parental consents were obtained before using the product. The trial included five cases with tracheoesophageal fistula, one case of penoscrotal hypospadias, one case of urethocutaneous fistula and two cases of extrophy complex with vesicocutaneous fistula.

1- Cases with Tracheoesophageal Fistula

The glue was used in five cases of tracheoesophageal atresia and fistula (TEF). In a 2-day-old girl the glue was used to cover the native esophagus and fistula to minimize the incidence of reopening due to fragile tissue. Three of the patients (with an age range of two to eight months) had recurrent fistula following the esophageal dilatation. In such patients, under endoscopic guidance, the fistulas were first de-epithelialized with a Bugbee diathermy electrode (5-15 W), and then were sealed with the glue completely. Antibiotic (cefexime [Tolid Daro, Tehran, Iran] at 50 mg/kg/day) were used during the treatment. The closure of the fistula was checked by bronchoscopy four weeks later (figure 1). We also used the glue in a premature 5-day-old girl who had a very low birth weight and pneumonia. She underwent temporary sealing of the large carinal fistula with bronchoscope,⁴ for stabilizing her before the definitive operation.

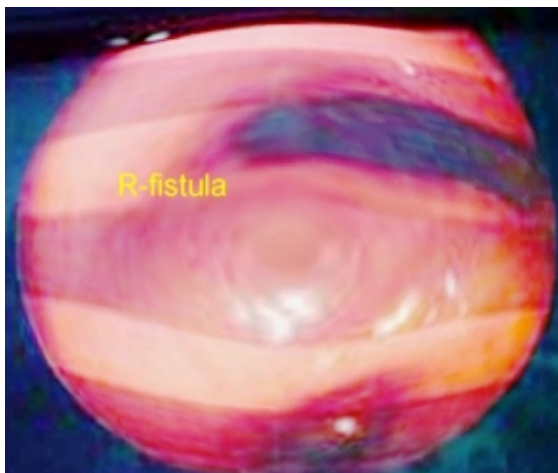


Figure 1: The posterior aspect of the closure of recurrent tracheoesophageal fistula 1.5 cm above carina

The postoperative recurrent TEF were closed by transbronchoscopic glue injection within 4 weeks. They were followed up for six months, during which no recurrence occurred.

One TEF case with a fragile anastomosis was protected by covering the anastomosis with glue, which prevented anastomosis leakage. The unstable TEF case with pneumonia, which had a temporary fistula closure, underwent a definitive operation later and survived.

2- Pediatric Urological Cases

Two pediatric urological cases were also used to examine the effectiveness of the glue. One was a two-year-old boy, who was a case of penoscrotal hypospadias, and the other was a 4-year-old boy with urethocutaneous fistula. Both underwent glue coverage after surgery using a thin layer of glue on suture line of urethroplasty, and a thick layer of glue between dartus flap and skin coverage (figure 2,3).⁵ Two extrophy complex cases had vesicocutaneous fistulas. The fistula tracts were first deepithelialized, and then were filled by glue. The free drainage of bladder was performed as well.

The thick layer of glue, which was used between dartus flap and skin in the two cases of hypospadias caused necrosis of skin; therefore, the necrosis of skin was repaired again. A thin layer of glue on urethroplasty, not only caused the dehiscence of urethroplasty, but also helped the neourethra from collapsing after the removal of the temporary stent. Both vesicocutaneous fistulas in extrophy complex were closed in a matter of eight weeks.

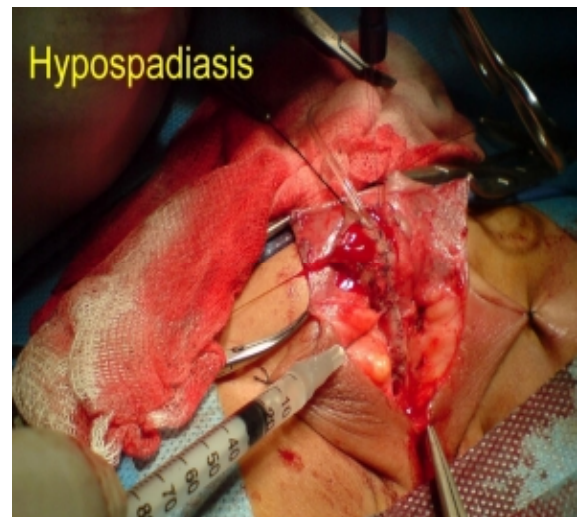


Figure 2: The placement of glubran 2 on urethroplasty in severe hpospadias

Discussion

Fibrin glue has been widely used for tissue repair, but compared to a new generation of cyanoacrylate without cyanide toxicity, it has disadvantage of permeability and easy

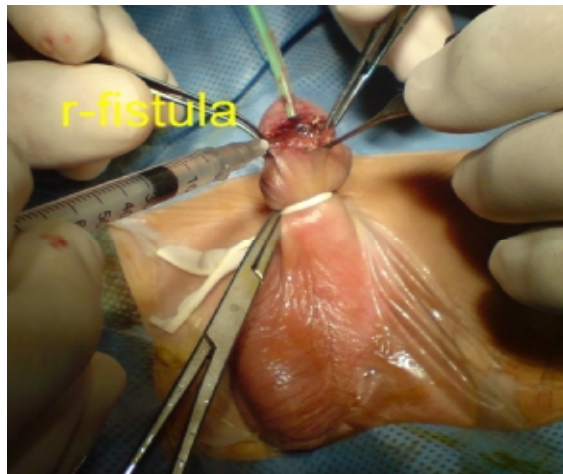


Figure 3: A dissected urethrocutaneous fistula in hypospadias, which was reinforced by glubran

degradability.³ The privilege of new polymer of glue is that when it comes in contact with living tissues in a moist environment, it polymerizes rapidly to create a thin elastic film, and is not impaired by blood or organic fluids.^{1,2} Moreover, the glue has the advantage that it does not cause tissue necrosis or adverse reaction when it is used as a protective layer or an easier way of the treatment for postoperative complications.²

Open surgical approaches for recurrent tracheoesophageal fistulas have been associated with substantial rates of morbidity and mortality. The outcomes of the present cases suggest that compared to a number of previous studies,^{3,4,6,7} we had a lower mortality and a high rate of cure outcome.

Urethrocutaneous fistula is one of the most common complications after hypospadias surgery.⁴ Fibrin glue has been effectively used in the treatment and prevention of fistula tract.⁶ However, high durability and impermeability of new cyanoacrylate glue was helpful in protecting the wounds from bacteria and dehiscence.

Conclusion

The findings of the present study suggest that it might be possible to recommend Glubran 2 glue whenever there is a need for a safe material as a sealant, or a protective layer to obviate a major surgery for fistula closure.

Conflict of Interest: None declared

References

- 1 Gandini R, Angelopoulos G, Konda D, et al. Transcatheter embolization of a large symptomatic pelvic arteriovenous malformation with Glubran 2 acrylic glue. *Cardiovasc Intervent Radiol* 2008; 31: 1030-3.
- 2 Masetti L, Bellei E, Dalla F, Dalpozzo B. Use of Glubran 2 in Ophthalmic Surgery: A preliminary study. *Vet Res Commun* 2007; 31: 305-7.
- 3 Upadhyaya VD, Gopal SC, Gangopadhyaya AN, et al. Role of fibrin glue as a sealant to esophageal anastomosis in cases of congenital esophageal atresia with tracheoesophageal fistula. *World J Surg* 2007; 31: 2412-5.
- 4 Richter GT, Ryckman F, Brown RL, Rutter MJ. Endoscopic management of recurrent tracheoesophageal fistula. *J Pediatr Surg* 2008; 43: 238-45.
- 5 Gopal SC, Gangopadhyay AN, Mohan TV, et al. Use of fibrin glue in preventing urethrocutaneous fistula after hypospadias repair. *J Pediatr Surg* 2008; 43: 1869-72.
- 6 Yurtçu M, Arbag H, Çağlayan O, et al. The effect of cyanoacrylate in esophagocutaneous leakages occurring after esophageal anastomosis. *Int J Pediatr Otorhinolaryngol* 2009; 73: 1053-5.
- 7 Elemen L, Sarimurat N, Ayik B, et al. Is the use of cyanoacrylate in intestinal anastomosis a good and reliable alternative? *J Pediatr Surg* 2009; 44: 581-6.