

Anisakiasis

JUDY A. SAKANARI* AND JAMES H. MCKERROW

Department of Pathology, University of California, San Francisco, California 94143

INTRODUCTION	278
LIFE CYCLE.....	278
CLINICAL PRESENTATION	278
DIAGNOSIS AND TREATMENT	278
Endoscopy	279
Radiologic Films	279
Immunodiagnostic Assays	279
Worm Morphology	280
Identification of <i>Anisakis</i> sp. in Histologic Section	280
HISTOPATHOLOGY	280
IMMUNOLOGIC RESPONSE TO ANISAKIS INFECTION.....	281
EPIDEMIOLOGY.....	281
PUBLIC HEALTH IMPORTANCE	282
ACKNOWLEDGMENTS.....	283
LITERATURE CITED.....	283

INTRODUCTION

Anisakiasis is a human disease caused by the accidental ingestion of larval nematodes belonging to the family *Anisakidae*. Humans acquire the infection by eating raw seafood dishes such as sushi, sashimi, ceviche, and lomi-lomi or undercooked fish and squid dishes.

There are three types of anisakid larvae that have been implicated in human disease: *Anisakis* (sensu lato), *Pseudoterranova* (= *Phocanema*) (sensu lato), and *Contracaecum* (sensu lato) species. Because the number of case reports attributed to the latter group is rare (15, 29, 48), we will focus our review on *Anisakis* and *Pseudoterranova* species only.

There are two forms of anisakiasis: noninvasive (or luminal) and invasive. The noninvasive form is generally asymptomatic and involves no tissue penetration by the worm. This form gives rise to the "tingling throat syndrome," which occurs when worms migrate back up the esophagus into the oropharynx. These worms are often coughed up or felt wiggling around in the mouth between the gums and cheek 1 day to 2 weeks after ingestion of the infected meal (11, 32). Generally, larvae belonging to the genus *Pseudoterranova* are noninvasive, but penetration into tissues has been reported (28, 35, 38).

Invasive anisakiasis occurs when larvae attach to, embed in, or penetrate host tissues. *Anisakis* spp. are most often implicated in this type of anisakiasis. They have been found in the mucosa or submucosa of the stomach and intestine and have migrated to other tissues such as the omentum, pancreas, liver, and probably the lung (34, 58, 77).

LIFE CYCLE

The life cycles of these anisakid nematodes have not been completely described, but ecological surveys and laboratory experiments (48, 61, 62, 75) suggest that they involve three hosts (Fig. 1). Adult worms are found in the stomachs of marine mammals such as dolphins, sea lions, and whales. Female worms lay eggs which exit the body in the feces of

the marine mammal and embryonate in the seawater (Fig. 1a). Second-stage larvae that hatch out (Fig. 1b) are eaten by small crustaceans such as krill (Fig. 1c). This infected first intermediate host is then eaten by marine fishes and squid (Fig. 1d), in which the third-stage larvae encyst. The life cycle is completed when the marine mammals eat these infected fish or squid (Fig. 1f). The crustacean host theoretically could infect the marine mammals, in which case fish and squid would act only as transport hosts, but this mode of infection has not been documented.

Human infection is accidental (Fig. 1e), and humans are not suitable hosts for these parasites. No multiplication occurs in humans, and no reproductively mature anisakid nematodes have been reported from human infections (59).

CLINICAL PRESENTATION

Symptoms of acute gastric anisakiasis include sudden epigastric pain, nausea, vomiting, diarrhea, and urticaria and can occur 1 to 12 h after the infected meal (12, 48, 63), with most occurring within 6 h (3). Many acute cases are misdiagnosed and the infection becomes chronic, with patients having a history of intermittent abdominal pain, nausea, and vomiting lasting from weeks to several years (23, 48). The time to onset of clinical symptoms with intestinal anisakiasis in most cases is within 48 h (3), and the duration of abdominal pain, nausea, and vomiting is about 1 to 5 days (23). Patients also exhibit a slight elevation of temperature and moderate leukocytosis (10,000 to 15,000 leukocytes per mm³) (27). Eosinophil counts vary widely (4 to 41%) in reported cases. Abdominal tenderness is diffuse, and pain on pressure is not confined to specific areas of the abdomen. In one survey, occult blood was present in gastric juices and stools in 70% of the gastrointestinal cases (77).

DIAGNOSIS AND TREATMENT

Because symptoms of anisakiasis are vague, the disease is often misdiagnosed. In a clinicopathologic study of 92 cases of anisakiasis in Japan, over 60% of the cases were diagnosed preoperatively as appendicitis, acute abdomen, gas-

* Corresponding author.

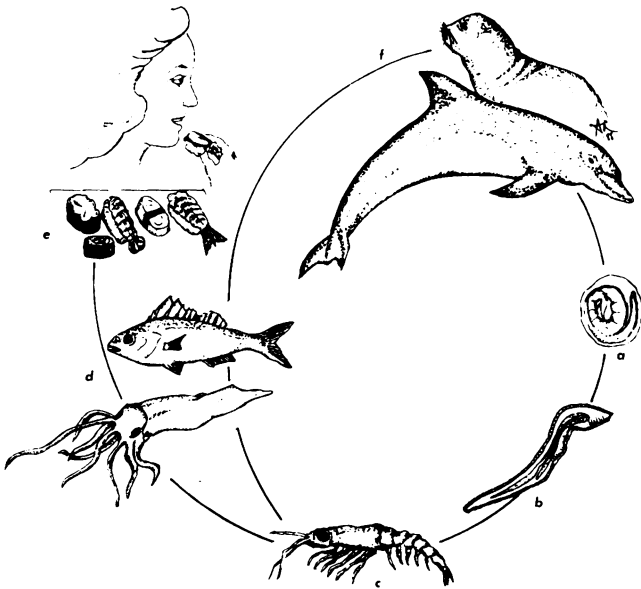


FIG. 1. Life cycle of *Anisakis* sp. Eggs (a) from adult *Anisakis* species exit the body with the feces of marine mammals. A larva hatches out (b) and is eaten by microcrustaceans such as krill (c). Squid and fish (d) become infected by eating the infected krill. Humans are accidental hosts and become infected by ingesting (e) raw or improperly cooked seafood dishes. The life cycle is completed when marine mammals eat squid and fish infected with *Anisakis* larvae.

tric tumor or cancer, ileitis, cholecystitis, diverticulitis, tuberculous peritonitis, and cancer of the pancreas (77). Another retrospective study in Japan found that anisakiasis was also often misdiagnosed as Crohn's disease (23).

In another study in which gastric anisakiasis and intestinal anisakiasis were separately assessed, gastric anisakiasis was preoperatively misdiagnosed as stomach ulcer, stomach cancer, stomach polyps, and stomach tumors in 86% (132 of 153) of the cases; intestinal anisakiasis was misdiagnosed as acute appendicitis and acute regional ileitis in 52% (34 of 66) of the cases (48).

Endoscopy

In 1968, Namiki and co-workers first successfully diagnosed and treated gastric anisakiasis in Japan, using an endoscope (cited in reference 1). The fiberoptic endoscope with biopsy forceps continues to be the most important tool for the diagnosis and treatment of gastric anisakiasis (1, 49, 63). It has even been used successfully to treat two cases of duodenal anisakiasis (9, 33). Endoscopy allows the physician to remove the larva with the biopsy forceps and identify the worm morphologically. Early removal of the worm is believed to prevent the formation of eosinophilic granulomas caused by the allergic reaction to the degenerating worm in chronic infections.

Radiologic Films

In a study of 178 patients by Sugimachi et al. (63), worms were found in all regions of the mucosal surface of the stomach. In the mucosa, there was local or generalized edema with or without erosions. Pseudotumor formation was observed in 36% (64 of 178) of the patients, and swelling

of gastric folds was present in 35.4% (63 of 178) of the cases. After removal of the worm, pain disappeared within a few hours. Although ulcer formation was rare, antacids were nevertheless recommended.

Upper gastrointestinal tract X rays have also been helpful in the diagnosis of this disease. Thickened, narrowed, and obstructed areas caused by the host response to the worm can be seen (1, 2, 23, 35, 53, 55, 63, 72). A filling defect seen in the ascending colon consistent with the appearance of an *Anisakis* larva aided in the confirmation of one case (24). Threadlike gastric filling defects approximately 30 mm in length were observed in 47.7% (62 of 130) of gastric anisakiasis cases in a study by Sugimachi et al. (63). It is important to note, however, that all 178 patients in this particular study had their worms removed by endoscopy and, hence, were definitively diagnosed.

While surgery is often necessary for resection of the lesions, two patients with radiographic evidence of small-bowel obstruction due to anisakiasis did not undergo surgery (72). Follow-up examination with barium revealed no abnormalities after 4 days in one case and after 3 weeks in the other. Verhamme and Ramboer (72) advocate conservative treatment in the absence of dramatic abdominal signs even though the patient history may suggest the diagnosis of anisakiasis. They further recommend the use of corticosteroids during treatment to decrease the inflammatory response to the worm. However, no large controlled studies of steroid use in anisakiasis have been performed. No anthelmintic drugs are currently considered useful in anisakiasis.

Immunodiagnostic Assays

Various immunologic assays have been used to diagnose anisakiasis, including the intradermal skin test (3, 48), complement fixation test (48), immunofluorescent-antibody test (48, 59, 63, 64), immunodiffusion test (34, 42), immunoelectrophoretic assays (19, 34), enzyme-linked immunosorbent assay (59), and radio-allergosorbent test (RAST) (12, 19, 59). There is no routine clinical laboratory testing for anisakiasis, and practical applications using any one of these assays are of limited value, because sera from known anisakiasis patients cross-react with antigens from closely related nematode species (e.g., *Ascaris* and *Toxocara* species) or because normal human sera give false-positive results with *Anisakis* antigens.

Of all serodiagnostic assays in use, the RAST may be the most sensitive and specific. The RAST is a radioimmunologic assay that indirectly measures the amount of immunoglobulin E (IgE) that binds to parasite antigens which have been coupled to cyanogen bromide-activated beads. Radioactively labeled anti-IgE which has reacted with the antigen-antibody complex is then quantified by a scintillation counter. Sera from four confirmed anisakiasis patients were RAST positive against *Anisakis* antigen and RAST negative against *Toxocara* antigens in a study by Desowitz et al. (19). IgE titers to *Anisakis* antigens were shown to be elevated for up to 2 (12) and 6 (59) months postinfection when assayed by the RAST. Positive results from the RAST must be evaluated with some caution, however, because these studies also showed that known *Ascaris*-positive and known *Toxocara*-positive sera cross-reacted with *Anisakis* antigens. Hence, this assay is not useful for patients with previous *Ascaris* or *Toxocara* infections.

Use of monoclonal antibodies specific to *Anisakis* antigens may alleviate this problem. Monoclonal antibodies have been prepared to larval *Anisakis* antigens that do not cross-

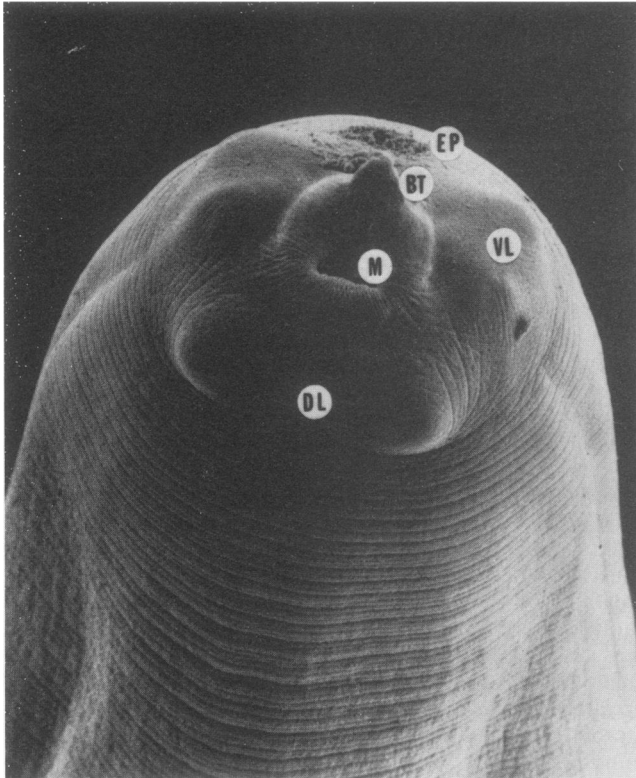


FIG. 2. Scanning electron micrograph of a third-stage larva of *A. simplex*. The anterior end of the worm has the excretory pore (EP), boring tooth (BT), mouth (M), ventrolateral lips (VL), and dorsolateral lips (DL). Note that although the outline of developing lips is apparent under the cuticle, the lips are not present on this larval stage.

react with *Ascaris*, *Toxocara*, *Trichinella*, or *Echinococcus* spp. and are being developed for use in a serodiagnostic assay (65, 66). In addition, we are currently cloning larval *Anisakis* antigens from a complementary deoxyribonucleic acid expression library for use as serodiagnostic reagents for anisakiasis.

Worm Morphology

If intact worms are expectorated, passed in stools, or removed from tissues, they can be identified by placing the worm in 70% ethanol and clearing it in liquid phenol (100%) until the worm is translucent. Clearing takes a few hours, and worms may be left immersed in the phenol overnight. It may be necessary to roll the worm around on the microscope slide to see the distinguishing features. The following is a description of some key features useful for identifying anisakid larvae. For more details on the morphometrics of the worms, see references 10, 32, 48, and 61. Drawings or photographs have also been published in the following references: *Anisakis* spp., references 18, 48, 57, and 71; *Pseudoterranova* spp., references 7 and 38; and both, in addition to other anisakid nematodes, references 44, 47, and 56.

Figure 2 is a scanning electron micrograph of a third-stage anisakid larva. The following are gross characteristics: (i) cuticle has fine striations; (ii) three bilobed lips are present, one dorsal and two ventrolateral; (iii) a boring tooth is present (projects anteroventrally, ventral to the mouth); (iv) an excretory pore lies between the ventrolateral lips; (v)

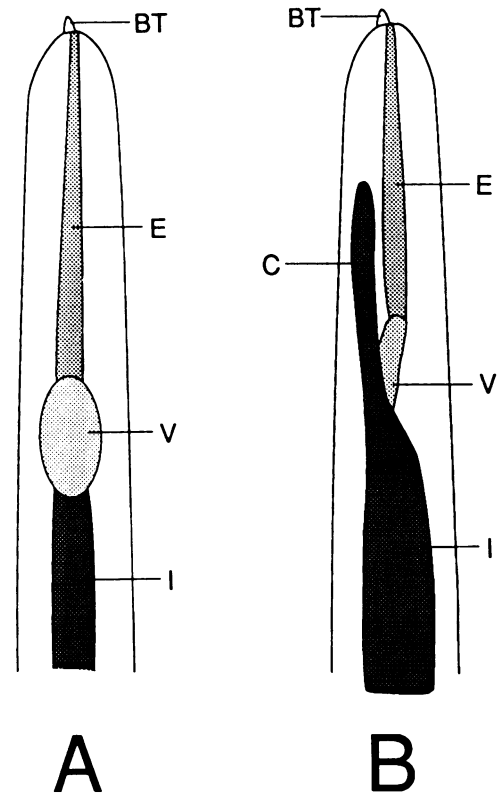


FIG. 3. Diagram of the morphology of (A) *Anisakis* sp. (sensu lato) and (B) *Pseudoterranova* sp. (sensu lato). Anterior portion of the worms showing the boring tooth (BT), esophagus (E), ventriculus (V), cecum (C), and intestine (I).

Anisakis sp. (sensu lato) has a simple digestive tube, esophagus-ventriculus-intestine (Fig. 3a), and *Pseudoterranova* sp. (sensu lato) has esophagus-ventriculus-intestine with anteriorly directed cecum (Fig. 3b); (vi) *Anisakis* total length is 10 to 29 mm and its width is 0.44 to 0.54 mm; *Pseudoterranova* total length is 25 to 50 mm and its width is 0.3 to 1.2 mm.

Identification of *Anisakis* sp. in Histologic Section

Anisakis sp. may be identified in histologic sections by the following characteristics: (i) distinctive Y-shaped lateral chords; (ii) no lateral alae (winglike projections) extending from cuticle as with larval *Ascaris* sp.; and (iii) 60 to 90 muscle cells per quadrant; 60 to 80 cells in the intestine.

Oshima (48) noted that *Anisakis* sp. can be distinguished from *Pseudoterranova* sp. by the following: *Pseudoterranova* sp. has butterfly-shaped lateral chords, more than 100 intestinal cells, and an intestinal cecum.

Additional photographs or drawings of histologic sections of *Anisakis* sp. are found in references 8, 21, 23, 48, 58, 59, 72, and 76. Other histologic sections of anisakid nematodes have been published (13, 16, 51).

HISTOPATHOLOGY

As a result of studies in Japan, the histopathologic lesions have been classified into five types (48).

(i) The early primary infections are characterized by infiltration and proliferation of neutrophils with few eosinophils and foreign body giant cells. Little edema, fibrinous exudation, hemorrhage, or vascular damage is present.

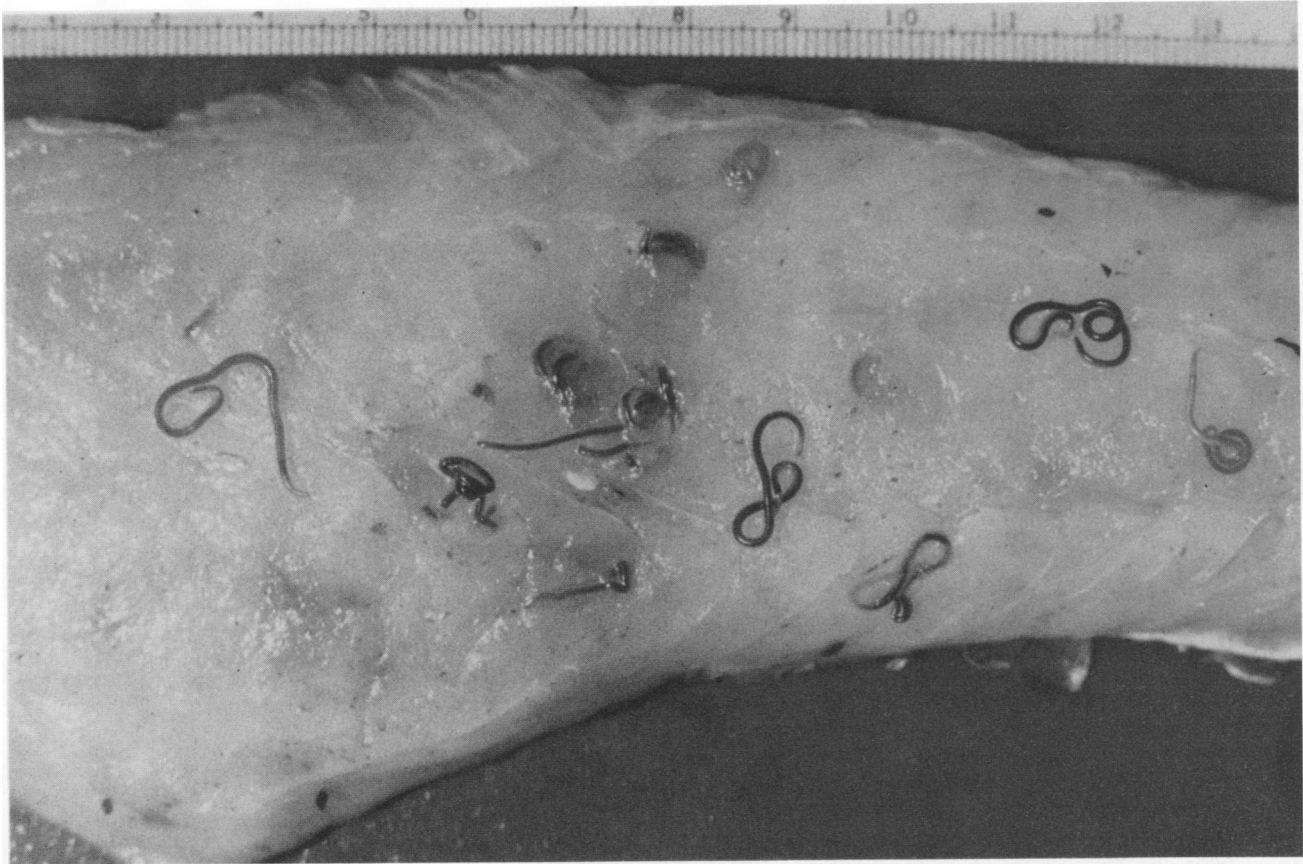


FIG. 4. Numerous *Pseudoterranova* larvae in a fillet of rockfish (photo by M. Moser, University of California, Santa Cruz). Note that *Anisakis* larvae are much more difficult to see with the unaided eye because they are smaller than *Pseudoterranova* larvae and are lighter in color.

(ii) Within the first week of an acute intestinal infection, there may be edematous thickening of the submucosa with massive eosinophilic infiltration along with lymphocytes, monocytes, neutrophils, and plasma cells.

(iii) In cases of chronic gastric and intestinal anisakiasis, there may be abscesses characterized by necrosis and hemorrhage with eosinophilic infiltration.

(iv) Alternatively, in gastric anisakiasis of >6 months in duration, eosinophilic infiltration of the granuloma may be less extensive and lymphocytes may predominate. Foreign body giant cells may surround the degenerated larva.

(v) In advanced disease (6 months to years), the abscess or granulomatous inflammation may be replaced by granulation tissue with some eosinophilic infiltration. Only remnants of the degenerated larva (or no worm at all) are present in the center of the lesion.

IMMUNOLOGIC RESPONSE TO ANISAKIS INFECTION

Research over the past 8 years has clearly defined both a humoral and a cell-mediated response to *Anisakis* infections in humans. Histopathologic studies of *Anisakis* infections in humans invariably show both eosinophils and macrophages responding to the migrating helminth larvae. The importance of these cells in the immune response to *Anisakis* larvae is not unexpected, since they have been shown to play a similar role in the immune response to other helminthic parasites (4, 73).

A humoral immune response has also been identified, and attention has recently been turned to the presence of potent

immunogens in the excretory/secretory (ES) products of third-stage L_3 larvae. Raybourne et al. (54) showed that 66 to 95-kilodalton proteins were recognized by human antibodies to ES products. Serum IgE is elevated in *Anisakis* infections, and both IgE and IgG antibodies can be useful in serodiagnosis of anisakiasis by the RAST, using L_3 *Anisakis simplex* somatic antigens. Bier and Raybourne (6) also demonstrated that the "cap" of protein seen at the anterior end of *Anisakis* larvae in tissue and in vitro in the presence of serum is composed of ES antigens and host antibody.

Two interesting products of the worm may serve to modulate the immune response. Tanaka and Torisu (67) reported on a factor released from *Anisakis* larvae that was chemotactic for eosinophils. More recently, Raybourne et al. (54) reported that ES products of *Anisakis* larvae inhibited concanavalin A-induced lymphocyte blastogenesis. Further fractionation of the complex mixture of proteins found in larval ES may yield important new insights into the host-parasite interaction in anisakiasis as well as potential serodiagnostic reagents.

EPIDEMIOLOGY

One purpose of this review is to alert clinicians, public health workers, microbiologists, epidemiologists, and parasitologists to the growing concern over the increase of this parasitic disease.

In Canada during the 1940s and 1950s, much attention was paid to *Pseudoterranova* sp., the "codworm," so named because of the presence of larvae in the flesh of cod (43-45).

TABLE 1. Anisakiasis: North America and Hawaii

Location	No. of cases (state)			Reference(s)
	<i>Anisakis</i> sp.	<i>Pseudoterranova</i> sp.	Anisakids ^a	
Tingling throat	2 (Wash.)	2 (Calif.)		Personal observation, 1988 Deardorff et al., 1987 (11) Desowitz, 1986 (18) Kliks, 1983 (32) ^b
	1 (Calif.)	3 (Calif.)	2	
Stomach	1 (Calif.)			Personal observation, 1988 Deardorff et al., 1986 (12) Kliks, 1986 (33) Hsiu et al., 1986 (26)
	1 (Hawaii) 1 (Hawaii)		1 (Va.)	
Intestine	1 (Calif.)			Sakanari et al., 1988 (59) Kwee & Sautter, 1987 (35) Kliks, 1986 (33) Appleby et al., 1982 (2); Valdiserri, 1981 (69) (same case) Pinkus et al., 1975 (53) Richman & Lewicki, 1973 (55)
	1 (Hawaii)	1 (Pa.)		
	1 (Pa.)			
	1 (Mass.) 1 (Mass.)			
Other				
Omentum			1 (Calif.)	Personal observation, 1987 Rushovich et al., 1983 (58) Kobayashi et al., 1985 (34)
Lung	1 (Ill.)			
Abdominal cavity	1 (Calif.)	1 (Mass.)		Little & MacPhail, 1972 (38)

^a Genus not specified.^b Report includes five incompletely documented cases of anisakiasis.

These worms are easily seen with the naked eye and are brown or reddish-brown in color (Fig. 4). Because they are not aesthetically pleasing to the public, there was great concern that the marketability of cod would be lowered (40, 46).

Case studies of individuals who became infected by *Anisakis* after eating "green herring" and descriptions of the pathogenicity of this "herring worm" were first reported in The Netherlands in the early 1960s (71). The disease was soon recognized as a public health problem in Japan (23, 48, 77).

In the early 1970s, the United States Food and Drug Administration decided to study the potential health risk of anisakids in seafoods (7, 14, 29, 30, 40, 46). Throughout the 1970s, documented cases of anisakiasis appeared in North America and Hawaii (38, 40, 53, 55). In the 1980s, the number of cases has increased (Table 1). The reasons for the increase may be severalfold: (i) increased public awareness of the disease; (ii) increased tendency to eat raw or lightly cooked seafood dishes by immigrants from fish-eating areas and native North Americans who delight in eating such fish dishes; and (iii) the increase in marine mammal populations along the east and west coasts of the United States that maintain the life cycles of anisakids (11, 14, 40a).

PUBLIC HEALTH IMPORTANCE

Anisakid nematodes have a worldwide distribution and have been reported from all major oceans and seas. Anisakiasis occurs in areas where the dietary habits include eating raw or improperly cooked infected seafoods and where the parasite is geographically distributed (for reviews on the life history, see references 48 and 62).

Anisakiasis has been reported from The Netherlands (70), Germany (39, 41), Switzerland (31), France (25, 42), United Kingdom (37, 74), Belgium (72), New Zealand (52), Chile (60, 68) and Japan (48). In Japan, where raw fish and squid are consumed as an integral part of the Japanese diet, the number of cases is over 1,000/year (50) (Table 2).

In North America and Hawaii, there have been over 50 confirmed cases of anisakiasis (not all reports have been published) (59). With the increased popularity of eating raw or lightly cooked seafood dishes, the number of cases may be expected to increase. Several fish species have been implicated in the transmission of anisakiasis, including Pacific salmon (*Oncorhynchus* spp.), rockfish (*Sebastes* spp.), herring (*Clupea* spp.), cod (*Gadus* spp.), halibut (*Hippoglossus stenolepis*), mackerel (*Scomber* spp.), and squid (*Todarodes* spp.) (17, 22, 49).

TABLE 2. Anisakiasis in Japan^a

% of cases (no. positive/total)			Reference
Gastric	Intestinal	Other	
65.2 (60/92)	30.4 (28/92)	4.3 (4/92) (mesentery, greater omentum, pancreas)	Yokogawa & Yoshimura, 1967 (77)
71 (196/278)	28 (77/278)	1 (3/278) (liver, mesentery, pancreas)	Hayasaka et al., 1971 (23)
91.7 (4,296/4,682) ^b	8 (375/4,682)	0.2 (11/4,682)	Ishikura et al., 1988 (28)

^a From three clinicopathologic studies in Japan. The increased usage of the endoscope may account for the increased number of gastric versus intestinal cases.^b 215 were *Pseudoterranova* infections.

Thorough cooking and adequate freezing of seafood are easy preventive measures against infection by anisakid nematodes. The Food and Drug Administration released a code interpretation stating that "fishery products which are not cooked throughout to 140°F (60°C) or above, must have been or must, before service or sale in ready-to-eat form, be blast frozen to -31°F (-35°C) or below for 15 hours or regularly frozen to -10°F (-23°C) or below for 168 hours (7 days)." For home preparation, fish fillets should be cooked so that the internal temperature reaches 60°C or higher for 10 min (5, 20). Thorough heating of the fish dish is essential, since anisakid nematodes are reported to have survived after fish was prepared in a microwave oven (36). Alternatively, seafoods should be frozen at -20°C (temperature of most home freezers) for 3 days; a whole fish weighing 4 to 8 pounds should be frozen at -20°C for at least 5 days (5). At room temperature, *Anisakis* larvae can survive for up to 6 days in 10% Formalin, 112 days in 1% HCl, 51 days in vinegar, 1 day in soy sauce, and 1 day in Worcestershire sauce (48).

ACKNOWLEDGMENTS

We thank Glenda Reifenrath, University of California, San Francisco, for assistance in taking the scanning electron micrograph; Majid Tavakolljou, University of California, San Francisco, for help with the literature search; Alice Russell, University of California, Santa Cruz, for the life cycle drawing; William Keene, University of California, Berkeley, for the worm drawing; and Ed M. Shimazu, University of California, San Francisco, for typing the manuscript. We are grateful to Thomas Deardorff and Richard Raybourne, U.S. Food and Drug Administration, for helpful suggestions.

LITERATURE CITED

- Akasaka, Y., M. Kizu, A. Aoike, and K. Kawai. 1979. Endoscopic management of acute gastric anisakiasis. *Endoscopy* 2:158-162.
- Appleby, D., W. Kapoor, M. Karpf, and S. Williams. 1982. Anisakiasis. Nematode infestation producing small-bowel obstruction. *Arch. Surg.* 117:836.
- Asaishi, K., C. Nishino, M. Totsuka, H. Hayasaka, and T. Suzuki. 1980. Studies on the etiologic mechanism of anisakiasis. *Gastroenterol. Jpn.* 15:128-134.
- Askenase, P. W. 1983. Effector and regulatory functions of cells in the immune response to parasites. *Fed. Proc.* 42:1740-1743.
- Bier, J. W., T. L. Deardorff, G. J. Jackson, and R. B. Raybourne. 1987. Human anisakiasis. *Bailliere's Clin. Trop. Med. Commun. Dis.* 2:723-733.
- Bier, J. W., and R. B. Raybourne. 1988. *Anisakis simplex* (Nematoda: Ascaridoides): formation of immunogenic attachment caps in pigs. *Proc. Helminthol. Soc. Wash.* 55:91-94.
- Chitwood, M. 1970. Nematodes of medical significance found in market fish. *Am. J. Trop. Med. Hyg.* 19:599-602.
- Chitwood, M., and J. R. Lichtenfels. 1972. Parasitological review. Identification of parasitic metazoa in tissue sections. *Exp. Parasitol.* 32:407-519.
- Cocheton, J. J., T. Gombeaud, and J. P. Ferroir. 1984. Anisakiasis duodénale aiguë extraction endoscopique. *Presse Med.* 13:744.
- Davey, J. T. 1971. A revision of the genus *Anisakis*. Dujardin, 1945 (Nematoda: Ascaridata). *J. Helminthol.* 45:51-72.
- Deardorff, T. L., J. Altman, and C. M. Nolan. 1987. Human anisakiasis: two case reports from the state of Washington. *Proc. Helminthol. Soc. Wash.* 54:274-275.
- Deardorff, T. L., T. Fukumura, and R. B. Raybourne. 1986. Invasive anisakiasis. A case report from Hawaii. *Gastroenterology* 90:1047-1050.
- Deardorff, T. L., M. M. Kliks, and R. S. Desowitz. 1983. Histopathology induced by larval *Terranova* (Type HA) (Nematoda: Anisakinae) in experimentally infected rats. *J. Parasitol.* 69:191-195.
- Deardorff, T. L., M. M. Kliks, M. E. Rosenfeld, R. A. Rychlinski, and R. S. Desowitz. 1982. Larval ascaridoid nematodes from fishes near the Hawaiian Islands, with comments on pathogenicity experiments. *Pac. Sci.* 36:187-201.
- Deardorff, T. L., and R. M. Overstreet. 1980. *Contraecium multipapillatum* (= *C. robustum*) from fishes and birds in the Northern Gulf of Mexico. *J. Parasitol.* 66:853-856.
- Deardorff, T. L., R. B. Raybourne, and R. S. Desowitz. 1984. Description of a third-stage larva, *Terranova* type Hawaii A (Nematoda: Anisakinae), from Hawaiian fishes. *J. Parasitol.* 70:829-831.
- Deardorff, T. L., and R. Throm. 1988. Commercial blast-freezing of third stage *Anisakis simplex* larvae encapsulated in salmon and rockfish. *J. Parasitol.* 74:600-603.
- Desowitz, R. S. 1986. Human and experimental anisakiasis in the United States. *Hokkaido Igaku Zasshi* 61:358-371.
- Desowitz, R. S., R. B. Raybourne, H. Ishikura, and M. Kliks. 1985. The radioallergosorbent test (RAST) for the serological diagnosis of human anisakiasis. *Trans. R. Soc. Trop. Med. Hyg.* 79:256-259.
- Fontaine, R. E. 1985. Anisakiasis from the American perspective. *J. Am. Med. Assoc.* 253:1024-1025.
- Frederickson, D. W., and R. D. Specian. 1981. The value of cuticular fine structure in identification of juvenile anisakine nematodes. *J. Parasitol.* 67:647-655.
- Hauck, A. K. 1977. Occurrence and survival of the larval nematode *Anisakis* spp. in the flesh of fresh, frozen, brined, and smoked Pacific herring, *Clupea harengus pallasi*. *J. Parasitol.* 63:515-519.
- Hayasaka, H., H. Ishikura, and T. Takayama. 1971. Acute regional ileitis due to *Anisakis* larvae. *Int. Surg.* 55:8-14.
- Higashi, M., K. Tanaka, T. Kitada, K. Nakatake, and M. Tsuji. 1988. Anisakiasis confirmed by radiography of the intestine. *Gastrointest. Radiol.* 13:85-86.
- Hoang, C., Y. Garin, J. Ichou, and Y. Le Charpentier. 1985. Jejunal anisakiasis and intestinal occlusion. *Gastroenterol. Clin. Biol.* 9:847-848.
- Hsui, J. G., A. J. Gamsey, C. E. Ives, N. A. D'Amato, and A. N. Hiller. 1986. Gastric anisakiasis: report of a case with clinical, endoscopic, and histologic findings. *Am. J. Gastroenterol.* 81:1185-1187.
- Ishikura, H., H. Hayasaka, and Y. Kikuchi. 1967. Acute regional ileitis at Iwanai in Hokkaido. *Sapporo Med. J.* 32:183-196.
- Ishikura, H., Y. Kobayashi, K. Miyamoto, K. Yagi, O. Nakajima, O. Fujita, Y. Oikawa, J. Maejima, T. Aji, Y. Akao, and H. Hayasaka. 1988. Transition of occurrence of anisakiasis and its paratenic host fishes in Japan, with pathogenesis of anisakiasis. *Med. J. Hokkaido* 63:376-391. (In Japanese.)
- Jackson, G. J. 1975. The "new disease" status of human anisakiasis and North American cases: a review. *J. Milk Food Technol.* 38:769-773.
- Jackson, G. J., J. W. Bier, W. L. Payne, T. A. Gerding, and W. G. Knollenberg. 1978. Nematodes in fresh market fish of the Washington, D.C., area. *J. Food Prot.* 41:613-620.
- Jlidi, R., and F. Chatelanat. 1987. Anisakiasis of the small intestine and review of the literature. *Rev. Med. Suisse Romande* 107:973-976.
- Kliks, M. 1983. Anisakiasis in the western United States: four new case reports from California. *Am. J. Trop. Med. Hyg.* 32:526-532.
- Kliks, M. 1986. Human anisakiasis: an update. *J. Am. Med. Assoc.* 255:2605.
- Kobayashi, A., M. Tsuji, and D. L. Wilbur. 1985. Probable pulmonary anisakiasis accompanying pleural effusion. *Am. J. Trop. Med. Hyg.* 34:310-313.
- Kwee, H. G., and R. L. Sautter. 1987. Anisakiasis. *Am. Fam. Physician* 36:137-140.
- Lane, C. D., R. N. Master, and R. H. Tietbohl. 1988. If you uneaten food moves, take it to a doctor. *J. Am. Med. Assoc.* 260:340-341.
- Lewis, R., and J. H. Shore. 1985. Anisakiasis in the United Kingdom. *Lancet* ii:1019.

38. Little, M. D., and J. C. MacPhail. 1972. Large nematode larva from the abdominal cavity of a man in Massachusetts. *Am. J. Trop. Med. Hyg.* **21**:948-950.
39. Lorenz, G. 1982. Morphological changes of anisakiasis. *Zentralbl. Allg. Pathol. Pathol. Anat.* **126**:477-482. (In German.)
40. Margolis, L. 1977. Public health aspects of "codworm" infection: a review. *J. Fish. Res. Board Can.* **34**:887-898.
- 40a. McKerrow, J. H., J. A. Sakanari, and T. L. Deardorff. 1988. Revenge of the "sushi parasite." *New Engl. J. Med.* **319**:1228-1229.
41. Möller, H., and S. Schröder. 1987. New aspects of anisakiasis in Germany. *Arch. Lebensmittelhyg.* **38**:123-127. (In German.)
42. Mudry, J., P. Lefebvre, E. Dei-Cas, A. Vernes, J. Poirriez, M. Débat, R. Marti, P. Binot, and A. Cortot. 1986. Anisakiasis humaine: 5 cas dans le nord de la France. *Gastroenterol. Clin. Biol.* **10**:83-87. (In French.)
43. Myers, B. J. 1970. Nematodes transmitted to man by fish and aquatic mammals. *J. Wildl. Dis.* **6**:266-271.
44. Myers, B. J. 1975. The nematodes that cause anisakiasis. *J. Milk Food Technol.* **38**:774-782.
45. Myers, B. J. 1976. Research then and now on the anisakidae nematodes. *Trans. Am. Microsc. Soc.* **95**:137-142.
46. Myers, B. J. 1979. Anisakine nematodes in fresh commercial fish from waters along the Washington, Oregon and California coasts. *J. Food Prot.* **42**:380-384.
47. Olson, A. C., M. D. Lewis, and M. L. Hauser. 1983. Proper identification of anisakine worms. *Am. J. Med. Technol.* **49**:111-114.
48. Oshima, T. 1972. *Anisakis* and anisakiasis in Japan and adjacent areas. *Prog. Med. Parasitol. Jpn.* **4**:305-393.
49. Oshima, T. 1987. Anisakiasis—is the sushi bar guilty? *Parasitol. Today* **3**:44-48.
50. Oshima, T., and M. Kliks. 1987. Effects of marine mammal parasites on human health. *Int. J. Parasitol.* **17**:415-421.
51. Overstreet, R. M., and G. W. Meyer. 1981. Hemorrhagic lesions in stomach of rhesus monkey caused by a piscine ascaridoid nematode. *J. Parasitol.* **67**:226-235.
52. Paltridge, G. P., J. L. Faoagali, and H. B. Angus. 1984. Intestinal anisakiasis: a new New Zealand disease. *N. Z. Med. J.* **97**:558-559.
53. Pinkus, G. S., C. Coolidge, and M. D. Little. 1975. Intestinal anisakiasis. First case report from North America. *Am. J. Med.* **59**:114-120.
54. Raybourne, R., T. L. Deardorff, and J. W. Bier. 1986. *Anisakis simplex*: larval excretory secretory protein production and cytostatic action in mammalian cell cultures. *Exp. Parasitol.* **62**:92-97.
55. Richman, R. H., and A. M. Lewicki. 1973. Right ileocolitis secondary to anisakiasis. *Am. J. Roentgenol. Radium Ther. Nucl. Med.* **119**:329-331.
56. Rohde, K. 1984. Diseases caused by metazoans: helminths, p. 193-320. *In* O. Kinne (ed.), *Diseases of marine animals*, vol. 4, part 1. Biologische Anstalt Helgoland, Hamburg, Federal Republic of Germany.
57. Rosset, J. S., K. D. McClatchey, G. I. Higashi, and A. S. Knisely. 1982. *Anisakis* larva type I in fresh salmon. *Am. J. Clin. Pathol.* **78**:54-57.
58. Rushovich, A. M., E. L. Randall, J. A. Caprini, and G. O. Westenfelder. 1983. Omental anisakiasis: a rare mimic of acute appendicitis. *Am. J. Clin. Pathol.* **80**:517-520.
59. Sakanari, J. A., H. M. Loinaz, T. L. Deardorff, R. B. Raybourne, J. H. McKerrow, and J. G. Frierson. 1988. Intestinal anisakiasis. A case diagnosed by morphologic and immunologic methods. *Am. J. Clin. Pathol.* **90**:107-113.
60. Sapunar, J., E. Doerr, and T. Letonja. 1976. Human anisakiasis in Chile. *Bol. Chil. Parasitol.* **31**:79-83.
61. Smith, J. W. 1983. *Anisakis simplex* (Rudolphi, 1809, det. Krabbe, 1878) (Nematoda: Ascaridoidea): morphology and morphometry of larvae from euphausiids and fish, and a review of the life-history and ecology. *J. Helminthol.* **57**:205-224.
62. Smith, J. W., and R. Wooten. 1978. *Anisakis* and anisakiasis. *Adv. Parasitol.* **16**:93-163.
63. Sugimachi, K., K. Inokuchi, T. Ooiwa, T. Fujino, and Y. Ishii. 1985. Acute gastric anisakiasis. *J. Am. Med. Assoc.* **253**:1012-1013.
64. Suzuki, T., Y. Sato, T. Yamashita, H. Sekikawa, and M. Otsuru. 1974. Anisakiasis: preparation of a stable antigen for indirect fluorescent antibody test. *Exp. Parasitol.* **35**:418-424.
65. Takahashi, S., and N. Sato. 1987. Analysis of *Anisakis* larvae specific antigens using monoclonal antibodies and their applications. *Sapporo Med. J.* **56**:291-303.
66. Takahashi, S., N. Sato, and H. Ishikura. 1986. Establishment of monoclonal antibodies that discriminate the antigen distribution specifically found in *Anisakis* larvae (Type I). *J. Parasitol.* **72**:960-962.
67. Tanaka, J., and M. Torisu. 1978. *Anisakis* and eosinophil. I. Detection of a soluble factor selectively chemotactic for eosinophils in the extract from *Anisakis* larvae. *J. Immunol.* **120**:745-749.
68. Torres, P., E. Hernandez, and I. Sandoval. 1983. Anisakiasis and phocanemiasis in marine fishes from the south of Chile. *Int. J. Zoonoses* **10**:146-150.
69. Valdiserri, R. O. 1981. Intestinal anisakiasis. Report of a case and recovery of larvae from market fish. *Am. J. Clin. Pathol.* **76**:329-333.
70. Van Thiel, P. H. 1976. The present state of anisakiasis and its causative worms. *Trop. Geogr. Med.* **2**:75-85.
71. Van Thiel, P. H., and H. Van Houten. 1967. The localization of the herringworm *Anisakis marina* in- and outside the human gastrointestinal wall. *Trop. Geogr. Med.* **19**:56-62.
72. Verhamme, M. A. M., and C. H. R. Ramboer. 1988. Anisakiasis caused by herring in vinegar: a little known medical problem. *Gut* **29**:843-847.
73. Wakelin, D. 1978. Immunity to intestinal parasites. *Nature (London)* **273**:617-620.
74. Watt, I. A., N. R. McLean, R. W. A. Girdwood, L. H. Kissen, and A. H. B. Fyfe. 1979. Eosinophilic gastroenteritis associated with a larval anisakine nematode. *Lancet* **ii**:893-894.
75. Williams, H. H., and A. Jones. 1976. Marine helminths and human health. Commonwealth Agricultural Bureaux, Farnham Royal, Bucks, England.
76. Yokogawa, M., and H. Yoshimura. 1965. *Anisakis*-like larvae causing eosinophilic granulomata in the stomach of man. *Am. J. Trop. Med. Hyg.* **14**:770-773.
77. Yokogawa, M., and H. Yoshimura. 1967. Clinicopathologic studies on larval anisakiasis in Japan. *Am. J. Trop. Med. Hyg.* **16**:723-728.