

Human Infections Due to *Malassezia* spp.

MARIO J. MARCON^{1,2,3*} AND DWIGHT A. POWELL²

Departments of Pathology¹ and Pediatrics,² The Ohio State University, Columbus, Ohio 43210, and Section of Clinical Microbiology, Department of Laboratory Medicine, Children's Hospital, Columbus, Ohio 43205^{3*}

INTRODUCTION	101
TAXONOMY	101
HISTORICAL PERSPECTIVE	102
IN VITRO CHARACTERISTICS	102
Culture Requirements	102
Macroscopic and Microscopic Morphology	103
Reproductive, Physiologic, and Antigenic Characteristics.....	103
EPIDEMIOLOGY OF <i>M. FURFUR</i>	105
Skin Colonization in Healthy Children and Adults	105
Skin Colonization in Infants	105
PATHOGENESIS OF <i>MALASSEZIA</i> INFECTIONS.....	105
Pityriasis Versicolor	105
Catheter-Associated Sepsis	106
<i>MALASSEZIA</i> INFECTIONS.....	106
<i>M. furfur</i> Skin Infections	106
Clinical features.....	106
Treatment	110
Antibody and cell-mediated immune response	110
<i>M. furfur</i> Catheter-Associated Infections	110
Clinical features.....	111
Treatment	112
<i>M. pachydermatis</i> Human Infections	113
LABORATORY DIAGNOSIS OF <i>MALASSEZIA</i> INFECTIONS	115
Pityriasis Versicolor.....	115
Catheter-Associated Sepsis	115
Direct examination of catheter or peripheral blood.....	115
Blood cultures	115
Catheter cultures	116
CONCLUSION.....	116
ACKNOWLEDGMENTS.....	116
REFERENCES	116

INTRODUCTION

Yeasts of the genus *Malassezia* (synonym: *Pityrosporum*) are obligatory or nonobligatory lipophilic, normal flora organisms of the skin of warm-blooded hosts; under appropriate conditions, they cause superficial infections of the skin and associated structures (1, 23, 39, 49, 68, 95, 132, 151). The most commonly described human infection due to a member of the genus is pityriasis versicolor, a chronic, superficial disease of the stratum corneum layer of the epidermis containing the typical hyphal elements and yeast cells of *Malassezia furfur* in tissue (39, 49, 91, 115, 132, 151). Recently, data from several institutions have implicated both *M. furfur* and *M. pachydermatis* as causing a number of more invasive human infections, including intravascular catheter-associated sepsis (5-8, 17, 27, 55, 63, 82, 87, 93, 106, 108, 110, 113, 114, 128, 138). With the increasing number of patients presenting with immunologic dysfunction associated with susceptibility to invasive disease caused by organisms of low virulence, it is likely that the incidence of *Malassezia* infections will increase. This review will focus

on the microbiologic, epidemiologic, clinical, and diagnostic aspects of *Malassezia* infections.

TAXONOMY

Malassezia organisms are globose to ellipsoidal, unipolar budding, lipophilic yeasts that appear to be basidiomycetes (96). The data supporting this relationship include their positive diazonium blue B staining reaction, positive urea hydrolysis reaction, laminar cell wall ultrastructure as revealed by electron microscopy, and resistance to cell wall lysis by β -(1,3)-D-glucanase (60, 130, 151). The genus contains at least three species: *M. furfur*, an obligatory lipophilic organism commonly found on human skin; *M. sympodialis*, a second obligatory lipophilic species for which two human isolates have been described; and *M. pachydermatis*, a nonobligatory lipophilic species most often isolated from dogs (1, 91, 126, 131, 151).

Some controversy still surrounds the appropriate scientific name for this genus and the number of species within the genus. Most investigators believe that such taxonomic terms as *Pityrosporum ovale* and *P. orbiculare* represent morphologic variants of *M. furfur* (151). Genetic, morphologic, and immunologic studies support this conclusion (see below).

* Corresponding author.

TABLE 1. Physiologic, antigenic, and genetic characteristics of *Malassezia* spp.

<i>Malassezia</i> sp.	Common habitat	Obligatory lipophilic	Lipid requirement supplied by oleic acid or Tween 80	Multilaminar cell wall	Diazonium blue B staining	Urea hydrolysis	Unipolar budding	Sympodial budding	G+C content (%)	No. of serovars
<i>M. furfur</i>	Human skin	+	+	+	+	+	+	0	66	3 ^a
<i>M. sympodialis</i>	Human skin	+	0	+	+	+	+	+	54	ND ^b
<i>M. pachydermatis</i>	Canine skin	0	NA ^c	+	+	+	+	0	55	ND

^a All antigenically distinct from *M. pachydermatis*.

^b ND, not determined.

^c NA, not applicable.

Thus, we will use the names *M. furfur* (Robin) Ballion and *M. sympodialis* Simmons et Guého throughout this review (except in the section on historical perspective) to define the obligatory lipophilic species. To maintain consistency, *M. pachydermatis* (Weidman) Dodge will be used to define a third species which does not require, but whose growth is stimulated by, exogenous lipids.

HISTORICAL PERSPECTIVE

The earliest reports of *Malassezia*-like yeasts were those of Eichstedt in 1846 (32) and Robin in 1853 (118), who described the organism in the skin scales of patients with pityriasis versicolor. In 1973, Rivolta reported yeasts of a similar type isolated from patients with psoriasis (116), and in 1874, Malassez described the typical round and oval budding yeast cells in the stratum corneum of patients with pityriasis versicolor and a variety of other skin conditions (84). Malassez is credited with distinguishing the agent of this disease from the agents of true ringworm (tinea) infections. In recognition of the work of Malassez, Baillon proposed the name *M. furfur* in 1889 to describe the furfuraceous (consisting of or covered with flaky particles) nature of the skin lesions observed in patients with pityriasis versicolor (10). The genus *Pityrosporum* was proposed 15 years later by Sabouraud to describe budding yeast cells without hyphal elements observed in and isolated from normal skin and scalp (124). The species name *P. ovale* was first used by Castellani and Chalmers, who were able to consistently culture this oblong to ellipsoidal yeast from human skin scales (21). In 1951, Gordon isolated a spherical to oval yeast from pityriasis versicolor lesions and normal skin; he named the organism *P. orbiculare* (57, 58). Weidman cultured a *Malassezia*-like, nonobligatory lipophilic yeast from animals in 1925, and he named the organism *P. pachydermatis* (145).

A number of investigators have conducted morphologic, immunologic, and genetic studies of these yeasts to define their taxonomic relationships. Burke observed typical structures of *M. furfur* in a patient experimentally infected with *P. orbiculare*; she also was able to produce hyphal elements in cultures of this organism (20). Keddie and Shadomy isolated *P. orbiculare* from scales of patients with pityriasis versicolor in which the presence of *M. furfur* had been demonstrated by staining and direct microscopic examination (72). Dorn and Roehnert reported that globose cells of *P. orbiculare* readily converted to hyphal elements in a defined medium (29). Salkin and Gordon reported changes in the morphologic characteristics of *P. orbiculare* during maintenance in culture (125). They suggested that the alteration from globose (*P. orbiculare*) to oval and cylindrical (*P. ovale*) forms represented different stages in the developmental cycle of the organism. Ranjandiche also showed that the

two morphologies were not stable and could coexist in the same lesion or culture (111).

The most convincing data supporting the classification of *Malassezia* spp. relate to the genetic analysis of these organisms. Guého and Meyer studied the molar percentage of G+C content and DNA-DNA reassociation kinetics of *Malassezia*-like yeast cells isolated from human scalp and forehead (*P. ovale*-like), human chest and back (*P. orbiculare*-like), human sources other than skin (both obligatory and nonobligatory lipophilic), and canine ears (*M. pachydermatis*-like) (60). The human obligatory lipophilic isolates could be assigned to a group with a G+C content of about 66%; human and canine nonobligatory lipophilic isolates had G+C contents of around 55.5%. Furthermore, all combinations of human obligatory lipophilic isolates gave DNA-DNA reassociation percentages of >85%, a degree of homology high enough to indicate a single species. Similarly, the DNAs of both human and canine nonobligatory lipophilic isolates showed high reassociation percentages, suggesting a single species. However, reassociation between the DNAs of obligatory and nonobligatory isolates was low, suggesting different species (60).

Recently, Simmons and Guého isolated a *Malassezia*-like organism from the ear canal of a healthy male and from the scalp of an AIDS patient with tinea capitis (131). The yeast was obligatory lipophilic with unipolar, percurrent, and sympodial budding and with a G+C content of 54%. The organism's diazonium blue B staining reaction, urea hydrolysis reaction, and cell wall ultrastructure were consistent with classification as a *Malassezia* sp. However, the organism's sympodial budding, percent G+C, and low DNA-DNA reassociation values with the other *Malassezia* spp. suggested classification as a new species; it was named *M. sympodialis* Simmons et Guého. These data, as well as immunologic studies (see below), suggest that three taxa of *Malassezia* are justified: *M. furfur* and *M. sympodialis* for the obligatory lipophilic species, and *M. pachydermatis* for the nonobligatory lipophilic species. The characteristic features of these organisms are summarized in Table 1 and discussed below.

IN VITRO CHARACTERISTICS

Culture Requirements

Growth of *M. furfur* and *M. sympodialis* is absolutely dependent on the presence of medium- or long-chain fatty acids in the culture medium (129, 131, 132, 146, 151). Visible colonies develop over 2 to 4 days at temperatures between 34 and 37°C. Fatty acids also stimulate the growth of *M. pachydermatis*. These compounds are commonly found in natural oils, including olive, corn, soybean, and safflower oils. Most saturated and unsaturated fatty acids in the C₁₂ to

C₂₄ series will satisfy the requirement for exogenous lipids. Nazzaro-Porro et al. (100) reported that oleic, arachidic, stearic, and palmitic acids as well as several Tween compounds were the best sources of lipid for growth of *M. furfur*; however, *M. sympodialis* does not grow on an enriched medium when oleic acid or Tween 80 is used as the sole fatty acid supplement (131). For *M. pachydermatis*, growth occurs on solid medium after 2 to 3 days at 35 to 37°C on a variety of common culture media, including chocolate agar, tryptic soybean digest agar or brain heart infusion agar with 5% sheep blood, Sabouraud dextrose agar, and malt extract agar; growth is poor at 25°C (126, 132, 151). The optimum pH for growth is between 5.5 and 6.5. *M. furfur* and *M. sympodialis* do not grow or produce only very tiny colonies on such media unless the medium is supplemented with a long-chain fatty acid source; olive oil is commonly used for this purpose and can be added directly to the agar surface. Alternatively, the fatty acid source can be added to the molten agar during preparation. Faergemann (36) developed such a medium, composed of glucose-yeast extract-peptone agar supplemented with olive oil, Tween 80, and glycerol monostearate (GYP-S agar). This medium, unlike media on which olive oil has been dropped, has the advantage of permitting determination of quantitative colony counts; it is commercially available as MAL agar (Becton Dickinson Microbiology Systems, Cockeysville, Md.). The organism can be maintained in the laboratory on this medium by performing monthly subculture. *M. pachydermatis* is recovered more quickly and develops larger colonies on GYP-S agar than on agars without lipid supplements. *M. furfur* and *M. pachydermatis* grow equally well in aerobic, microaerophilic, and capneic conditions; by contrast, anaerobic growth is poor (46).

Recently, Leeming and Notman described an improved medium for the primary isolation and quantitation of *M. furfur* from human skin (79). It is similar in composition to GYP-S agar but has the following additional components: glycerol, ox bile, and whole-fat cow's milk in place of olive oil. These authors showed a significant increase in colony counts on their medium compared with GYP-S agar when skin samples collected from various body sites were cultured. In addition, Bezjak et al. (14) described PSM, a solid medium supplemented with 5% horse serum, Eagle's minimal essential medium, and amino acids, and M-7, a liquid medium, similarly supplemented, both of which yielded excellent growth of *M. furfur*. The last two media may prove to be advantageous in obtaining populations of *M. furfur* devoid of oily carryover, a potential problem for biochemical and genetic studies.

Macroscopic and Microscopic Morphology

The colonial morphology of *Malassezia* spp. on GYP-S agar is variable. Typically, colonies are smooth, sometimes glistening, and cream to yellowish brown with an intact margin. Alternatively, colonies may be dull and lightly wrinkled with a lobate margin. The latter morphology is common with older cultures (Fig. 1).

Microscopically, *M. pachydermatis* cells are subglobose to ellipsoidal and 2.5 to 5.5 by 3.0 to 6.5 µm in size (132, 151). The cells of *M. sympodialis* are usually globose and 2.5 to 7.5 by 2.0 to 8.0 µm in size (131). Two microscopic forms of *M. furfur* can be recognized in culture. The *P. ovale* form is ovoidal, ellipsoidal, or cylindrical and 1.5 to 4.5 by 2.0 to 6.5 µm in size. The *P. orbiculare* form, usually less abundant in culture, is primarily globose and 2.5 to 4.5 µm in diameter.

Both forms are usually found in the same culture. Well-developed hyphae, such as occur in the lesions of pityriasis versicolor, are rarely seen in normal culture but may be induced in vitro by special culture conditions (see below). *M. pachydermatis* does not produce hyphae in vitro or in vivo.

When studied by electron microscopy, the cell walls of all *Malassezia* spp. are relatively thick and multilaminar, with characteristic invaginations of the innermost layer (2, 130, 131). There is some controversy as to the number of layers and relative thickness of the cell wall of the various *Malassezia* spp. However, Simmons and Ahearn (130) suggested that the cell wall characteristics and unipolar budding of the organisms indicate a close association between *Malassezia* spp. and the basidiomycetes.

Reproductive, Physiologic, and Antigenic Characteristics

Reproduction of the *Malassezia* spp. occurs by budding on a broad base and from the same site (monopolar or unipolar) (141). The extruded bud is divided from the mother cell by a septum, and the daughter cell is separated by fission. Separation of the daughter cell leaves a scar; successive scars form a small collar (collarlette) from which later buds emerge (91). *M. sympodialis* also displays a sympodial type of budding process (131).

Malassezia spp. do not grow in the liquid medium used in standard assimilation tests (132, 151). Sanguinetti et al. (126) tested 120 *M. pachydermatis* isolates from dogs for assimilation of carbon sources by a modification of the classical auxanographic method. They found that glucose and mannitol were assimilated by all isolates (though mannitol assimilation was delayed); lactose, lactic acid, and succinic acid were not assimilated. Using similar methods, Slooff found that *M. pachydermatis* assimilated glucose, mannitol, and glucitol (132). Fermentation tests were all negative. All three species are positive for urease production (Christensen's urea) within 24 h at 35°C. *Malassezia* spp. are also relatively inactive in common commercial yeast identification systems such as API-20C (Analytab Products, Plainview, N.Y.) and Flow Uni-Yeast-Tek (Remel, Lenexa, Kans.) (85). *M. furfur* and *M. pachydermatis* hydrolyze urea only in the Flow Uni-Yeast-Tek system. In addition, *M. pachydermatis* may be positive for glucose, glycerol, and sorbitol in the API-20C system and thus be misidentified as *Candida lipolytica* unless microscopic observations are done (85).

A number of studies have described the specific fatty acid requirements and lipid metabolism of *M. furfur* (100, 129, 146). These studies demonstrated that in vitro growth occurs only in the presence of long-chain fatty acids from the C₁₂ to C₂₄ series. Although lipids can be the only carbon source, growth is enhanced in the presence of a carbon energy source such as glucose (100). Thus, it appears that *M. furfur* cannot perform de novo synthesis of lipids necessary for membrane synthesis unless an exogenous source of fatty acids is supplied; however, high concentrations of fatty acids may be growth inhibitory (100). Furthermore, *M. furfur* appears to have the ability to synthesize a variety of lipids containing both saturated and unsaturated fatty acids from a single fatty acid source.

Nazzaro-Porro et al. (99) studied the effect of complex lipids such as cholesterol and cholesterol esters on the in vitro growth and induction of hyphae by *M. furfur*. They successfully induced hyphae on yeast morphology agar containing cholesterol, cholesteryl stearate, and glyceryl monostearate. They indicated that the mycelial type of

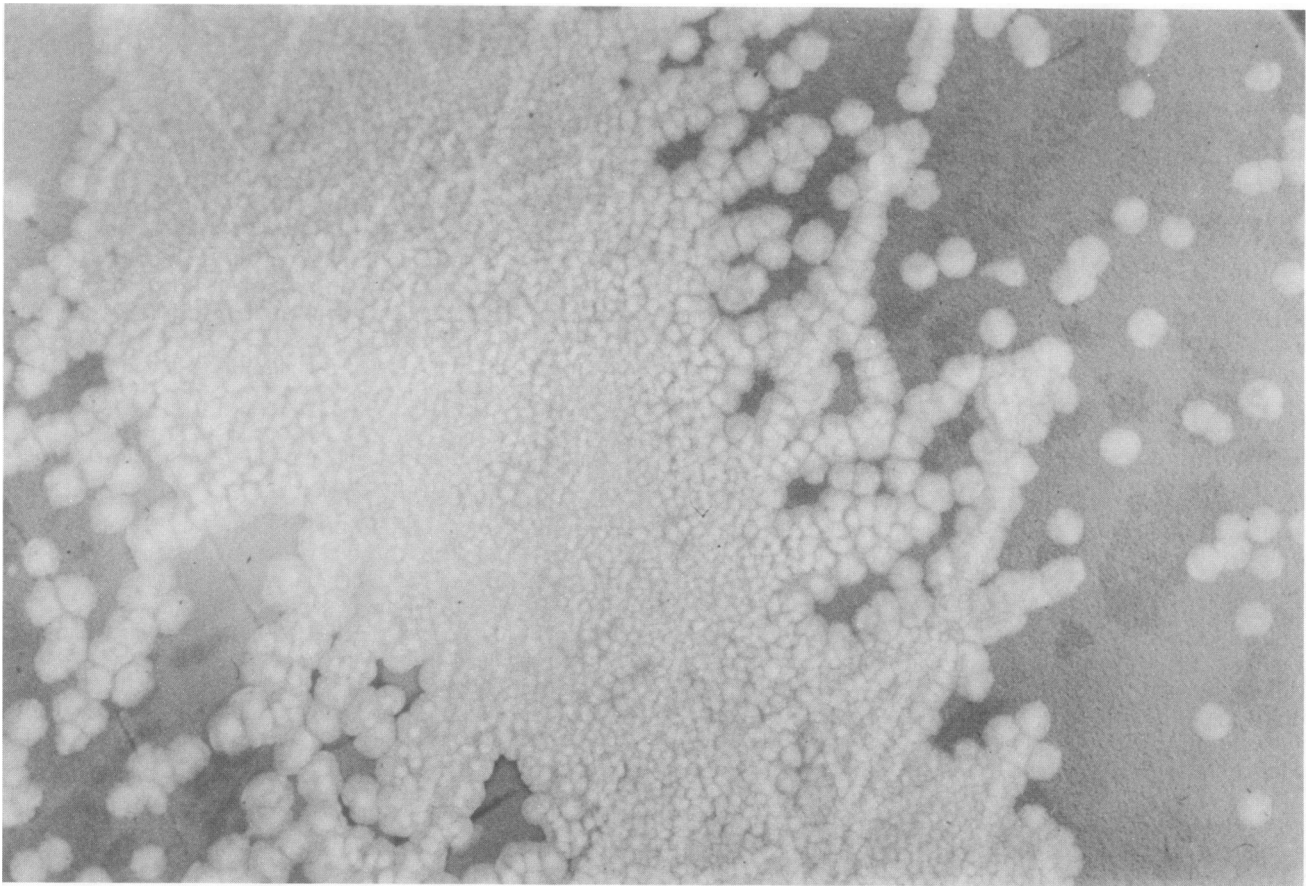


FIG. 1. Photograph of colonies of *M. furfur* on GYP-S agar incubated at 35°C for 7 days. Note the dull, lightly wrinkled nature of the colonies.

growth in culture closely resembled that of *M. furfur* in tissue; the mycelial form of the organism is thought to represent the invasive pathogenic form.

Although many investigators have studied the morphology and lipid metabolism of *Malassezia* spp., little work has been done toward understanding the protein and carbohydrate components of the organism, either to establish a serologic typing scheme or to determine which antigens are involved in the immune response in animal models and human infections.

Tanaka and Imamura used both Ouchterlony gel diffusion and direct immunofluorescence (IF) tests with antisera prepared in rabbits to show that human *Malassezia* isolates (obligatory lipophilic) grown in vitro have significant antigenic similarities to yeasts seen in biopsy material from pityriasis versicolor lesions; however, little antigenic similarity was seen between human and canine isolates (nonobligatory lipophilic), suggesting that the latter organisms represent a different species (142). Faergemann et al. (50) used indirect IF techniques with purified immunoglobulin G (IgG) fractions of rabbit antisera to confirm the findings of Tanaka and Imamura. None of these investigators were able to demonstrate unique antigenic differences characterizing subsets of *M. furfur* isolates.

Bruneau and Guinet used a variety of quantitative immunoelectrophoretic techniques to study protein antigens of *Malassezia* spp. (18). Immune serum, prepared from rabbits, produced 35 to 63 precipitin peaks in crossed immunoelec-

trophoresis with soluble extracts of a variety of *Malassezia* isolates. These studies again confirmed the close antigenic relationship among obligatory lipophilic isolates and that *M. pachydermatis* was distinct antigenically.

Recently, Cunningham et al. (25) studied a limited number of *M. furfur* isolates from clinically healthy adult skin to determine whether antigenic differences occurred and could be correlated with skin site or cultural morphology. Using indirect IF and differential absorption with rabbit antisera, they grouped the isolates into three serovars corresponding to groups based on cultural characteristics (growth rate and microscopic and colonial morphology). These results support the earlier work of Takahashi et al. (140) and Midgley (94, 95) that suggested antigenic differences within the species. By using double diffusion, Takahashi and coworkers showed three group-specific soluble antigens among obligatory lipophilic isolates; these group antigens were associated with organisms displaying different blastospore shapes (140). Midgley also suggested that the stable morphologic variants of *M. furfur* expressed different soluble antigens as determined by immunoelectrophoresis (94, 95).

Clearly, we are far from understanding the antigenic makeup of *Malassezia* spp. and establishing a serologic typing scheme useful in better understanding the epidemiology of the organisms. The various morphologic phases of *M. furfur* (in vivo and in vitro) may express different protein antigens, but this hypothesis needs to be confirmed. Techniques such as polyacrylamide gel electrophoresis (PAGE)

of total cellular proteins, PAGE followed by immunoblotting, and PAGE followed by isoenzyme analysis may be helpful in establishing unique protein profiles of the organism.

EPIDEMIOLOGY OF *M. FURFUR*

Skin Colonization in Healthy Children and Adults

A number of investigators have conducted studies of *M. furfur* colonization of healthy skin and scalp. Roberts cultured healthy skin and scalp of 100 Caucasians (primarily adults) and isolated *M. furfur* from the scalp, chest, and back of 74, 92, and 100%, respectively, of these individuals (117). The organism was less frequently cultured from a variety of other sites, including the face and limbs. Faergemann et al. (36, 42) confirmed these observations by quantitating the number of colonies of *M. furfur* obtained from skin scrapings in 10 adult volunteers. Counts from the back and chest were >10-fold higher than those from the upper arm, leg, and back of the hand, suggesting preferential growth of *M. furfur* in sebum-containing skin sites. Using an improved technique for quantitative isolation of *M. furfur*, Leeming et al. (79, 80) demonstrated that 100% of 16 healthy adults were colonized with *M. furfur*. Again, the organisms were most abundant in areas containing pilosebaceous glands, a finding that supported Leeming's previous observation that *M. furfur* colonizes the lumen of the pilosebaceous unit (78).

The frequency of *M. furfur* skin colonization has been correlated with both race and age differences. Noble and Midgley (101) studied skin colonization of *M. furfur* in Caucasian and black children between 7 and 16 years old; they found higher colonization rates in Caucasians (79 versus 65%) and in children >12 years old. Faergemann and Fredriksson (47), studying 175 children from newborns through 15 years of age, found that the prevalence of *M. furfur* skin colonization directly correlated with age. The highest prevalence (93%) was in the 15-year-old group, and the lowest (10%) was in children 5 years old. No organisms were isolated from 85 children \leq 1 year old, including 25 newborns. These data suggest that colonization with *M. furfur* most commonly occurs during adolescence, when the sebaceous glands become active and the concentration of skin lipids increases (3).

Skin Colonization in Infants

After *M. furfur* catheter-associated sepsis in newborn infants was described, investigators examined the incidence of *M. furfur* skin colonization of hospitalized infants (7, 12, 106, 107, 114). Powell et al. (106) recovered *M. furfur* from skin scrapings of the back, chest, or arms in 8 of 25 (32%) premature infants in a neonatal intensive care unit (NICU). A positive culture correlated with lower gestational age and longer duration of stay in the unit, but not with parenteral administration of lipid emulsions. Aschner et al. (7) reported that 28% of infants in an NICU were colonized in the first week of life, while 84% of older infants were skin culture positive for *M. furfur*. Bell et al. (12) reported isolation of *M. furfur* from only 1.4% of premature newborns during their first week in an NICU, whereas by the second week, the colonization rate reached nearly 50%. Thus, it appears that *M. furfur* skin colonization of neonates is acquired as the infant spends time in the NICU environment.

It is unlikely that *M. furfur* is transmitted from mother to infant during birth, because three studies have documented

the total absence of skin colonization in healthy, full-term newborns (12, 47, 106). Additionally, <5% of healthy infants examined in well-baby clinics in Rochester and Philadelphia during the first 3 months of life showed *M. furfur* skin colonization (7, 12). In Thailand, on the other hand, 47% of 125 healthy, 1- to 5-day-old newborns were colonized with *M. furfur*, suggesting some difference between genetic or environmental factors which influence colonization (69). However, most data point to the NICU environment as one of the major factors contributing to *M. furfur* skin colonization of newborns and infants.

Further assessment of risk factors for *M. furfur* skin colonization in the NICU has been addressed recently. Powell et al. (107) performed monthly chest or back skin cultures for *M. furfur* and recorded daily care activities on all infants in the NICU and surgical intensive care unit for 1 year. Of 361 infants from whom specimens were taken, *M. furfur* was recovered from 133 (36.8%) during 1 or more months. Although positive skin cultures occurred throughout the year, the lowest colonization rates occurred in the winter months of November, December, and January. Infants who were hospitalized for >1 month and thus provided specimens at least twice were colonized more frequently than infants hospitalized for \leq 1 month, suggesting that length of hospitalization is a major risk factor for colonization. No correlation was found with race, sex, type of birth delivery, the use of parenteral lipids, or length of antimicrobial therapy, but prematurity, length of hospitalization, time spent in an isolette or lying on lamb's wool, and total number of days that occlusive dressings were used correlated directly with higher colonization rates. These observations suggest that heat and humidity may play a role in augmenting *M. furfur* skin colonization of the newborn.

The data that may help us identify the nursery sources of *M. furfur* transmission to the hospitalized neonate are limited. During the only recorded outbreak of *M. furfur* sepsis in an NICU (three cases within 4 days), investigators from the Centers for Disease Control found only a 20% prevalence of skin colonization in infants (114). In contrast to the usual high prevalence of adult skin colonization, only 2 of 11 nursing personnel were colonized. No association was made between infected infants and colonized nurses. Environmental sources were not examined to corroborate the previous observation that *M. furfur* may be recovered from swabs of isolettes (107). In a very small case control analysis of infants matched by birth weight in the involved NICU, the only identified risk factor for *M. furfur* sepsis was the prolonged duration of antimicrobial therapy in infected infants (39 ± 13 versus 17.5 ± 9 days [114]). A complete understanding of factors influencing skin colonization, transmission, and risk of infection with *M. furfur* awaits further investigations of risk factors and the development of a useful typing scheme for tracing individual isolates.

PATHOGENESIS OF *MALASSEZIA* INFECTIONS

Pityriasis Versicolor

A number of factors probably stimulate the colonizing, budding yeast form of *M. furfur* to convert to the mycelial form and cause pityriasis versicolor (39). The most important of these factors relates to local conditions on the skin; both high temperature and high relative humidity promote development of disease, which probably explains why pityriasis versicolor is observed more commonly in tropical climates. Skin conditions such as seborrhea and hyperhidrosis

or the liberal use of oils on the skin may also contribute to development of the disease. Genetic factors and subtle differences in cell-mediated immunity may also contribute to disease predisposition (39).

Faergemann et al. (44) studied the effect of occlusive dressings on the growth of *M. furfur* naturally occurring on human skin. Colony counts of the organism increased 10-fold after 3 days; this increased growth rate, compared with growth on nonoccluded skin, was associated with increased local temperature and relative humidity. Faergemann and Fredriksson were also able to produce skin lesions in a rabbit model and pityriasis versicolor in human volunteers by inoculating the organism and occluding the skin with dressings (34, 48). The lesions healed within a few weeks following removal of the occlusive dressings.

At present, there is little information on the relative pathogenicity or virulence factors of *M. furfur* isolates. Faergemann et al. (41, 43), studying the adherence of *M. furfur* to human stratum corneum cells in vitro, showed that five strains adhered equally well to cells obtained from the forearm, chest, and back. Within 90 min in culture, a number of *M. furfur* cells produced short, hyphalike filaments, and within 5 days, the culture microscopically resembled that seen with pityriasis versicolor in vivo. Although adherence to epithelial cells is an important first step in colonization and subsequent infection, there are likely other unknown microbial factors that are important in pathogenesis.

Catheter-Associated Sepsis

Catheter-associated *Malassezia* sepsis is an iatrogenic infection, primarily of low-birth-weight infants, that occurs infrequently as a complication of placement of central venous catheters (CVCs) for long-term venous access coupled with administration of hyperalimentation fluids containing lipid emulsions (88). Presumably, the series of events leading to sepsis begins with the organism colonizing the infant's skin, gaining access to the catheter, colonizing the catheter with local reproduction, and finally invading the bloodstream and causing signs and symptoms of sepsis.

Skin colonization of newborns hospitalized in intensive care units and the associated risk factors for colonization have already been discussed. Interestingly, administration of lipid emulsions through the catheter does not appear to be a risk factor for skin colonization (107).

Exactly how the organism gains access to the catheter is unclear. It is possible that the catheter becomes contaminated with the organism at the time of surgical placement, by administration of a contaminated infusate through the catheter, or by hematogenous seeding of the catheter from a distant point of bloodstream invasion. However, it appears more likely that the organism gains access by migration of the organism from colonized skin along the subcutaneous catheter tract and outer catheter wall or by migration from a contaminated catheter hub (external connecting port) through the lumen (81). We have performed a limited number of hub cultures at the time of catheter removal in patients with culture-proven, catheter-associated *M. furfur* sepsis (85). Cultures were collected with swabs and plated onto GYP-S agar. In three of four cases, the organism was recovered from the hub as well as from the catheter tip. However, organisms were not recovered from the catheter hubs of 20 patients who had been receiving lipid emulsions for at least 2 weeks but without evidence of *Malassezia* infection. Instead of being the initial site of contamination, the hub may have been contaminated in the three cases as a

result of blood being drawn through an infected catheter. Further prospective studies may help in determining the role of hub contamination in the pathogenesis of catheter-associated *M. furfur* sepsis.

Once the organism gains access to the catheter, it may colonize the catheter locally (inner hub or outer subcutaneous surface) without producing overt clinical symptoms. In some patients, however, the organism gains access to the intravascular space by migrating around or within the catheter to the distal tip located in the inferior or superior vena cava or right atrium of the heart. At some point, the organism adheres to one or more segments of the catheter (Fig. 2), perhaps through some association between the outer fungal wall and fibrin sleeve or fibrin-platelet deposits formed outside and within the lumen of most long-term vascular catheters (122). In this location, the organism replicates to relatively large numbers.

We performed scanning electron microscopy studies on two catheters removed from patients with *M. furfur* catheter sepsis (109). The distal tips contained a dense mixture of erythrocytes and yeast cells in both the lumen and the inner luminal wall (Fig. 3). Organisms were also seen adhering to fibrous material on the middle intravascular and subcutaneous luminal walls, but in lower numbers. Results of these studies correlated with semiquantitative cultures of catheter segments. Scanning electron microscopy revealed no organisms on the external surface of any portion of the catheters.

In contrast to our data, Nowak et al. (103) reported that a catheter removed from an adult *M. furfur* sepsis patient was coated with a slimy, yellowish material on the external and internal subcutaneous segments; this material contained abundant leukocytes (WBCs) and yeast cells. Azimi et al. (8) reported a series of patients in whom occlusion of intravenous catheters was correlated with visible growth and recovery in culture (100%) of *M. furfur* from an external clear catheter that was connected to the intravascular device; recovery of *M. furfur* from the intravascular catheter tips was low (<50%). Collectively, these results suggest that catheter colonization may occur at a number of sites.

Colonization of the deep-line catheter by *M. furfur* is not necessarily associated with signs and symptoms of sepsis (7, 8). In fact, catheter colonization alone probably occurs more commonly than catheter-associated sepsis. Although the number of colonizing organisms may play a role in pathogenesis, Aschner et al. (7) and Azimi et al. (8) reported that infants may have heavily colonized catheters without obvious clinical symptoms. Other microbial factors as well as host factors (immunocompetence and pulmonary status) probably play a role in localizing the organisms to the catheter or in progression to fungemia and clinical sepsis. When organisms are shed into the bloodstream, the majority are probably trapped in the pulmonary vasculature, thus explaining the difficulty in isolating the organism from peripheral blood cultures, even when appropriate culture techniques are used (see below).

MALASSEZIA INFECTIONS

M. furfur Skin Infections

M. furfur has long been associated with a variety of superficial infections of the skin, including pityriasis versicolor and folliculitis (39, 51, 68, 115). Its role in several other skin diseases such as seborrhea and atopic dermatitis has recently received attention.

Clinical features. Pityriasis versicolor is a common scaling

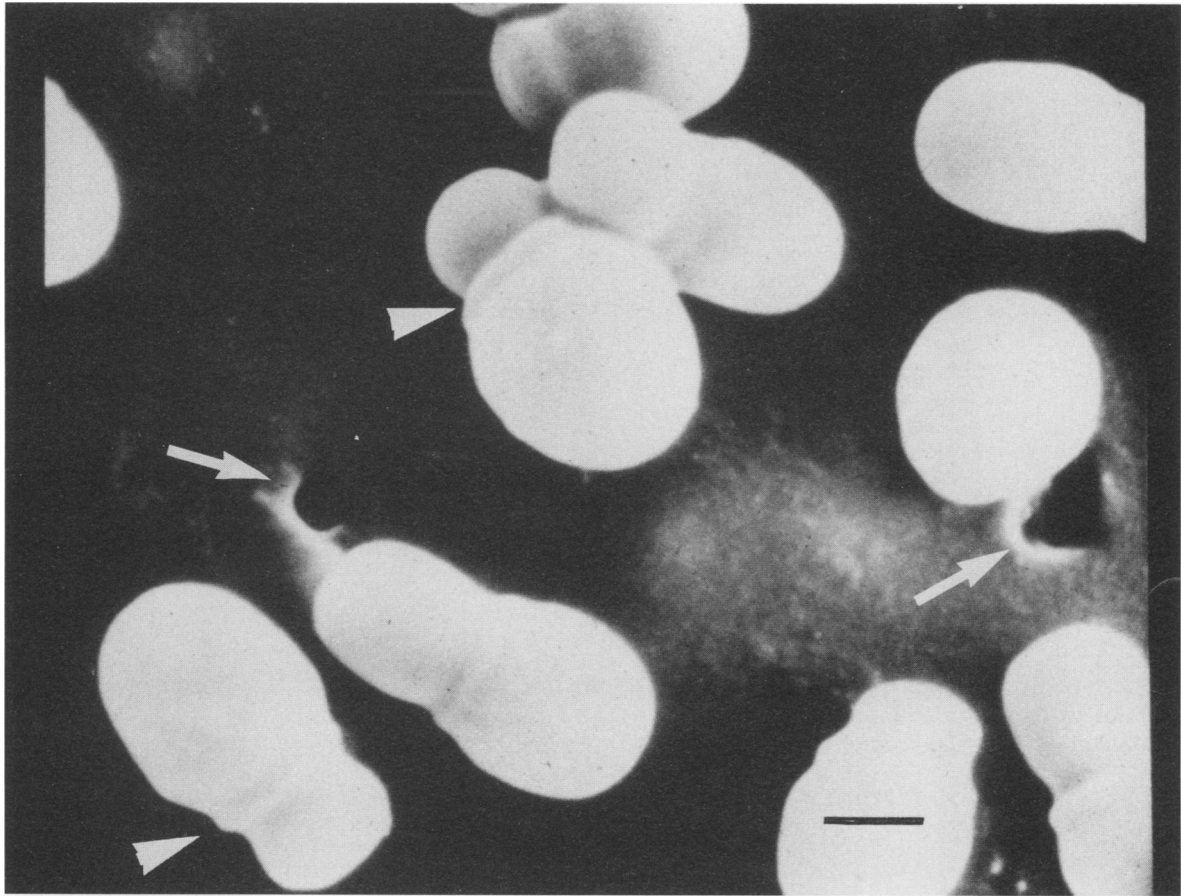


FIG. 2. Scanning electron micrograph of *M. furfur* attached to the luminal surface of a Broviac catheter. The catheter segment was incubated in vitro for 72 h in broth suspension with the organism. Note the characteristic morphology of unipolar budding yeast cells with collarettes (arrowheads) at the bud junctions. Also note the irregularities (arrows) in the surface of the catheter. Bar, 1 μ m. Adapted from reference 109, with permission of the publisher.

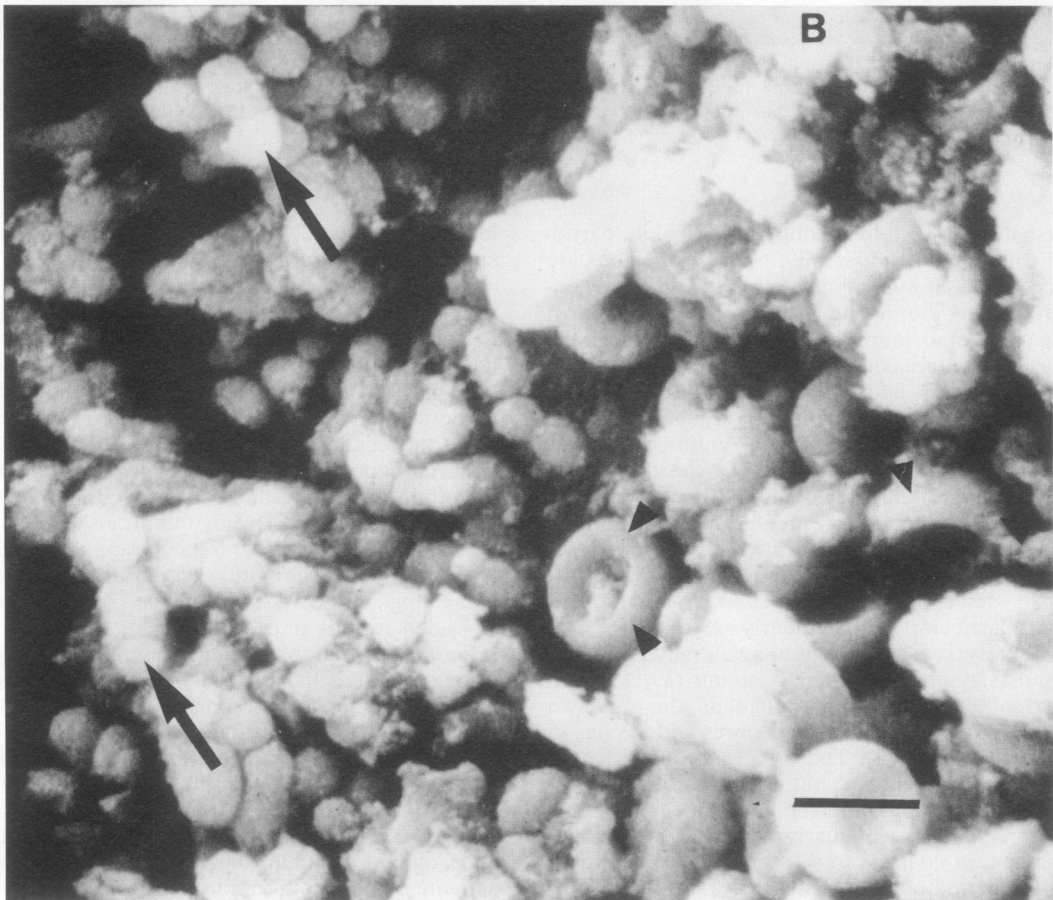
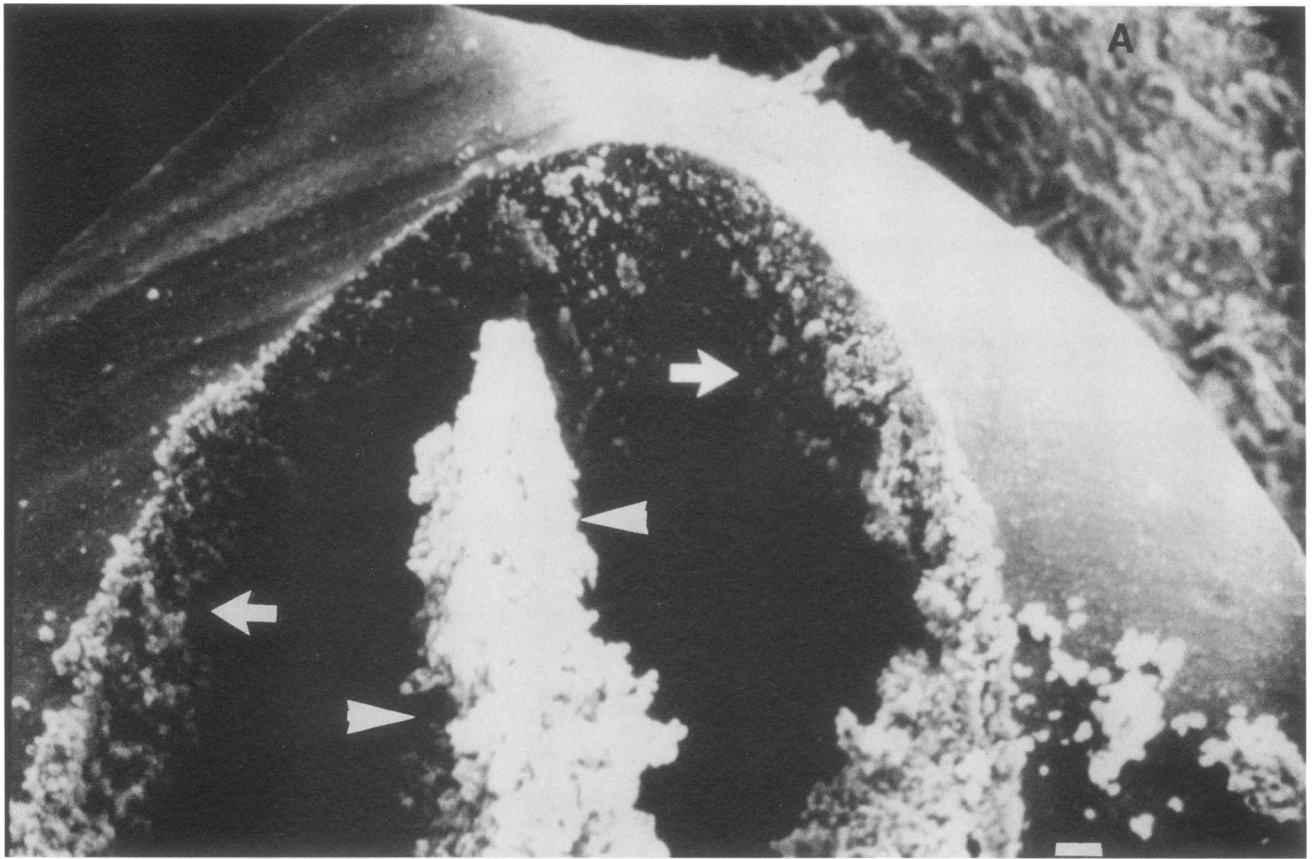
dermatosis usually confined to small patches of skin, particularly on the trunk and shoulders (39, 68, 115). Lesions are very superficial areas of hypopigmentation or hyperpigmentation that are chronic but asymptomatic. The rash is most notable in the summer as tanning occurs in surrounding skin while sparing infected areas of skin. The condition is most common in adolescents and young adults but has been described in infants as young as 1 month of age (97) and in the elderly (28). Although *M. furfur* in culture generally produces budding yeast cells only, some transformation to a mycelial phase occurs on infected skin. Diagnosis is usually established when skin scrapings treated with potassium hydroxide and examined microscopically reveal the characteristic yeast cells and hyphae (43, 68). Although fluorescence is usually detected by Wood's lamp examination, it may be absent, particularly in the elderly (28).

The lesions of pityriasis versicolor are generally restricted to the outermost layers of stratum corneum (39, 115). In periodic acid-Schiff-stained biopsy specimens, the organism may be seen in large numbers as blastospores and hyphae in the stratum corneum (Fig. 4). The organisms may also be seen extending into hair follicles, but invasion of the epidermis is seldom seen. Infiltration of the epidermis and dermis by lymphocytic cells is not regularly observed with hematoxylin-eosin stain, in contrast to infections due to *Candida albicans* and the dermatophytes. Thus, pityriasis versicolor

lesions are generally not accompanied by clinical symptoms such as redness or itching.

Some cases of pityriasis versicolor may be accompanied by greater pathologic findings. Breathnach et al. (15) reported that hyperkeratosis (hypertrophy of the corneous layer of the skin) and acanthosis (hyperplasia of the epidermis) may be seen by histology. Additionally, they observed moderate perivascular infiltrates of lymphocytes, plasma cells, and histiocytes in the dermis. Scheynius et al. (127) confirmed these findings and suggested that cellular changes in both the epidermis and dermis occur more frequently than reported previously. Drouhet et al. also observed hyperkeratosis, particularly at the follicular ostia and pilous bulbs, in an experimental dermatitis model of *M. furfur* infection in guinea pigs and Swiss white mice (30). Wu and Chen (149) classified lesions into groups by predominant color of the lesion: erythematous, hyperpigmented, and hypopigmented. They suggested that erythematous lesions resulted from a greater inflammatory response; however, no histologic examinations were performed.

The ability of antigen extracts of *M. furfur* to activate human serum complement may play some role in the type and magnitude of the inflammatory response found in pityriasis versicolor lesions. Both Belew et al. (11) and Sohnle and Collins-Lech (136) showed that the organism was able to activate complement in normal serum or serum having only



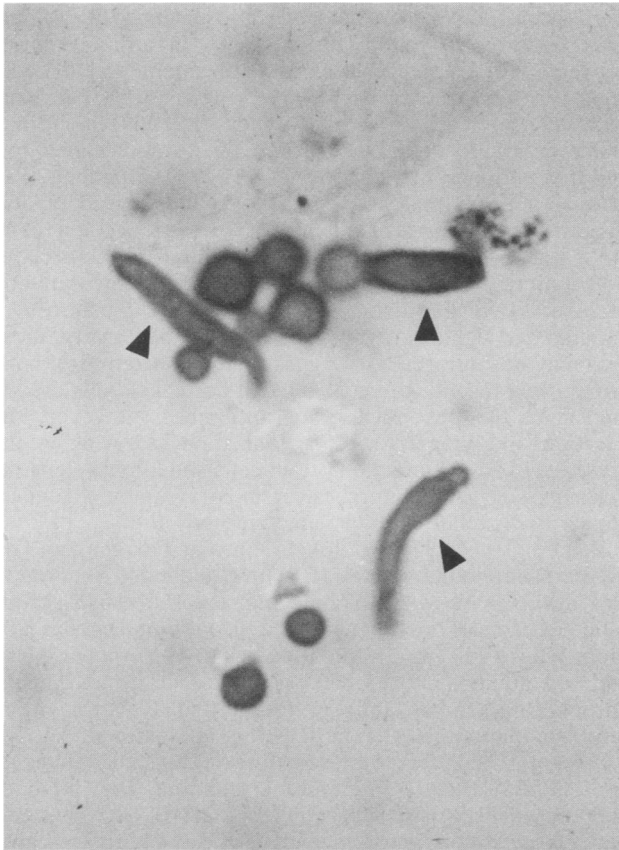


FIG. 4. Light micrograph of periodic acid-Schiff-stained skin scrapings from an adult with pityriasis versicolor. Note the budding yeast cells and hyphal forms (arrowheads) of *M. furfur*. Adapted from reference 88, with permission of the publisher.

the alternative complement pathway intact. Complement activation was similar for *C. albicans*, an organism causing superficial cutaneous infections that, in marked contrast to *M. furfur*, are highly inflammatory with large numbers of neutrophils in acute infections and marked mononuclear cell infiltration in chronic infections (136). Thus, the complement-activating ability of those two organisms cannot account for the differences in degree of inflammation seen in cutaneous lesions.

Several investigators have studied the cause of both hypo- and hyperpigmentation of pityriasis versicolor lesions. Allen and Charles (4) concluded that the red-brown color of hyperpigmented lesions was due to an increase in size and a change in distribution of melanosomes (tyrosinase-containing granules that synthesize melanin within melanocytes) compared with those in normal skin. Charles et al. (22) found abnormally small melanosomes in hypopigmented lesions and suggested that there was a block in the transfer of melanosomes from melanocytes to keratinocytes. Nazzaro-Porro and Passi suggested that the organism produced a

substance that inhibited tyrosinase activity and thus prevented synthesis of melanin (98).

Folliculitis due to *M. furfur* was first mentioned by Weary (144) in 1968 and described in clinical detail by Potter et al. (105) in 1973. It is an erythematous papulopustular rash that most often affects adults and may be more common than recognized. Underlying conditions that may predispose to *M. furfur* folliculitis include diabetes mellitus, Cushing's syndrome, multiple trauma, chronic renal failure, renal transplantation, bone marrow transplantation, malignancy, and the administration of broad-spectrum antibiotics or corticosteroids (19, 65, 74, 76, 152). Lesions are distributed most commonly over the back and anterior portion of the chest and, to a lesser extent, on the shoulders, arms, neck, and flanks. The typical lesions begin as inflamed hair follicles that progress to papules or pustules 2 to 4 mm in diameter and are usually pruritic (9, 51). Lesions may develop crusting and heal in 3 to 5 days, but most become chronic, going undiagnosed for up to 8 years. In immunocompromised patients, lesions may spread rapidly and be accompanied by high fever (19).

Folliculitis due to *M. furfur* must be differentiated from acne, the macronodular lesions of disseminated candidiasis, and the candidal papulopustulosis of heroin addicts (74, 75). In contrast to acne, folliculitis is often pruritic, lacks comedones, and is unusual in adolescents. Both of the candidal infections are thought to result from candidal sepsis and are differentiated from *M. furfur* folliculitis by biopsy and culture. Biopsy of the papulopustules caused by *M. furfur* shows keratin plugging of the pilosebaceous follicle, amorphous cellular debris, and inflammatory cells. The follicle wall may be destroyed, with resultant intense perifollicular inflammation. Budding yeast cells but not mycelia are evident in the hair follicle infundibulum.

Skin diseases in which the role of *M. furfur* is less well established include psoriasis, adult and infantile seborrheic dermatitis, atopic dermatitis, confluent and reticulate papillomatosis, intertrigo, and erythema annulare centrifigum (16, 49, 71, 73, 102). Support for the role of *M. furfur* in psoriasis and seborrhea comes primarily from the beneficial effect of ketoconazole on both of these dermatologic conditions (52, 121). In the only placebo-controlled trial of seborrhea treatment, Faergemann demonstrated a significantly higher cure rate in adults with seborrhea and cultures positive for *M. furfur* who were treated for 4 weeks with a twice-weekly ketoconazole shampoo (40). Heng et al. (64) recently correlated the severity of seborrheic dermatitis with the number of *M. furfur* yeast cells seen during microscopic examination of skin scrapings from adult males. The quantity of yeast cells in scrapings from patients with any degree of facial seborrhea was significantly greater than that observed in scrapings from healthy controls. Following twice-daily application of 5% precipitated sulfur and 2% salicylic acid in a shampoo base for 3 months, 90 of the 100 patients with facial seborrhea became clinically cured and had markedly less *M. furfur* present on microscopic examination of skin scrapings.

M. furfur may also be involved in infantile seborrhea. In two studies, the prevalence of *M. furfur* recovered from skin

FIG. 3. Scanning electron micrographs of the distal tip of a Broviac catheter removed from an infant with *M. furfur* sepsis. (A) The lumen of the catheter contains a blood clot (arrowheads), and the luminal wall (arrows) is covered with a dense matrix of erythrocytes and yeast cells. Bar, 20 μ m. (B) Higher magnification of scanning electron micrograph in panel A, showing erythrocytes (arrowheads) and *M. furfur* yeast cells (arrows) lining the luminal surface of the Broviac catheter. Bar, 5 μ m. Adapted from reference 109, with permission of the publisher.

scrapings was significantly higher from infants <1 year old with seborrhea than from healthy controls or infants with other dermatoses (16, 123).

There has been research interest in *M. furfur* as a potential etiologic agent of the seborrheic dermatitis that occurs in 30 to 80% of patients with AIDS; this contrasts to a 3 to 5% incidence in the general population (33, 90). In a survey of 10 patients with AIDS and seborrheic dermatitis, *M. furfur* was identified on microscopic examination of skin scrapings from areas of rash in all patients (59). The quantity of yeast cells correlated with the severity of the rash. Two patients, who were treated topically with 2% ketoconazole for 2 weeks, had rapid clearing of their rash. In a comparison of 12 patients without rash but seropositive for human immunodeficiency virus infection and 12 seronegative controls, no significant differences in the quantity of *M. furfur* cells from skin scrapings were found for the two groups (62). Thus, human immunodeficiency virus infection appears not to predispose to more abundant skin colonization with *M. furfur*, but progression to AIDS may result in the evolution of *M. furfur*-associated skin lesions.

The role of *M. furfur* in adolescent and adult atopic dermatitis has also received recent attention. In a study of 131 affected children aged 7 to 18 years, IgE antibodies to *M. furfur* were present in 38% with active eczema, 22% with a history of eczema, and 7% with no history of eczema (102). Similarly, Rokugo et al. (119) demonstrated a significantly higher incidence of positive immediate hypersensitivity reactions to scarification-patch skin tests with *M. furfur* extracts in children with eczema than in healthy controls. Adults with eczema and an erythematous, scaling, and pruritic rash of the head, neck, and shoulders had significantly more *M. furfur* identified microscopically in their skin scrapings than did healthy controls or eczema patients without the scaling rash (139). This association was consistent with the observation of Hjorth and Clemmensen (67) that ketoconazole was beneficial in the treatment of atopic patients with a severe dermatitis of the head, neck, and shoulders.

Treatment. Treatment for the various *M. furfur* skin infections is usually prolonged, and relapses may be frequent (19, 51, 53, 66, 74, 144). For pityriasis versicolor, 2.5% selenium sulfide is applied to all involved areas, left overnight, and washed off the following morning by bath or shower. Application is repeated weekly for 3 to 4 weeks and then monthly for 3 months (144). Alternative therapy includes topical ketoconazole or miconazole creams or lotions, as well as oral ketoconazole (74). For folliculitis, treatment involves application of propylene glycol (50% in water) twice daily for 3 weeks or clotrimazole or miconazole cream daily for 2 to 3 weeks (74). In severe or refractory cases, oral ketoconazole (200 mg daily for 2 to 3 weeks) is recommended (51, 53, 66). Response to therapy may be slow, requiring several months of treatment, and relapses are frequent, particularly in AIDS patients (31). In neutropenic patients, treatment may fail until absolute neutrophil counts rise to $>500/\text{mm}^3$ (19).

The clinical utility of antifungal agents in the treatment of other skin diseases attributed to *M. furfur* is less well established.

Antibody and cell-mediated immune response. A number of investigators used indirect IF to determine the antibody response to *M. furfur* in patients with pityriasis versicolor and in healthy controls. Furukawa et al. (54) studied pityriasis versicolor patients and healthy controls and found no difference between antibody titers and lesional duration,

distribution, color, or presence or absence of itching. Faergemann also found no difference in antibody titers between patients and adult controls or among patients with regard to age, sex, or duration or distribution of lesions; however, adult controls had higher antibody titers than children (35). In contrast, Wu and Chen found higher IgG and IgM antibody titers in pityriasis versicolor patients than in age- and sex-matched controls (149). Their data also suggest that the degree of inflammation of the lesion (erythematous lesion suggesting the greatest inflammation) correlates with antibody titers. DaMert et al. (26) found low antibody titers to *M. furfur* in healthy subjects, but a majority of patients had significantly elevated titers. Collectively, these data may be interpreted to suggest that colonization with *M. furfur* (the presence of yeast cells on normal skin) is associated with the development of antibodies; however, the duration and magnitude of colonization, as well as the presence of actual infection (yeast cells and hyphal elements in lesions suggesting pityriasis versicolor) with the organism, appear to correlate with elevated antibody titers.

Sohnle et al. (137) and Johansson and Faergemann (70) used enzyme immunoassay (EIA) techniques to study antibody levels to *M. furfur*. Sohnle and coworkers, using crude saline extracts of the organism as antigen, found similar EIA titers of IgG, IgA, and IgM antibodies to *M. furfur* in young and old adults (137). Johansson and Faergemann, using unbroken yeasts as antigen, found that EIA was more sensitive than indirect IF in detecting IgG antibodies to *M. furfur* (70). Using this more sensitive method, they detected low antibody titers in 6-month-old children. EIA methods may be of value in separating colonized from infected patients. Additional studies such as EIA with purified antigens or Western blot (immunoblot)-type assays are needed to better define the antibody responses to *M. furfur* in healthy and infected patients. It is clear, however, that most pityriasis versicolor patients have significant levels of antibody to *M. furfur*, perhaps indicating that antibody is not protective.

As a group, patients with pityriasis versicolor do not have increased susceptibility to infectious agents; thus, generalized deficiencies in cell-mediated immunity are unlikely. However, some studies have shown decreased cell-mediated immune response to *M. furfur* antigens in patients compared with healthy subjects. Sohnle and Collins-Lech (133-135) found that most pityriasis versicolor patients produce fewer lymphokines (leukocyte migration inhibition factor) than healthy subjects when their respective lymphocytes were stimulated with *M. furfur* extracts in vitro (134). In addition, lymphocytes from patients appear to have decreased blast transformation responses to the organism (135). Scheynius et al. (127) confirmed and extended earlier work (133-135) showing that T- and B-cell proportions, T-cell subpopulations, and proliferative responses of circulating mononuclear cells to a variety of antigens and mitogens were normal in pityriasis versicolor patients. Thus, selective depression in cell-mediated immunity may play some role, along with other nonimmunological factors, in permitting chronic infection with this organism.

M. furfur Catheter-Associated Infections

In addition to involvement of the skin in a variety of diseases, *M. furfur* is associated with systemic illness. Although there have been two case reports of peritonitis (56, 143), one of mixed bacterial-fungal septic arthritis (150), one of dacryocystitis (148), one of mastitis (13), and one of

TABLE 2. Clinical features of 57 published cases of *M. furfur* sepsis in 55 infants <1 year old^a

Yr published	Reference(s)	Total no. of patients	No. of patients with ^b :					
			Fever	RD or apnea	Pneumonia	Leukopenia ^c	Leukocytosis ^d	Thrombocytopenia ^e
1984-1987	87, 106, 108	17	14	8	9	0	7	8
1984	110	1	1	1	0	0	0	1
1985	113	3	3	3	3	0	1	2
1985	82	5	4	2	0	1	1	3
1987	5	7	1	4	NS	2	1	5
1987	8	2	1	1	1	0	0	1
1987	7	5	1	3	NS	NS	NS	NS
1988	27	5	0	1	0	1	0	2
1989	114	3	0	3	3	0	3	2
1989	128	3	1	1	1	0	2	0
1989	138	6	4	3	1	0	1	1
Total (%)		57	30 (53)	30 (53)	18 (40)	4 (8)	16 (31)	25 (48)

^a Two infants had two separate infectious episodes.

^b RD, respiratory distress; NS, not stated.

^c <5,000 WBCs per mm³.

^d >15,000 WBCs per mm³.

^e <150,000 platelets per mm³.

chronic postoperative sinusitis (104), nearly all other reported cases of *M. furfur*-associated systemic illness have involved patients receiving intravenous lipid infusions through an indwelling CVC, commonly of the Broviac or Hickman type. Catheter-associated *M. furfur* sepsis has been reported in 57 episodes involving 55 infants of <1 year of age (5, 7, 8, 27, 82, 87, 106, 108, 110, 113, 114, 128, 138), 4 children from 1 to 18 years of age (63, 87, 113), and 9 adults (6, 17, 27, 55, 93, 113). All of the patients had been receiving parenteral lipid emulsions through a CVC within 3 days of diagnosis of infection. Due to the severity of underlying illness in many of these patients, it is difficult to assess the precise role of *M. furfur* in clinical status and final outcome of patients.

Clinical features. Catheter-associated infection was first described in a 749-g premature infant who had received 6 weeks of therapy with parenteral intravenous lipid emulsions (112). Following sudden respiratory deterioration and progressive bilateral pulmonary consolidation with leukocytosis, an open lung biopsy was performed, and it demonstrated bronchopneumonia and pulmonary vasculitis. Large numbers of unipolar budding yeast cells were seen in the lumen, intima, media, and adventitia of pulmonary arteries. Cultures of a portion of the lung biopsy sample grew *M. furfur*. Despite therapy with amphotericin B and 5-fluorocytosine, the infant died 2 weeks later. Autopsy confirmed the diffuse fungal vasculitis. This infant represents the severe end of a spectrum of infection that ranges from asymptomatic catheter colonization to clinical sepsis and death.

Of the 55 infected infants who were <1 year old, 33 were premature newborns with a variety of complications including simple feeding intolerance, respiratory distress syndrome, or chronic bronchopulmonary dysplasia; 19 had surgical short-gut syndromes (e.g., gastroschisis, ruptured viscus, or necrotizing enterocolitis); and 3 were otherwise chronically ill. All infants had been receiving total parenteral nutrition with lipid supplementation for 4 to 210 days. Two of the infants developed a second infection occurring at 4 and 12 months after the first infection resolved; both new infections involved new CVCs.

The most commonly reported symptoms of systemic infection in the infants have been fever (53%) and respiratory

distress with or without apnea (53%) (Table 2). Other less common symptoms have included lethargy, poor feeding, bradycardia, hepatomegaly, and splenomegaly. Of note, skin rash has not been described with systemic infections, and erythema, swelling, or purulence at the entry site of the infected CVC has been absent. Pneumonia with an interstitial, bronchopneumonic, or consolidative appearance on roentgenograms has been described in 40% of infants. The primary laboratory abnormalities have been leukopenia (<5,000 WBCs per mm³) in 8%, leukocytosis (>15,000 WBCs per mm³) in 31%, and thrombocytopenia (<150,000 platelets per mm³) in 48% (Table 2).

The clinical features of *M. furfur* sepsis in children aged 1 to 18 years and adults >18 years old are listed in Table 3. The four children included an 18-month-old female with trisomy 21, Hirschsprung's disease, and a colostomy (113); a 3.5-year-old boy with short-bowel syndrome after surgery for volvulus and ileal atresia (63); a 9.75-year-old boy with a brain stem glioma (87); and a 16-year-old male with Crohn's disease and total small-bowel resection (113). All had been receiving parenteral lipid emulsions through CVCs for 4 days to 3.5 years prior to infection. The child with the longest duration of parenteral nutrition received fat emulsions only twice weekly; the others received daily administration. Three children presented with fever as their initial symptom of infection. One of them, the 3.5 year old, had a right atrial clot surrounding the tip of the CVC; the clot required surgical excision after streptokinase therapy failed to dissolve it. Cultures of the clot grew *M. furfur*. Ten days later, the patient required a left pneumonectomy because of complete occlusion of the left pulmonary artery, and *M. furfur* was visualized in areas of vasculitis throughout the infarcted lung (63). Fever and leukocytosis resolved 4 days after the pulmonary resection. One child had leukopenia and two had thrombocytopenia. The child with a brain tumor had been receiving parenteral lipid emulsions for only 4 days; a low platelet count was the only sign of infection. Pneumonia was documented only in the 18-month-old child, but it was not stated whether he had respiratory distress.

The nine adults with catheter-associated *M. furfur* sepsis presented with a variety of underlying illnesses (Table 3). The patients were 22 to 71 years old, and all but one were

TABLE 3. Clinical features of *M. furfur* sepsis in children and adults

Age group and yr published	Reference	Total no. of patients	No. of patients with ^a :					
			Fever	RD or apnea	Pneumonia	Leukopenia ^b	Leukocytosis ^c	Thrombocytopenia ^d
Children, 1-18 yr								
1983	63	1	1	0	0	0	1	0
1985	113	1	1	0	0	0	1	0
1987	87	2	2	NS	1	1	0	1
Total (%)		4	4 (100)	0 (0)	1 (25)	1 (25)	2 (50)	1 (25)
Adults, >18 yr								
1985	113	2	2	NS	2	1	0	1
1987	27	2	2	0	0	0	0	0
1987	55	2	2	0	0	0	0	0
1987	17	1	1	0	0	NS	NS	NS
1987	93	1	1	0	1	NS	NS	1
1991	6	1	1	0	0	NS	NS	NS
Total (%)		9	9 (100)	0 (0)	3 (33)	1 (11)	0 (0)	2 (22)

^a RD, respiratory distress; NS, not stated.

^b <5,000 WBCs per mm³.

^c >15,000 WBCs per mm³.

^d <150,000 platelets per mm³.

males. Six of the patients had recently undergone some form of bowel surgery for intestinal injury due to radiation (17), massive intraabdominal trauma (6), Crohn's disease (93), postoperative bowel infarction (55), colonic hemorrhage (27), or adenocarcinoma with bowel resection (27). The other three patients had hemorrhagic pancreatitis (113), longstanding short-bowel syndrome, and seizure disorder (55) or aplastic anemia with allogeneic bone marrow transplantation and severe gastrointestinal graft-versus-host disease (113). All had been receiving parenteral lipid emulsions through CVCs for periods ranging from 3 days to 2 years. Lipids were given every third day to one patient and twice weekly to another. In all adults, fever was the consistent presenting symptom. When described, fever was spiking in nature and usually low grade, although two patients had fever as high as 40°C. Three adults had pneumonia described as bilateral basilar infiltrates, diffuse left lung consolidation, or patchy left lower lobe infiltrate. No mention was made of interstitial appearance of the infiltrates. The only other symptoms mentioned in the nine adult patients were some episodes of chest pain and cholestatic jaundice, which developed simultaneously with pneumonia and spiking fevers in an adult with acute nonlymphocytic leukemia in remission. This same patient and two others developed thrombocytopenia. Leukopenia was observed in another thrombocytopenic patient.

The predominant pathologic changes associated with catheter-associated *M. furfur* infections have involved the heart and lungs; these included mycotic thrombi around the tips of deeply placed catheters, vegetations of the endocardium, and inflammatory lesions of the lung (128). In cases in which lung biopsy (63, 112, 113) or autopsy (113, 128) were performed, *M. furfur* was well stained with Gomori methenamine silver, periodic acid-Schiff, the Gridley fungus stain, and tissue Gram stains. The appearance of round to oval yeasts, 2 to 5 µm in diameter with unipolar budding through a collarette, distinguishes *M. furfur* from other fungi. Pathologic changes within the lung include mycotic emboli with complete occlusion of pulmonary arteries (63, 128), septic thrombi, pulmonary vasculitis, and alveolitis (112, 113, 128).

Septic thrombi are often attached to arterial intima and contain yeasts, fibrin, lipid droplets, degenerating WBCs, and histiocytes with ingested yeast cells. Some thrombi are associated with acute vasculitis and present a layered or "target" appearance that suggests growth by accretion around emboli impacting in arterioles or around organisms directly infecting lipid-containing arterial intima (128). Some thrombi are organized and partially recanalized, while others have no surrounding vasculitis, suggesting recent dislodgement from CVC tips (113). *M. furfur* may be found in the walls of surrounding alveoli, which are filled with acute inflammatory cells, and in the lumina of alveoli, bronchioles, and bronchi.

Shek et al. (128) observed that *M. furfur* may disseminate to deep organs other than the lungs. In three fatal cases of *M. furfur* sepsis, yeast cells were identified in blood vessels of the heart, kidney, pancreas, colon, adrenal gland, liver, spleen, and brain. While yeast cells were usually not associated with thrombi or inflammation, clusters of cells occluded some small vessels and some were associated with small "target" thrombi. One infant had *M. furfur*-associated meningoencephalitis. Vessels of the subarachnoid space were occluded by septic thrombi, and yeast cells were seen in multiple foci of necrotizing encephalitis involving periventricular white matter, cerebral cortex, basal ganglia, and brain stem.

Treatment. Treatment of *M. furfur* sepsis has varied greatly from center to center, and precise details of management are lacking for some of the patients. Therapy has generally involved (i) discontinuation of lipids while the CVC was left in place, (ii) removal of the CVC (with or without continuation of lipid emulsions), (iii) antifungal therapy without CVC removal, or (iv) antifungal therapy with CVC removal. Eight recorded deaths resulted from the 57 infections in infants <1 year old, four deaths occurred in adult patients, and none occurred in the four children. In assessing the outcomes, the most successful mode of treatment seems to have been removal of the infected CVC. None of the eight infant deaths occurred among the 44 episodes managed by removing the infected CVC, whether

or not antifungal agents were given. In contrast, death occurred in all six infants who received no form of therapy, one of two infants who only had lipids discontinued without catheter removal, and one of five infants who received antifungal therapy with the catheter left in place.

Three infants survived but failed to resolve their infections despite antifungal therapy through infected catheters. One of these patients, as reported by Dankner et al. (27), had been treated for *M. furfur* sepsis with 7 days of intravenous amphotericin B (dose not stated) and discontinuation of parenteral nutrition. The original Broviac catheter was not removed, and *M. furfur* was again cultured from blood drawn through the same catheter 22 days after the last day of amphotericin B therapy. Powell and Marcon (108) attempted unsuccessfully to treat two infants with infusions of antifungal agents through infected Broviac catheters. The first infant was treated with miconazole (30 mg/kg of body weight/day) for 7 days and then with amphotericin B (0.5 mg/kg/day) for 9 days. The second infant was treated with miconazole (25 mg/kg/day) for 11 days. Blood cultures from the two infants remained positive for 16 and 7 days, respectively, and *M. furfur* grew from luminal washings of the distal tips of both catheters removed on days 16 and 11 of antifungal therapy, respectively.

Of the four children and nine adults with *M. furfur* sepsis, four were successfully treated with catheter removal. Four of five patients, treated with antifungal therapy administered through the infected CVC, died; however all had severe underlying diseases, and none had autopsies with appropriate cultures to determine the role of *M. furfur* in their deaths. One patient improved for 4 days after therapy with amphotericin B was begun, but new pulmonary infiltrates necessitated an open lung biopsy that demonstrated *Pneumocystis carinii* and residual *M. furfur* (113). Another patient from whom the CVC could not be removed died from cardiac arrest 10 days after amphotericin B therapy was begun. Although histologic sections of lung at autopsy did not reveal pulmonary vasculitis or deep fungal infection, cultures or special fungal stains were not done (55). Despite 4 weeks of intravenous amphotericin B therapy, blood cultures from two other patients were repeatedly positive for *M. furfur* until shortly before their deaths (17, 55). Thus, it is necessary to remove the deep-line catheter in most cases to eradicate *M. furfur*.

Several patients, some of whom received coincident antifungal therapy, recovered from *M. furfur* sepsis following discontinuation of parenteral lipid emulsions; however, it is not clearly stated in the reports whether the infected CVC was removed. Two children and one adult were successfully treated by discontinuation of parenteral lipids (113), and three premature infants were successfully treated by discontinuation of parenteral lipids and intravenous miconazole therapy (13 to 30 mg/kg/day) for 10 to 15 days (138). While these patients may represent cases successfully treated without removal of the infected CVC, there is one definitive case report of eradication of *M. furfur* without removal of the infected catheter. Arnow and Kushner (6) recently described a novel method for successfully managing *M. furfur* sepsis in an adult without removing the infected catheter. Following isolation of *M. furfur* from blood culture, the patient was treated with a total of 435 mg of amphotericin B infused through the infected Hickman catheter (20 to 35 mg/day). Although blood cultures obtained through the catheter remained negative for 3 months, infection recurred, with multiple positive cultures drawn through the same catheter; infection was associated with fatigue and

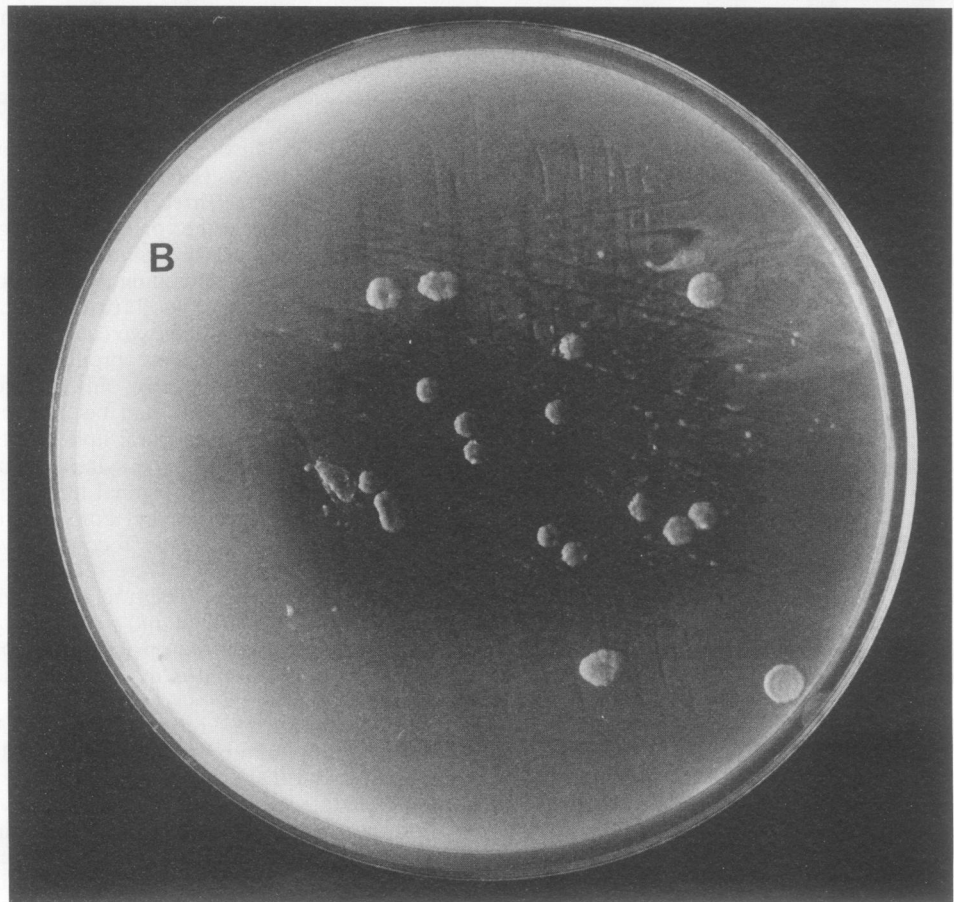
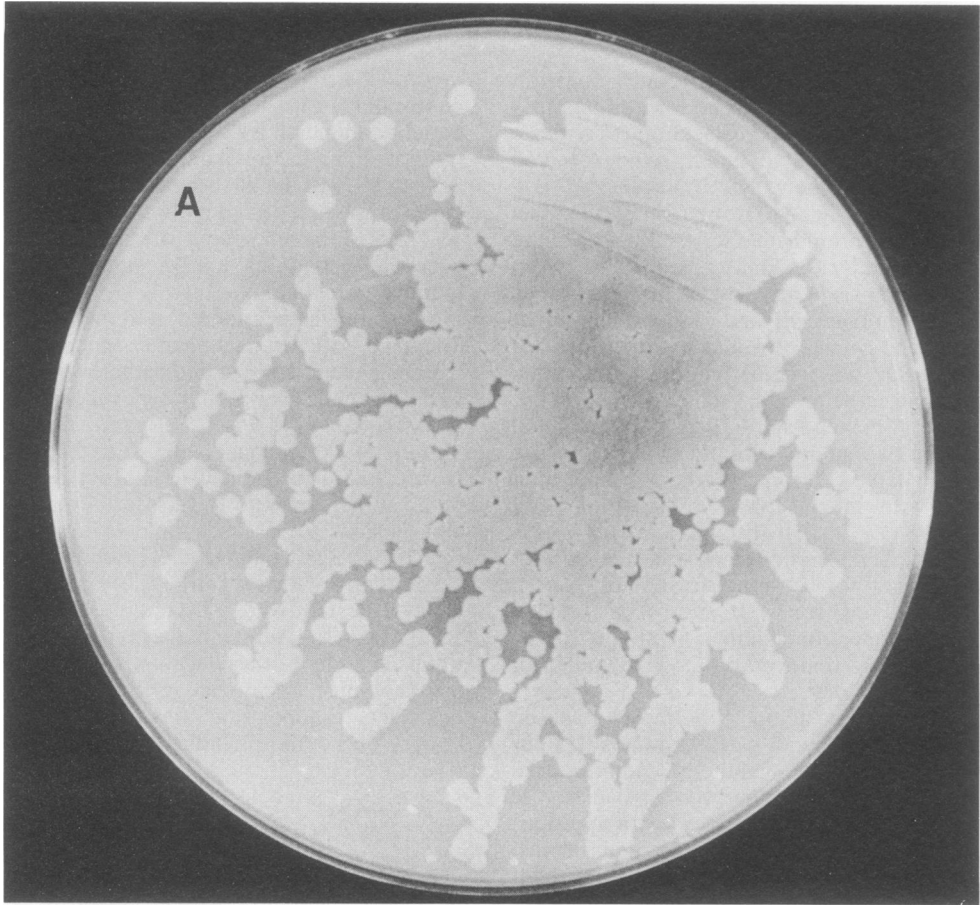
fever. This time, parenteral lipids were halted and an amphotericin B catheter "lock" technique was used. After the patient completed a 12-h infusion of parenteral alimentation (without lipids), 2 ml of amphotericin B at a concentration of 2.5 mg/ml was instilled and locked into the lumen of the catheter for 12 h each day for 21 days. Fever resolved within 48 h after the beginning of this form of treatment, and subsequent cultures for *M. furfur* were negative for 16 months after therapy.

Several investigators reported the in vitro susceptibility of *M. furfur* to antifungal agents. Marcon et al. (86) reported that 15 systemic (blood and catheter tip) and 10 skin isolates were susceptible or moderately susceptible to amphotericin B (MIC range, 0.3 to 2.5 µg/ml), miconazole (0.4 to 1.5 µg/ml), and ketoconazole (0.025 to 0.4 µg/ml); however, the isolates were resistant to 5-fluorocytosine (MIC, >100 µg/ml). Faergemann and Bernander (45) reported that 16 of 19 skin isolates were susceptible to miconazole (MIC range, 0.05 to 1.5 µg/ml); however, 3 isolates were resistant (MIC, >50 µg/ml). Faergemann (37) also reported that six of six isolates tested were susceptible to ketoconazole (MIC, ≤0.05 µg/ml). Although these data suggest the potential utility of some of these agents in the treatment of *M. furfur* sepsis, clinical experience in eradicating infection with them has been disappointing; this failure is probably due to a variety of factors, including the presence of a foreign body (the CVC).

M. pachydermatis Human Infections

Reports of human infections with *M. pachydermatis* have been fewer than those with *M. furfur* (61, 77, 92). Except for a single report of *M. pachydermatis* canaliculitis in a 61-year-old man (120), the two reports of confirmed clinical cases involved infants in an NICU. Larocco et al. (77) retrospectively reviewed their clinical microbiology laboratory records of cultures obtained from 507 infants hospitalized in their NICU from October 1985 to January 1987. They identified eight infants (1.6%) from whom *M. pachydermatis* had been recovered. Three infants had single isolates from cerebrospinal fluid, urine, or eye discharge; one infant had positive urine and ear discharge cultures; and four infants had multiple isolates, including isolates from catheter blood (four cases), peripheral blood (two cases), central line catheter tip (three cases), urine (two cases), and tracheal aspirate (one case). All infants were premature and had multiple complications of prematurity; all but the infant with the cerebrospinal fluid isolate had been receiving broad-spectrum antibiotics and parenteral lipid emulsions for 18 to 35 days through a CVC. Clinical symptoms occurred in all but the infant with the cerebrospinal fluid isolate and included apnea and/or bradycardia or temperature instability. The four patients with fungemia recovered without antifungal therapy when their CVCs were removed. The two patients with a single positive eye culture and a single positive urine culture died from cardiac and pulmonary decompensation, respectively. Because autopsies were not performed, any role for *M. pachydermatis* in causing these deaths is speculative.

Mickelson et al. (92) reported details of *M. pachydermatis* sepsis in three infants in their NICU. All infants had birth weights of <1,000 g and had numerous complications of prematurity. Lipid emulsions had been given for 8 weeks to 5 months prior to development of symptoms, which included fever (two cases), lethargy (one case), respiratory distress (one case), and repeat bouts of bradycardia (one case). One



infant developed erythema at the catheter insertion site 2 days after onset of symptoms. Chest roentgenograms were normal in all three patients. Laboratory findings included thrombocytopenia (all three infants), leukocytosis (two infants), and leukopenia (one infant). All had multiple positive blood cultures obtained from a CVC, and two infants had positive cultures of peripheral venous blood. Two infants recovered promptly after removal of the CVC and short courses of amphotericin B, while one infant recovered after a 10-day course of amphotericin B infused through the infected catheter.

Mickelson et al. (92) also reported isolating *M. pachydermatis* from an additional 30 patients over a 3-year time period; 28 of the 30 patients were infants in the NICU. Clean-catch or bagged urine samples accounted for 80% of the isolates; other samples included endotracheal aspirates and swab specimens from the nares, rectum, and vagina. None of the 30 patients had symptoms or signs of illness. These data suggest that *M. pachydermatis* may colonize various anatomic sites in hospitalized patients, particularly those patients in an NICU.

A survey of yeasts received at a reference center confirmed the observation that multiple anatomic sites can be sources of *M. pachydermatis* (61). Because clinical descriptions were not included in the survey, it is impossible to determine whether most isolates were causing an infection or merely colonizing the sites; however, 4 of 15 isolates were obtained from blood culture.

LABORATORY DIAGNOSIS OF *MALASSEZIA* INFECTIONS

Pityriasis Versicolor

Laboratory diagnosis of pityriasis versicolor and other superficial infections is most easily accomplished by microscopy. Skin scrapings of the affected areas should be examined by KOH or KOH-calcofluor white preparations as wet mounts. Microscopic examination shows characteristic budding yeast and short hyphal forms that are diagnostic for pityriasis versicolor. Scrapings may also be stained with periodic acid-Schiff if procedures are used to ensure that the material adheres to the glass slide.

Faergemann described a simple method that facilitates preparation of material for direct microscopy (39). Transparent cellophane tape is pressed firmly against the affected skin to obtain a thin layer of superficial epithelial cells, and the tape is then stained with a 1% solution of methylene blue, mounted on a glass slide, and examined under the microscope.

Although culture of the organism from skin is generally not necessary for routine diagnosis, it can be easily accomplished and may be helpful in diagnosing superficial infections other than pityriasis versicolor. A skin scrub (36) method as well as a contact plate method (38) have been described elsewhere. The use of solid culture medium with lipid source contained in the agar (such as GYP-S), thus allowing for quantitative counts of organisms, may be helpful in differentiating infected from colonized individuals. Winkler et al. (147) have described a Scotch tape method of

performing quantitative skin cultures for *M. furfur*; the method may be useful in diagnosing both pityriasis versicolor and seborrheic dermatitis associated with *M. furfur*.

Catheter-Associated Sepsis

Compared with other yeasts such as *Candida* spp. and with bacteria such as the staphylococci, *Malassezia* spp. are a relatively uncommon cause of catheter-associated sepsis. However, the specialized growth requirements of these organisms mandate that laboratorians develop modified diagnostic methods to support clinical diagnosis.

Catheter-associated *Malassezia* sepsis should be suspected in a patient with clinical evidence of sepsis who is receiving lipid emulsions through a CVC. Laboratory methods for establishing the diagnosis can be classified into two groups: those that require catheter removal and those that do not require removal. Generally, the latter method is initially attempted because clinicians wish to maintain the CVC if possible.

Direct examination of catheter or peripheral blood. Nowak et al. (103) detected *M. furfur* as the probable agent of catheter sepsis by examining Giemsa-stained smears of blood drawn through the catheter; no organisms were seen in smears of peripheral blood. Mickelson et al. (92) observed yeast cells suggesting *Malassezia* spp. in a Wright's stain of a peripheral blood smear; *M. pachydermatis* was recovered from a peripheral blood culture. Long and Keyserling (82) diagnosed catheter-associated *M. furfur* sepsis in four patients by examining buffy coat Gram-stained smears of blood obtained through the catheter. Azimi et al. (8) detected catheter-associated *M. furfur* sepsis by observing visible growth in the clear connecting catheter located between the infusate and the deep intravenous line and then culturing the fluid and material flushed out of the catheter.

Blood cultures. Most investigators report that the diagnosis of *Malassezia* catheter-associated sepsis was made by recovering the organism in large numbers from blood cultures drawn through the infected catheter. We first isolated *M. furfur* from a blood culture drawn through a catheter after we had observed budding yeast cells on a "blind" Gram stain of the blood culture broth and subcultured the broth onto tryptic soybean digest agar with 5% sheep blood. The blood culture bottle (BACTEC 6B aerobic bottle; Becton Dickinson Diagnostic Instrument Systems, Sparks, Md.) did not show overt turbidity or other signs suggesting microbial growth; it was radiometrically negative. The organism produced only very tiny colonies on the agar surface until a few drops of olive oil were added. Subsequently, several isolates were detected radiometrically in BACTEC 6B aerobic bottles, but this has been an inconsistent finding. In some patients, lipids sufficient to support growth and allow radiometric detection are probably transferred from the patient's blood to the bottle. We studied the effect of various lipid sources, including Tween 80 and two commercial parenteral lipid emulsions, on radiometric detection and growth of *M. furfur* in BACTEC 6B bottles (89). Time to detection varied from 3 to 5 days depending on the lipid source and the size of the initial inoculum of *M. furfur*. Final colony counts in the bottles generally exceeded 10^6 CFU/ml. Although it may

FIG. 5. Photographs of *M. furfur* colonies growing on GYP-S agar after 5 days at 35°C. (A) Plate was inoculated with 0.3 ml of blood collected from a patient through a Broviac catheter and transported to the laboratory in a pediatric Isolator tube. (B) Plate showing *M. furfur* colonies recovered from 0.3 ml of blood collected via peripheral venipuncture from the same patient.

be tempting to supplement blood culture bottles with lipids in an attempt to recover *M. furfur*, this procedure may be associated with introducing contaminating organisms, and high lipid concentrations may inhibit growth of *Malassezia* spp. (88, 89).

We prefer the use of DuPont Isolator tubes (Wampole Laboratories, Cranbury, N.J.) as an adjunct procedure for collection of blood when *Malassezia* sepsis is suspected (88, 89). The catheter blood may be plated onto GYP-S agar, Sabaroud dextrose agar with olive oil overlay, or alternative media with lipid supplementation. Plates are inoculated at 35 to 37°C and held for 1 week. Most *Malassezia* isolates are detected after 2 to 4 days of incubation. As discussed above, peripheral blood cultures are much less likely to be positive for *Malassezia* spp. than are cultures of catheter blood. In a series of 10 patients with clinical sepsis and catheter blood cultures positive for *M. furfur*, we found that peripheral blood cultures were positive in only 4 patients (87). In all four cases, fewer than 100 CFU of *M. furfur* per ml were recovered from peripheral blood compared with >300 CFU/ml recovered from catheter blood (Fig. 5). Thus, recovery of large numbers of organisms from the catheter blood of a patient with a clinically consistent presentation and for whom other causes of sepsis have been ruled out is sufficient for diagnosis of *Malassezia* infection.

Catheter cultures. When catheter blood cultures yield *Malassezia* spp., it is prudent to remove the catheter as soon as possible. Although the diagnosis has already been made, we confirm the association of the organism with the catheter by culturing a 1-in. (2.54-cm) segment of the catheter tip on GYP-S by using the roll-streak method of Maki et al. (83). Plates are incubated at 35 to 37°C for 4 days. Although a lumen washout method (24) for catheter culture yields more organisms, suggesting that the luminal wall of the catheter is the predominant site of growth in the catheter, we have discontinued this procedure because it is time-consuming and unnecessary to confirm the association of *Malassezia* spp. with the catheter.

CONCLUSION

Malassezia spp. can now be added to a growing list of normal skin flora organisms of low virulence that may cause serious systemic infection in the susceptible host. Clinicians must be aware of the patient population at risk for infection, and they must communicate to the laboratory the need to include special procedures to recover the organism. Understanding the epidemiologic and pathogenic mechanisms of catheter-associated *Malassezia* sepsis in the neonate awaits the development of a suitable typing system to allow tracking of strains. The newer molecular methods for analyzing and comparing proteins and nucleic acids of individual strains should allow further understanding of these mechanisms.

ACKNOWLEDGMENTS

We thank the technical staff of the Children's Hospital Clinical Microbiology Laboratory for their past and continuing cooperative support in investigating new and interesting findings. We especially thank Jeffery Aungst, whose expertise and thoroughness in his approach to medical mycology led us to investigate the initial cases of catheter-associated *M. furfur* sepsis. We also thank Karen Jones and Nancy Denney for their excellent secretarial assistance in the preparation of the manuscript.

REFERENCES

1. Abou-Gabal, M., C. B. Chastain, and R. M. Hogle. 1979. *Pityrosporum (pachydermatis) canis* as a major cause of otitis externa in dogs. *Mykosen* **22**:192-199.
2. Abou-Gabal, M., and J. A. Fagerland. 1979. Electron microscopy of *Pityrosporum canis* "pachydermatis." *Mykosen* **22**: 85-90.
3. Abraham, Z., A. Berderly, and E. Lefler. 1987. *Pityrosporum orbiculare* in children. *Mykosen* **30**:581-583.
4. Allen, H. B., and C. R. Charles. 1976. Hyperpigmented tinea versicolor. *Arch. Dermatol.* **112**:1110-1112.
5. Alpert, G., L. M. Bell, and J. M. Campos. 1987. *Malassezia furfur* fungemia in infancy. *Clin. Pediatr.* **26**:528-531.
6. Arnow, P. M., and R. Kushner. 1991. *Malassezia furfur* catheter infection cured with antibiotic lock therapy. *Am. J. Med.* **90**:128-130.
7. Aschner, J. L., A. Punsalang, Jr., W. M. Maniscalco, and M. A. Menegus. 1987. Percutaneous central venous catheter colonization with *Malassezia furfur*: incidence and clinical significance. *Pediatrics* **80**:535-539.
8. Azimi, P. H., K. Levernier, L. M. Lefrak, A. M. Petru, T. Barrett, H. Schenck, A. S. Sandhu, G. Duritz, and M. Valesco. 1988. *Malassezia furfur*: a cause of occlusion of percutaneous central venous catheters in infants in the intensive care nursery. *Pediatr. Infect. Dis. J.* **7**:100-103.
9. Back, O., J. Faergemann, and R. Harquist. 1985. *Pityrosporum* folliculitis: a common disease of the young and middle-aged. *J. Am. Acad. Dermatol.* **12**:56-62.
10. Baillon, H. 1889. *Traité de botanique médicale cryptogamique*, p. 234-235, Octave Doin, Paris.
11. Belew, P. W., E. W. Rosenberg, and B. R. Jennings. 1980. Activation of the alternative pathway of complement by *Malassezia ovalis* (*Pityrosporum ovale*). *Mycopathologia* **70**: 187-191.
12. Bell, L. M., G. Alpert, P. H. Slight, and J. M. Campos. 1988. *Malassezia furfur* skin colonization in infancy. *Infect. Control Hosp. Epidemiol.* **9**:151-153.
13. Bertini, B., E. S. Kuttin, and A. M. Beemer. 1975. Cytopathology of nipple discharge due to *Pityrosporum orbiculare* and cocci in an elderly woman. *Acta Cytol.* **19**:38-42.
14. Bezjak, V., T. M. Al-Nakib, and R. Chandry. 1989. New oil-free media for *Malassezia furfur* (*Pityrosporum orbiculare*), abstr. F-51, p. 466. Abstr. 89th Annu. Meet. Am. Soc. Microbiol. 1989. American Society for Microbiology, Washington, D.C.
15. Breathnach, A. S., M. Nazzaro-Porro, and B. Martin. 1975. Ultrastructure of skin in pityriasis versicolor. *J. Ital. Dermatol.* **110**:457-469.
16. Broberg, A., and J. Faergemann. 1989. Infantile seborrheic dermatitis and *Pityrosporum ovale*. *Br. J. Dermatol.* **120**:359-362.
17. Brooks, R., and L. Brown. 1987. Systemic infection with *Malassezia furfur* in an adult receiving long-term hyperalimentation therapy. *J. Infect. Dis.* **156**:410-411. (Letter.)
18. Bruneau, S. M., and R. M. F. Guinet. 1983. Quantitative immunoelectrophoretic study of genus *Pityrosporum* Sabouraud. *Mykosen* **27**:123-136.
19. Bufill, J. A., L. G. Lum, J. G. Caya, C. R. Chitambar, P. S. Ritch, T. Anderson, and R. Ash. 1988. *Pityrosporum* folliculitis after bone marrow transplantation. Clinical observations in five patients. *Ann. Intern. Med.* **108**:560-563.
20. Burke, R. C. 1961. Tinea versicolor: susceptibility factors and experimental infection in human beings. *J. Invest. Dermatol.* **36**:389-401.
21. Castellani, A., and A. J. Chalmers. 1913. *Manual of tropical medicine*, 2nd ed., p. 1747. Bailliére, Tindall, and Cox, London.
22. Charles, C. R., D. J. Sire, B. L. Johnson, and J. G. Beidles. 1973. Hypopigmentation in tinea versicolor; a histological and microscopic study. *Int. J. Dermatol.* **12**:48-58.
23. Chengappa, M. M., R. L. Maddus, and S. C. Greer. 1983. A microbiologic survey of clinically normal and otitic canine ear canals. *Vet. Med. Small Anim. Clin.* **78**:343-344.
24. Cleri, D. J., M. L. Corrado, and S. L. Seligman. 1980.

- Quantitative culture of intravenous catheters and other intravascular inserts. *J. Infect. Dis.* **141**:781-786.
25. Cunningham, A. C., J. P. Jeeming, E. Ingham, and G. Gowland. 1990. Differentiation of three serovars of *Malassezia furfur*. *J. Appl. Bacteriol.* **68**:439-446.
 26. DaMert, G. J., C. H. Kirkpatrick, and P. G. Sohnle. 1980. Comparison of antibody responses in chronic mucocutaneous candidiasis and tinea versicolor. *Int. Arch. Allergy Appl. Immunol.* **63**:97-104.
 27. Dankner, W. M., S. A. Spector, J. Fierer, and C. E. Davis. 1987. *Malassezia* fungemia in neonates and adults: complication of hyperalimentation. *Rev. Infect. Dis.* **9**:743-753.
 28. DiSilverio, A., M. Mosca, G. Brandozzi, and M. Gatti. 1989. Pityriasis versicolor in the aged: a clinical investigation and epidemiological survey in 190 elderly hospitalized patients. *Mycopathologia* **105**:187-190.
 29. Dorn, M., and K. Roehnert. 1977. Dimorphism of *Pityrosporum orbiculare* in defined culture medium. *J. Invest. Dermatol.* **69**:244-248.
 30. Drouhet, E., D. Domp martin, A. Papachristou-Moriati, and P. Ravisse. 1980. Dermatitis expérimentale à *Pityrosporum ovale* et(ou) *Pityrosporum orbiculare* chez le cobaye et la souris. *Sabouraudia* **18**:149-156.
 31. DuPont, B. 1990. Fungal infection and AIDS, p. 421-437. In J. F. Riley (ed.), *Chemotherapy of fungal diseases. Handbook of experimental pharmacology*, vol. 96. Springer-Verlag, New York.
 32. Eichstedt, C. 1846. Pilzbildung in der Pityriasis versicolor. *Neue Notizen aus dem Gebiete der Natur-und Heilkunde. Froriep's Notizen Ser.* **2**,39(853):270-271.
 33. Eisenstat, B. A., and G. P. Wormser. 1984. Seborrheic dermatitis and butterfly rash in AIDS. *N. Engl. J. Med.* **311**:189. (Letter.)
 34. Faergemann, J. 1979. Experimental tinea versicolor in rabbits and humans with *Pityrosporum orbiculare*. *J. Invest. Dermatol.* **72**:326-329.
 35. Faergemann, J. 1983. Antibodies to *Pityrosporum orbiculare* in patients with tinea versicolor and controls of various ages. *J. Invest. Dermatol.* **80**:133-135.
 36. Faergemann, J. 1984. Quantitative culture of *Pityrosporum orbiculare*. *Int. J. Dermatol.* **23**:330-333.
 37. Faergemann, J. 1984. In vitro and in vivo activities of ketoconazole and itraconazole against *Pityrosporum orbiculare*. *Antimicrob. Agents Chemother.* **26**:773-774.
 38. Faergemann, J. 1987. The use of contact plates for quantitative culture of *Pityrosporum orbiculare*. *Mykosen* **30**:298-304.
 39. Faergemann, J. 1989. Epidemiology and ecology of pityriasis versicolor. *Curr. Top. Med. Mycol.* **3**:153-167.
 40. Faergemann, J. 1990. Treatment of seborrheic dermatitis of the scalp with ketoconazole shampoo. A double-blind study. *Acta Derm. Venereol.* **70**:171-172.
 41. Faergemann, J., R. Aly, and H. I. Maibach. 1983. Adherence of *Pityrosporum orbiculare* to human stratum corneum cells. *Arch. Dermatol. Res.* **275**:246-250.
 42. Faergemann, J., R. Aly, and H. I. Maibach. 1983. Quantitative variations in distribution of *Pityrosporum orbiculare* on clinically normal skin. *Acta Derm. Venereol.* **63**:346-348.
 43. Faergemann, J., R. Aly, and H. I. Maibach. 1983. Growth and filament production of *Pityrosporum orbiculare* and *Pityrosporum ovale* on human stratum corneum in vitro. *Acta Derm. Venereol.* **63**:388-392.
 44. Faergemann, J., R. Aly, D. R. Wilson, and H. I. Maibach. 1983. Skin occlusion: effect on *Pityrosporum orbiculare*, skin pCO₂, pH, transepidermal water loss, and water content. *Arch. Dermatol. Res.* **275**:383-387.
 45. Faergemann, J., and S. Bernander. 1979. The activity in vitro of five different antimycotics against *Pityrosporum orbiculare*. *Acta Derm. Venereol.* **59**:521-524.
 46. Faergemann, J., and S. Bernander. 1981. Microaerophilic and anaerobic growth of *Pityrosporum* sp. *Sabouraudia* **19**:117-121.
 47. Faergemann, J., and T. Fredriksson. 1980. Age incidence of *Pityrosporum orbiculare* on human skin. *Acta Derm. Venereol.* **60**:531-533.
 48. Faergemann, J., and T. Fredriksson. 1981. Experimental infections in rabbits and humans with *Pityrosporum orbiculare* and *Pityrosporum ovale*. *J. Invest. Dermatol.* **77**:314-318.
 49. Faergemann, J., and H. I. Maibach. 1984. The *Pityrosporum* yeasts: their role as pathogens. *Int. J. Dermatol.* **23**:463-465.
 50. Faergemann, J., U. Tjernlund, A. Scheynuis, and S. Bernander. 1982. Antigenic similarities and differences in genus *Pityrosporum*. *J. Invest. Dermatol.* **78**:28-31.
 51. Ford, G. 1984. *Pityrosporum* folliculitis. *Int. J. Dermatol.* **23**:320-321.
 52. Ford, G. P., P. M. Farr, F. A. Ive, and S. Shuster. 1984. The response of seborrheic dermatitis to ketoconazole. *Br. J. Dermatol.* **111**:603-607.
 53. Ford, G. P., F. A. Ive, and G. Midgley. 1982. *Pityrosporum folliculitis* and ketoconazole. *Br. J. Dermatol.* **107**:691-695.
 54. Furukawa, F., K. Dunno, S. Imamura, and Y. Soh. 1981. Histological and serological studies of *Pityrosporum orbiculare* in cases of pityriasis versicolor. *J. Dermatol.* **8**:27-30.
 55. Garcia, C. R., B. L. Johnston, G. Corvi, L. J. Walker, and W. L. George. 1987. Intravenous catheter-associated *Malassezia furfur* fungemia. *Am. J. Med.* **83**:790-792.
 56. Gidding, H., L. Hawes, and B. Dwyer. 1989. The isolation of *Malassezia furfur* from an episode of peritonitis. *Med. J. Aust.* **151**:603. (Letter.)
 57. Gordon, M. A. 1951. Lipophilic yeast-like organisms associated with tinea versicolor. *J. Invest. Dermatol.* **17**:267.
 58. Gordon, M. A. 1951. The lipophilic microflora of skin: in vitro culture of *Pityrosporum orbiculare*. *Mycologia* **43**:524-535.
 59. Groisser, D., E. J. Bottone, and M. Lebowitz. 1989. Association of *Pityrosporum orbiculare* (*Malassezia furfur*) with seborrheic dermatitis in patients with acquired immunodeficiency syndrome (AIDS). *J. Am. Acad. Dermatol.* **20**:770-773.
 60. Guého, E., and S. A. Meyer. 1989. A reevaluation of the genus *Malassezia* by means of genome comparison. *Antonie van Leeuwenhoek* **55**:245-251.
 61. Guého, E., R. B. Simmons, W. R. Pruitt, S. A. Meyer, and D. G. Ahearn. 1987. Association of *Malassezia pachydermatis* with systemic infections of humans. *J. Clin. Microbiol.* **25**:1789-1790.
 62. Håkansson, C., J. Faergemann, and G. B. Lowhagen. 1988. Studies on the lipophilic yeast *Pityrosporum ovale* in HIV-seropositive and HIV-seronegative homosexual men. *Acta Derm. Venereol.* **68**:422-426.
 63. Hassall, E., T. Ulich, and M. Ament. 1983. Pulmonary embolus and *Malassezia* pulmonary infection related to urokinase therapy. *J. Pediatr.* **102**:722-725.
 64. Heng, M. C., C. L. Henderson, D. C. Barker, and G. Haberkfeld. 1990. Correlation of *Pityrosporum ovale* density with clinical severity of seborrheic dermatitis as assessed by a simplified technique. *J. Am. Acad. Dermatol.* **23**:82-86.
 65. Heymann, W. R., and D. J. Wolf. 1986. *Malassezia* (*Pityrosporum*) folliculitis occurring during pregnancy. *Int. J. Dermatol.* **25**:49-51.
 66. Hill, M. K., M. J. Goodfield, F. G. Rodgers, J. L. Crowley, and E. M. Saihan. 1990. Skin surface electron microscopy in *Pityrosporum folliculitis*. The role of follicular occlusion in disease and the response to oral ketoconazole. *Arch. Dermatol.* **126**:1071-1074.
 67. Hjorth, N., and O. J. Clemmensen. 1983. Treatment of dermatitis of the head and neck with ketoconazole in patients with type I hypersensitivity for *Pityrosporum orbiculare*. *Semin. Dermatol.* **2**:26-29.
 68. Hurwitz, S. 1981. Skin disorders due to fungi, p. 287-288. In S. Hurwitz (ed.), *Clinical pediatric dermatology*. The W. B. Saunders Co., Philadelphia.
 69. Imwidthaya, S., and M. Thianprasit. 1988. *Malassezia furfur* in dermatological patients and clinically normal persons. *J. Med. Assoc. Thai.* **71**:145-149.
 70. Johansson, S., and J. Faergemann. 1990. Enzyme linked immunosorbent assay (ELISA) for detection of antibodies against *Pityrosporum orbiculare* in cases of pityriasis versicolor. *J. Med. Vet. Mycol.* **28**:257-260.
 71. Katoh, T., S. Kagawa, and M. Ishimoto. 1988. *Malassezia*

- intertrigo, a new clinical entity. *Mycoses* 31:558-562.
72. **Keddie, F. M., and S. Shadomy.** 1963. Etiological significance of *Pityrosporum orbiculare* in tinea versicolor. *Sabouraudia* 3:21-25.
 73. **Kikuchi, I., K. Ogata, and S. Inoue.** 1984. *Pityrosporum* infection in an infant with lesions resembling erythema annulare centrifugum. *Arch. Dermatol.* 120:380-382.
 74. **Klotz, S. A.** 1989. *Malassezia furfur*. *Infect. Dis. Clin. North Am.* 3:53-64.
 75. **Klotz, S. A., D. J. Drutz, M. Huppert, and J. E. Johnson.** 1982. *Pityrosporum* folliculitis: its potential for confusion with skin lesions of systemic candidiasis. *Arch. Intern. Med.* 142:2126-2129.
 76. **Koronda, F. C., E. M. Dehmel, G. Kahn, and I. Penn.** 1974. Cutaneous complications in immunosuppressed renal homograft recipients. *JAMA* 229:19-24.
 77. **Larocco, M., A. Dorenbaum, A. Robinson, and L. K. Pickering.** 1988. Recovery of *Malassezia pachydermatis* from eight infants in a neonatal intensive care nursery: clinical and laboratory features. *Pediatr. Infect. Dis. J.* 7:398-401.
 78. **Leeming, J. P., K. T. Holland, and W. J. Cundiff.** 1984. Microbial ecology of pilosebaceous units isolated from human skin. *J. Gen. Microbiol.* 130:803-807.
 79. **Leeming, J. P., and F. H. Notman.** 1987. Improved methods for isolation and enumeration of *Malassezia furfur* from human skin. *J. Clin. Microbiol.* 25:2017-2019.
 80. **Leeming, J. P., F. H. Notman, and K. T. Holland.** 1989. The distribution and ecology of *Malassezia furfur* and cutaneous bacteria on human skin. *J. Appl. Bacteriol.* 67:47-52.
 81. **Linarez, J., A. Sitges-Serra, J. Garau, J. Perez, and R. Martin.** 1985. Pathogenesis of catheter sepsis: a prospective study with quantitative and semi-quantitative cultures of catheter hub and segments. *J. Clin. Microbiol.* 21:357-362.
 82. **Long, J. G., and H. L. Keyserling.** 1985. Catheter-related infection in infants due to an unusual lipophilic yeast—*Malassezia furfur*. *Pediatrics* 76:896-900.
 83. **Maki, D. G., C. E. Weise, and H. W. Sarafin.** 1977. A semiquantitative culture method for identifying intravascular catheter-related infection. *N. Engl. J. Med.* 296:1305-1309.
 84. **Malassez, L.** 1874. Note sur le champignon du pityriasis simplex. *Arch. Physiol. Norm. Pathol. (Ser. 2)* 1:451-464.
 85. **Marcon, M. J.** Unpublished data.
 86. **Marcon, M. J., D. E. Durrell, D. A. Powell, and W. J. Buesching.** 1987. In vitro activity of systemic antifungal agents against *Malassezia furfur*. *Antimicrob. Agents Chemother.* 31:951-953.
 87. **Marcon, M. J., and D. A. Powell.** 1987. Epidemiology, diagnosis, and management of *Malassezia furfur* systemic infection. *Diagn. Microbiol. Infect. Dis.* 7:161-175.
 88. **Marcon, M. J., and D. A. Powell.** 1988. *Malassezia furfur*. *Clin. Microbiol. Newsl.* 10:41-45.
 89. **Marcon, M. J., D. A. Powell, and D. E. Durrell.** 1986. Methods for optimal recovery of *Malassezia furfur* from blood culture. *J. Clin. Microbiol.* 24:696-700.
 90. **Mathes, B. H., and M. C. Douglas.** 1985. Seborrheic dermatitis in patients with acquired immunodeficiency syndrome. *J. Am. Acad. Dermatol.* 13:947-951.
 91. **McGinnis, M.** 1980. *Laboratory handbook of medical mycology*, p. 393-394. Academic Press, Inc., New York.
 92. **Mickelsen, P. A., M. C. Viano-Paulson, D. A. Stevens, and P. S. Diaz.** 1988. Clinical and microbiological features of infection with *Malassezia pachydermatis* in high-risk infants. *J. Infect. Dis.* 157:1163-1168.
 93. **Middleton, C., and R. M. Lowenthal.** 1987. *Malassezia furfur* fungemia as a treatable cause of obscure fever in a leukemia patient receiving parenteral nutrition. *Aust. N. Z. J. Med.* 17:603-604.
 94. **Midgley, G.** 1985. Comparison of *Pityrosporum (Malassezia)* isolates by morphology and immunoelectrophoresis. *Br. J. Dermatol.* 113:783-784.
 95. **Midgley, G.** 1989. The diversity of *Pityrosporum (Malassezia)* yeasts *in vivo* and *in vitro*. *Mycopathologia* 106:143-153.
 96. **Moore, R. T.** 1980. Taxonomic proposals for classification of marine yeasts and other yeast-like fungi including the smuts. *Bot. Mar.* 23:361-373.
 97. **Nanda, A., S. Kaur, O. N. Bhakoo, I. Kaur, and C. Vaishnavi.** 1988. Pityriasis (tinea) versicolor in infancy. *Pediatr. Dermatol.* 5:260-262.
 98. **Nazzaro-Porro, M., and S. Passi.** 1978. Identification of tyrosinase inhibitors in cultures of *Pityrosporum*. *J. Invest. Dermatol.* 71:205-208.
 99. **Nazzaro-Porro, M., S. Passi, F. Caprilli, and R. Mercantini.** 1977. Induction of hyphae in cultures of *Pityrosporum* by cholesterol and cholesterol esters. *J. Invest. Dermatol.* 69:531-534.
 100. **Nazzaro-Porro, M., S. Passi, F. Caprilli, P. Nazzaro, and G. Morphogo.** 1976. Growth requirements and lipid metabolism of *Pityrosporum orbiculare*. *J. Invest. Dermatol.* 66:178-182.
 101. **Noble, W. C., and G. Midgley.** 1978. Scalp carriage of *Pityrosporum* species: the effect of physiological maturity, sex, and race. *Sabouraudia* 16:229-232.
 102. **Nordvall, S. L., and S. Johansson.** 1990. IgE antibodies to *Pityrosporum orbiculare* in children with atopic diseases. *Acta Paediatr. Scand.* 79:343-348.
 103. **Nowak, J. A., V. A. Ruppert, and M. A. Menegus.** 1985. *Pityrosporum ovale* colonization of a Hickman catheter, abstr. C-348, p. 358. Abstr. 85th Annu. Meet. Am. Soc. Microbiol. 1985. American Society for Microbiology, Washington, D.C.
 104. **Oberle, A. D., M. Fowler, and W. D. Grafton.** 1981. *Pityrosporum* isolate from the upper respiratory tract. *Am. J. Clin. Pathol.* 76:112.
 105. **Potter, B., C. F. Burgoon, and S. C. Johnson.** 1973. *Pityrosporum* folliculitis. Report of seven cases and review of the *Pityrosporum* organism relative to cutaneous disease. *Arch. Dermatol.* 107:388-391.
 106. **Powell, D. A., J. Aungst, S. Snedden, N. Hansen, and M. Brady.** 1984. Broviac catheter-related *Malassezia furfur* sepsis in five infants receiving intravenous fat emulsions. *J. Pediatr.* 105:987-990.
 107. **Powell, D. A., J. Hayes, D. E. Durrell, M. Miller, and M. J. Marcon.** 1987. *Malassezia furfur* skin colonization of infants hospitalized in intensive care units. *J. Pediatr.* 111:217-220.
 108. **Powell, D. A., and M. J. Marcon.** 1987. Failure to eradicate *Malassezia furfur* broviac catheter infection with antifungal therapy. *Pediatr. Infect. Dis. J.* 6:579-580.
 109. **Powell, D. A., M. J. Marcon, D. E. Durrell, and R. M. Pfister.** 1987. Scanning electron microscopy of *Malassezia furfur* attachment to Broviac catheters. *Hum. Pathol.* 18:740-745.
 110. **Prober, C. G., and S. H. Ein.** 1984. Systemic tinea versicolor, or how far can furfur go. *Pediatr. Infect. Dis.* 6:592.
 111. **Ranjanidiche, M.** 1976. Polymorphism of *Pityrosporum ovale* (Bizzozero) Castellani and Chalmers *in vivo* and *in vitro*. *Bull. Soc. Fr. Mycol. Med.* 5:79-82.
 112. **Redline, R. W., and B. B. Dahms.** 1981. *Malassezia* pulmonary vasculitis in an infant on long-term intralipid therapy. *N. Engl. J. Med.* 305:1395-1398.
 113. **Redline, R. W., S. S. Redline, B. Boxerbaum, and B. B. Dahms.** 1985. Systemic *Malassezia furfur* infections in patients receiving intralipid therapy. *Hum. Pathol.* 16:815-822.
 114. **Richet, H. M., M. M. McNeil, M. C. Edwards, and W. R. Jarvis.** 1989. Cluster of *Malassezia furfur* pulmonary infections in infants in a neonatal intensive-care unit. *J. Clin. Microbiol.* 27:1197-1200.
 115. **Rippon, J. W.** 1982. *Medical mycology—the pathogenic fungi and the pathogenic actinomycetes*, 2nd ed., p. 140-145. The W. B. Saunders Co., Philadelphia.
 116. **Rivolta, S.** 1873. Dei parassiti vegetali come introduzione allo studio delle malattie parassitarie e delle alterazioni dell'alimento degli animali domestica. Torino, Italy.
 117. **Roberts, S. O. B.** 1969. *Pityrosporum orbiculare*: incidence and distribution on clinically normal skin. *Br. J. Dermatol.* 81:264-269.
 118. **Robin, C.** 1853. *Historie naturelle des végétaux parasites qui croissent sur l'homme et sur les animaux vivants*, p. 436-439. Ballière, Paris.
 119. **Rokugo, M., H. Tagami, Y. Usuba, and Y. Tomita.** 1990.

- Contact sensitivity to *Pityrosporum ovale* in patients with atopic dermatitis. Arch. Dermatol. **126**:627-632.
120. Romano, A., E. Segal, and M. Blumenthal. 1978. Canaliculitis with isolation of *Pityrosporum pachydermatis*. Br. J. Ophthalmol. **62**:732-734.
 121. Rosenberg, E. W., and P. W. Belew. 1982. Improvement of psoriasis of the scalp with ketoconazole. Arch. Dermatol. **118**:370-371.
 122. Rotrosen, D., R. A. Calderone, and J. E. Edwards. 1986. Adherence of *Candida* sp. to host tissues and plastic surfaces. Rev. Infect. Dis. **8**:73-85.
 123. Ruiz, M. R., M. R. Lopez, E. L. Perez-Chavarría, C. L. Rocio, and L. Tamayo. 1989. *Pityrosporum ovale* in infantile seborrheic dermatitis. Pediatr. Dermatol. **6**:16-20.
 124. Sabouraud, R. 1904. Maladies due cuir chavelu. II. Les maladies desquamatoires pityriasis et alopecies pellicularis. Masson et cie, Paris.
 125. Salkin, I., and M. A. Gordon. 1977. Polymorphism of *Malassezia furfur*. Can. J. Microbiol. **23**:471-475.
 126. Sanguinetti, M. P., P. Tampieri, and L. Morganti. 1984. A survey of 120 isolates of *Malassezia (Pityrosporum) pachydermatis*. Mycopathologia **85**:93-95.
 127. Scheynius, A., J. Faergemann, U. Forsum, and O. Sjöberg. 1984. Phenotypic characterization in situ of inflammatory cells in pityriasis (tinea) versicolor. Acta Derm. Venereol. **64**:473-479.
 128. Shek, Y. H., M. C. Tucker, A. L. Viciano, H. J. Manz, and D. H. Connor. 1989. *Malassezia furfur* disseminated infection in premature infants. Am. J. Clin. Pathol. **92**:595-603.
 129. Shifrine, M., and A. G. Marr. 1963. The requirement of fatty acids by *Pityrosporum ovale*. J. Gen. Microbiol. **32**:263-270.
 130. Simmons, R. B., and D. G. Ahern. 1987. Cell wall ultrastructure and Diazonium Blue B reaction of *Sporopachydermia quercuum*, *Bullera tsugae*, and *Malassezia* spp. Mycologia **79**:38-43.
 131. Simmons, R. B., and E. Guého. 1990. A new species of *Malassezia*. Mycol. Res. **94**:1146-1149.
 132. Slooff, W. C. 1971. Genus 6. *Pityrosporum* Sabouraud, p. 1167-1186. In J. Lodder (ed.), The yeasts—a taxonomic study, 2nd ed. North-Holland Publishing Co., Amsterdam.
 133. Sohnle, P. G. 1988. *Pityrosporum* immunology—a review, p. 64-69. In J. Torres-Rodriguez (ed.), Proceedings of the X Congress of the International Society for Human and Animal Mycology. J. R. Prous Science, Barcelona.
 134. Sohnle, P. G., and C. Collins-Lech. 1978. Cell-mediated immunity to *Pityrosporum orbiculare* in tinea versicolor. J. Clin. Invest. **62**:45-53.
 135. Sohnle, P. G., and C. Collins-Lech. 1982. Analysis of the lymphocyte transformation response to *Pityrosporum orbiculare* in patients with tinea versicolor. Clin. Exp. Immunol. **49**:559-564.
 136. Sohnle, P. G., and C. Collins-Lech. 1983. Activation of complement by *Pityrosporum orbiculare*. J. Invest. Dermatol. **80**:93-97.
 137. Sohnle, P. G., C. Collins-Lech, and K. E. Huhta. 1983. Class-specific antibodies in young and aged humans against organisms producing superficial fungal infections. Br. J. Dermatol. **108**:69-76.
 138. Surmont, I., A. Gavilanes, J. Vandepitte, H. Devlieger, and E. Eggermont. 1989. *Malassezia furfur* fungaemia in infants receiving intravenous lipid emulsions. A rarity or just underestimated? Eur. J. Pediatr. **148**:435-438.
 139. Svejgaard, E., J. Faergemann, G. Jemec, M. Kieffer, and V. Ottevanger. 1989. Recent investigations on the relationship between fungal skin diseases and atopic dermatitis. Acta Derm. Venereol. Suppl. **144**:140-142.
 140. Takahashi, M., T. Ushijima, and Y. Ozaki. 1981. Comparative studies on biological and serological characteristics of each species *Pityrosporum*. Jpn. J. Med. Mycol. **22**:314-321.
 141. Takeo, K., and E. Nakai. 1986. Mode of cell growth of *Malassezia (Pityrosporum)* as revealed by using plasma membrane configuration as natural markers. Can. J. Microbiol. **32**:389-394.
 142. Tanaka, M., and S. Imamura. 1979. Immunological studies on *Pityrosporum* genus and *Malassezia furfur*. J. Invest. Dermatol. **73**:321-324.
 143. Wallace, M., H. Bagnall, D. Glenn, and S. Averill. 1979. Isolation of lipophilic yeasts in "sterile" peritonitis. Lancet **ii**:956.
 144. Weary, P. E. 1968. *Pityrosporum ovale*. Arch. Dermatol. **98**:408-422.
 145. Weidman, F. D. 1925. Exfoliative dermatitis in the Indian rhinoceros (*Rhinoceros unicornis*) with description of a new yeast species, *Pityrosporum pachydermatis*, p. 36-44. In H. Fox (ed.), Report of the laboratory and museum of comparative pathology of the Zoological Society of Philadelphia. Zoological Society of Philadelphia, Philadelphia.
 146. Wilde, P. F., and P. S. Stewart. 1968. A study of the fatty acid metabolism of the yeast *Pityrosporum ovale*. Biochem. J. **108**:225-231.
 147. Winkler, J. R., P. deHann, and C. Nieboer. 1988. The "tape method": a new and simple method for quantitative culture of *Pityrosporum* yeasts. Acta Derm. Venereol. **68**:445-449.
 148. Wolter, J. R. 1977. *Pityrosporum* species associated with dacryoliths in obstructive macrocystitis. Am. J. Ophthalmol. **84**:806-809.
 149. Wu, Y. C., and K. T. Chen. 1985. Humoral immunity in patients with tinea versicolor. J. Dermatol. **12**:161-166.
 150. Wurtz, R. M., and W. N. Knosp. 1989. *Malassezia furfur* fungemia in a patient without the usual risk factors. Ann. Intern. Med. **109**:432-433.
 151. Yarrow, D., and D. G. Ahern. 1984. Genus 7. *Malassezia* Baillon, p. 882-885. In N. J. W. Kreger-van Rij (ed.), The yeasts—a taxonomic study, 3rd ed. Elsevier Science Publishing Co., Amsterdam.
 152. Yohn, J. J., J. Lucas, and C. Camisa. 1985. *Malassezia* folliculitis in immunocompromised patients. Cutis **35**:536-538.