

A Case of Anisakidosis Caused by *Pseudoterranova decipiens* Larva

Hak Kyun Na¹, Min Seo², Jong-Yil Chai³, Eun Kyoung Lee⁴ and Soung Min Jeon^{4,*}

¹Department of Laboratory Medicine, Dankook University Hospital, Cheonan 330-715, Korea; ²Department of Parasitology, College of Medicine, Dankook University and Research Center for Mummy, Cheonan 330-714, Korea; ³Department of Parasitology and Tropical Medicine, Seoul National University College of Medicine, Seoul 110-799, Korea; ⁴Department of Internal Medicine, College of Medicine, Dankook University, Cheonan 330-714, Korea

Abstract: *Pseudoterranova decipiens* larva is a rare cause of anisakiasis. Indeed, prior to the present study, there had been only 12 reports of larval *P. decipiens* infection in the Republic of Korea. In June 2011, an anisakid larva, 32.1 mm in length and 0.88 mm in width, and finally identified as the third stage larva of *P. decipiens* owing to the presence of an intestinal cecum but lacking ventricular appendage, was discovered in a 61-year-old woman during the course of endoscopy executed as a part of routine physical examinations. The patient had eaten raw a rockfish 13 hr prior to the endoscopy, but showed no symptoms of anisakiasis. This paper is the 13th report of *P. decipiens* infection in Korea.

Key words: *Pseudoterranova decipiens*, anisakiasis, endoscopy, rockfish

INTRODUCTION

Anisakiasis, a well-known disease occurring in humans, is caused by ingestion of anisakid larvae in dishes with raw marine fish and squids. Post-consumption, the third stage larvae can penetrate the stomach and intestinal walls, leading to such symptoms as stomach pain, fever, diarrhea, vomiting, or even, in cases of multiple infection, mental stupor [1,2]. Also, recently anisakid larvae have been implicated as a possible causative food allergen in adult patients presenting with urticaria, angioedema, anaphylaxis, and other maladies [3].

Most cases of human anisakiasis have been traced to the genus *Anisakis*, and the genus *Pseudoterranova* is the second most common anisakid found in humans [1]. The Republic of Korea has a longstanding tradition of raw fish consumption, and so it is not surprising that numerous Korean patients have been diagnosed with anisakiasis, most of those cases being *Anisakis simplex* [4]. As for *Pseudoterranova*, however, there have been only 12 confirmed cases in Korea [5]. In this paper, we report a case of human infection by *P. decipiens* larva, discovered in a

routine physical examination.

CASE RECORD

In June 2011, an anisakid larva was discovered in a 61-year-old woman during the course of endoscopy executed at Dankook University Hospital (Fig. 1). The laboratory findings were within the normal limits, except for a mild elevation of the eosinophil count (5.3%). She was living in Cheonan city, Chungcheongnam-do, and on an evening about 13 hr prior to her endoscopy, ate a rockfish (*Sebastes* sp.). The larva was immediately fixed in 10% formalin, and transferred to the Department of Parasitology, College of Medicine, Dankook University. It was cleaned in glycerin-alcohol, mounted with glycerin-jelly and observed under a light microscope. The larva was 32.1 mm in length and 0.88 mm in width. The mouth was surrounded by 3 lips, and the boring tooth was present. The esophagus was 2.4 mm in length, and was composed of long muscular and short ventricular parts.

The intestinal cecum, confirmed by section of the anterior part of the worm, was 1.1 mm in length, stretching to the middle level of the ventriculus. The tail, 0.20 mm in length, was conical with a terminal mucron. The presence of an intestinal cecum without ventricular appendage was easily observed in the transverse section of the worm (Fig. 2). All of these findings readily identified the specimen as a third stage larva of

•Received 16 September 2012, revised 19 November 2012, accepted 27 November 2012.

*Corresponding author (davidsmj@hanmail.net)

© 2013, Korean Society for Parasitology and Tropical Medicine

This is an Open Access article distributed under the terms of the Creative Commons Attribution Non-Commercial License (<http://creativecommons.org/licenses/by-nc/3.0>) which permits unrestricted non-commercial use, distribution, and reproduction in any medium, provided the original work is properly cited.

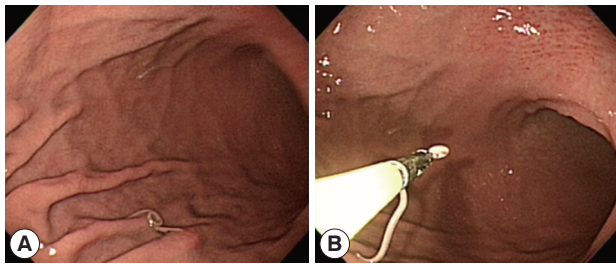


Fig. 1. Endoscopic findings of the patient. (A) A whitish worm is identified in the gastric mucosa. (B) The worm is being removed from the stomach using a biopsy forcep.

Pseudoterranova decipiens. After removal of the larva, the patient returned home and followed up uneventfully.

DISCUSSION

As already noted, this case of *P. decipiens* infection is the 13th discovered in Korea. Since *Anisakis* type I larvae have been implicated in most cases of human anisakiasis in Korea, other anisakid larvae such as *Pseudoterranova* and *Contracaecum* frequently have been overlooked [6]. In fact, human infections with *Pseudoterranova* spp. is far from rare in northern Japan, amounting to 769 cases by the mid-1990s [7] and 7 cases of *P. decipiens* have occurred in Chile [8,9]. Recently, *P. decipiens* was classified, by the molecular method, into 5 sibling species, i.e., *P. decipiens* sensu stricto, *P. azarasi*, *P. cattani*, *P. krabbei*, and *P. bulbosa* [10]. Unfortunately, whereas multiple infections of anisakid larvae are possible [2], most patients have been singly infected, which fact has hindered application of the molecular technique, as in the present case. Although molecular identification often is unavailable, comprehensive and detailed understanding of anisakid fauna can be attained through morphology-based genus-level identification.

The most important structure of anisakid larvae in species identification is their esophagointestinal morphologies with the corresponding measurements. *Anisakis* spp. larvae have a simple and straight arranged digestive tract, i.e., muscular esophagus, ventriculus, and intestine. On the other hand, in *Pseudoterranova* spp. larvae, the presence of an intestinal cecum without ventricular appendage is the key to distinguish from *Contracaecum* spp. larvae [5]. The present worm could be diagnosed as a third stage larva in consideration of the fact that the cecum reached beyond the one-third level of the ventriculus anteriorly, along with the presence of a mucron at the posterior end [5].

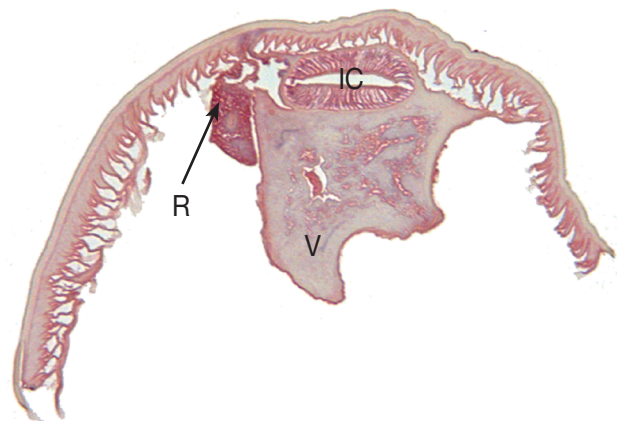


Fig. 2. Transverse section of the *P. decipiens* larva. Note that the intestinal cecum (IC), ventriculus (V), and renette cell (R) are seen.

Curiously, the patient whose case prompted this study did not complain of any symptoms arising from *P. decipiens* infection, that can include allergic symptoms. Most Japanese patients with *Pseudoterranova* spp. had acute or subacute abdominal pain [9], and Korean patients have complained of epigastric pain [3,5,11]. However, *P. decipiens* larvae, as seen in a Chilean case [8], can be expelled from the mouth in the absence of gastric symptoms. The sensation of a foreign body between the teeth has been the chief complaint of some infected patients [12]. Finally, it has been suggested that *P. decipiens* larvae are less invasive than *A. simplex* [8], though it should be noted that the varied symptoms of *P. decipiens* may result from different responses of individual hosts or different pathogenicity of *Pseudoterranova* spp.

Although *Pseudoterranova* spp. larvae exist in very small numbers compared with other *Anisakis* spp., they have been traced to more than 30 marine fish species such as cod, pollock, halibut, and flatfish worldwide [13]. However, they have never been recovered from host fish caught in Korea. For example, the larvae recovered from the yellow corvina (*Pseudosciaena manchurica*), have been *Anisakis simplex* (80.4%), *Contracaecum* spp. (15.5%), and other unidentifiable species (3.9%) [14]. Nonetheless, total 13 cases of *P. decipiens* infection, including the present case have been diagnosed in Korea. This reflects the fact that *P. decipiens* larvae must be distributed in fish hosts caught in Korea. Certainly in Korea, where raw seafood, as already noted, is a popular feature of the cuisine, human infection resulting from ingestion of *P. decipiens* larvae, which reside primarily in fish muscle [15], could be discovered much more. Further studies on *Pseudoterranova* spp. infection, its distribu-

tion and epidemiology, along with molecular examinations of *Pseudoterranova* larva, are required.

REFERENCES

1. Chai JY, Murrell KD, Lymbery A. Fish-borne parasitic zoonoses: status and issues. *Int J Parasitol* 2005; 35: 1233-1254.
2. Noh JH, Kim BJ, Kim SM, Ock MS, Park MI, Goo JY. A case of acute gastric anisakiasis provoking severe clinical problems by multiple infection. *Korean J Parasitol* 2003; 41: 97-100.
3. Choi SJ, Lee JC, Kim MJ, Hur GY, Shin SY, Park HS. The clinical characteristics of *Anisakis* allergy in Korea. *Korean J Intern Med* 2009; 24: 160-163.
4. Im KI, Shin HJ, Kim BH, Moon SI. Gastric anisakiasis cases in Cheju-do, Korea. *Korean J Parasitol* 1995; 33: 179-186.
5. Yu JR, Seo M, Kim YW, Oh MH, Sohn WM. A human case of gastric infection by *Pseudoterranova decipiens* larva. *Korean J Parasitol* 2001; 39: 193-196.
6. Seol SY, Ok SC, Pyo JS, Kim IH, Lee SH, Chung JM, Choi HJ, Jung SJ, Sohn WM. Twenty cases of gastric anisakiasis caused by *Anisakis* type I larva. *Korean J Gastroenterol* 1994; 26: 17-24.
7. Ishikura H. Anisakiasis. 2. Clinical pathology and epidemiology. *Prog Med Parasitol Japan* 2003; 8: 451-473.
8. Mercado R, Torres P, Muñoz V, Apt W. Human infection by *Pseudoterranova decipiens* (Nematoda, Anisakidae) in Chile: report of seven cases. *Mem Inst Oswaldo Cruz* 2001; 96: 653-655.
9. Arizono N, Miura T, Yamada M, Tegoshi T, Onishi K. Human infection with *Pseudoterranova azarasi* roundworm. *Emerg Infect Dis* 2011; 17: 555-556.
10. Lee IH, Jang S, Lee CY, Park JS, Lee HJ, Kim HJ, Choi DS, Chun DC, Kim JS, Sohn WM. A case of human infection of the larvae from *Pseudoterranova decipiens*. *Korean J Gastrointest Endosc* 1998; 18: 732-736.
11. Sohn WM, Seol SY. A human case of gastric anisakiasis by *Pseudoterranova decipiens* larva. *Korean J Parasitol* 1994; 32: 53-56.
12. Torres P, Jercic MI, Weitz JC, Dobrew EK, Mercado RA. Human pseudoterranovosis, an emerging infection in Chile. *J Parasitol* 2007; 93: 440-443.
13. Bristow GA, Berland B. On the ecology and distribution of *Pseudoterranova decipiens* (Nematoda: Anisakidae) in an intermediate host, *Hippoglossoides platessoides*, in Northern Norwegian waters. *Int J Parasitol* 1992; 22: 203-208.
14. Chai JY, Chu YM, Sohn WM, Lee SH. Larval anisakids collected from the yellow corvina in Korea. *Korean J Parasitol* 1986; 24: 1-11.
15. Oshima T. Anisakiasis: is the sushi bar guilty? *Parasitol Today* 1987; 3: 44-49.

