

M. Corneffjord  
K. Olmarker  
K. Otani  
B. Rydevik

## Nucleus pulposus-induced nerve root injury: effects of diclofenac and ketoprofen

Received: 20 November 2000  
Revised: 29 March 2001  
Accepted: 19 April 2001  
Published online: 25 July 2001  
© Springer-Verlag 2001

M. Corneffjord · K. Olmarker · K. Otani  
B. Rydevik  
Department of Orthopaedics,  
Gothenburg University,  
Gothenburg, Sweden

M. Corneffjord (✉)  
Department of Orthopaedics,  
Uppsala University Hospital,  
75185 Uppsala, Sweden  
e-mail: michael.corneffjord@ortopedi.uu.se,  
Tel.: +46-18-6114477,  
Fax: +46-18-509427

K. Otani  
Department of Orthopaedic Surgery,  
Fukushima Medical College,  
Fukushima, Japan

**Abstract** *Main problem.* Nucleus pulposus and/or chronic compression can induce spinal nerve root injury. Inflammation has been proposed as having major importance in the pathophysiologic mechanisms involved in the induction of such injuries. Corticosteroids, potent anti-inflammatory drugs, have been demonstrated to reduce nucleus pulposus-induced spinal nerve root injury. The aim of the present study was to assess the effects of two potent non-steroidal anti-inflammatory drugs (NSAIDs), diclofenac and ketoprofen, in experimental nucleus pulposus-induced spinal nerve root injury in a pig model. *Methods.* Eighteen pigs were included in the study. Autologous nucleus pulposus was harvested from a lumbar disc and applied locally around the first sacral nerve root after a partial laminectomy of the first and second sacral vertebrae. Six pigs were treated with daily intramuscular injections of diclofenac, 3 mg/kg body weight, for 7 days. Six other pigs were treated with daily intramuscular injections of ketoprofen, 4 mg/kg body weight,

for 7 days. As controls, six pigs received injections with physiologic saline. After 7 days, the pigs were reanesthetized and the nerve conduction velocity over the exposed nerve root area was determined. *Results.* The nerve conduction velocity was significantly higher in pigs treated with diclofenac than in the saline-treated controls, ( $57 \pm 6$  m/s vs  $38 \pm 18$  m/s,  $P < 0.05$ , Student's *t*-test). The velocity in pigs treated with ketoprofen,  $42 \pm 24$  m/s, did not differ significantly from that of controls. *Conclusions.* This study of two potent NSAIDs indicates that nucleus pulposus-induced nerve root dysfunction may be reduced by diclofenac but not by ketoprofen. The reason for this difference is not known, but it might be related to the fact that ketoprofen and diclofenac belong to different NSAID subgroups and have a different selectivity for the two cyclo-oxygenases COX-1 and COX-2.

**Keywords** Spinal nerve roots · Inflammation · Intervertebral disc · Ketoprofen · Diclofenac

### Introduction

Spinal nerve root injury can be induced by chronic compression and/or the presence of nucleus pulposus [1, 3, 4, 5, 20, 21, 22, 26, 31, 32, 33, 34, 35, 36, 37, 38, 39, 46, 52]. It has been demonstrated experimentally that epidurally applied autologous nucleus pulposus, without any

compression, can induce significant changes in nerve root morphology and function in animal models [4, 5, 21, 22, 31, 34, 35]. Nucleus pulposus has been demonstrated to have inflammatory properties [33] and abundant macrophages and interleukin- $1\beta$  immunoreactive cells have been demonstrated in human disc hernias, suggesting an active inflammation [11, 13]. Inflammatory mechanisms have been suggested to be of pathogenetic significance in sciatic

ica induced by a herniated disc, in both recent and older literature [13, 14, 15, 18, 19, 24, 26, 39, 44, 45, 48]. High-dose administration of methylprednisolone, a potent anti-inflammatory drug, has been shown in other experiments to reduce nucleus pulposus-induced nerve root injury dramatically [32]. Recently, the nonsteroidal anti-inflammatory drug (NSAID) indomethacin was demonstrated to reduce the nucleus pulposus-induced effects on nerve root conduction velocity and intraneural blood flow in a dog model [1] and another NSAID, piroxicam, has been reported to reduce the inflammatory mediator phospholipase A2 in patients with herniated discs [41]. However, serious complications such as sterile meningitis and constrictive arachnoiditis have also been reported regarding both epidural and intrathecal injections of corticosteroids [28], leading to a decreased use of such injections in spinal pain syndromes.

The aim of the present study was to assess the efficacy of two potent NSAIDs, diclofenac and ketoprofen, in preventing nucleus pulposus-induced nerve root injury in an established pig model.

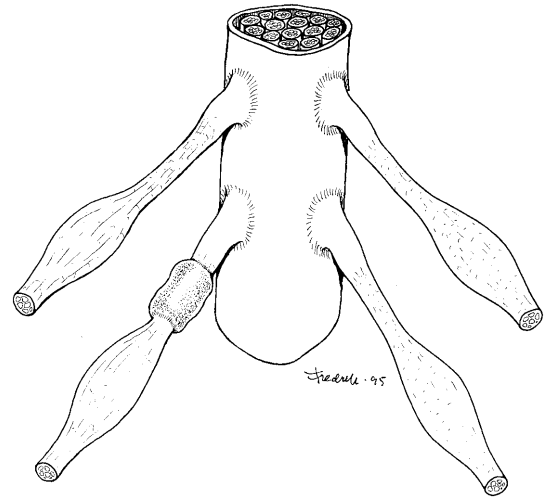
## Material and methods

Eighteen pigs (Swedish land breed/Swedish Yorkshire) weighing 25–30 kg received an intramuscular injection of 20 mg/kg body weight of ketamine 50 mg/ml (Ketalar, Parke-Davis, Morris Plains, N.J., USA) and an intravenous injection of 4 mg/kg body weight of (methomidate chloride 50 mg/ml (Hypnodil, AB Leo, Helsingborg, Sweden) and 0.1 mg/kg body weight of azaperon 2 mg/ml (Stresnil, Janssen, Beerse, Belgium). Anesthesia was maintained by additional intravenous injections of 2 mg/kg body weight of Hypnodil and 0.05 mg/kg body weight of Stresnil. An intramuscular injection of 10 mg/kg of benzylpenicillin (Novocillin, Novo Nordiska A/S, Bagsvaerd, Denmark) was given just prior to surgery and after surgery. The pigs also received an intravenous injection of 0.1 mg/kg of diazepam (Stesolid Novum, Dumex, Helsingborg, Sweden) after surgery.

Nucleus pulposus was first harvested from the L2-3 disc, with the animal placed on the side, through a retroperitoneal approach [31]. The wound was then sutured and the pig placed prone. Through a midline incision, a partial laminectomy of the first and second sacral vertebra was performed to expose the first sacral nerve roots bilaterally by aid of a microscope and under sterile conditions. Approximately 100 mg of nucleus pulposus was placed epidurally around the first left sacral nerve root in all the pigs (Fig. 1). Starting 24 h after the nucleus pulposus application, six pigs were treated with daily intramuscular injections of diclofenac (Voltaren, Novartis, Basel, Switzerland), 3 mg/kg body weight, for 7 days. Six other pigs were treated with daily intramuscular injections of 100 mg/ml ketoprofen (Romefen vet., Pherrovet, Malmö, Sweden), 4 mg/kg body weight, for 7 days. For control, six pigs received daily intramuscular injections of physiologic saline.

The drug injections were administered by the staff of the animal house at our department and the observer had no access to information regarding whether the pigs were treated or not. The experimental protocol was approved by the Animal Ethics Research Committee of Gothenburg University.

In all pigs, analysis was performed after 7 days. The pigs were then reanesthetized by an intramuscular injection of 20 mg/kg body weight of Ketalar and an intravenous injection of 35 mg/kg of thiopental sodium (Pentothal, Abbott, Chicago, Ill., USA). The pigs were ventilated on a respirator. Anesthesia was maintained



**Fig. 1** Nucleus pulposus applied to the first left sacral nerve root just cranially to the dorsal root ganglion

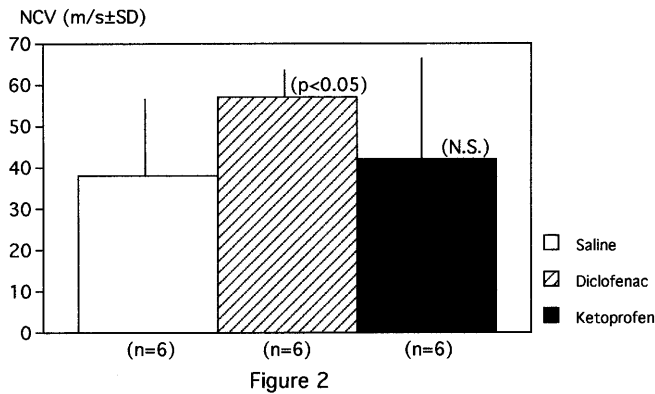
by an intravenous bolus injection of 100 mg/kg body weight of ( $\alpha$ )-D(+)-glucochloralose (Chloralose, Merck, Darmstadt, Germany) and by a continuous supply of 30 mg/kg per h of Chloralose. A laminectomy from the sixth lumbar to the third sacral vertebra was performed. The preparation was covered with a polyethylene sheath to maintain temperature and moisture. Local tissue temperature was continuously monitored and maintained at 37.5–38.0°C by means of a heating lamp.

The thecal sac was then opened. The left first sacral nerve root was stimulated by two E2 platinum needle electrodes (Grass, Quincy, Mass., USA), which were connected to a Grass SD9 stimulator. The electrodes were gently slid under the intrathecal part of the nerve root, approximately 10 mm cranially to the application site, and under the extrathecal part of the nerve root, approximately 10 mm caudally to the constrictor. Muscle action potentials (MAPs) were registered by two platinum needle electrodes placed approximately 10 mm apart in the paraspinal muscles of the tail. This procedure is reproducible and represents a functional measurement of the motor nerve fibers of the cauda equina nerve roots [30, 40, 43]. The EMG was visualized using a Macintosh IICI computer provided with Superscope software and a MacADIOS II A/D converter (GW Instruments, Sommerville, Mass., USA) together with a Grass P18 preamplifier. The separation distance between the first peaks of the MAPs from the two recordings was determined and that between the two stimulation sites on the cauda equina was measured with calipers. The nerve conduction velocity between the two stimulation sites could thus be calculated from these two measurements. To ensure that only impulses from exposed nerve fibers were registered, the nerve root was slightly elevated during stimulation. Statistical analyses were comprised of calculations of the mean nerve conduction velocity for all experiments in each treatment group. Student's *t*-test for unpaired samples was used to compare the different series.

## Results

There were no infections or neurologic deficits in any of the animals, except for slightly impaired tail movement.

The results of the neurophysiologic assessment are presented in Fig. 2. The nerve conduction velocity was significantly higher ( $P < 0.05$ , Student's *t*-test) in pigs



**Fig. 2** Nerve conduction velocity in the different subseries 7 days after application of nucleus pulposus

treated with diclofenac than in saline-treated controls. However, there were no significant differences in nerve conduction velocity in pigs treated with ketoprofen from controls ( $P=0.70$ )

## Discussion

The results of the present study demonstrate that the NSAID diclofenac may reduce the nucleus pulposus-induced nerve conduction velocity reduction.

In 1993 it was demonstrated that epidural application of autologous nucleus pulposus, without any compression, induced significant changes in nerve root morphology and function [31]. In a follow-up study, ultrastructural changes such as swelling of Schwann cells were demonstrated using electron microscopy [34]. The capacity of nucleus pulposus to induce both structural and functional changes in spinal nerve roots has been verified in several recent studies evaluating the biologic effects of nucleus pulposus [1, 3, 4, 20, 21, 22, 35, 38, 39, 44, 47, 52]. Nucleus pulposus' role in pain induction has recently been evaluated [22, 36, 37]. In a model for walking analysis of rats, it was demonstrated that application of nucleus pulposus epidurally, in combination with mechanical deformation, may induce pain [37]. However, the authors could find no apparent changes in the walking analysis, indicating that local application of nucleus pulposus per se, without any mechanical deformation or compression, could induce pain-related behavior. In another model for inducing disc herniation in rats, the authors found that puncture of a lumbar disc with subsequent herniation of nucleus pulposus without nerve root compression or chronic displacement of a lumbar nerve root did not induce significant changes in thresholds for mechanical or thermal stimulation compared to sham-operated animals [36]. On the other hand, the combination of disc puncture and displacement was demonstrated to cause a reduction of the threshold for thermal stimulation, indicating hyperalgesia.

Corticosteroids, known to be potent anti-inflammatory drugs, have been used clinically for many years in some parts of the world for relief of sciatica in patients with painful disc herniations [42, 50]. The corticosteroids have been injected both epidurally and intrathecally [42]. However, serious complications of this treatment, including constrictive arachnoiditis and sterile meningitis [28], have also been reported, and the use of epi- or intradural injections of corticosteroids has now decreased. Methylprednisolone, a corticosteroid, was demonstrated in a pig model to reduce nucleus pulposus-induced effects on nerve root function dramatically if administered intravenously in high doses within 48 h [32]. The pharmacological mechanisms in high-dose steroid treatment are complex and not yet fully understood [16], but they include inhibition of phospholipase A2 activation [27], prostaglandin synthesis [7], and physical stabilization of membranes [2].

Nonsteroidal anti-inflammatory drugs exert their major therapeutic effects by inhibition of prostanoid synthesis [51]. Diclofenac, one of the NSAIDs used in this study, has a potent inhibitory effect on cyclo-oxygenase and reduces the production of leukotrienes by cells participating in the inflammatory process due to decreased availability of intracellular arachidonic acid [23]. Ketoprofen, the other NSAID used here, is also a well-known cyclo-oxygenase inhibitor [29]. However, the two isoforms of cyclo-oxygenase, COX-1 and COX-2, are inhibited to varying degrees by different anti-inflammatory drugs [6, 12]. Recently, the inhibitory potency and selectivity of different NSAIDs were assessed in blood from humans [6]. Ketoprofen was found to be COX-1-selective, but diclofenac was COX-2-selective. In another study, ketoprofen was found to be the least COX-2-selective NSAID of all compounds tested [12]. This difference in cyclo-oxygenase selectivity might be one of the reasons why the effects of ketoprofen and diclofenac differed regarding nucleus pulposus-induced nerve root injury in the present study.

The varying inhibitory effects on phospholipase A2 of different NSAIDs have been assessed in serum from patients with acute pancreatitis [25]. Indomethacin was the only NSAID that inhibited the enzyme activity at a serum concentration level achieved after intravenous injections in clinical use. However, when higher concentrations were evaluated, diclofenac and ketoprofen were found to have similar effects on the inhibition of phospholipase A2 activity, reducing by 93% and 90% respectively. Betamethasone and hydrocortisone, both corticosteroids, were interestingly reported to have a weaker inhibitory effect on phospholipase A2 activity than all tested NSAIDs. Indomethacin has also been demonstrated to inhibit highly purified mammalian phospholipase A2 in rabbit alveolar macrophages and peritoneal polymorphonuclear leukocytes [9].

The more potent inhibitory effect of indomethacin than ketoprofen on phospholipase A2 activity might, together with differences in cyclo-oxygenase selectivity [6, 25],

explain why indomethacin has been reported to block the nucleus pulposus-induced changes in nerve conduction velocity [1], although ketoprofen failed to do so in the present study. However, in 1998 it was also reported that two different phospholipase A2 enzymes are present in herniated disc tissue from humans [14] and the difference in inhibitory effects of varying NSAIDs on these two enzyme types is, to our knowledge, still not known.

Recently, a new generation of NSAIDs with COX-2 selectivity but no effects on COX-1 have been introduced [8, 10, 17, 49]. Unfortunately, these two drugs, celecoxib [8, 10] and rofecoxib [49] are today available only for oral administration and not for intramuscular or intravenous injection.

In summary, the results of this study indicate that diclofenac and similar NSAIDs may modulate the pathophysiologic mechanisms involved in spinal nerve root injury induced by nucleus pulposus and demonstrate that other anti-inflammatory drugs than corticosteroids may have a role in the treatment of spinal nerve root injury induced by nucleus pulposus. Nevertheless, we want to

stress that the pharmacological and pathophysiological mechanisms involved in these treatment effects are incompletely known and need to be further investigated.

## Conclusions

From this experimental study on the effects of two different NSAIDs on spinal nerve root injury induced by nucleus pulposus, we may conclude that diclofenac seems to reduce the nucleus pulposus-induced nerve root dysfunction demonstrated as a preserved nerve conduction velocity in the nerve root after nucleus pulposus application. Ketoprofen, however, did not seem to have a similar effect.

**Acknowledgements** This study was supported by grants from the Swedish Medical Society, the Swedish Medical Research Council (8655), the Carin Trygger Memorial Foundation, the Inga Britt and Arne Lundberg Research Foundation, the Felix Neubergh Foundation, Gothenburg University, and the Gothenburg Medical Society.

## References

1. Arai I, Otani K, Konno S, Mao GP, Olmarker K, Kikuchi S (1997) Indomethacin blocks the nucleus pulposus-induced changes in nerve conduction and nerve blood flow in experimental disc herniation. *International Society for the Study of the Lumbar Spine*. Singapore
2. Bangham AD, Standish MM, Weismann G (1965) The action of steroids and streptolysin S on the permeability of phospholipid structures to cations. *J Mol Biol* 13:253–259
3. Byröd G, Rydevik B, Nordborg C, Olmarker K (1998) Early effects of nucleus pulposus application on spinal nerve root morphology and function. *Eur Spine J* 7:445–449
4. Cornefjord M (1996) Spinal nerve root injury induced by chronic compression and nucleus pulposus. Experimental studies on effects of controlled, slow-onset chronic compression and biochemical effects of nucleus pulposus on nerve root function, neuropeptide concentrations and morphology in a porcine model. Doctoral thesis. Gothenburg University, Sweden
5. Cornefjord M, Olmarker K, Rydevik B, Nordborg C (1996) Mechanical and biochemical injury of spinal nerve roots. A morphological and neurophysiologic study. *Eur Spine J* 5:187–192
6. Cryer B, Feldman M (1998) Cyclooxygenase-1 and cyclooxygenase-2 selectivity of widely used nonsteroidal anti-inflammatory drugs. *Am J Med* 104:413–421
7. Di Rosa M, Persico P (1979) Mechanism of inhibition of prostaglandin biosynthesis by hydrocortisone in rat leukocytes. *Br J Pharmacol* 66:161–163
8. Fort J (1999) Celecoxib, a COX 2-specific inhibitor: the clinical data. *Am J Orthop* 28 [Suppl 13]:188
9. Franson RC, Eisen D, Jesse R, Lanni C (1980) Inhibition of highly purified mammalian phospholipases A by nonsteroidal anti-inflammatory agents. Modulation by calcium ions. *Biochem J* 186:633–636
10. Goldenberg MM (1999) Celecoxib, a selective cyclooxygenase-2 inhibitor for the treatment of rheumatoid arthritis and osteoarthritis. *Clin Ther* 21:1497–1513
11. Grönblad M, Virri J, Tolonen J, Seitsalo S, Kääpä E, Kankare J, Myllynen P, Karaharju E (1994) A controlled immunohistochemical study of inflammatory cells in disc herniation tissue. 19:2744–2751
12. Grossman CJ, Wiseman J, Lucas FS, Trevethick MA, Birch PJ (1995) Inhibition of constitutive and inducible cyclooxygenase activity in human platelets and mononuclear cells by NSAIDs and Cox 2 inhibitors. *Inflamm Res* 44:253–257
13. Habtemariam A, Grönblad M, Virri J, Seitsalo S, Karaharju E (1998) A comparative immunohistochemical study of inflammatory cells in acute-stage and chronic-stage disc herniations. *Spine* 23:2159–2166
14. Habtemariam A, Grönblad M, Virri J, Airaksinen O, Luukkonen M, Turunen V, Savolainen S, Karaharju E (1998) Comparative immunohistochemical study of group II (synovial-type) and group IV (cytosolic) phospholipases A<sub>2</sub> in disc prolapse tissue. *Eur Spine J* 7:387–393
15. Habtemariam A, Virri J, Grönblad M, Seitsalo S, Karaharju E (1999) The role of mast cells in disc herniation inflammation. *Spine* 24:1516–1520
16. Hall ED (1992) The neuroprotective pharmacology of methyl-prednisolone. *J Neurosurg* 76:13–22
17. Hawkey CJ (1999) Cox-2 inhibitors. *Lancet* 353:307–314
18. Holmes JM, Sworn BR (1946) Lumbosacral root pain *Br Med J* 1:946
19. Jaffray D, O'Brien JP (1986) Isolated intervertebral disc resorption. A source of mechanical and inflammatory back pain? *Spine* 11:397–401
20. Kayama S, Konno S, Olmarker K, Yabuki S, Kikuchi S (1996) Incision of the annulus fibrosus induces nerve root morphologic, vascular and functional changes. An experimental study. *Spine* 22:2539–2543
21. Kayama S, Olmarker K, Larsson K, Sjögren-Jansson E, Lindahl A, Rydevik B (1998) Cultured, autologous nucleus pulposus cells induce functional changes in spinal nerve roots. *Spine* 23:2155–2158



22. Kawakami M, Tamaki T, Weinstein JN, Hashizume H, Nishi H, Meller ST (1996) Pathomechanism of pain-related behavior produced by allografts of intervertebral disc in the rat. *Spine* 21: 2101–2107
23. Ku EC, Lee W, Kothari HV, Kimble EF, Liauw L, Tjan J (1985) The effects of diclofenac sodium on arachidonic acid metabolism. *Semin Arthritis Rheum* 15 [Suppl 1]:36–41
24. Lewin P (1943) Backache and sciatic neuritis. Lea and Fabinger, Philadelphia
25. Makela A, Kuusi T, Schroder T (1997) Inhibition of serum phospholipase-A2 in acute pancreatitis by pharmacological agents in vitro. *Scand J Clin Lab Invest* 57:401–407
26. McCarron RF, Wimpee MW, Hudkins P, Laros GS (1987) The inflammatory effect of nucleus pulposus. A possible element in the pathogenesis of low-back pain. *Spine* 12:760–764
27. Mentz P, Giessler C, Förster W (1980) Evidence of a direct inhibitory effect of glucocorticosteroids on the activity of phospholipase A2 as a further possible mechanism of some actions of steroidal antiinflammatory drugs. *Pharmacol Res Commun* 12:817–827
28. Nelson DA, Vates TS Jr, Thomas RB (1973) Complications from intrathecal therapy in patients with multiple sclerosis. *Acta Neurol Scand* 49:176–188
29. Nikolov R (1984) Arachidonic acid cascade and anti-hypoxic drugs. *Methods Find Exp Clin Pharmacol* 6:231–234
30. Olmarker K (1991) Spinal nerve root compression. Nutrition and function of the porcine cauda equina compressed in vivo. *Acta Orthop Scand* [Suppl 242]: 1–27
31. Olmarker K, Rydevik B, Nordborg C (1993) Autologous nucleus pulposus induces neurophysiologic and histologic changes in porcine cauda equina nerve roots. *Spine* 18:1425–1432
32. Olmarker K, Byröd G, Cornefjord M, Nordborg C, Rydevik B (1994) Effects of methyl-prednisolone on pulposus-induced nerve root injury. *Spine* 19:1803–1808
33. Olmarker K, Blomquist J, Stromberg J, Nannmark U, Thomsen P, Rydevik B (1995) Inflammatory properties of nucleus pulposus. *Spine* 20:665–669
34. Olmarker K, Larsson K, Nordborg C, Rydevik B (1996) Ultrastructural changes in spinal nerve roots induced by autologous nucleus pulposus. *Spine* 21:411–414
35. Olmarker K, Brisby H, Yabuki S, Nordborg C, Rydevik B (1997) The effects of normal, frozen and hyaluronidase digested nucleus pulposus on nerve root structure and function. *Spine* 24: 471–475
36. Olmarker K, Myers RR (1998) Pathogenesis of sciatic pain: role of herniated nucleus pulposus and deformation of spinal nerve root and dorsal root ganglion. *Pain* 78:99–105
37. Olmarker K, Iwabuchi M, Larsson K, Rydevik B (1998) Walking analysis of rats subjected to experimental disc herniation. *Eur Spine J* 7:394–399
38. Olmarker K, Larsson K (1998) Tumor necrosis factor alpha and nucleus pulposus-induced nerve root injury. *Spine* 23:2538–2544
39. Otani K, Arai I, Mao GP, Konno S, Olmarker K, Kikuchi S (1999) Nucleus pulposus-induced nerve root injury: relationship between blood flow and motor nerve conduction velocity. *Neurosurgery* 45:614–620
40. Pedowitz RA, Garfin SR, Hargens AR, Swenson MR, Myers RR, Massie JB, Rydevik BL (1992) Effects of magnitude and duration of compression on spinal nerve root conduction. *Spine* 17:194–199
41. Piperno M, Hellio le Graverand MP, Reboul P, Mathieu P, Tron AM, Perrin G, Peschard MJ, Richard M, Vignon E (1997) Phospholipase A2 activity in herniated lumbar discs. Clinical correlations and inhibition by piroxicam. *Spine* 22:2061–2065
42. Ryan MD, Taylor TKF (1981) Management of lumbar nerve root pain by intrathecal and epidural injections of depot methylprednisolone acetate. *Med J Aust* 2:532–534
43. Rydevik BL, Pedowitz RA, Hargens AR, Swenson MR, Myers RR, Garfin SR (1991) Effects of acute graded compression on spinal nerve root function and structure: an experimental study on the pig cauda equina. *Spine* 16:487–493
44. Saal JS, Franson RC, Dobrow R, Saal JA, White AH, Goldthwaite N (1990) High levels of inflammatory phospholipase A2 activity in lumbar disc herniation. *Spine* 16:674–678
45. Saifuddin A, Mitchell R, Taylor BA (1999) Extradural inflammation associated with annular tears: demonstration with gadolinium-enhanced lumbar spine MRI. *Eur Spine J* 8:34–39
46. Sato K, Olmarker K, Cornefjord M, Rydevik B, Kikuchi S (1994) Changes of intradiscal blood flow in chronic nerve root compression. An experimental study on pigs. *Neuro-Orthopedics* 16:1–7
47. Satoh K, Konno S, Nishiyama K, Olmarker K, Kikuchi S (1999) Presence and distribution of antigen-antibody complexes in the herniated nucleus pulposus. *Spine* 24:1980–1984
48. Sawin PD, Traynelis VC, Rich G, Smith BA, Maves TJ, Follett KA, Moore SA (1997) Chymopapain-induced reduction of proinflammatory phospholipase A2 activity and amelioration of neuropathic behavioral changes in an in vivo model of acute sciatica. *J Neurosurg* 86:998–1006
49. Scott LJ, Lamb HM (1999) Rofecoxib. *Drugs* 58:409–507
50. Sehgal AD, Gardner WJ (1960) Corticosteroids administered intradurally for relief of sciatica. *Cleve Clin Q* 27:198–201
51. Stichtenoht DO, Zeidler H, Frolich JC (1998) New nonsteroidal anti-rheumatic drugs: selective inhibitors of inducible cyclooxygenase. *Med Klin* 93: 407–415
52. Yabuki S, Kikuchi S, Olmarker K, Myers RR (1998) Acute effects of nucleus pulposus on blood flow and endoneurial fluid pressure in rat dorsal root ganglia. *Spine* 23:2517–2523