

H. F. H. Halm
U. Liljenqvist
T. Niemeyer
D. P. K. Chan
K. Zielke
W. Winkelmann

Halm-Zielke instrumentation for primary stable anterior scoliosis surgery: operative technique and 2-year results in ten consecutive adolescent idiopathic scoliosis patients within a prospective clinical trial

Received: 17 November 1997
Revised: 21 March 1998
Accepted: 6 April 1998

H. F. H. Halm (✉) · U. Liljenqvist
T. Niemeyer · W. Winkelmann
Department of Orthopedic Surgery,
Westfälische Wilhelms-University,
Albert-Schweitzer-Strasse 33,
D-48149 Münster, Germany

D. P. K. Chan
University of Virginia Medical Center,
Charlottesville, Virginia, USA

K. Zielke
Am Unterscheid 9,
Bad Wildungen, Germany

Abstract Halm-Zielke instrumentation (HZI) was developed to eliminate the disadvantages of Zielke instrumentation (VDS) in terms of lack of primary stability and a kyphogenic effect. HZI is an anterior double-rod system. The system is composed of a lid-plate, which is fixed at the lateral aspect of the vertebral body with two screws, a sunk screw anteriorly and a VDS screw posteriorly. The lid-plate design provides the lowest possible implant profile. The longitudinal components consist of a threaded VDS rod and a solid, fluted rod. Correction is performed with the threaded rod and the solid rod. The solid rod allows internal derotation and relordosation, eliminates the Zielke three-point lever system and augments the system. The fluted design of the rod provides rotatory stability. This is a report of

the first ten consecutive adolescent idiopathic scoliosis patients in a prospective clinical trial using HZI with a minimum follow-up of 2 years. Curves ranged from 36° to 77°. Correction of the frontal plane averaged 77.5% and 72.2% postoperatively and at follow-up, respectively. Thoracolumbar kyphosis was present in three patients and corrected in all from an average of +18° to +1.7° at follow-up. Implant-related complications were not observed. All patients were treated without any additional external immobilization. In our opinion, HZI is a major improvement on the original Zielke VDS. It eliminates the kyphogenic effect and provides primary stability.

Key words Halm-Zielke instrumentation · Scoliosis · Surgery

Introduction

First published in 1969, Dwyer instrumentation was the first anterior system for correction of scoliotic deformities of the spine [2]. Major disadvantages of this system were a marked kyphogenic effect, ineffectiveness of derotation, frequent cable fractures with pseudarthrosis and screw pullouts. Ventral Derotation Spondylodesis (VDS), also known as Zielke instrumentation, was developed to preserve the advantages and to eliminate the disadvantages of Dwyer's technique [21]. VDS is the gold standard of scoliosis surgery from the anterior approach [7]. Whereas frontal plane correction and derotation have been reported

to be superior to posterior instrumentation techniques, the influence of VDS on the sagittal plane has been a subject of debate during the last two decades. A few authors pointed out that the sagittal plane can be positively influenced with VDS [3, 4, 21]. However, others have reported a kyphogenic effect [1, 11, 13–18, 20]. Another major disadvantage of VDS is lack of stability, which makes long-term brace or even cast treatment necessary. Screw pullouts, especially at the most superiorly instrumented level and fractures of the threaded rod were reported by several authors [8, 13, 16, 19]. These were associated with painful pseudarthrosis and loss of correction in quite a number of patients. Halm-Zielke instrumentation (HZI) was developed to eliminate the disadvantages of Zielke VDS.

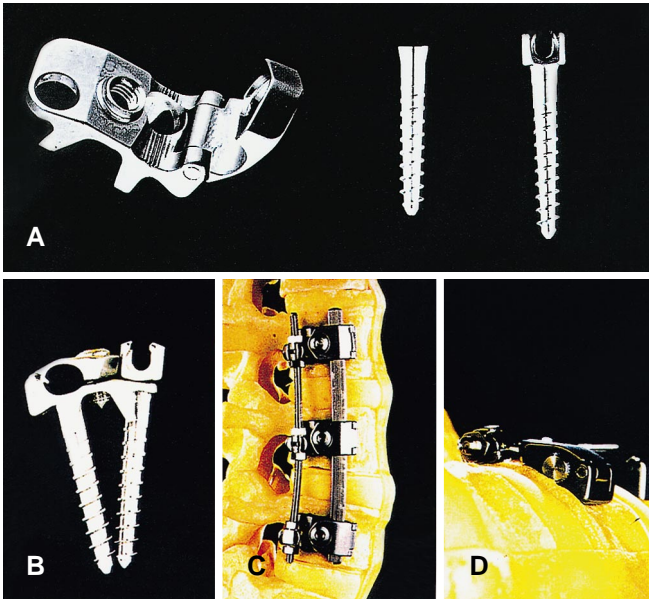


Fig. 1A–D Implants of Halm-Zielke instrumentation, excluding the threaded and solid rod

Material and methods

Implants and operative technique

Indications for HZI are identical with those for Zielke VDS. The implants of HZI are illustrated in Fig. 1. It consists of a lid-plate, which is attached to the lateral aspect of the vertebral body with two screws, a sunk screw anteriorly and a VDS screw posteriorly. The VDS screws are interconnected by a 4-mm threaded rod with collared hex nuts. With this threaded rod partial correction of the scoliotic deformity is performed, as described for VDS. Instead of Zielke’s lever system with its three-point fixation, a solid fluted 6-mm rod is present, inserted and fixed in place by closure of the lids. However, the lids are not completely tightened down, so that the solid rod can still be rotated around its longitudinal axis. Rotation of the rod then gradually leads to derotation and relordosation. If the system is used in the thoracic spine, rod rotation is performed the other way round to produce or enhance physiological kyphosis. Additionally segmental compression or distraction can be performed to enhance or reduce lordosis or kyphosis, if this is desirable. The operative principals of curve correction are illustrated in Fig. 2.

Fig. 2A–D Operative technique. **A** Partial correction is obtained with the threaded rod, followed by insertion of the solid rod and **B** derotation and relordosation is achieved by means of rod rotation. **C** After that segmental compression or distraction is still possible. **D** Final result

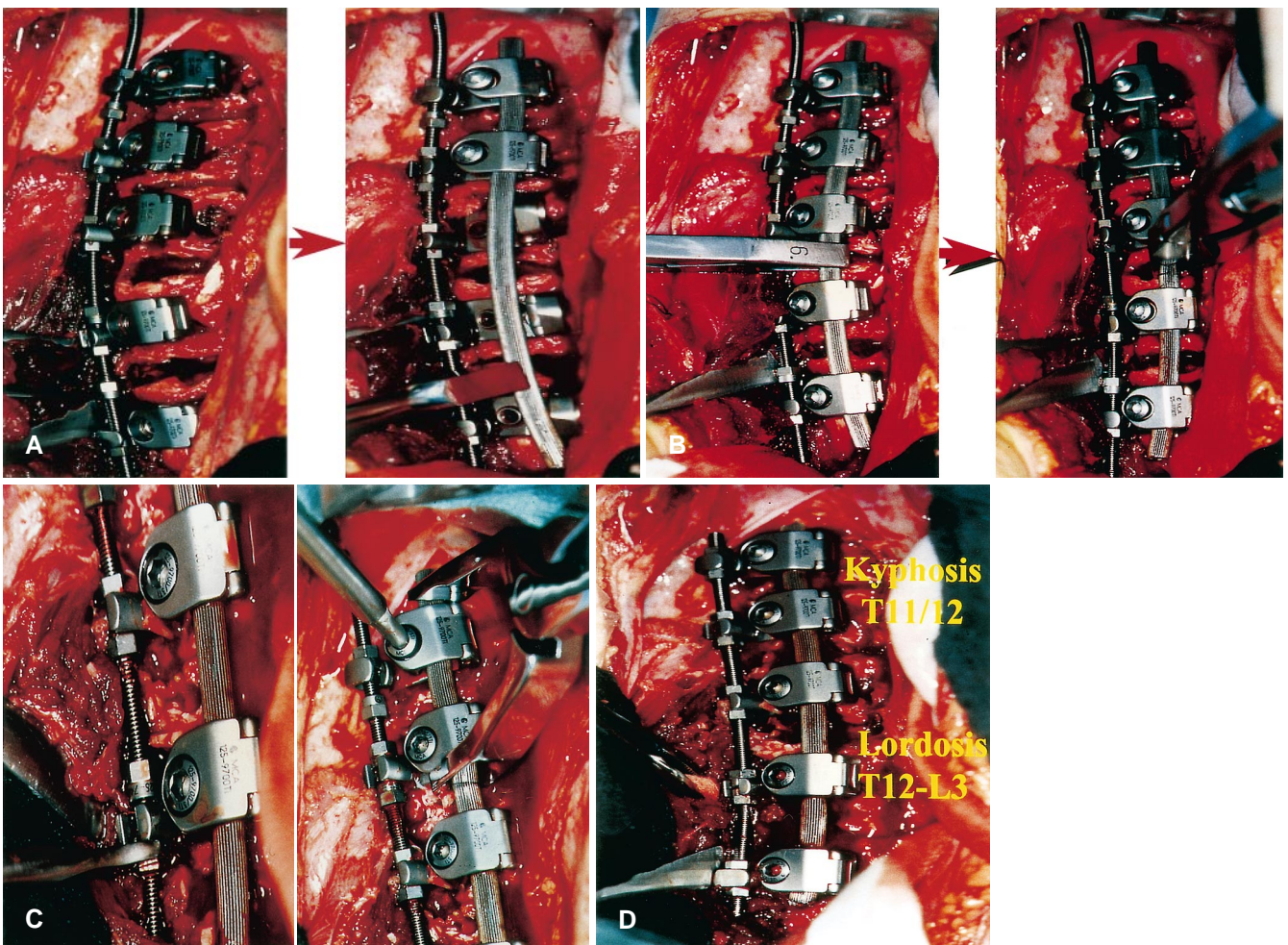


Table 1 Data on the major curve (MC) of the ten patients (FU follow-up)

Patient no.	Initials	Curve type	Age (years)	Curve length	Fusion length	Preop. MC (°)	Bending MC (°)	Postop. MC (°)	FU MC (°)
1	A.K.	Lumbar	16	5	5	58	34	18	20
2	N.K.	Thoracolumbar	16	4	4	48	28	20	27
3	C.G.	Thoracolumbar	17	3	3	42	18	4	6
4	A.K.	Thoracolumbar	14	5	5	63	36	5	8
5	K.V.	Low thoracic	17	6	6	68	36	14	20
6	N.H.	Thoracolumbar	17	5	6	61	22	7	10
7	N.H.	Lumbar	17	6	5	77	35	15	22
8	I.D.	King II	14	6	7	68	45	22	25
9	N.S.	Thoracolumbar	15	4	4	55	18	10	10
10	C.M.	Thoracolumbar	15	4	4	36	5	12	12
Mean			15.8	4.8	4.9	57.6	27.7	12.7	16.0

Patients and evaluation

This is a report on the first ten consecutive adolescent idiopathic scoliosis patients with a mean angle of 57.6°, operatively treated with HZI within a prospective clinical trial. All patients were female. The data of all patients were documented in specially designed charts: aetiology (idiopathic), type (adolescent), convexity of the primary and secondary curves, length and extent of the primary and secondary curves (measured between the two end vertebrae), location of the major curve (lumbar, thoracolumbar, thoracic), age at the time of the operation, length and extent of the instrumented fusion, blood loss, intraoperative complications, postoperative complications during hospital stay, late complications after dismissal until follow-up (Table 1).

For radiographic evaluation, frontal and lateral standing radiographs were available preoperatively, postoperatively and at follow-up. For measurement of curve flexibility, bending films were obtained preoperatively.

Results

Frontal plane

Length of the major curve, fusion length, the average results and the results of each patient for the major curve are

Table 2 The values of the instrumented curve, which was not always identical with the major curve as measured between the end vertebrae (HZI Halm-Zielke instrumentation)

Patient no.	Initials	HZI MC preop. (°)	HZI MC postop. (°)	HZI MC Follow-up (°)
1	A.K.	58	19	20
2	N.K.	40	16	18
3	C.G.	42	4	4
4	A.K.	62	8	8
5	K.V.	68	18	20
6	N.H.	57	12	12
7	N.H.	72	16	16
8	I.D.	68	22	25
9	N.S.	55	10	10
10	C.M.	36	12	12
Mean		55.8	13.7	14.5

illustrated in Table 1. The major curve averaged 57.6° preoperatively and was corrected to 12.7° and 16.0° postoperatively and at follow-up, respectively. The levels between the end vertebrae, however, were not always identical with the fusion levels. Therefore, the instrumented curve was measured selectively. These results are illustrated in Table 2. Preoperatively the instrumented curve measured 55.8° and was corrected to 13.7° and 14.5° postoperatively and at follow-up. This demonstrates, that the slight loss of correction did not occur within the instrumented curve.

The tilt of the lowest instrumented vertebra was corrected from an average of 29.2° to 8.1° without notable changes at follow-up (Table 3). The upper compensatory curve averaged 29.5° preoperatively, corrected to 14.2° on the bending film, and measured 18.1° postoperatively. This value was almost unchanged at follow-up (Table 4). Frontal plane decompensation averaged 1.7 cm preoperatively, and this mean value was unchanged at final follow-up.

Table 3 The values of the tilt angle of the lowest instrumented vertebra

Patient no.	Initials	Tilt preop. (°)	Tilt postop. (°)	Tilt FU (°)
1	A.K.	22	10	11
2	N.K.	26	8	10
3	C.G.	28	4	2
4	A.K.	36	6	6
5	K.V.	31	5	10
6	N.H.	28	4	4
7	N.H.	40	15	10
8	I.D.	34	11	10
9	N.S.	25	10	10
10	C.M.	22	8	8
Mean		29.2	8.1	8.1

Table 4 The values of the upper compensatory curve (UCC)

Patient no.	Initials	Preop. UCC (°)	Bending UCC (°)	Postop. UCC (°)	FU UCC (°)
1	A.K.	48	24	42	34
2	N.K.	28	20	28	28
3	C.G.	16	10	8	9
4	A.K.	28	16	8	6
5	K.V.	24	12	8	10
6	N.H.	32	2	10	14
7	N.H.	48	28	30	28
8	I.D.	–	–	–	–
9	N.S.	30	4	19	19
10	C.M.	10	0	10	10
Mean		29.5	12.9	18.1	17.5

Table 5 The values of the thoracolumbar junction (TLJ)

Patient no.	Initials	TLJ preop. (°)	TLJ postop. (°)	TLJ FU (°)
1	A.K.	2	-2	2
2	N.K.	-6	-2	-6
3	C.G.	-2	0	0
4	A.K.	4	5	4
5	K.V.	13	-5	-2
6	N.H.	27	3	4
7	N.H.	16	5	3
8	I.D.	–	–	–
9	N.S.	4	12	9
10	C.M.	2	-2	-2
Mean		6.7	1.5	1.2
Max. lordosis		-6	-5	-6
Max. kyphosis		27	12	9

Sagittal plane

Thoracic kyphosis (T4–T12) averaged 22.3° preoperatively and 24.5° postoperatively without changes at follow-up. Lumbar lordosis decreased from -42° preoperatively to -36° postoperatively without relevant changes at follow-up. Of major interest was the influence of HZI on the instrumented spinal levels. There were three patients with thoracolumbar kyphosis averaging 18° preoperatively. In all patients this was completely corrected. In one patient with thoracic scoliosis, there was lordosis of -2° within the thoracic spine. This was corrected to 10° of kyphosis due to rotation of the solid rod the other way around its longitudinal axis into kyphosis. Patients with a physiological sagittal plane within the instrumented spinal segments were almost unchanged postoperatively and at follow-up (Table 5).

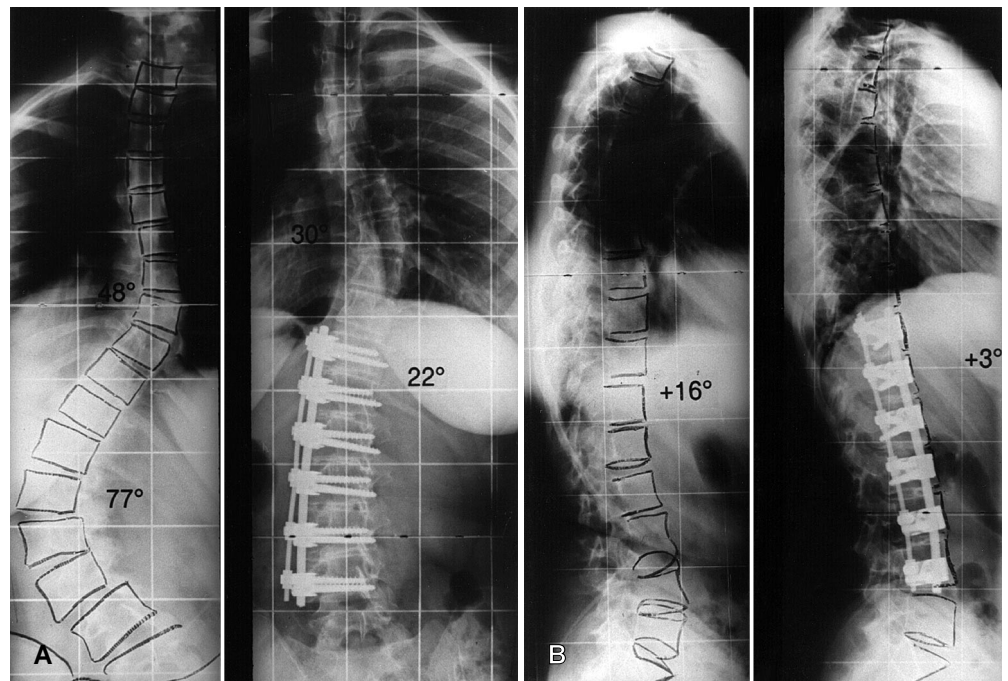
Blood loss and complications

Blood loss averaged 525 ml with a maximum of 1000 ml for the most severe curve of 77° and a minimum of 250 ml. All patients donated 3–4 units of blood. Only one patient required 1 and another one 2 units of donated blood back intraoperatively or postoperatively.

There were no intraoperative complications. Postoperatively one patient complained of hypoesthesia at the anterior aspect of the thigh and had a painful weakness of hip flexion. This slight neurologic deficit completely resolved within the first 6 months postoperatively.

Implant related complications were not noted within the first 2 postoperative years. Radiographically all segments seem to be fused (Fig. 3).

Fig. 3 **A** A 17-year-old girl with severe adolescent idiopathic lumbar scoliosis of 77° and an associated thoracolumbar kyphosis of 16°. **B** Good correction of the frontal and sagittal plane with a well-balanced spine



Discussion

Zielke VDS was developed in 1974 and represents a major improvement on Dwyer instrumentation in terms of derotation. It still is the gold standard of anterior scoliosis surgery. Meanwhile, a few anterior, more rigid implants for scoliosis surgery have been developed, for example the Texas Scottish Rite Hospital system (TSRH) and the Cotrel-Dubousset-Hopf system (CDH) [7, 20]. However, their correcting principles are not based on the correcting principles of VDS. The methods of Kaneda et al., Jeszenszky et al. and Harms are partly based on the VDS correcting principles [6, 10, 12].

Frontal plane correction in our series averaged 71% at follow-up, and is comparable to reports on VDS [3, 4, 18, 21]. With this correction, the tilt angle of the lowest instrumented vertebra was well corrected. Correction of the major curve led to spontaneous correction of the upper compensatory curve, which also occurs after VDS [3, 4, 14, 17, 21].

A major shortcoming of VDS is a kyphogenic effect within the instrumented levels [8, 13–18]. With development of our system we aimed at preserving the established and proved correcting principles of VDS. The data demonstrates that this was achieved. In addition, improvement of sagittal plane control and sagittal plane correction was obtained by means of rod rotation with the additional solid, fluted rod, which takes over the tasks of the Zielke three-point lever system. Of course the authors are aware of the fact, that it is difficult to measure the sagittal plane accurately in scoliosis patients, because the rotational component does not allow a true lateral view of the whole curve. However, in thoracolumbar curves the end vertebrae of the thoracolumbar junction, T10 and L2, are neutrally or almost neutrally rotated vertebrae, so that in our mind the Cobb method is still the best method to measure the sagittal plane, especially the thoracolumbar junction on standard radiographs. On the other hand, it is well known that in quite a number of scoliotic curves the kyphotic component represents rotational kyphosis or "pseudokyphosis". Thus derotation by means of anterior instrumentation contributes to sagittal realignment [3, 21].

The solid rod, when locked in place by tightening down the lids of each plate, augments the system and provides primary stability. The improved stabilizing capabilities of HZI compared to VDS have been demonstrated with multidirectional, biomechanical tests and were published elsewhere [5]. Improvement of stability was of major interest, because VDS, although a good system for scoliosis correction, has very limited stabilizing capabilities. This is true for the threaded rod, serving as an interlink as well as the bone metal interface. With VDS, rod fractures with or without pseudarthrosis were reported in 9–23% of the cases, even when postoperative cast or brace treatment was used. Pseudarthrosis is associated with high risk of loss of correction and recurrence or appearance of pain [19]. In addition to this VDS screw loosening or pullout with or without vertebral body fracture was reported in up to 29% of the cases, mostly at the superior end vertebra level [13, 16]. With the two-screw per vertebral body fixation of HZI, this problem is solved. Biomechanical tests have shown that axial pullout forces of HZI are twice those of VDS [5].

With HZI no implant-related complications were observed. No postoperative brace or cast treatment was performed and, after wound healing, the patients were allowed to go swimming for physiotherapy purposes. At final follow-up, all segments appear to be fused radiographically and no screw or rod fracture or loosening at interlink sites were observed. However, we did not perform conventional tomographies to evaluate the intervertebral fusion mass in order to avoid additional radiographic exposure.

One of our patients complained of hypoaesthesia and pain at the anterior aspect of the thigh. This is a well-known complication related to the anterior exposure of the lumbar spine, and occurs in up to 30% of cases [17]. It is related to the mobilization and retraction of the psoas muscle and irritation of the underlying nerve root.

In summary, the data of this limited series of patients proves that HZI is a major improvement on VDS. The results of an additional 12 patients with scoliosis of different aetiologies treated with HZI and a minimum follow-up of 1 year so far support the above conclusions.

References

1. Bridwell KH (1994) Spine update. Surgical treatment of adolescent idiopathic scoliosis. The basics and the controversies. *Spine* 19: 1095–1100
2. Dwyer AF, Newton NC, Sherwood AA (1969) An anterior approach to scoliosis. *Clin Orthop* 62: 192–202
3. Giehl JP, Zielke K, Hack HP (1989) Die ventrale Derotationspondylodese nach Zielke. *Orthopäde* 18: 101–117
4. Halm H, Liljenqvist U, Castro WHM, Jerosch J (1995) Die operative Behandlung idiopathischer thorakolumbalen Skoliosen: Cotrel-Dubousset instrumentation versus ventrale Derotationspondylodese. *Z Orthop Ihre Grenzgeb* 133: 282–288
5. Halm H (1997) Biomechanische und klinische Untersuchungen zur Optimierung der Formkorrektur und Stabilisierung von idiopathischen Skoliosen. Thesis, Westfälische Wilhelms-University, Münster, pp 25–106
6. Harms J (1992) Screw-threaded rod system in spinal fusion surgery. In: *Spine: State of the Art Reviews* 6: 541–575
7. Hopf C, Eysel P, Dubousset J (1995) CDH – Vorläufiger Ergebnisbericht über ein primärstabiles ventrales Wirbelsäuleninstrumentarium. *Z Orthop Ihre Grenzgeb* 133: 274–281

8. Horton WC, Holt RT, Johnson JR (1988) Zielke instrumentation in idiopathic scoliosis: late effects and minimizing complications. *Spine* 13: 1145–1149
9. Jendrisak MD (1986) Spontaneous abdominal aortic rupture from erosion by a lumbar spine fixation device. A case report. *Surgery* 99: 631–634
10. Jeszenszky D, Harms J, Beele B (1995) The ventral correction of lumbar or thoracolumbar scoliosis: the ventral lordosis-derotation spondylosyndesis. Poster Presentation at the 30th Annual Meeting of the Scoliosis Research Society, Asheville, North Carolina, p 81
11. Kaneda K, Fujiya N, Satoh S (1986) Results with Zielke instrumentation for idiopathic thoracolumbar and lumbar scoliosis. *Clin Orthop* 205: 195–203
12. Kaneda K, Yamamoto I, Satoh S, Kotani Y (1992) New anterior instrumentation (the two-rod system) for treatment of thoracolumbar and lumbar scoliosis – early clinical results. Presented at the Biannual Meeting of the European Spinal Deformity Society, Lyon, p 105
13. Karbowski A, Liljenqvist U, Bettin D, Heine J (1996) Langfristige Behandlungsergebnisse ventraler und kombinierter ventrodorsaler Spondylothesen in der operativen Therapie der Skoliose. *Z Orthop Ihre Grenzgeb* 134: 81–88
14. Lowe TG, Peters JD (1993) Anterior spinal fusion with Zielke instrumentation for idiopathic scoliosis. *Spine* 18: 423–426
15. Luk KDK, Leong JCY, Reyes L, Hsu LCS (1989) The comparative results of treatment in idiopathic thoracolumbar and lumbar scoliosis using the Harrington, Dwyer and Zielke instrumentation. *Spine* 14: 275–280
16. Moe JH, Purcell GA, Bradford DS (1983) Zielke instrumentation (VDS) for correction of spinal curvature. *Clin Orthop* 180: 133–153
17. Moskowitz A, Trommanhauser S (1993) Surgical and clinical results of scoliosis surgery using Zielke instrumentation. *Spine* 18: 2444–2451
18. Ogiela DM, Chan DPK (1986) Ventral derotation spondylothesis. *Spine* 11: 18–22
19. Puno RM, Johnson JR, Ostermann PAW (1989) Analysis of the primary and compensatory curvatures following Zielke instrumentations for idiopathic scoliosis. *Spine* 14: 738–743
20. Turi M, Johnston CE, Richards BS (1993) Anterior correction of idiopathic scoliosis using TSRH instrumentation. *Spine* 18: 417–422
21. Zielke K (1982) Ventrale Derotationsspondylothese. Behandlungsergebnisse bei idiopathischen Lumbalskoliosen. *Z Orthop Ihre Grenzgeb* 120: 320–329