

F. López-Oliva Muñoz  
B. García de las Heras  
V. Concejero López  
J. J. Asenjo Siguero

## Comparison of three techniques of anterior fusion in single-level cervical disc herniation

Received: 9 March 1998  
Revised: 21 August 1998  
Accepted: 25 August 1998

No benefits in any form have been received or will be received from a commercial party related directly or indirectly to the subject of this article. No funds were received in support of this study.

F. López-Oliva Muñoz (✉)  
B. García de las Heras  
V. Concejero López · J. J. Asenjo Siguero  
Department of Orthopaedic Surgery,  
Centro de Rehabilitación Fremap,  
Carretera Pozuelo-Majadahonda, km 3.5,  
E-28220 Majadahonda, Madrid, Spain

**Abstract** This study compared the clinical and radiographic outcome of three techniques of anterior fusion for cervical disc herniation: Cloward fusion with autograft, Cloward fusion with freeze-dried bone, and BAK-C device fusion. In a cohort of 84 consecutive patients, 34 were treated by classic autograft Cloward's technique, in 26 patients freeze-dried xenograft Surgibone was used and in the last 24 patients a BAK-C titanium device was implanted. The mean follow-up period of this last group was 14.6 months. All patients were operated by the same surgeon at the same hospital and all underwent single-level surgery. Results were evaluated on the basis of patient satisfaction and postoperative capacity to work. There was no significant difference between the three groups related to the preoperative assessment. The analysis revealed that BAK-C patients had significantly shorter hospital stays. No postoperative cervical collar was worn by BAK-C patients and they had the highest percentage of excellent clinical results. Concerning radiographic

evaluation, BAK-C achieved a more stable fixation of the involved segment without complications in contrast with the two others, which presented a significant incidence of extrusion, collapse, kyphosis and pseudarthrosis. Measurement of the progressive kyphosis grade shows statistically significant differences between the three groups. BAK-C patients had the lowest kyphosis grade at the end of the follow-up. There is an important correlation between collapse, collapse with kyphosis and pseudarthrosis with bad clinical results. In conclusion, the BAK-C device showed significant advantages, including higher patient satisfaction, unnecessary postoperative collar, early rehabilitation and a lower rate of complications. Furthermore, BAK-C is cost effective because of it shortens postoperative hospital stay and allows an earlier return to work.

**Key words** Cervical spine · Disc herniation · Instrumented fusion · Titanium implant · Bone graft substitute

### Introduction

Anterior cervical discectomy with interbody fusion has been shown to be effective in the treatment of cervical disc herniation [2, 4, 7, 8, 10, 12]. Because of its good clinical results and low morbidity, anterior surgery has

gained wide acceptance over the last three decades. Cloward's technique [5] is one of the most widely used in the world. This fact and its good surgical reliability encouraged us to employ Cloward's procedure to operate our cervical disc herniation patients.

The objectives of anterior fusion must be to achieve restoration of normal cervical alignment, foraminal dis-

traction and prevention of collapse and kyphosis [6, 14]. The problem is bone grafting. Following authors like Zdeblick and Ducker [17], from July 1992 on we began to use cylindrical freeze-dried xenograft, to avoid the morbidity of autogenous iliac crest grafting. Later, some mechanical failures encouraged us to use the new BAK-C fusion procedure. This device is based on the principle of a threaded spacer and soft bone graft containment. Introduced in the discectomy space, this new implant promised to safeguard the objectives of anterior cervical fusion without morbidity and failures.

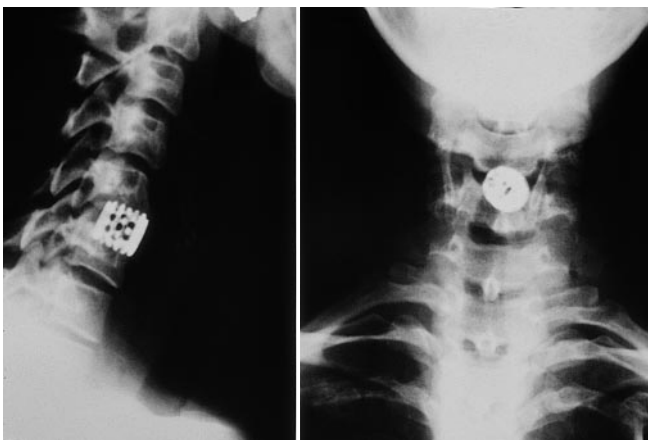
The aim of the current study was to compare the clinical and radiological outcome of these three different techniques for surgical treatment of the same disease – single-level soft cervical disc herniation.

## Materials and methods

Eighty-four consecutive patients who were treated surgically for symptomatic single-level soft cervical disc herniation between June 1987 and June 1997 were reviewed retrospectively. All had suffered work-related injuries. Thirty-four of these patients were treated by strict Cloward's procedure, employing autogenous iliac crest bone graft. In 26 patients freeze-dried allograft (Unilab Surgibone, Mississauga, Ontario) was used, and in the last 24 patients a BAK-C (Spinetech, Minneapolis, Min., USA) fusion cage was implanted instead of bone graft. All patients were operated by the same surgeon at the same hospital and all underwent single-level surgery.

The indications for surgery were the same in all three groups: neck and/or arm pain, findings of physical examination and CT or MRI consistent with the diagnosis, and more than 6 weeks of conservative treatment. The follow-up periods were different for each group. The autogenous graft group had a follow-up of 78.6 months (range 24–124 months); the Surgibone cases 36.7 months (range 23–50 months) and the BAK-C patients only 14.6 months (range 6–23 months).

We will not describe the well-known Cloward technique [5] with auto or xenograft, but we will summarize the BAK-C procedure (Fig. 1).



**Fig. 1** C5–C6 disc herniation treated by discectomy and BAK-C fusion

After performing an anterior cervical discectomy using conventional methods, a distraction plug is inserted into the disc space establish the appropriate implant diameter. In a second step, an adjustable drill tube is inserted by impaction to guide the drill, which drills the hole between the two adjacent vertebrae. After drilling, a tap makes the threads screw the BAK-C into the hole. Before inserting the implant, the bone from the drill is removed and packed in. Additional bone can be obtained from osteophytes.

Postoperatively, all the patients in the Cloward with autograft group were placed in a Philadelphia collar for 6 weeks and those with xenograft for 4 weeks. In the patients operated with BAK-C no postoperative collar was used. Each patient's age, sex, job, duration of symptoms, level of disc herniation, clinical presentation, neurological status and associated degenerative changes were recorded. Postoperative hospital stay, complications and time to return to work also were recorded.

The clinical results were established according to the following scale: excellent – all symptoms relieved; fair – improved but persistence of mild symptoms; poor – symptoms and signs unchanged.

Regarding return to work, results were classified as follows: W1 – returned to previous employment, even heavy work; W2 – changed to another more sedentary employment full time; W3 – unable to work.

Radiological postoperative assessment was made by plain radiographs to measure the sagittal segmental kyphosis angle and to detect complications such as collapse, kyphosis, extrusion and pseudarthrosis. This angle was measured from the upper end plate of the superior vertebra to the lower end plate of the inferior vertebra. Statistical analysis was carried out by a biostatistics expert using SPSS (Statistical Package for the Social Sciences, Medical Statistics, Chicago). For all analyses, the significance criterion was  $P < 0.05$ .

Independent observers reviewed the patients. The surgeon did not participate in this study.

## Results

### Preoperative assessment

There were no significant differences between the three groups of this cohort related to the preoperative assessment. The three groups therefore had the same preoperative conditions and it is meaningful to compare them. All patients were insured under workers' compensation insurance.

### Postoperative hospital stay

The analysis revealed that BAK-C patients had a significantly shorter hospital stay (2.87–4.04 days, mean 3.56 days) than the other groups (autograft: 5.35–7.59 mean, 6.47; Surgibone: 4.16–5.91, mean 5.04;  $P > 0.001$ ).

### Collar wearing period

Autograft patients wore a postoperative collar for 6 weeks and Surgibone patients for 4 weeks. No postoperative cervical collar was worn by BAK-C patients.

**Table 1** Clinical results by treatment group

Treatment technique	Excellent	Fair	Poor
Autograft	16 47.1%	15 44.1%	3 8.8%
Surgibone	7 26.9%	12 46.2%	7 26.9%
BAK-C	16 66.7%	6 25.0%	2 8.3%

### Donor graft site problems

By nature of the procedure, only autografts had this type of complication. Two patients developed a deep infection at the iliac crest and three others complained of disturbances at the graft donor site. No femorocutaneous nerve injuries were recorded.

### Clinical evaluation

#### *Time to return to work*

The mean time taken to return to work for the three groups was (in months): autograft, 6.18 (range 4.98–7.37); Surgibone, 8.85 (range 6.60–11.10) and BAK-C, 5.79 (range 4.22–7.36). The Classic Cloward's technique and BAK-C had similar results, while for Surgibone patients time off work was significantly longer ( $P = 0.018$ ).

#### *Patient satisfaction*

Regarding the patients' evaluation of the outcome, the three groups differed significantly (Chi-square,  $P = 0.037$ ). BAK-C patients had the highest percentage of excellent results as shown Table 1.

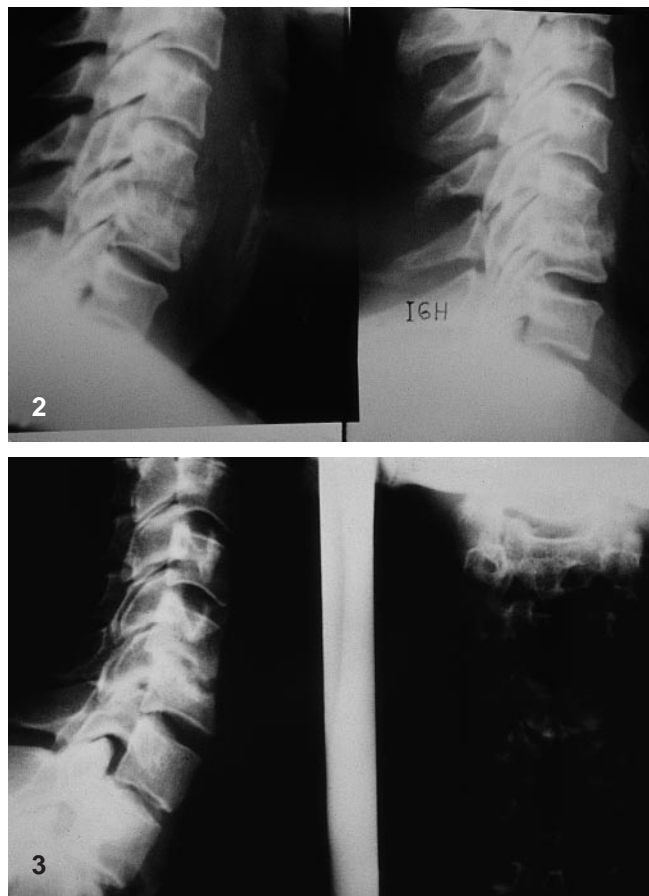
#### *Capacity to work*

In the autogenous graft group 31 patients (91.2%) were rated W1 and 3 (8.8%) W3. Fifteen (57.7%) Surgibone patients were rated W1 and 11 (42.3%) W3. Twenty-one (87.5%) BAK-C patients were rated as W1, one (4.2%) as W2 and two (8.3%) as W3.

### X-ray evaluation

#### *Collapse*

Collapse was identified in 15 patients (44.1%) of the autograft group, 12 (35.3%) of the Surgibone group. There were no cases of significant collapse in the BAK-C group ( $P < 0.001$ ). All BAK-C patients showed a variable mini-

**Fig. 2** Collapse and kyphosis in an autograft case**Fig. 3** Pseudarthrosis of xenograft C5–C6 fusion

mal collapse, always less than 3 mm, due to accommodation of the implant. No radiolucent lines were observed in our cases at the end of follow-up period.

#### *Collapse and kyphosis*

There were seven cases of collapse and kyphosis in the autogenous group (20.8%), seven in the Surgibone group (26.9%) and none in the BAK-C group ( $P < 0.001$ ) (Fig. 2).

#### *Extrusion*

Extrusion was observed in two patients in the autogenous group (6%), one in the Surgibone group (3.8%) and none in the BAK-C group ( $P < 0.001$ ).

#### *Pseudarthrosis*

Pseudarthrosis was recorded in one patient of the autogenous group (2.9%) and four patients (15.4%) of the Surgi-

**Table 2** Kyphosis grade at the end of follow-up

Treatment technique	< -5°	-5-0°	0°	0-5°	5-10°	> 10°
Autograft			20	4	9	3
Surgibone			8	8	7	3
BAK-C	3	4	10	4	2	

bone group (Fig. 3); no case of pseudarthrosis or radiological failure was observed in the BAK-C group ( $P < 0.001$ ).

#### *Progressive kyphosis (Table 2)*

Statistically significant differences in kyphosis were found between the three groups ( $P = 0.009$ ). BAK-C patients had the lowest kyphosis grade at the end of follow-up.

#### Correlation between complications and results

There is an important correlation of collapse ( $P = 0.039$ ) and collapse with kyphosis ( $P = 0.008$ ) with bad clinical results, while extrusion ( $P = 0.0834$ ) does not correlate. Pseudarthrosis has a very strong correlation with bad results ( $P < 0.001$ ).

#### Complications

No operative mortality occurred. No technical or neurological complications were recorded in the three groups.

### Discussion

Bailey and Badgley [1] developed the anterior approach for cervical trauma and published their results in 1952. Almost simultaneously, Smith and Robinson [16] developed a similar approach for degenerative diseases of the cervical spine. Cloward [5] in 1958 published his technique of cervical discectomy and fusion with innovative new instrumentation, which was widely accepted by many surgeons for treatment of cervical disc herniation and spondylosis. In expert hands, Cloward's procedure is safe and effective in solving the clinical symptoms of the patients in a high percentage of cases. However, significant morbidity related to donor site was reported by many authors as well as radiological complications including collapse, extrusion, kyphosis and failures of fusion [2-4, 8, 11, 12].

Discectomy without fusion has been advocated as the solution to this morbidity [9, 15], but we think that dis-

cectomy alone does not achieve the aims of restoration of normal cervical alignment, foraminal distraction and prevention of collapse and kyphosis.

Bone-bank fusion appeared to be a less morbid technique [3, 17], and we began to use it in our patients. But the evidently bad results forced us to look for other alternatives. We knew the advantages of anterior decompression and internal fixation with titanium plates [13], but chose the easier BAK-C technique.

BAK-C acts as a spacer or interference screw, and ensures a reliable fixation of the adjoining vertebral segments.

In our comparative study, the BAK-C system had a shorter follow-up than the auto and xenograft Cloward's technique. We can therefore only speak about early results. Long-term outcome will be analysed in further studies.

In accordance with other published data [3] the freeze-dried xenograft showed a higher rate of complications and bad results than the autograft techniques. Surgibone seems to be unable to support the loading forces and develops collapse with an significant incidence of pseudarthrosis. These failures worsen the clinical results significantly.

Iliac crest graft has a better clinical outcome, although the radiological analysis shows a high incidence of segmental collapse.

In this study the BAK-C technique achieved the best clinical results, with a better radiological outcome. No loosening signs have been detected in any case. Only slight peripheral bone resorption with segmental collapse of less than 3 mm can be measured in some patients, without radiolucent lines. We think this minimal collapse may be due to accommodation of the implant.

It is difficult to establish whether the BAK-C implant achieved solid bone fusion in all cases. The device produces disturbances on CT and MRI studies and we have not been able to evaluate the fusion mass or bone continuity across the implant. The optimal roentgenological outcome shows that, of the three techniques, BAK-C gave better stability and distraction to the discectomy segment and maintained it during our short follow-up period.

### Conclusion

In the treatment of single-level disc herniation, the short-term BAK-C implants show important advantages, such as higher patient satisfaction, no requirement for a postoperative collar, early rehabilitation, and a lower rate of complications. Furthermore, BAK-C proved cost effective, because of the shorter postoperative hospital stay and earlier return to work.

## References

1. Bailey RW, Badgley CE (1960) Stabilization of the cervical spine by anterior fusion. *J Bone Joint Surg [Am]* 42: 565–594
2. Blondi C, Moroni A, Cantagalli S, Trinchese L, Vicenzi G, Pezzuto V, Rollo G (1990) The surgical treatment of cervical disc herniation. *Chir Organi Mov* 75: 311–314
3. Brown MD, Malinin TI, Davis PB (1976) A roentgenographic evaluation of frozen allografts versus autografts in anterior cervical spine fusions. *Clin Orthop* 119: 231–236
4. Clements DH, O'Leary PF (1990) Anterior cervical discectomy and fusion. *Spine* 15: 1023–1025
5. Cloward RB (1958) The anterior approach for removal of ruptured cervical discs. *J Neurosurg* 15: 602–617
6. De Palma AF, Rothman RH, Lewinnek GE, Canale ST (1972) Anterior interbody fusion for severe cervical disc degeneration. *Surg Gynecol Obstet* 134: 755–758
7. Dubuisson A, Lenelle J, Stevenaert A (1993) Soft cervical disc herniation: a retrospective study of 100 cases. *Acta Neurochir (Wien)* 125: 115–119
8. Eriksen EF, Buhl M, Fode K, et al (1984) Treatment of cervical disc disease using Cloward's technique. The prognostic value of clinical preoperative data in 1,106 patients. *Acta Neurochir (Wien)* 70: 181–197
9. Herkowitz HN, Kurz LT, Overholt DP (1990) Surgical management of cervical soft disc herniation. A comparison between the anterior and posterior approach. *Spine* 15: 1026–1030
10. Laus M, Pignatti G, Alfonso C, Martelli C, Giunti A (1992) Anterior surgery for the treatment of soft cervical disc herniation. *Chir Organi Mov* 77: 101–109
11. Martino V, Nina P, Franco A, Di Benedetto A, Chiappetta F, Schisano G (1997) Cervical myelopathy caused by median disc herniation: analysis of the complications following anterior discectomy with and without fusion. Report of 90 cases. *J Neurosurg Sci* 412: 153–158
12. Mosdal C (1984) Cervical osteochondrosis and disc herniation. Eighteen years' use of interbody fusion by Cloward's technique in 755 cases. *Acta Neurochir (Wien)* 70: 207–225
13. Muhlbauer M, Saringer W, Aichholzer M, Sunder-Plassmann M (1995) Microsurgical anterior decompression and internal fixation with iliac bone graft and titanium plates for treatment of cervical intervertebral disc herniation. *Acta Neurochir (Wien)* 134: 207–213
14. Phillips FM, Carlson G, Emery SE, Bohlman HH (1997) Anterior cervical pseudoarthrosis. Natural history and treatment. *Spine* 22: 1585–1589
15. Pointillart V, Cernier A, Vital JM, Sénégas J (1995) Anterior discectomy without interbody fusion for cervical disc herniation. *Eur Spine J* 4: 45–51
16. Smith GW, Robinson RA (1958) The treatment of certain cervical spine disorders by anterior removal of the intervertebral disc and interbody fusion. *J Bone Joint Surg [Am]* 40: 607–623
17. Zdebilck TA, Ducker TB (1991) The use of freeze-dried allograft bone for anterior cervical fusions. *Spine* 16: 1974–1983