

H. Halm
T. Niemeyer
T. Link
U. Liljenqvist

Segmental pedicle screw instrumentation in idiopathic thoracolumbar and lumbar scoliosis

Received: 23 September 1999
Revised: 20 January 2000
Accepted: 26 January 2000

H. Halm (✉) · T. Niemeyer
Center for Spine Surgery
and Scoliosis Center, Klinikum Neustadt,
Am Kiebitzberg 10,
23730 Neustadt, Germany
e-mail: HHalm@schoen-kliniken.de,
Tel.: +49-4561-544901,
Fax: +49-4561-544910

Th. Link
Department of Clinical Radiology, West-
fälische Wilhelms-Universität, Münster,
Germany

U. Liljenqvist
Department of Orthopedic Surgery,
Westfälische Wilhelms-Universität,
Münster, Germany

Abstract The role of posterior correction and fusion in thoracolumbar and lumbar scoliosis as well as pedicle screw instrumentation in scoliosis surgery are matters of debate. Our hypothesis was that in lumbar and thoracolumbar scoliosis, segmental pedicle screw instrumentation is safe and enables a good frontal and sagittal plane correction with a fusion length comparable to anterior instrumentation. In a prospective clinical trial, 12 consecutive patients with idiopathic thoracolumbar or lumbar scolioses of between 40° and 60° Cobb angle underwent segmental pedicle screw instrumentation. Minimum follow-up was 4 years (range 48–60 months). Fusion length was defined according to the rules for Zielke instrumentation, normally ranging between the end vertebrae of the major curve. Radiometric analysis included coronal and sagittal plane correction. Additionally, the accuracy of pedicle screw placement was measured by use of postoperative computed tomographic scans. Major curve correction averaged 64.6%, with a loss of correction of 3°. The tilt angle was corrected by 67.0%, the compensatory thoracic curve cor-

rected spontaneously according to the flexibility on the preoperative bending films, and led to a satisfactory frontal balance in all cases. Average fusion length was the same as that of the major curve. Pathological thoracolumbar kyphosis was completely corrected in all but one case. One patient required surgical revision with extension of the fusion to the midthoracic spine due to a painful junctional kyphosis. Eighty-five of 104 screws were graded “within the pedicle”, 10 screws had penetrated laterally, 5 screws bilaterally and 4 screws medially. No neurological complications were noted. In conclusion, despite the limited number of patients, this study shows that segmental pedicle screw instrumentation is a safe and effective procedure in the surgical correction of both frontal and sagittal plane deformity in thoracolumbar and lumbar scoliosis of less than 60°, with a short fusion length, comparable to anterior fusion techniques, and minimal loss of correction.

Key words Idiopathic scoliosis · Surgery · Pedicle screw · Posterior instrumentation

Introduction

Posterior instrumentation and fusion for treatment of idiopathic scoliosis has become popular with the introduc-

tion of Harrington instrumentation (HI) [15]. Newer posterior multisegmental instrumentation systems, like Cotrel-Dubousset instrumentation (CDI), offer the advantages of better frontal and sagittal plane correction and provide primary stability [4, 7, 8, 18, 23]. Whether CDI using hooks

enables a shorter fusion length, saving distal motion segments, compared to HI remains a matter of debate [2, 18, 19, 22, 27]. Since introduction of the VDS-Zielke instrumentation [44], this procedure has become an accepted technique for correction of thoracolumbar and lumbar curves [11, 12, 20, 28, 29, 31–33]. In comparison to CDI, VDS-Zielke is reported to provide a better frontal plane correction with a shorter fusion length [12, 29, 38]. In thoracic scoliosis, Suk et al. demonstrated a shorter fusion length and a better three-dimensional correction with posterior pedicle screw instrumentation compared to hooks [39]. However, both neural and vascular, as well as visceral, structures are at potential risk from misplaced pedicle screws [6, 10, 16, 35, 40–42]. In order to evaluate frontal and sagittal plane correction in thoracolumbar and lumbar scoliosis by use of segmental pedicle screw instrumentation, with special regard to fusion length and accuracy of pedicle screw placement, a prospective clinical trial was conducted.

Materials and methods

Twelve consecutive patients, eight adolescents and four adults with idiopathic thoracolumbar and lumbar scoliosis ranging from 41° to 59° Cobb angle were surgically treated with the Münster Posterior Doublerod System (MPDS, Schäfer Micromed GmbH, Göppingen, Germany). The adult patients (aged 21–34 years) had curves comparable to the adolescent patients, without degenerative changes in the area of the compensatory curves, and with approximately the same flexibility of the major and compensatory curves on the bending films. In particular, any possibility that they were suffering from de novo scoliosis, which has a completely different etiology, was ruled out.

The MPDS consists of two interlinked 5- or 6-mm solid, fluted rods with pedicle screws of 6.0 and 6.5 mm in diameter. The screw-rod interface is secured using cap nuts with integrated set screws. The indication for surgery was curve progression in the adolescent patients and persistent, disabling back pain in the adult group.

Surgical technique

The selection of fusion levels was performed according to the rules established for Zielke instrumentation [11, 44], normally ranging between the end vertebrae of the major curve. These fusion levels were chosen because we were sure, and wanted to prove, that with pedicle screw instrumented fusion in moderate curves (less than 60° Cobb angle) the extent of the fusion could be kept as short as with anterior instrumentation without adverse effects. A few exceptions were made. The fusion was extended an additional level distally in two curves, in which the distal end vertebra was horizontalized by less than 15° on the reverse bending films, and in which a convex disc space gapping below the lower end vertebra was found. This procedure was also proposed by Zielke for VDS in comparable instances, and is particularly useful in avoiding the so-called “adding-on phenomenon”. In two cases with a partially rigid thoracic compensatory curve, the instrumentation was carried out one segment short of the cranial end vertebra, in order to let this segment (disc space) contribute to spontaneous correction of the compensatory thoracic curve. At this point it must be mentioned that in all cases we would have chosen the same fusion length had we performed an anterior instrumented fusion with VDS. In choosing the fusion levels, we also took the sagittal plane into consider-

ation. In particular, the option of ending the instrumentation below the pathological kyphosis was ruled out. A standard pedicle screw placement technique was performed using the “Weinstein” approach [42], with segmental pedicle screw fixation on the convexity of the curve, including the apical vertebra in every case (Figs. 1, 2). After entering and widening the pedicle with an awl, the pedicular cavity was explored with a sounder to verify intact pedicular walls and exclude any cortical penetration. To confirm appropriate length and placement of the screws, anteroposterior and lateral fluoroscopy was used during surgery. Curve correction was achieved by the rod rotation maneuver of the contoured convex rod, according to the principles established by Cotrel and Dubousset [7, 8], followed by slight convex compression and concave distraction. The rationale for using a pedicle screw at every level on the convexity is that the rod rotation maneuver is the major force for obtaining correction. We therefore aimed at as much force distribution as possible. Finally, the frame construct was completed with two transverse connectors followed by spinal arthrodesis with autologous iliac bone grafts.

Evaluation

All patients underwent frontal and sagittal plane analysis on long cassette posteroanterior and lateral standing radiographs preoperatively, postoperatively, 2 years postoperatively (follow-up 1) and at final follow-up (follow-up 2). Minimum follow-up was 4 years (range 48–60 months, mean 52 months). For evaluation of curve flexibility and fusion levels, preoperative maximum supine bending films were obtained. Primary and cranial compensatory curves were analyzed according to Cobb as well as measurement of the tilt angle of the lowest instrumented vertebra. Frontal plane decompensation was measured by drawing a line between the spinous processes of C7 and S1.

The sagittal curves were measured with the Cobb method from T4 to T12 (thoracic spine), from T10 to L2 (thoracolumbar junction) and from L1 to S1 (lumbar spine). Angles were considered to be physiological if thoracic kyphosis was in the range of +20° to +40°, the thoracolumbar junction in the range of +10° to -10° and lumbar lordosis in the range of -30° to -55° [3]. Data collection and radiographic measurements were performed by an unbiased observer.

In order to evaluate the accuracy of pedicle screw placement, computed tomographic (CT) scans (Tomoscan LX, Philips, Hamburg, Germany) were performed postoperatively. Each screw was studied with 3-mm-thick sections, strictly parallel to the longitudinal axis of each screw. To minimize artifacts, a special filter and an individually adjusted window (2500–4000HE) were used (Figs. 3, 4). All screws were evaluated by a radiologist and two spine surgeons for intrapedicular placement and length. Any penetration of bony cortex was registered and measured in millimeters with a

Fig. 1A–E A 17-year-old female with a progressive idiopathic thoracolumbar curve of 48°. **A** Segmental pedicle screw instrumentation and fusion from T11 to L3. Good frontal curve correction with abalanced spine is evident on both postoperative (**B**) and 4-year follow-up films (**C**). The thoracic hypokyphosis is corrected from 12° (**D**) to 20° (**E**), resulting in a normal thoracolumbar and lumbar profile

Fig. 2A–E A 16-year-old female with a progressive idiopathic thoracolumbar curve of 50°. **A** Segmental pedicle screw instrumentation and fusion from T10 to L3. Good frontal curve correction with a balanced spine is evident on both postoperative (**B**) and 4-year follow-up films (**C**). Note the slight adding-on with convex disc space gapping of L3/L4, which is stable during follow-up. **D, E** Correction of thoracolumbar kyphosis and thoracic hypokyphosis

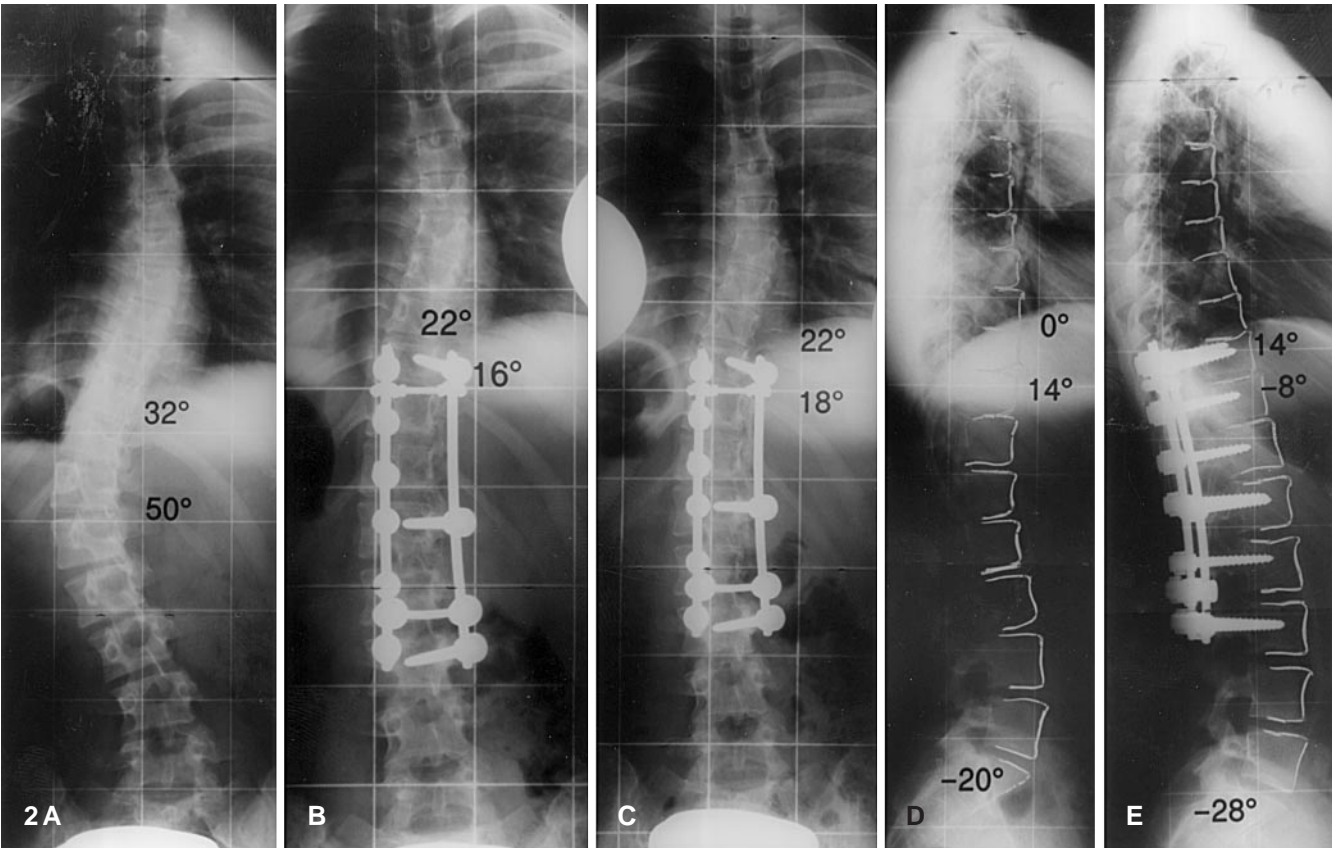
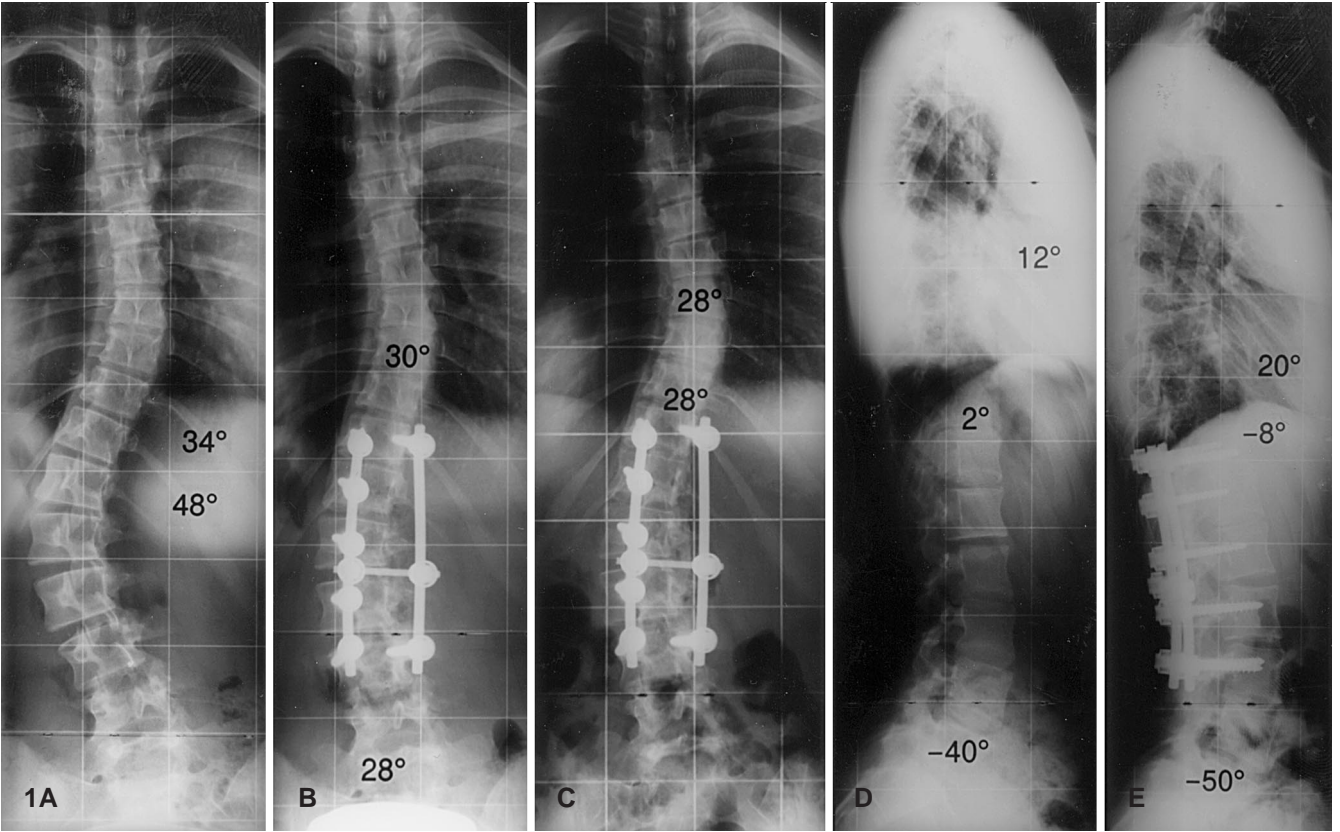
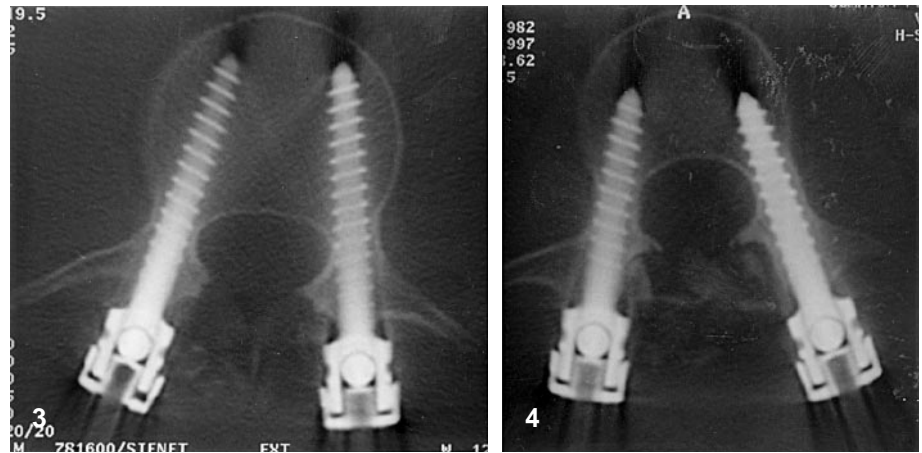


Fig. 3 Computed tomographic (CT) scan of L3 with both pedicle screws strictly intra-pedicular

Fig. 4 CT scan of L1 in a left-sided thoracolumbar curve, with lateral pedicle screw penetration on the right due to a too large screw diameter



measuring device installed in the Tomoscan. In cases of differing results between the examiners, a consensus decision was made.

Results

The length of the thoracolumbar or lumbar major curve averaged 4.8 segments (range 4–5 segments), the fusion length averaged 5.0 segments (range 4–6 segments). The average preoperative major curve was 52.5° (41° – 59°), reduced with side bending to 30.4° (a 42.1% reduction). Postoperative curve correction was 64.6%, to 18.6° , and at final follow-up 59.2% (21.4°), giving an average loss of correction of slightly less than 3° (Fig. 4). The preoperative upper compensatory curve measured 28.7° on average (range 24° – 34°), with a flexibility of 58.2% on side bending. Spontaneous postoperative curve correction averaged 55.4%, with a stable course during follow-up (Fig. 5). The tilt angle of the lowest instrumented vertebra was corrected from 28.5° (range 19° – 36°) to 8.7° (69.5% correction) and measured 9.4° (range 2° – 16°) at the latest follow-up. Spinal decompensation in the frontal plane averaged 2.8 cm (0–4 cm) preoperatively and 0.9 cm (0–1.5 cm) at final follow-up. Five patients showed spinal decompensation of more than 2 cm (2–4 cm); all 12 patients had a plumb line shift of less than 2 cm at final follow-up.

The sagittal plane analysis is illustrated in Fig. 6. Six patients had a pathological thoracolumbar kyphosis of more than 10° , which was corrected to normal values in all but one case.

Concerning accuracy of pedicle screw placement, the overall results are shown in Table 1. In total, 104 screws had been inserted between T10 and L4. Eighty-five screws were graded as wholly within the pedicle (Fig. 3), ten screws had penetrated the lateral pedicular wall by less than 3 mm, of which six screws were in direct contact with the medial pedicular wall (Fig. 4). Five screws had penetrated bilaterally by less than 2 mm on either side, due to a too large screw diameter. Four screws had penetrated medially by less than 2 mm.

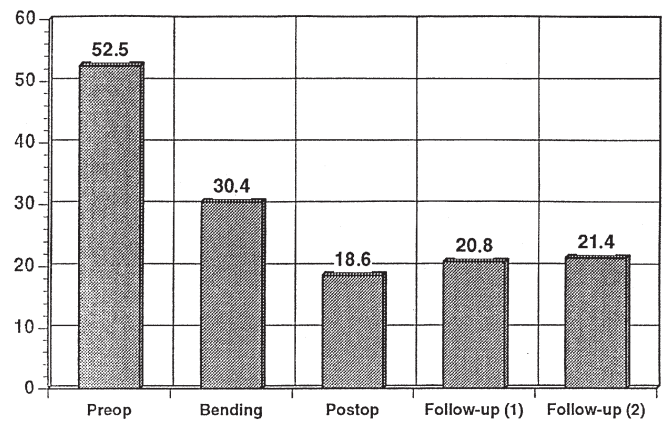


Fig. 5 Average Cobb angle of major curve preoperatively, on bending films, postoperatively, and at 2-years and final follow-up

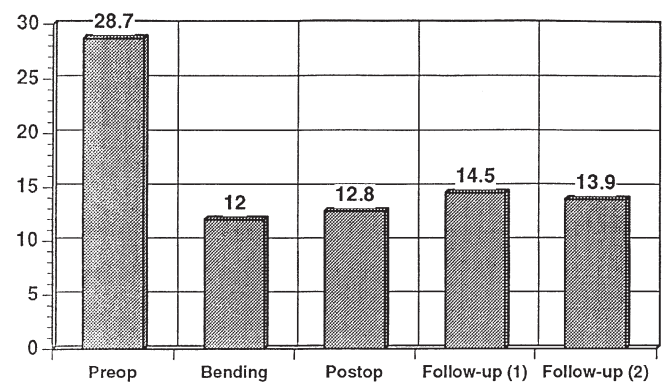
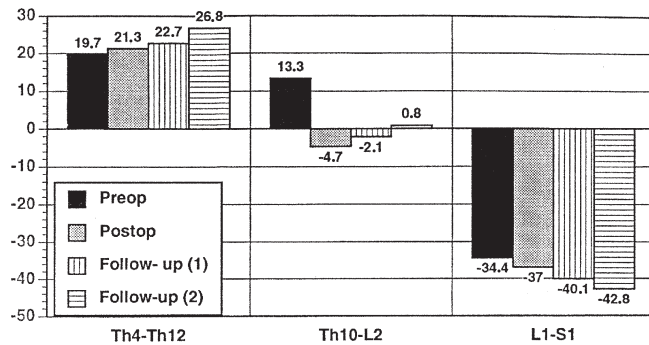


Fig. 6 Average Cobb angle of secondary thoracic curve preoperatively, on bending films, postoperatively, and at 2-years and final follow-up

Blood loss averaged 1425 ml (range 350–4000 ml) and OR time 234 min (range 180–300 min). Two adult patients complained of residual back pain 2 years postoperatively. In one patient (male, 38 years) the symptoms resolved spontaneously and he reported at final follow-up that he

Table 1 Overall results of accuracy of pedicle screw placement

| Vertebra | No. of screws | Intra-pedicular | Medial penetration | Bilateral penetration | Lateral penetration |
|------------|---------------|-----------------|--------------------|-----------------------|---------------------|
| T10 | 4 | 2 | 0 | 1 | 1 |
| T11 | 22 | 17 | 1 | 2 | 2 |
| T12 | 14 | 12 | 1 | 1 | 0 |
| L1 | 20 | 15 | 1 | 1 | 3 |
| L2 | 14 | 12 | 0 | 0 | 2 |
| L3 | 22 | 19 | 1 | 0 | 2 |
| L4 | 8 | 8 | 0 | 0 | 0 |
| Total | 104 | 85 | 4 | 5 | 10 |
| Percentage | 100 | 81.7 | 3.8 | 4.8 | 9.6 |

**Fig. 7** Average values of the sagittal plane (thoracic spine, thoracolumbar junction, lumbar spine) preoperatively, postoperatively and at 2-years and final follow-up

had successfully participated in a marathon run. The other adult patient (female, 32 years) had residual thoracolumbar kyphosis of more than 10° at follow-up, and developed additional junctional kyphosis above the instrumentation, which made extension of instrumented fusion to T5 necessary 3 years postoperatively. Today, 1 year after this second operation, she is completely asymptomatic and has returned to full-time work. A slight distal adding-on phenomenon was seen twice (Fig. 2). In one patient, spinal decompensation of 3 cm in the frontal plane preoperatively worsened to 4 cm postoperatively. Brace treatment for a 3-month period was therefore conducted, which led to recompensation to 0.5 cm within the brace and 1 cm at final follow-up. There were no neurological complications in any of the patients. No broken screws or rods or other signs of pseudarthrosis were noted at follow-up.

Discussion

Since 1976, Zielke Instrumentation (VDS) has gained increasing popularity in the surgical treatment of thoracolumbar and lumbar scoliosis [44]. Reports comparing the results of VDS with those of both HI and CDI have shown

the former to offer superior curve correction with a shorter fusion length [12, 29, 38]. Whether CDI using hooks enables a shorter fusion length, saving distal motion segments, compared to HI remains unresolved [2, 18, 19, 22, 27]. In this study, the same criteria for fusion length as with Zielke-VDS were applied using segmental pedicle screw instrumentation with a fusion from end vertebra to end vertebra in thoracolumbar and lumbar curves of less than 60° Cobb angle.

Final curve correction averaged 59% in this study, which is slightly less than the values given in the literature on anterior instrumentation techniques [11, 12, 28, 44]. However, it is important not to overcorrect the major curve with respect to the flexibility of the compensatory thoracic curve, because this will inevitably lead to either spinal decompensation in the frontal plane or disc space gapping below the lowest instrumented vertebra as a compensatory reaction, the latter being also called the “adding-on phenomenon”. In all except two cases, where overcorrection led to a slight “adding-on phenomenon” distally, the amount of correction achieved led to a well-balanced spine without any disc space gapping. The average final curve correction in this study was superior to that reported by other authors using multisegmental hook instrumentation, which ranges from 28 to 52% [17, 37]. This observation is confirmed by both Barr et al. and Hamill et al., who compared lumbar pedicle screws versus hooks in double major curves with fusion of both the thoracic and lumbar spine. The two studies found an average correction of the lumbar curve of 67% and 52%, respectively, which was significantly greater with pedicle screws than with hooks [1, 14]. The big advantage of pedicle screws over hooks is that the apical vertebra can be instrumented without risk of compression of the conus medullaris, and therefore correction of the apical vertebral translation and thus correction of the frontal plane is much better.

In this study, loss of frontal curve correction was minimal, averaging slightly less than 3° over a 4-year follow-up. As already reported by Suk et al. concerning pedicle screw fixation in thoracic scoliosis [39], loss of correction using pedicle screws appears to be less compared to hooks. Reports on multisegmental hook instrumentation for thoracolumbar and lumbar curves found an average loss of frontal curve correction of between 5° and 11° during a 2- to 4-year follow-up [1, 37]. Correction of the lowest instrumented vertebra averaged 67% in this study, and is comparable to the data given in the literature. In comparison with hooks, pedicle screws enable a significantly better correction of the vertebral tilt [1, 14].

Sagittal plane control with VDS is reported to be critical, as some authors have experienced a kyphogenic effect [20, 28, 32]. Other studies, however, have demonstrated that, due to segmental derotation, sagittal plane control or even realignment is possible [11, 12, 44]. The results of this study show that segmental pedicle screw instrumentation led to an excellent correction of thoracolumbar kypho-

sis. This is mainly related to the rod rotation maneuver of the convex rod followed by segmental compression. However, in curves greater than 60° Cobb angle, sagittal plane control might be difficult and anterior instrumentation techniques should be preferred.

There is a paucity of information in the current literature on the accuracy of pedicle screws in scoliosis surgery. Several studies have shown that roentgenogram-based assessment of accuracy of pedicle screw placement reveals an unacceptably high rate of false-negative and false-positive results [6, 9, 42]. However, CT scans have proven to provide a reliable assessment of pedicle screw placement [9, 10]. In the present study, 82% of all screws were strictly intrapedicular. While earlier studies have demonstrated a similar accuracy rate in the thoracolumbar spine, they also found a cortical penetration rate of 25% in thoracic scoliosis [13, 25]. Merloz et al. reported a cortical penetration rate of 14% (4 out of 28 screws) in the thoracolumbar spine in scoliosis surgery using a computer-assisted guidance technique [30]. In 11 out of 19 screws penetrating the pedicular cortex in his study the screw diameter was too large, either penetrating laterally with direct contact with the medial wall or penetrating bilaterally. Several studies on the morphometry of pedicles in normal spines have shown thoracolumbar pedicle diameters of between 6 and 10 mm, on average [40, 45]. However, Liljenqvist et al. analyzed pedicle dimensions in idiopathic scoliosis, and found a significant intravertebral deformity with thoracolumbar pedicle diameters of between 5 and 7 mm and smaller pedicles in the concavity, especially in the thoracic spine [26]. We therefore recommend the use of 5 mm screws in the lower thoracic spine and 6 mm screws in the lumbar spine.

In a historical cohort study on complications of pedicle screw instrumentation in 3498 patients, Yuan et al. report a neurological complication rate of about 1% [43]. Brown et al. analyzed the complication rate of pedicle screw instrumentation in 120 patients with scoliosis, and found a

neurological complication rate due to screw misplacement of less than 1%. The authors conclude that pedicle screw instrumentation inserted by properly trained surgeons is safe even in a pediatric and adolescent population [5]. In two larger studies on pedicle screw instrumentation in the lumbar spine for double major curves in idiopathic scoliosis, the authors did not have any complications related to pedicle screw misplacement [1, 14].

Despite a cortical penetration rate of 18% in this study, there were no complications related to the pedicle screw fixation. The most frequent side of cortical penetration is lateral, which is due to the fact that the medial pedicular cortex is between two and three times thicker than the lateral cortex [21, 34]. Even though lateral pedicle penetration rarely is of clinical relevance, it should be avoided, since in the thoracic spine the lung and segmental vessels and in the lumbar spine the superior nerve root might be injured. Medial pedicle screw penetration might lead to spinal cord or nerve root injury. There is also a risk of indirect compression of the cord or nerve roots by a hematoma caused by an injury of the pedicular wall. Papin et al. reported on a case of spinal cord compression in a thoracic scoliosis due to two medially misplaced pedicle screws [35]. The so-called "safe zone" of 4 mm in the thoracolumbar spine, in which a medial screw penetration is tolerated [10], can only be applied to normal spines. In scoliosis, both Rauschnig and Liljenqvist have demonstrated that there is a shift of the dural sack to the concavity of each curve, which is maximal at the apex [24, 36]. Therefore, any medial cortical pedicle penetration must be avoided, especially on the concavity of the curves.

In conclusion, the results of this study demonstrate that segmental pedicle screw instrumentation for correction and fusion of thoracolumbar and lumbar scoliosis of less than 60° Cobb angle is a safe and effective procedure with good frontal and sagittal curve correction, minimal loss of correction and a short fusion length, comparable to anterior instrumentation techniques.

References

1. Barr SJ, Schuette AM, Emans JB (1997) Lumbar pedicle screw versus hooks. *Spine* 22:1369–1379
2. Behensky H, Krismer M, Bauer R (1998) Comparison of spinal mobility after Harrington and CD instrumentation. *J Spinal Disord* 11:155–162
3. Bernard M, Bridwell KH (1989) Segmental analysis of the sagittal plane alignment of the normal thoracic and lumbar spines and thoracolumbar junction. *Spine* 7:717–721
4. Bridwell KH, Betz R, Capelli AM, Huss G, Harvey C (1991) Sagittal plane analysis in idiopathic scoliosis patients treated with Cotrel-Dubousset instrumentation. *Spine* 7:644–649
5. Brown CA, Lenke LG, Bridwell KH, Geideman WM, Hasan SA, Blanke K (1998) Complications of pediatric thoracolumbar and lumbar pedicle screws. *Spine* 23:1566–1571
6. Castro WHM, Halm H, Jerosch J, Malm J, Steinbeck J, Blasius S (1996) Accuracy of pedicle screw placement in lumbar vertebrae. *Spine* 21:1320–1324
7. Cotrel Y, Dubousset J, Guillaumat M (1988) New universal instrumentation in spinal surgery. *Clin Orthop* 227:10–23
8. Dubousset J, Cotrel Y (1989) Die CD-Instrumentation in der Behandlung von Wirbelsäulendeformitäten. *Orthopäde* 18:118–127
9. Farber GL, Place HM, Mazur RA, Casey Jones DE, Damiano TR (1995) Accuracy of pedicle screw placement in lumbar fusions by plane radiographs and computed tomography. *Spine* 20:1494–1499

10. Gertzbein SD, Robbins SE (1990) Accuracy of pedicular screw placement in vivo. *Spine* 15:11–15
11. Giehl JP, Zielke K, Hack HP (1989) Die Ventrale Derotationsspondylodese nach Zielke. *Orthopäde* 18:101–117
12. Halm H, Liljenqvist U, Castro WHM, Jerosch J (1995) Die operative Behandlung idiopathischer thorakolumbaler Skoliosen: Cotrel- Dubousset Instrumentation versus Ventrale Derotationsspondylodese. *Z Orthop* 133:282–288
13. Halm H, Liljenqvist U, Link T, Jerosch J, Winkelmann W (1996) Computertomographische Lagekontrolle von Pedikelschrauben in der Skoliosechirurgie. *Z Orthop* 134: 492–497
14. Hamill CL, Lenke LG, Bridwell KH, Chapman MP, Blanke K, Baldus C (1996) The use of pedicle screw fixation to improve correction in the lumbar spine of patients with idiopathic scoliosis. *Spine* 21:1241–1249
15. Harrington PR (1962) Treatment of scoliosis. *J Bone Joint Surg* 44:591–602
16. Heini P, Schöll E, Wyler D, Eggli S (1998) Fatal cardiac tamponade associated with posterior spinal instrumentation. *Spine* 23:2226–2230
17. Hopf Ch (1990) Indikation und Ergebnisse des CD-Verfahrens in der operativen Skoliosebehandlung. *Beitr Orthop Traumatol* 37:401–413
18. Humke T, Grob D, Scheier H, Siegrist H (1995) Cotrel-Dubousset and Harrington instrumentation in idiopathic scoliosis: a comparison of long-term results. *Eur Spine J* 4:280–283
19. King HA, Moe JH, Bradford DS, Winter RB (1983) The selection of fusion levels in thoracic idiopathic scoliosis. *J Bone Joint Surg Am* 65:1302–1313
20. Kostuik JP, Carl A, Ferron S (1989) Anterior Zielke instrumentation for spinal deformity in adults. *J Bone Joint Surg Am* 71:898–904
21. Kothe R, O'Holleran JD, Liu W, Panjabi MM (1996) Internal architecture of the thoracic pedicle. *Spine* 21:264–270
22. Lenke LD, Bridwell KH, Baldus C, Blanke K, Schoenacker P (1993) Ability of Cotrel-Dubousset instrumentation to preserve distal lumbar motion segments in adolescent idiopathic scoliosis. *J Spinal Disord* 6:339–350
23. Lenke LD, Bridwell KH, Blanke K, Baldus C, Weston J (1998) Radiographic results of arthrodesis with Cotrel-Dubousset instrumentation for the treatment of adolescent idiopathic scoliosis. *J Bone Joint Surg Am* 80: 807–814
24. Liljenqvist U (1999) Pedicle morphology in thoracic scoliosis. Presented at the Sixth International Meeting on Advanced Spine Techniques, Vancouver, Canada, July 1999
25. Liljenqvist U, Halm H, Link T (1997) Pedicle screw instrumentation of the thoracic spine in idiopathic scoliosis. *Spine* 22:2239–2245
26. Liljenqvist U, Link T, Halm H (1999) Morphometric analysis of thoracic and lumbar vertebrae in idiopathic scoliosis. *Spine* (in press)
27. Lonstein JE (1995) Idiopathic scoliosis. In: Lonstein JE, Bradford DS, Winter RB, Ogilvie JW (eds) *Moe's textbook of scoliosis and other spinal deformities*, 3rd edn. W.B. Saunders, Philadelphia, pp 219–256
28. Lowe TG, Peters JD (1993) Anterior spinal fusion with Zielke instrumentation for idiopathic scoliosis. *Spine* 18: 423–429
29. Luk KDK, Leong JCY, Reyes L, Hsu LCS (1989) The comparative results of treatment in idiopathic thoracolumbar and lumbar scoliosis using the Harrington, Dwyer and Zielke instrumentation. *Spine* 14:275–280
30. Merloz P, Tonetti J, Pittet L, Coulomb M, Lavallee S, Sautot P (1998) Pedicle screw placement using image guided techniques. *Clin Orthop* 354:39–48
31. Moe JH, Purcell GA, Bradford DS (1983) Zielke instrumentation (VDS) for correction of spinal curvature. *Clin Orthop* 180:133–153
32. Moskowitz A, Trommanhauser S (1993) Surgical and clinical results of scoliosis surgery using Zielke instrumentation. *Spine* 18:2444–2451
33. Ogiela DM, Chan DPK (1986) Ventral derotation spondylodesis. *Spine* 11:18–22
34. Panjabi MM, O'Holleran JD, Crisco JJ, Kothe R (1997) Complexity of the thoracic pedicle anatomy. *Eur Spine J* 6: 19–24
35. Papin P, Arlet V, Marchesi D, Rosenblatt B, Aebi M (1999) Unusual presentation of spinal cord compression related to misplaced pedicle screws in thoracic scoliosis. *Eur Spine J* 8:156–160
36. Rauschnig W (1995) Anterior surgery of the thoracolumbar junction and the lumbar spine. Anatomy, complications, safeguards. Presented at the Anterior Spine Surgery, Standards and New Techniques meeting, Berlin, October 1995
37. Richards BS, Herring JA, Johnston CE, Birch JG, Roach JW (1994) Treatment of adolescent idiopathic scoliosis using Texas Scottish Rite Hospital instrumentation. *Spine* 19:1598–1605
38. Suk SI, Lee CK, Chung SS (1994) Comparison of Zielke VDS and Cotrel-Dubousset instrumentation in the treatment of idiopathic lumbar and thoracolumbar scoliosis. *Spine* 19:419–429
39. Suk SI, Lee CK, Min HJ, Cho KH, Oh JH (1994) Comparison of Cotrel-Dubousset pedicle screws and hooks in the treatment of idiopathic scoliosis. *Int Orthop* 18:341–346
40. Vaccaro AR, Rizzolo SJ, Allardyce TJ, Ramsey M, Salvo J, Balderston RA, Cotler JM (1995) Placement of pedicle screws in the thoracic spine. 1. Morphometric analysis of the thoracic vertebrae. *J Bone Joint Surg Am* 77:1193–1199
41. Vaccaro AR, Rizzolo SJ, Balderston RA, Allardyce TJ, Garfin SR, Dolinskas C (1995) Placement of pedicle screws in the thoracic spine. 2. An anatomical and radiographical assessment. *J Bone Joint Surg Am* 77:1200–1206
42. Weinstein JN, Spratt K, Spengler D, Brick C, Reid S (1988) Spinal pedicle fixation: reliability and validity of roentgenogram-based assessment and surgical factors on successful screw placement. *Spine* 13:1012–1018
43. Yuan HA, Garfin SR, Dickman CA, Mardjetko SM (1994) A historical cohort study of pedicle screw fixation in thoracic, lumbar, and sacral spinal fusions. *Spine* 19:2279S–2296S
44. Zielke K (1982) Ventrale Derotationsspondylodese. Behandlungsergebnisse bei Idiopathischen Lumbalskoliosen. *Z Orthop* 120:320–329
45. Zindrick M, Wiltse L, Dornik A (1987) Analysis of morphometric characteristics of the thoracic and lumbar pedicles. *Spine* 12:160–166